

# UC Davis

## Dermatology Online Journal

### Title

Exogenous ochronosis

### Permalink

<https://escholarship.org/uc/item/0v91k51s>

### Journal

Dermatology Online Journal, 20(12)

### Authors

Nagler, Arielle  
Hale, Christopher S  
Meehan, Shane A  
et al.

### Publication Date

2015

### DOI

10.5070/D32012025053

### Copyright Information

Copyright 2015 by the author(s). This work is made available under the terms of a Creative Commons Attribution-NonCommercial-NoDerivatives License, available at <https://creativecommons.org/licenses/by-nc-nd/4.0/>

Peer reviewed

**Case Presentation**

**Exogenous ochronosis**

**Arielle Nagler MD, Christopher S. Hale MD, Shane A. Meehan MD, and Marie Leger MD PhD**

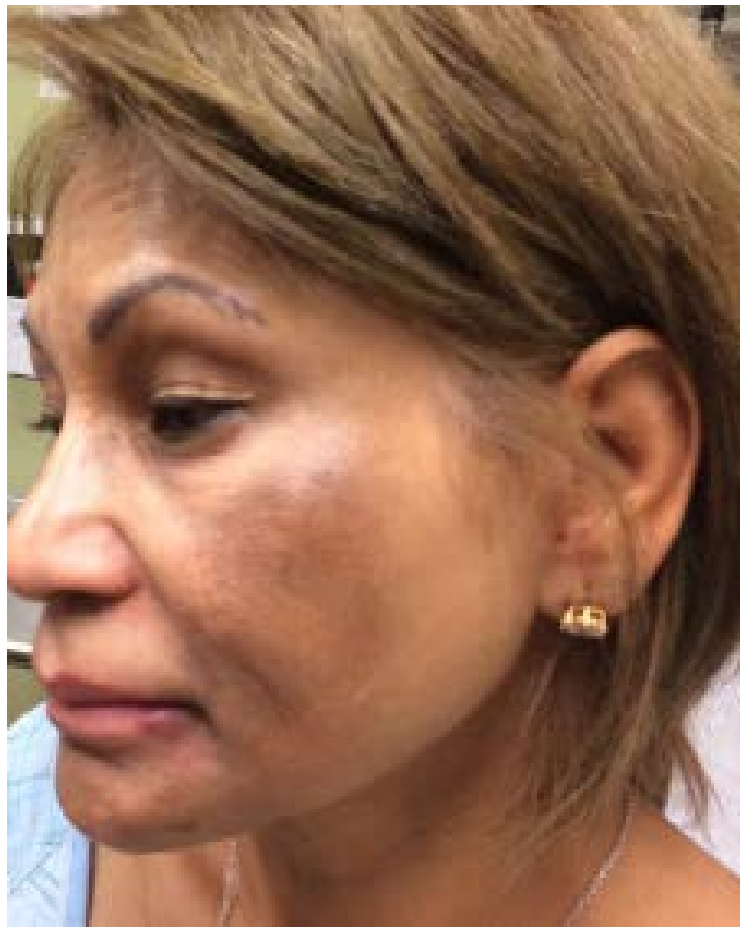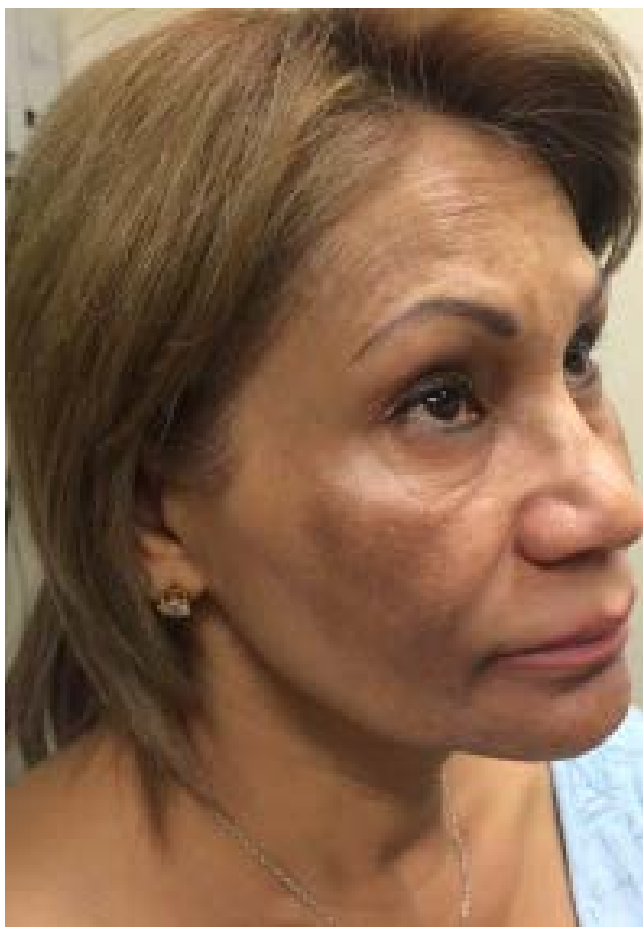**Dermatology Online Journal 20 (12): 5**

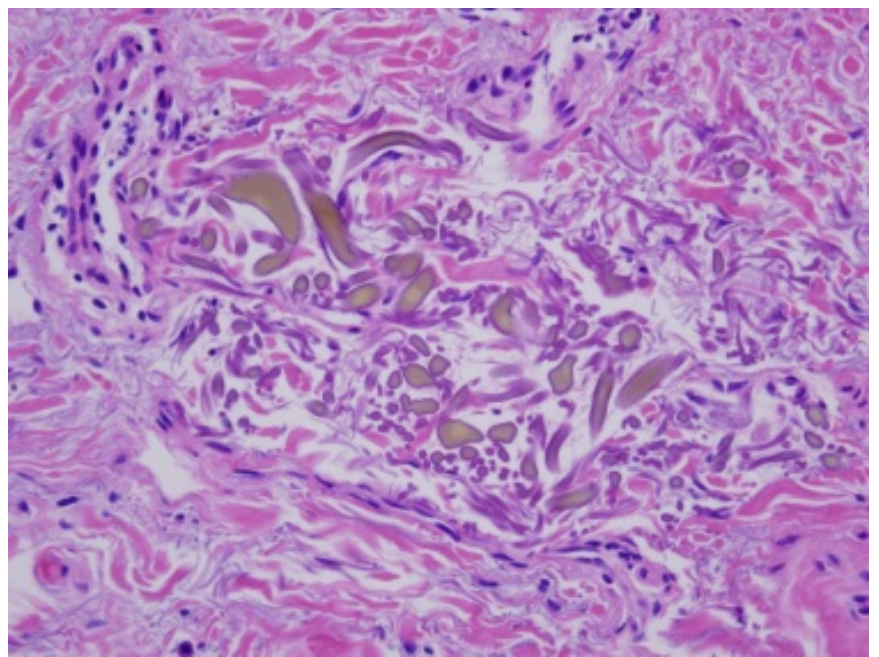
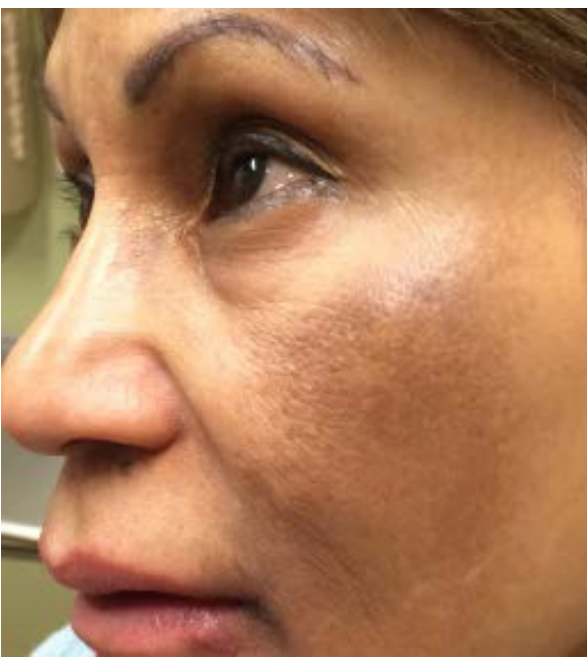**New York University School of Medicine**

**Special Guest Editor: Nicholas A. Soter, MD**

**Abstract**

We present a case of exogenous ochronosis in a 53-year-old woman with skin type IV, who used a topical hydroquinone preparation of an unknown concentration for several years. Traditionally, exogenous ochronosis was thought to occur exclusively in patients with darker skin types who use high concentrations of hydroquinone cream. Reports now document cases in patients of all skin types and in patients even using low concentrations of hydroquinone cream for short periods of time. Although the incidence of exogenous ochronosis in the United States is unclear, it may be more common than many clinicians believe. It is important for clinicians and patients to be aware of exogenous ochronosis in order to prevent exacerbation in patients with this rare side effect.





## Case synopsis

**History:** A 53-year-old woman presented to the Skin and Cancer Unit of the Ronald O. Perelman Department of Dermatology in January, 2014, for evaluation of hyperpigmented areas on the cheeks. The patient states that she had normal skin coloring until she went to a spa approximately six years prior for an unknown laser treatment to improve her complexion. The procedure left dark pigmentation on cheeks, which displeased her. She returned to the same spa and received hydroquinone cream to apply to her face as a bleaching cream. She does not recall the concentration, but states that she was told it was a stronger preparation than that available over the counter. She initially saw appreciable improvement with the topical hydroquinone treatment. However, after using the topical hydroquinone cream for several years, she slowly noticed darkening of her skin despite continued use of the hydroquinone cream. She denies any associated erythema or sensations of pruritus, burning, or pain. She discontinued the hydroquinone cream and presented to several outside dermatologists. A biopsy was performed at an outside office. The patient denies a history of dark urine, joint pains, or others areas of dyspigmentation. She has no family history of alkaptonuria, but her sister had a similar experience after using the same cream.

**Physical examination:** The patient has skin type IV, with mottled, brown, hyperpigmented macules on the cheeks. The hyperpigmentation has a faint, grey-blue hue. The hyperpigmented areas are more confluent centrally and have angulated, linear borders. No other areas of hyperpigmentation were present on a complete physical examination. Her sclerae were white.

**Laboratory studies:** A complete blood count and urinalysis were normal. Urine organic acids, which included homogentisic acid were normal. The aspartate aminotransferase was elevated at 36 U/L (normal range 10 to 35) and total cholesterol at 228 mg/dL (normal < 200).

**Histopathology:** There are dense, curvilinear bands of homogeneous, metachromatic material within the dermis.

**Diagnosis:** Exogenous ochronosis

**Comment:** Ochronosis first was described by Virchow in 1866 as brownish-yellow pigment (ochre) deposited in the connective tissue of various organs that include the skin [1]. Clinically, these microscopic deposits produce visible, blue-grey hyperpigmentation. Ochronosis may be either endogenous or exogenous in its etiology. Both types of ochronosis are histopathologically identical and show distinctive, yellow-brown, banana-shaped bodies in the papillary dermis.

Endogenous ochronosis, or alkaptonuria, is an autosomal recessive condition that results in a deficiency of the enzyme homogentisic acid oxidase. Homogentisic acid oxidase is involved in the biochemical degradation of homogentisic acid into acetoacetic and fumaric acids. The deficiency of this enzyme results in the accumulation of homogentisic acid, which is deposited in connective tissue and cartilage. By the third decade of life, hyperpigmentation clinically is apparent, particularly in the cartilage of the ears and the sclerae. Excess homogentisic acid also is excreted into the urine and produces black-staining urine, which darkens upon standing. Elevated homogentisic acid may be detected in the urine via laboratory testing.

Exogenous ochronosis first was described in 1906 by Pick as the deposition of ochre pigment in the dermis in response to certain topical therapies [2]. Unlike endogenous ochronosis, there is no systemic involvement and areas of hyperpigmentation are localized to those treated with the inducing topical therapy, most commonly the cheeks [3]. In 1976, exogenous ochronosis was described in conjunction with topical hydroquinone use [4]. Whereas hydroquinone is the most commonly cited cause of exogenous ochronosis, it also has been reported with the use of other topical therapies, which include phenol and resorcinol [5]. The diagnosis of exogenous ochronosis relies on the clinical presentation and characteristic histopathologic findings without a clinical history or laboratory data consistent with alkaptonuria. Our patient presented with initial lightening and subsequent darkening of her cheeks after prolonged use of topical hydroquinone cream with clinical and histopathologic confirmation of ochronosis, normal urine studies, and no evidence of systemic involvement on examination or history.

Exogenous ochronosis initially was reported almost exclusively in South African black patients who used higher concentrations of hydroquinone cream [3]. Since then many additional case reports have been published, which include patients of varying skin types who used different concentrations and preparations of hydroquinone. Exogenous ochronosis has been reported in Indian women [6] but also in women with lighter skin types, which include Asian women [7] and Hispanic women [8]. Although exogenous ochronosis still is thought to be more common with the use of higher concentrations of hydroquinone cream, it also has been reported in patients using hydroquinone cream in concentrations as low as 2 to 4% in the United States [3, 8-11]. Additionally, the development of ochronosis does not require extended durations of use; some cases have been reported after as little as two months of 2% hydroquinone cream use [10]. The actual incidence of exogenous ochronosis in the United States is not known for many reasons, which include the facts that many cases go unreported and that physicians often are not involved in the over-the-counter use of hydroquinone cream.

The etiology of hydroquinone-induced hyperpigmentation has yet to be elucidated, but there are several hypotheses. Melanocytes may be involved because most cases involve sun-exposed sites [12]. One study in gold fish found that lower concentrations of hydroquinone cream inhibited tyrosinase, but higher concentrations of hydroquinone cream activated tyrosinase and increased melanin synthesis [13]. Another hypothesis is that topically applied hydroquinone cream inhibits the activity of homogentisic acid oxidase locally in the skin and causes an accumulation of homogentisic acid, which polymerizes to form ochronotic pigment [14]. It also is possible that exogenous ochronosis is related to another ingredient that is common to many preparations of hydroquinone cream [15]. Interestingly, our patient reported that her sister had a similar response to the same cream. This fact may suggest a possible a genetic predisposition or that there was something specific in their preparations of hydroquinone that induced exogenous ochronosis.

The treatment of exogenous ochronosis is challenging but improving in the age of laser therapies. Treatment with topical retinoids, cryotherapy, and trichloroacetic acid has been ineffective [8]. Success has been reported with the use of the carbon dioxide laser as well as dermabrasion [10]. In one series of six patients with exogenous ochronosis that were treated with a Q-switched Alexandrite (755nm) laser, all six of the patients reported progressive lesional fading with no residual pigment deposits after six bimonthly treatments [16]. Another recent case series reported positive results using the Q-switched Nd:Yag laser in six Asian patients [7, 10]. The improvement was most appreciable in patients with more advanced ochronosis. Although treatment modalities are continually evolving and improving, prevention of exogenous ochronosis is of the utmost importance. Increasing physician and patient awareness of this rare side effect may decrease misdiagnosis and improve outcomes.

## References

1. Virchow R. Ein Fall von allgemeiner ochronose der knorpel aud knorpelahnlichen theile. *Virchos Arch* 1866; 37:212
2. Pick L. Uber die ochronosis kiln. *Wochenschr* 1906; 43:478
3. Snider R, Thiers B. Exogenous ochronosis. *J Am Acad Dermatol* 1993; 28:662 [PMID: 8463477]
4. Findlay G, et al. Exogenous ochronis and pigmented colloid milium from hydroquinone bleaching creams. *Br J Dermatol* 1975; 93:613 [PMID: 1220808]
5. Hardwick N, et al. Exogenous ochronosis: an epidemiological study. *Br J Dermatol* 1989; 120:229 [PMID:2923796]
6. Gandhi V, et al. Exogenous ochronosis after prolonged use of topical hydroquinone 2% in a 50-year-old Indian female. *Indian J Dermatol* 2012; 57:394 [PMID: 23112363]
7. Tan S. Exogenous Ochronosis – successful outcome after treatment with Q switched Nd:Yag laser. *J Cosmet Dermatol* 2013; 15:274 [PMID: 23464825]
8. Kramer K, et al. Exogenous Ochronosis. *J Am Acad Dermatol* 2000; 42:869 [PMID: 10767690]
9. Culluson D, et al. Localized exogenous ochronosis: report of a case and review of the literature. *J Am Acad Dermatol* 1983; 8:882
10. Diven D, et al. Hydroquinone-induced localzied exogenous ochronosis treated with dermabrasion and CO2 laser. *J Dermatol Surg Onc* 1990; 1990:1018 [PMID: 2246407]
11. Howard K, Furner B: Exogenous ochronosis in a mexican-american woman. *Cutis* 1990; 45:180 [PMID:2311433]
12. O'Donoghue M, et al. Ochronosis due to hydroquinone. *J Am Acad Dermatol* 1983; 8:123 [PMID: 6826796]

13. Levin C, Maibach H. Exogenous ochronosis: an update on clinical features, causative agents, and treatment options. *Am J Clin Dermatol* 2001; 2:212 [PMID: 11705248]
14. Zawar V, Mhaskar S. Exogenous ochronosis following hydroquinone for melasma. *J Cosmet Dermatol* 2004; 3:234 [PMID: 17166112]
15. Williams H. Skin lightening creams containing hydroquinone. *Br J Dermatol* 1992; 305:903 [PMID: 1458069]
16. Bellew S, Alster T. Treatment of exogenous ochronosis with Q-switched alexandrite (755 nm) laser. *Derm Surg* 2004; 1:555 [PMID: 15056151]