

UC Davis

Dermatology Online Journal

Title

Hypocomplementemic cutaneous small vessel vasculitis in a patient with IgG4-related disease

Permalink

<https://escholarship.org/uc/item/4dg0x6rk>

Journal

Dermatology Online Journal, 26(10)

Authors

Sato, Mayu
Honda, Aki
Yamamoto, Toshiyuki

Publication Date

2020

DOI

10.5070/D32610050462

Copyright Information

Copyright 2020 by the author(s). This work is made available under the terms of a Creative Commons Attribution-NonCommercial-NoDerivatives License, available at <https://creativecommons.org/licenses/by-nc-nd/4.0/>

Peer reviewed

Hypocomplementemic cutaneous small vessel vasculitis in a patient with IgG4-related disease

Mayu Sato MD, Aki Honda MD, Toshiyuki Yamamoto MD

Affiliations: Department of Dermatology, Fukushima Medical University, Fukushima, Japan

Corresponding Author: Toshiyuki Yamamoto, Hikarigaoka 1, Fukushima 960-1295, Fukushima, Japan, Tel: & Fax: 81-245471307, Email: toyamade@fmu.ac.jp

Abstract

A 62-year-old man was diagnosed with IgG4-related disease based on multiple sites of lymphadenopathy, lymph node biopsy, and elevated serum levels of IgG4. Hypocomplementemia was also observed. During admission, he was referred to our department complaining of multiple areas of purpura on the lower legs. Histological examination revealed leukocytoclastic vasculitis with fibrinoid necrosis, neutrophil infiltration, and nuclear dust in the upper dermis. To date, only a few cases of cutaneous vasculitis have been reported in IgG4-related disease, all of which showed hypocomplementemia. The role of IgG4 in the etiology of leukocytoclastic vasculitis in IgG4-related disease remains unknown and further studies are necessary.

Keywords: IgG4-related disease, leukocytoclastic vasculitis, purpura, lower extremities

Introduction

IgG4-related disease (IgG4-RD) is an immune-mediated systemic disease, characterized by IgG4-bearing plasma cell infiltration to various organ systems and elevated serum levels of IgG4 [1]. Herein, we describe a rare case of leukocytoclastic vasculitis in a patient with IgG4-RD and hypocomplementemia.

Case Synopsis

A 62-year-old man was hospitalized, complaining of weight loss and general malaise. Laboratory data on blood chemistry showed high levels of IgG (6976mg/dl, normal: 870-1700), IgG4 (1490mg/dl,

normal: 11-121mg/dl), and IgE (566mg/dl, normal <170IU/ml), as well as positive antinuclear antibody (1:1280) and hypocomplementemia (C3: 27mg/dl, C4: 2mg/dl, CH50: <12 U/ml). Antibodies against

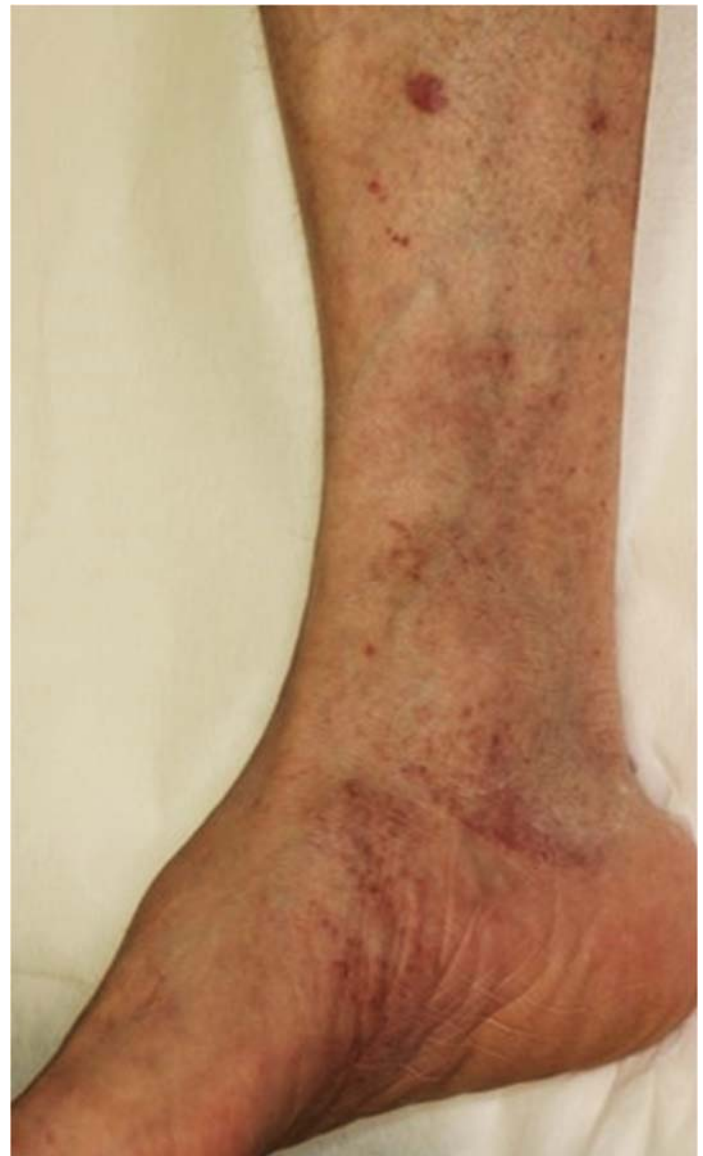

Figure 1. Multiple areas of purpura on the lower extremities.

DNA, Sm, SS-A, and SS-B were all negative. PET-CT showed sites of increased ^{18}F -deoxyglucose accumulation in lymph nodes throughout the body, including the groin, abdomen, mediastinal section, hilum, axilla, and neck. Lymph node biopsy from the inguinal region revealed dilatation between the follicles and an increase in plasma cells. Furthermore, IgG4-positive cells were abundant, accounting for almost 100% of the IgG-positive cells. Considering these results, the patient was diagnosed with IgG4-related disease.

He was referred to our department complaining of asymptomatic eruptions on the lower extremities. Physical examination showed multiple patches and thin plaques of purpura with mild infiltration

extending from both lower thighs to the dorsum of feet (**Figure 1**). A skin biopsy revealed leukocytoclastic vasculitis and interstitial neutrophil infiltration in the upper dermis (**Figure 2A**). Higher magnification revealed leukocytoclastic vasculitis with fibrinoid necrosis, neutrophil infiltration, and nuclear dust (**Figure 2B**). Direct immunofluorescence showed negative findings of IgG, IgM, IgA, and C3 in the vessel walls. He was treated with methylprednisolone pulse therapy for encephalitis associated with IgG4-related disease, followed by oral prednisolone (60mg/day). One week later, purpuric lesions had disappeared.

Case Discussion

IgG4-related disease is a fibroinflammatory condition, characterized by dense lymphoplasmacytic infiltrate, fibrosis, and obliterative phlebitis [1]. Although the pathogenesis of this peculiar condition remains unknown it has been proposed that aberrant Th2 and regulatory T cells sustained by putative autoreactive B cells drive collagen deposition through the production of profibrotic cytokines [2]. IgG4-related disease can affect nearly any organ system, including the skin. Skin manifestations of IgG4-RD are plaques, nodules, and papules, frequently involving the head and neck [3]. Aside from the specific cutaneous manifestation, which is histologically characterized by IgG4+ plasma cells, several secondary nonspecific inflammatory conditions have been observed. Nonspecific skin manifestations include psoriasis-like eruption, nonspecified maculopapular or erythematous eruption, hypergammaglobulinemic purpura, urticarial vasculitis, and ischemic digits [4].

The present patient was diagnosed with IgG4-RD based on the findings of multiple lymph node adenopathies, increased serum IgG4, histopathologically a ratio of IgG4-positive cells to IgG-positive cells of approximately 100%. In addition, hypocomplementemia was also detected, although both systemic lupus erythematosus and Sjögren syndrome were excluded. Histological features showed leukocytoclastic vasculitis with fibrinoid necrosis in the capillaries in the upper

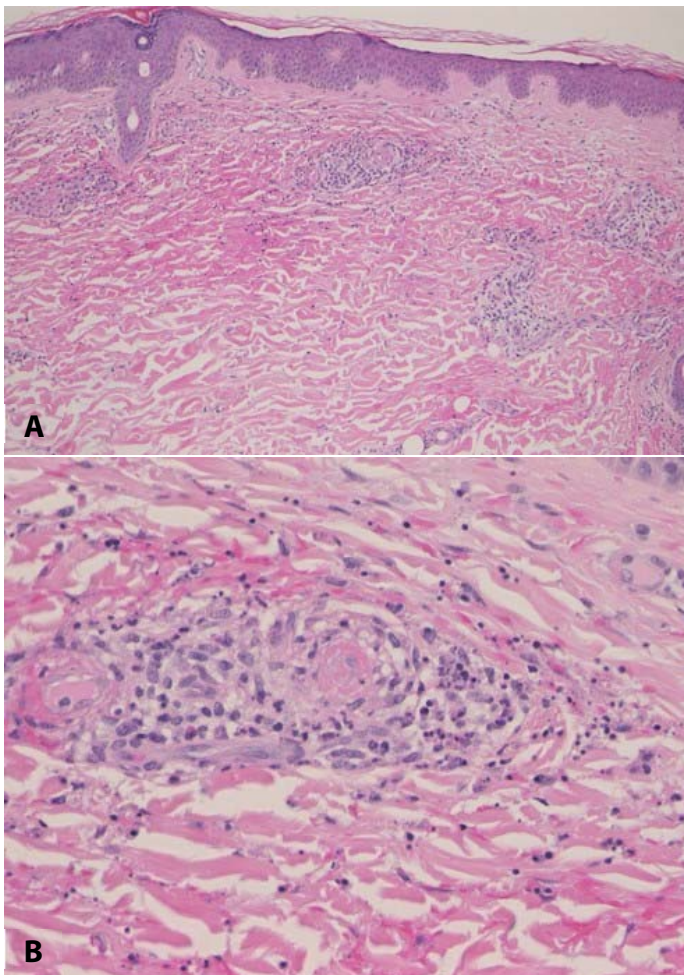


Figure 2. **A)** Histopathological examination showing leukocytoclastic vasculitis and interstitial neutrophil infiltration in the upper dermis. **B)** Higher magnification revealed leukocytoclastic vasculitis with fibrinoid necrosis, neutrophil infiltration, and nuclear dust. H&E, **A)** 100 \times , **B)** 200 \times .

dermis and interstitial neutrophil infiltration with nuclear dust in the upper dermis, without plasma cell infiltration. IgA deposition was not observed. There are only a few previous reports on leukocytoclastic vasculitis in association with IgG4-RD [5-7], which clinically presented with palpable purpura on the lower extremities. Hypocomplementemia was observed in all cases including ours'. Histopathological findings showed common features of leukocytoclastic vasculitis in the upper dermis with infiltration of lymphocytes, neutrophils, nuclear dust, and extravasated erythrocytes, whereas fibrinoid necrosis was not prominent. Direct immunofluorescence showed deposition of C3 [5], or IgG, IgM, and IgA [6]. IgG4 deposition in the vessel wall was observed in only one case [6]. Although

IgG4 has no or little ability to activate complement, IgG4 can stimulate neutrophils via Fc receptors to lead to vasculitis [8]. Alternatively, IgG4 may not play a direct role, but a hypergammaglobulinemic condition may be associated, which was included as one of the secondary eruptions associated with IgG4-RD [4].

Conclusion

Further studies are necessary to determine the etiology of leukocytoclastic vasculitis in IgG4-RD.

Potential conflicts of interest

The authors declare no conflicts of interests.

References

1. Kamisawa T, Zen Y, Pillai S, Stone JH. IgG4-related disease. *Lancet* 2015; 385: 1460-1471. [PMID: 25481618].
2. Della-Torre E, Lanzillotta M, Doglioni C. Immunology of IgG4-related disease. *Clin Exp Immunol* 2015; 181: 191-206. [PMID: 25865251].
3. Charrow A, Imadojemu S, Stephen S, et al. Cutaneous manifestations of IgG4-related disease (RD): a systematic review. *J Am Acad Dermatol* 2016; 75: 197-202. [PMID: 26946983].
4. Tokura Y, Yagi H, Yanaguchi H, et al. IgG4-related skin disease. *Br J Dermatol* 2014; 171: 959-967. [PMID: 25065694].
5. Kawakami T, Yamaguchi N, Soma Y, et al. Immunoglobulin G4-related disease associated with cutaneous vasculitis. *Acta Derm Venereol* 2014; 94: 327-328. [PMID: 24096856].
6. Nakagawa S, Nakamura Y, Yasui S, Yokosuka O, Matsue H. A case of leukocytoclastic vasculitis as a complication of IgG4-related skin disease. *Clin Exp Dermatol* 2017; 42: 235-236. [PMID: 27896847].
7. Takayama R, Ueno H, Saeki H. Immunoglobulin G4-related disease and its skin manifestations. *J Dermatol* 2017; 44: 288-296. [PMID: 28256769].
8. Hussain A, Pankhurst T, Goodall M, et al. Chimeric IgG4 PR3-ANCA induces selective inflammatory responses from neutrophils through engagement of Fcγ receptors. *Immunology* 2009; 128: 236-244. [PMID: 19740380].