

UC Davis

Dermatology Online Journal

Title

Giant melanoma of the abdomen: case report and revision of the published cases

Permalink

<https://escholarship.org/uc/item/4pp2825w>

Journal

Dermatology Online Journal, 20(7)

Authors

di Meo, Nicola
Stinco, Giuseppe
Gatti, Alessandro
et al.

Publication Date

2014

DOI

10.5070/D3207023137

Copyright Information

Copyright 2014 by the author(s). This work is made available under the terms of a Creative Commons Attribution-NonCommercial-NoDerivatives License, available at <https://creativecommons.org/licenses/by-nc-nd/4.0/>

Peer reviewed

Case Presentation

Giant melanoma of the abdomen: case report and revision of the published cases

Nicola di Meo¹, Giuseppe Stinco², Alessandro Gatti¹, Enzo Errichetti², Serena Bonin¹, Antonio Albano¹, Sara Trevisini¹, Giusto Trevisan¹

Dermatology Online Journal 20 (7): 10

¹Departement of Dermatology and Venereology, University of Trieste, Italy

²Department of Experimental and Clinical Medicine, Institute of Dermatology, University of Udine, Italy

Correspondence:

Nicola di Meo
Departement of Dermatology and Venereology
University of Trieste, Italy
nickdimeo@libero.it

Abstract

Malignant melanoma presenting as a giant cutaneous mass is rarely observed in clinical practice. A few patients with giant melanoma have been reported, Herein, we document our experience with a patient with giant cutaneous melanoma of the abdomen and review the features of previously reported individuals.

Introduction

The term "giant melanoma" is generally used to describe those cases of melanoma with a very large diameter independent of its depth [1,2]. There is no cutoff diameter for diagnosis of giant melanoma, although some authors confine this term to those lesions having a diameter larger than 10 cm [1]. To the best of our knowledge, the first description of a giant cutaneous melanoma dates back to 1970, when Bazex et al. described a case in a child [3]. Since then, a few other cases have been described. Herein we report our experience with a giant cutaneous melanoma and we review the cases reported in literature.

Case synopsis

A 60-year-old woman was referred to our clinic because of an asymptomatic skin neoplasm on her abdomen. The lesion had appeared about eight months before and it had progressively increased in size. At first, she neglected the problem, but sought medical attention after the mass began bleeding.

Physical examinations revealed a malodorous, brown-reddish, firm, bleeding vegetative mass with necrotic areas and purulent exudation. The dimension of the tumor was 18 cm x 15 cm x 6 cm (Figure 1). Mild erythema appeared in the surrounding skin. No other significant skin or mucosal lesions were detected. A palpable lymph node in her right axilla was identified.

The tumor was excised with a 3 cm margin and, after histological examination, it was diagnosed as a high-grade malignant melanoma of Clark's level IV and Breslow's depth 40 mm, The histological sections showed large polygonal cells with very pleomorphic nuclei that contained prominent nucleoli. Disseminated deposits of brown melanin pigment were present in the entire section (Figures 2, 3).

Total body *positron emission tomography-computed tomography* (PET-CT) scanning showed the involvement of an axillary lymph node, as already clinically revealed. No other areas of increased hypermetabolic uptake were detected. Serum lactate dehydrogenase (LDH) level was normal. Needle aspiration of the enlarged lymph node revealed melanoma involvement.

The patient underwent a right axillary nodal basin dissection. After histopathological analysis one lymph node out of twenty proved to be positive for melanoma involvement. At that time, six years ago, we did not perform any mutational investigation for BRAF, NRAS, or c-KIT in DNA obtained from the tumor tissue.

According to the American Joint Committee on Cancer (AJCC) TNM staging system, the patient was classified as stage III C disease (pT4b,N1b,M0). The patient refused interferon therapy; adjuvant chemotherapy with dacarbazine at 800 mg/mq for 10 cycles was performed. After 6 years there has been no evidence of local or distant metastasis.

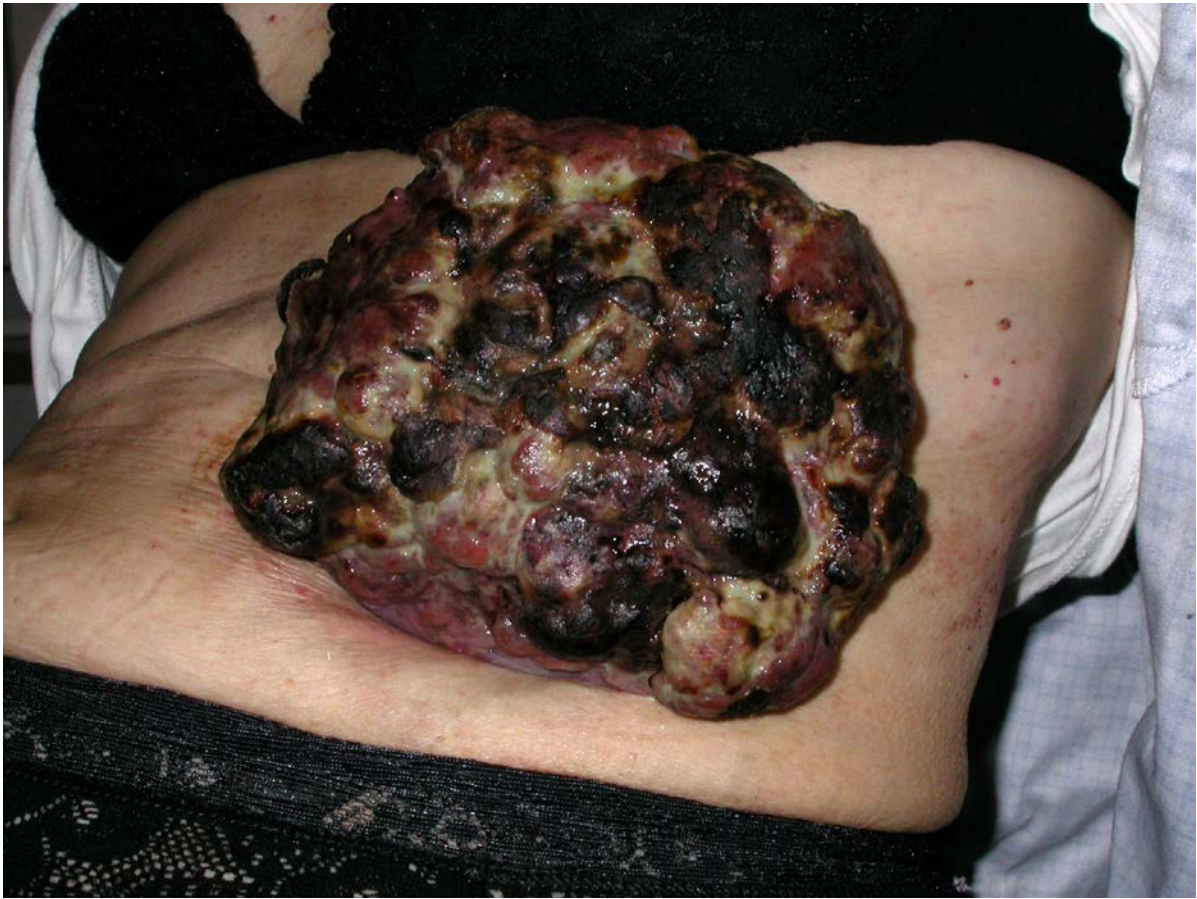

Figure 1. The giant vegetative melanoma of the left abdomen extending from the hypochondrium to mesogastrium.: The dimension of the tumor was 18 cm x 15 cm x 6 cm

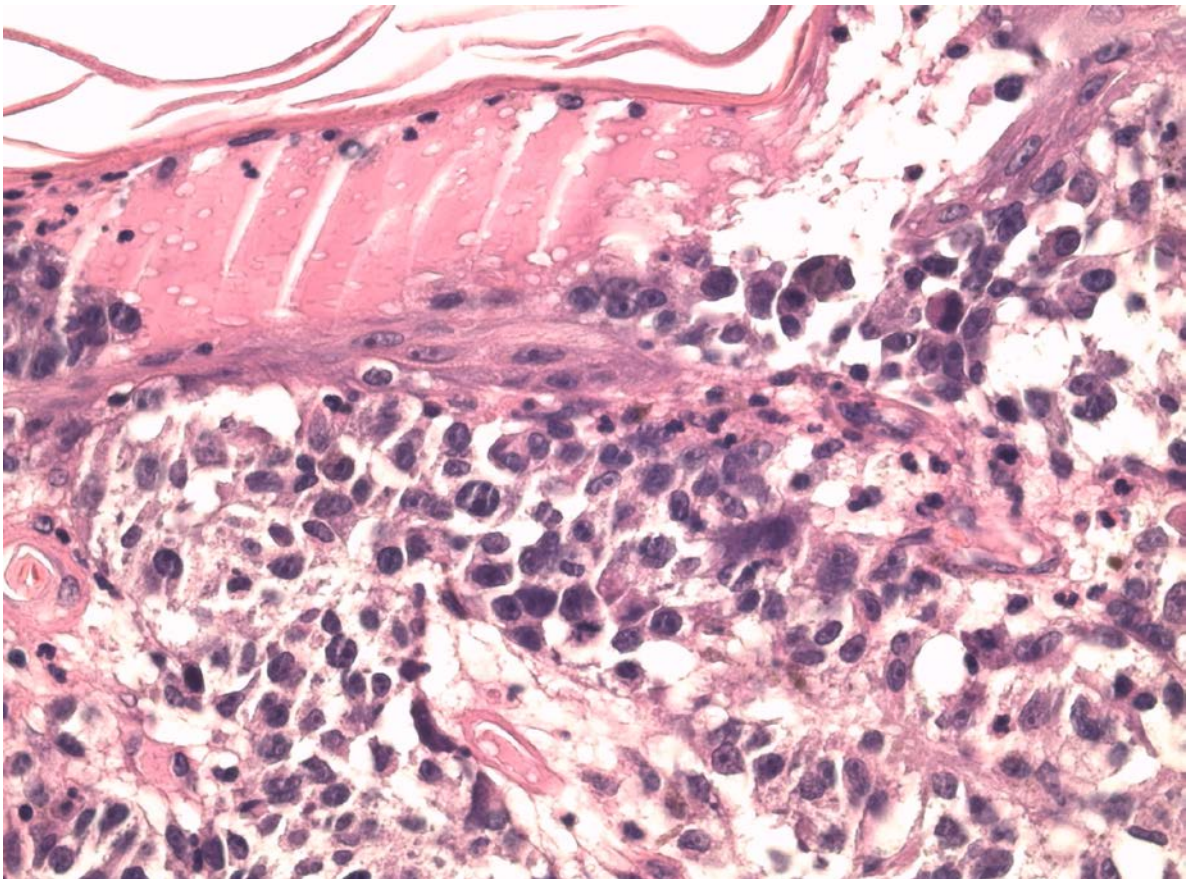


Figure 2. Histological section of the giant melanoma (H&E staining 40 x magnification) characterized by large polygonal cells with pleomorphic nuclei

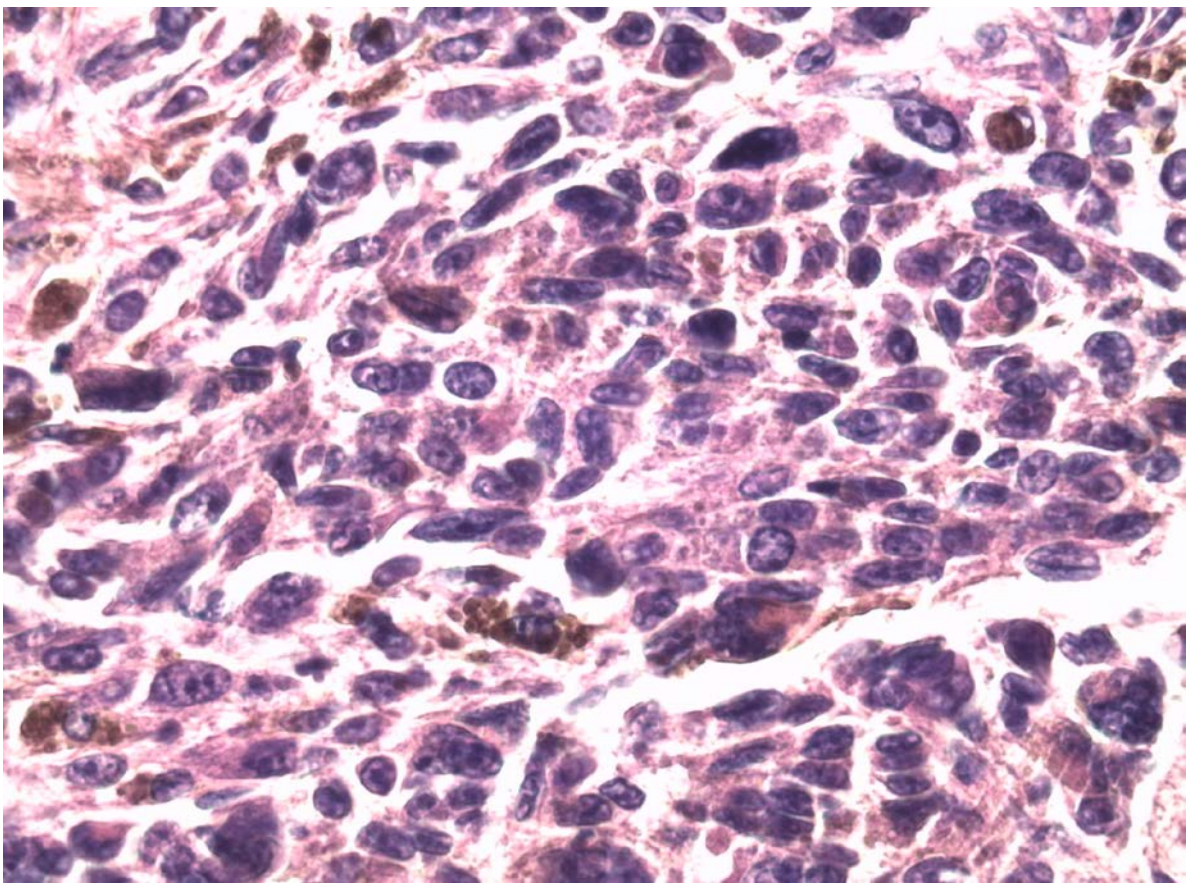


Figure 3. Histological section representing the melanoma cells in the dermis (H&E staining 40 x): Cells are large and have very pleomorphic nuclei that contain prominent nucleoli. Some deposits of brown melanin pigment are present.

Discussion

Giant melanoma has rarely been described in the literature because patients usually come for treatment earlier, and practitioners are well aware of the catastrophic consequences of neglecting such tumors [4]. A systematic literature review, limited to the English language, has shown only 16 patients with melanoma appearing as a giant cutaneous tumor (Table 1).

Excluding a congenital case [5], giant cutaneous melanoma occurs in adults with a mean age of onset of 57 years (range 29–88 years). There does not appear to be a sex prevalence; 8 cases occurring in both males and females have been described. The most common location is the back [5-9], followed by scalp [1,10,11], upper arm [2,12], thumb [4,14], abdomen (our patient and 14), and eyelid [15]. Most cases did not show any precursor lesion (*de novo* onset), but in two patients melanoma arose in a congenital melanocytic nevus [5,8] and in another two patients it developed from a previously acquired melanocytic nevus [12,15]. The diameter of the tumors have ranged between 4 and 25 cm and the Breslow thickness has varied from 0.45 mm to 100 mm, with a mean thickness of 44 mm (average value obtained from 13 reported patients).

The main morphologic feature of giant cutaneous melanoma is a vegetative tumor, although cases appearing as confluent purple-blue-grey macules, papules, and nodules covering most of the parietofrontotemporal scalp [10], and an abdominal plaque with a diameter of 18 cm that developed over 15 years have also been described [14]. The vegetative growths appear to be much thicker. This difference could relate to the different growth pattern of the two clinical variants, mainly horizontal for the plaque form and mostly vertical for vegetative lesions. The cases are described in Table 1.

As we observed in our experience, most cases of giant cutaneous melanoma presented with clinically palpable regional lymphadenopathy, about 82% of cases in which the macroscopic lymph node status was reported ($n = 11$). Moreover, to our knowledge, only four published patients did not have metastatic disease ($n = 13$). The thickest vegetative giant melanoma (Breslow depth of 100 mm) even showed neither loco-regional nor distant metastases [11]. The reason for local or loco-regional spread in some massive melanomas is unknown, although some authors suggested that it could be ascribed to intrinsic biological behavior of the tumor and patient's immunological response to the melanoma cells [8]. Those aspects are also likely to influence the growth rate of the tumor [2]. In reported cases it has taken from 3 months to 15 years to reach a massive size.

Regarding the staging of the disease, only one case in this review could be staged as IIc [11]; the other cases are at least stage III because of the nodal involvement (Table 1).

Table 1. Summary data of published reports referred to patients with primary giant cutaneous melanomas.

Case	Sex and Age (years)	Precursor lesion	Morphology of lesion	Localization	Length of growth	Size (cm)	Breslow thickness (mm)	Nodal diffusion	Metastatic disease	Stage of disease	Therapy
Del Boz (12)	F 29	Yes (AMN)	VT	Arm	8 months	20x15x7	70	Yes (histological evaluation)	Yes	IV	Palliative debulking; Ax ND
Grisham (7)	F 45	No	VT	Back	> 1 year	13xNA	55	Yes (palpable)	NA	Almost IIIC	WLE; Ax ND; α -interferon
De Giorgi (14)	F 45	No	Skin Plaque	Abdomen	15 years	16xNA	0,45	NA	NA	NA	NA
Kruijff (6)	F 56	No	VT	Back	NA	8x6	48	Yes (palpable)	Yes	IV	WLE; Bil Ax ND
Kim (4)	F 56	No	VT	Thumb	3 years	7x4x3,5	> 4	Yes (palpable)	No	IIIC	Thumb amputation; Ax ND; INF- α -2a
Our case	F 60	No	VT	Abdomen	8 months	18x15x6	40	Yes (palpable)	No	IIIC	WLE; Ax ND; Chemotherapy
Zeebregts (13)	F 74	No	VT	Thumb	7 months	5x7x5	NA	NA	Yes	IV	Local perfusion with γ -interferon, TNF- α and melphalan, surgical excision, Ax ND.
Müller (10)	F 84	No	Confluent purple-blue-grey macules, papules and nodules	Scalp	NA	NA	5	No (ultrasound evaluation)	NA	NA	None
Harting (9)	M 29	Yes (CMN)	VT	Back	1 year	22x25x7	54	Yes (palpable)	Yes	IV	WLE; Chemotherapy
Eisen (8)	M 47	No	VT	Back	6 months	8x9	40	NA	Yes	IV	WLE
Pai (15)	M 53	Yes (AMN)	VT	Eyelid	1 year	5x4,5 x4	45	Yes (palpable)	No	IIIC	Excision with a margin of 8 mm
Panajotovic (11)	M 57	No	VT	Scalp	3 years	12x10	100	No (clinical and imaging evaluation)	No	Likely IIC	WLE
Tseng patient B (2)	M 63	No	VT	Arm	> 1 year	23x21x6	75	Yes (palpable)	Yes	IV	WLE; Ax ND
Ching (1)	M 70	No	VT	Scalp	3 months	14,5x 10,4	18	Yes (palpable)	Yes	IV	WLE; SND
Tseng patient A (2)	M 88	No	VT	Arm	NA	10x8x3	31	Yes (palpable)	Yes	IV	WLE; Ax ND
Schneiderman (5)	M Premature newborn	Yes (CMN)	VT	Back	Congenital lesion	15x14x5	NA	NA	Yes	IV	None

AMN: acquired melanocytic nevus; Ax ND: Axillary Nodal Dissection; Bil Ax ND: Bilateral Axillary Nodal Dissection; CMN: Congenital melanocytic nevus; NA: Not available; SND: selective neck dissection; TNF- α : Tumor necrosis factor-alpha; VT: Vegetative tumor; WLE: Wide local excision.

Given the rarity of giant melanomas, it is difficult to draw any conclusion for the staging and management strategy. Consequently, there is no validated approach [2]. Nevertheless, for patients with clinically positive node(s), such as in our case, the current National Comprehensive Cancer Network (NCCN) guidelines for melanoma suggest evaluating the palpable node through fine-needle aspiration, avoiding sentinel lymph node biopsy (SLNB). Furthermore, baseline imaging (CT, PET/CT, MRI) for staging purpose and evaluation of specific signs or symptoms are also recommended for those patients. On the other hand, serum LDH level is considered to be optional [16]. According to those guidelines, in our patient we have performed careful clinical examination of all superficial lymph node basins, serum LDH level, and a total body PET-CT scan to investigate clinically occult nodal involvement or visceral metastasis. Subsequently, after checking the involvement in the clinically enlarged axillary lymph node through needle aspiration, we carried out nodal dissection, followed by histological examination.

Regarding therapy of giant melanoma, several authors have supported an attempt to treat with multimodality treatment, including aggressive surgical resection. Experimental treatment regimens and novel therapeutic agents may be considered, since giant melanomas are often associated with several negative prognostic factors (size, exophytic growth, ulceration, nodal disease) and a very poor prognosis [2]. In our patient, wide excision of the melanoma with 3-cm margins, complete axillary lymph node dissection, and adjuvant chemotherapy with dacarbazine 800mg/mq for 10 cycles were performed. At the present

time, after a 6-year follow-up, the patient is free of disease and she represents the giant melanoma patient with the longest disease-free survival.

Discussion

Giant cutaneous malignant melanoma is rarely observed in clinical practice. It has rarely been described in the literature. The main morphologic feature of giant cutaneous melanoma is a vegetative tumor. Given the rarity of giant melanomas, it is difficult to draw any conclusions for the staging and management strategy. Consequently, there is no validated therapeutic approach. Giant melanomas are often associated with a very poor prognosis. The reason for local or loco-regional spread in some massive melanomas without distant metastases is unknown, although some authors have suggested that it could be ascribed to the intrinsic biological behavior of the tumor and patient's immunological response to the melanoma cells

Acknowledgements: The authors thank Dr. Valentina Melita for the English revision of the manuscript.

References

1. Ching JA, Gould L. Giant scalp melanoma: a case report and review of the literature. *Eplasty*. 2012;12:e51 [PMID: 23185647].
2. Tseng WW, Doyle JA, Maguiness S, Horvai AE, Kashani-Sabet M, Leong SP. Giant cutaneous melanomas: evidence for primary tumour induced dormancy in metastatic sites? *BMJ case reports*. 2009;2009 [PMID: 21977058].
3. Bazex A, Dupre A, Christol B, Cantala P, Carton. [Giant melanoma in children and a tumor with a sarcomatous structure]. *Bulletin de la Societe francaise de dermatologie et de syphiligraphie*. 1970;77(3):428-30 [PMID: 5537441].
4. Kim JH, Jeong SY, Shin JB, Ro KW, Seo SH, Son SW, et al. Giant acral melanoma on the left thumb of a korean patient. *Annals of dermatology*. 2009;21(2):171-3 [PMID: 20523779].
5. Schneiderman H, Wu AY, Campbell WA, Forouhar F, Yamase H, Greenstein R, et al. Congenital melanoma with multiple prenatal metastases. *Cancer*. 1987;60(6):1371-7 [PMID: 3621120].
6. Eisen DB, Lack EE, Boisvert M, Nigra TP. Giant tumor of the back. *Archives of dermatology*. 2002;138(9):1245-50 [PMID: 12224992].
7. Grisham AD. Giant melanoma: novel problem, same approach. *Southern medical journal*. 2010;103(11):1161-2 [PMID: 20859251].
8. Harting M, Tarrant W, Kovitz CA, Rosen T, Harting MT, Souchon E. Massive nodular melanoma: a case report. *Dermatology online journal*. 2007;13(2):7 [PMID: 17498426].
9. Kruijff S, Vink R, Klaase J. Salvage surgery for a giant melanoma on the back. *Rare tumors*. 2011;3(3):e28 [PMID: 22066035].
10. Muller CS, Hinterberger L, Vogt T, Pfohler C. Giant melanoma of the scalp--discussion of a rare clinical presentation. *BMJ case reports*. 2011;2011 [PMID: 22693201].
11. Panajotovic L, Dordevic B, Pavlovic MD. A giant primary cutaneous melanoma of the scalp--can it be that big? *Journal of the European Academy of Dermatology and Venereology : JEADV*. 2007;21(10):1417-8 [PMID: 17958853].
12. del Boz J, Garcia JM, Martinez S, Gomez M. Giant melanoma and depression. *American journal of clinical dermatology*. 2009;10(6):419-20 [PMID: 19824743].
13. Zeebregts CJ, Schraffordt Koops H. Giant melanoma of the left thumb. *European journal of surgical oncology : the journal of the European Society of Surgical Oncology and the British Association of Surgical Oncology*. 2000;26(2):189-90 [PMID: 10744942].
14. De Giorgi V, Massi D, Carli P. Giant melanoma displaying gross features reproducing parameters seen on dermoscopy. *Dermatologic surgery : official publication for American Society for Dermatologic Surgery [et al]*. 2002;28(7):646-7 [PMID: 12135529].
15. Pai RR, Kini H, Kamath SG, Kumar S. Giant hanging melanoma of the eyelid skin. *Indian journal of ophthalmology*. 2008;56(3):239-40 [PMID: 18417829].
16. Network NCCC. *Clinical Practice Guidelines in Oncology - v.2.2014: Melanoma 2013* [October 23, 2013].http://www.nccn.org/professionals/physician_gls/pdf/melanoma.pdf.