

# UC Davis

## Dermatology Online Journal

### Title

Two sisters with Reed's syndrome: treatment with pregabalin

### Permalink

<https://escholarship.org/uc/item/4wx2s2xm>

### Journal

Dermatology Online Journal, 21(9)

### Authors

Yaldiz, Mahizer  
Metin, Murcan  
Erdem, Mustafa Teoman  
[et al.](#)

### Publication Date

2015

### DOI

10.5070/D3219028697

### Copyright Information

Copyright 2015 by the author(s). This work is made available under the terms of a Creative Commons Attribution-NonCommercial-NoDerivatives License, available at <https://creativecommons.org/licenses/by-nc-nd/4.0/>

Peer reviewed

## Case presentation

### Two sisters with Reed's syndrome: treatment with pregabalin

Mahizer Yaldiz MD<sup>1</sup>, Nurcan Metin MD<sup>1</sup>, Mustafa Teoman Erdem MD<sup>1</sup>, Bahar Sevimli Dikicier MD<sup>1</sup>, Zeynep Kahyaoğlu MD<sup>2</sup>

Dermatology Online Journal 21 (9): 11

<sup>1</sup>Sakarya Training and Research Hospital, Department of Dermatology, Sakarya, Turkey

<sup>2</sup>Sakarya Training and Research Hospital, Department of Pathology, Sakarya, Turkey

## Correspondence:

Mahizer Yaldiz MD  
Department of Dermatology  
Sakarya Training and Research Hospital  
Sakarya, Turkey 54010  
E-Mail: drmahizer@gmail.com  
Tel: 02642750090-1460  
Mobil phone: 05053572222

---

## Abstract

Cutaneous leiomyomas, which originate in the arrector pili muscles of the skin are rarely seen benign cutaneous tumors. Sometimes familial cutaneous and uterine leiomyomatosis can occur together, an autosomal dominant genetic condition called Reed syndrome or familial leiomyomatosis cutis et uteri. This disorder can be accompanied by malignancies, particularly by renal carcinoma. In this paper, two sisters with Reed syndrome are presented in view of the rarity of the disorder and good response to pregabalin therapy.

## Introduction

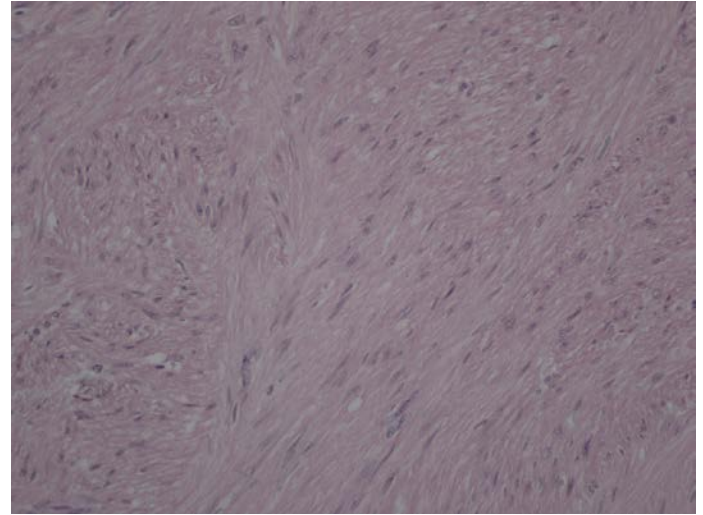
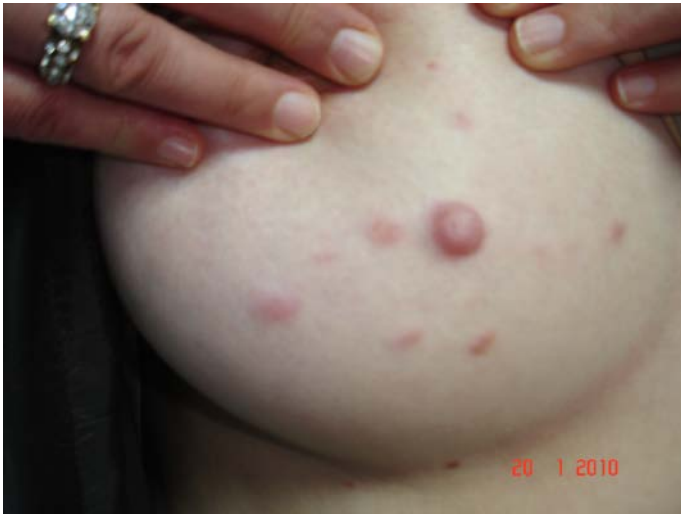Leiomyomas are tumors that typically originate in the smooth muscles of the skin. Skin leiomyomas are divided into three groups: solitary or multiple pilar leiomyomas arising from arrector pili muscles, angioleiomyomas arising from vascular smooth muscles, and dartoic leiomyomas arising from the dartos muscles of the genitalia, areola, and nipple [1-3]. In female patients, multiple leiomyomas and uterine leiomyomas can occur together, resulting in a condition called Reed syndrome [4, 5].

## Case synopsis

### Case 1

A 39-year-old woman referred to our outpatient clinic presented with painful swellings in the right breast that had been present for the past two years. She stated that cold temperatures increased the pain. According to her history, she had undergone an operation for a uterine myoma about one year earlier. She reported that her sister experienced similar symptoms and that her sister had also undergone surgery for a uterine myoma. She had no complaints related to other systems, and her physical examination findings were normal, except for her skin. The dermatological examination revealed seven red-brown, 0.5–1.5 cm-sized, indurated nodules around the right breast areola that were painful upon palpation (Figure1). Her hemogram, liver function tests, renal function tests, erythrocyte sedimentation rate, and peripheral blood smear were normal. The painful lesions were excised by a plastic surgeon. In the histopathological examination of the biopsied material, relatively well-limited and vascularized nodules were observed around some eccrine glands in the mid-dermis. The nodules consisted of proliferating

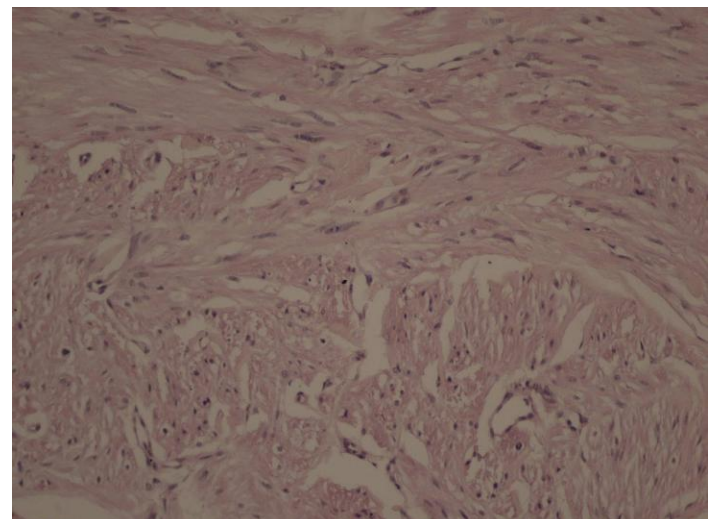
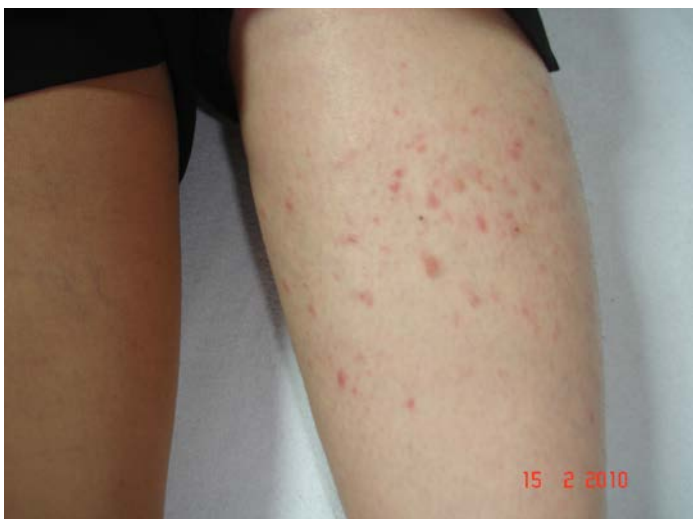smooth muscle cells, which crossed each other, formed whirlpool-like structures, and showed focal pleomorphism. The lesions were diagnosed as leiomyomas (Figure 2).



**Figure 1.** Seven red-brown, 0.5–1.5 cm-sized indurated nodules around the right breast areola that were painful with palpation (Case 1)  
**Figure 2.** Hematoxylin-eosin  $\times 20$ : In the mid-dermis, relatively well-limited and vascularized nodules were observed around some eccrine glands. The nodules consisted of proliferating smooth muscle cells, which crossed each other, formed whirlpool-like structures, and showed focal pleomorphism. The lesions were diagnosed as leiomyomas (Case 1).

## Case 2

Our second case was a 48-year-old woman who was the older sister of the patient in Case 1. She complained of painful swellings in her arms and legs that had been present for the past five years. She stated that cold temperatures increased her pain. She had undergone an operation for a uterine myoma about two years earlier. She had no complaints related to other systems and her physical examination findings were normal, except for her skin. The dermatological examination showed multiple, red-brown, oval, 0.5–1.5 cm-sized indurated papular lesions on both legs that were painful upon palpation (Figure 3). Her hemogram, liver function tests, renal function tests, erythrocyte sedimentation rate, and peripheral blood smear were normal. In the histopathological examination of the biopsied material taken from her lesions, crossing fascicles of spindle-shaped smooth muscle cells with vesicular chromatin were observed in the dermis. The lesions were diagnosed as leiomyomas (Figure 4). Surgery was not considered because of the multiplicity of the lesions. For pain, pregabalin (75 mg 2 $\times$ 1 for 1 week, then 150 mg 2 $\times$ 1) was started. At the one-month follow-up visit, her visual pain score, which had been 8, had dropped to 2.



**Figure 3.** Multiple, red-brown, oval, 0.5–1.5 cm-sized indurated papular lesions on both legs that were slightly painful with palpation (Case 2). **Figure 4.** Hematoxylin-eosin  $\times 20$ : In the dermis, crossing fascicles of spindle-shaped smooth muscle cells with vesicular chromatin. The lesions were diagnosed as leiomyomas (Case 2).

These two patients were diagnosed with Reed syndrome because of the multiple cutaneous leiomyomas and uterine leiomyomas. Given their biological relationship, the patients underwent tests for accompanying disorders, such as renal cell carcinoma, chronic myeloid leukemia, breast cancer, and polycythemia. None of these disorders were detected in the sisters. Both patients were informed about their disorder and advised to undergo periodic tests to check for the accompanying disorders.

## Discussion

Reed syndrome was first reported by Bloom et al. in 1954 in a 45-year-old female patient. It is an autosomal dominant condition with incomplete penetrance [6, 7].

Cutaneous leiomyomas are rarely seen benign tumors that originate in smooth muscles. Clinically, they are 0.2–2 cm-sized, flat-surfaced, and red- or tan-colored papules or nodules. They are pain-sensitive and can be soft or hard lesions with no fixation to subcutaneous tissues. Touch, cold, or emotional stress can trigger lesional pain [8]. Pseudo-Darier's sign can also be seen [9]. Cutaneous leiomyomas are more frequently seen in patients aged between 10 and 30 years. In 80% of cases, the localization patterns are multiple, disseminated, or segmental, and the lesions are most often located on the extremities, trunk, neck, and face [1, 7, 8, 9].

Patients with Reed syndrome, which is also called familial leiomyomatosis cutis et uteri, present with both cutaneous leiomyomas and uterine leiomyomas [1-5, 10, 11]. Affected females frequently develop uterine leiomyomas that are larger, more numerous, and emerge earlier than those in the general population [8]. Uterine leiomyomas may also show hyaline, cystic, or hemorrhagic degeneration [8]. In contrast to cutaneous leiomyomas, estrogen and progesterone receptors of uterine leiomyomas show positive staining [8].

Aggressive renal cell carcinomas may accompany Reed syndrome. In such cases, the condition is called hereditary leiomyomatosis and renal cell cancer [11]. The gene responsible for Reed syndrome is 1q42.3-43, which codes for fumarate hydratase. Fumarate hydratase is an enzyme in the Krebs cycle that catalyzes the conversion of fumarate to malate. It plays a tumor suppressor role in cutaneous and uterine leiomyomas and in the development of renal cell carcinomas [4, 5, 12]. In patients with Reed syndrome, besides renal cell carcinoma, patients may also develop chronic myeloid leukemia, polycythemia [13], and breast cancer [6]. It is thought that the development of polycythemia is associated with an erythropoietin-like substance secreted by the tumor [14].

The diagnosis of Reed syndrome is important. The condition often must be separated from other types of disease such as angiolipomas, neuromas, glomus tumors, eccrine spiradenomas, and blue rubber bleb nevus syndrome [14]. The diagnosis of a leiomyoma can be established with a histopathological examination. In the dermis, an increase in smooth muscle bundles and various amounts of intertwined collagen are also observed. The smooth muscle cells have elongated nuclei that look like cigars and eosinophilic cytoplasm. The cells stain blue-green with Masson-trichrome stain, and desmin and actin markers are positive [8, 12].

The treatment of cutaneous leiomyomas depends upon the number of lesions and the degree of discomfort. Given the benign character of the disorder, avoiding stress and cold that trigger the pain may be sufficient [8, 12]. For patients with multiple lesions, therapeutic modalities to manage the pain should be provided. The pathogenesis of pain is explained by the compression of nerve fibers, contraction of tumoral muscles, or excitation of alpha-adrenergic receptors on the arrector pili muscle [10, 15, 16]. To reduce the pain, pharmacological agents including calcium channel blockers (e.g., nifedipine), gabapentin, pregabalin, hydrobromide, nitroglycerin, phenoxybenzamine, and alpha-adrenergic receptor blockers have been tried. Additionally, therapies such as cryotherapy, carbon dioxide laser ablation, iontophoresis, botulinum toxin injections, and intralesional steroid injections have been used with varying success. Solitary and localized lesions can be surgically excised [8, 10, 15, 16].

Pregabalin is an analog of gamma aminobutyric acid. It exerts its effect by binding to the ancillary subunit of the voltage-dependent calcium channel in the central nervous system. Pregabalin also reduces pain by decreasing the release of neurotransmitters, including glutamate, substance P, and noradrenaline. Furthermore, pregabalin reduces neuropathic pain by decreasing neuronal hyperexcitability and increasing serotonin levels. The mechanism by which pregabalin exerts its effects is similar to that of gabapentin [16]. We selected pregabalin for our patient because patient compliance has been shown to be better with pregabalin than with gabapentin.

Kostopanagiotou et al. [16] reported a case of pregabalin usage in Reed syndrome and this is the only published study concerning this topic. The Kostopanagiotou et al. case was treated with a combined therapy of venlafaxine 75 mg daily, which was gradually increased to 600 mg daily (300 mg twice daily), and pregabalin 50 mg daily, which was also progressively increased to 600 mg daily (300 mg twice daily). They performed this therapy for 12 months and controlled the patient's pain. In our case, we started pregabalin at 75 mg twice a day for one week, then increased to 150 mg twice a day for the control of pain. At a follow-up visit after one month, the patient's visual pain score decreased from 8 to 2. At the 10-month follow-up visit, pregabalin was gradually stopped and at the 11-month follow-up visit, her visual pain score was still reported as 2.

In view of probable malignancies, patients with Reed syndrome and their close relatives should be followed closely. They should be advised to undergo regular exams including a pelvic examination, pelvic and renal ultrasonography, urine microscopy, and urologic consultations [8, 12].

The two sisters in the present case studies had cutaneous and uterine leiomyomas and they were diagnosed with Reed syndrome, both clinically and histopathologically. The patients underwent tests to determine the presence of accompanying malignancies, but we found no additional pathologies. In the first case, the patient's lesions were surgically excised because they were few in number. In the second case, the patient received no surgical therapy because of the presence of multiple lesions. Taking into consideration the neuropathic nature of her pain, the second patient was prescribed pregabalin. In a follow-up visit one month later, her pain was reduced. We informed the patients about their disorder and probable accompanying malignancies. We also advised them about the need to undergo periodic screening tests, not just for themselves, but also for their close relatives.

In conclusion, Reed syndrome is an autosomal dominant condition with a mutation in the tumor suppressor gene. Not only patients diagnosed with Reed syndrome, but also their close family members should be informed about the disorder and examined for malignancies, particularly renal cell carcinoma. If a total tumor excision cannot be performed, like in our second case, pregabalin treatment can be an important alternative therapy to reduce pain and enhance the patient's quality of life.

## References

1. Albrecht S. Neoplasias and hyperplasias of neural and muscular origin. In: Freedberg IM, Eisen AZ, Wolff K, Austen KF, Goldsmith LA, Katz SI, eds. *Dermatology in General Medicine*. 6th ed. New York: McGraw-Hill; 2003. p.1032-41.
2. Cislo M, Szepietowski F, Wasik JC, Maj J, Hrynciewicz-Gwózdź A, Nockowski P. Familial cutaneous and uterine leiomyomas: case report. *Acta Dermatovenerol Croat*. 2003;11:212-6.
3. Fernandez-Pugnaire MA, Delgado-Florencio V. Familial multiple cutaneous leiomyomas. *Dermatology*. 1995;191:295-8.
4. Chan I, Wong T, Martinez-Mir A, Christiano AM, McGrath JA. Familial multiple cutaneous and uterine leiomyomas associated with papillary renal cell cancer. *Clin Exp Dermatol*. 2005;30:75-8.
5. Garman ME, Blumberg MA, Ernst R, Raimer SS. Familial leiomyomatosis: a review and discussion of pathogenesis. *Dermatology*. 2003;207:210-3.
6. Alam NA, Barclay E, Rowan AJ, Tyrer JP, Calonje E, Manek S, Kelsell D, Leigh I, Olpin S, Tomlinson IP. Clinical features of multiple cutaneous and uterine leiomyomatosis; an underdiagnosed tumor syndrome. *Arch Dermatol*. 2005;141:199-206.
7. Akar ME, Kayacan N, Şatır F, Özbudak İH. Reed's Syndrome: Case Report. *Turkiye Klinikleri J Gynecol Obst*. 2009;19(6):361-4.
8. Emer JJ, Solomon S, Mercer SE. Reed's syndrome: A case of multiple cutaneous and uterine leiomyomas. *J Clin Aesthet Dermatol*. 2011;4:37-42.
9. Mandal RK, Koley S, Banerjee S, Kabiraj SP, Ghosh SK, Kumar P. Familial leiomyomatosis cutis affecting nine family members in two successive generations including four cases of Reed's syndrome. *Indian J Dermatol Venereol Leprol*. 2013;79(1):83-7.
10. Ürkmez A, Ertam İ, Karaarslan İK, Kazandı A, Ceylan C. Leiomyomatozis Kutis. *Turk J Dermatol*. 2011;5:101-3.
11. Kiuru M, Launonen V. Hereditary leiomyomatosis and renal cell cancer (HLRCC). *Curr Mol Med*. 2004;4:869-75.
12. Kim G. Multiple cutaneous and uterine leiomyomatosis (Reed's syndrome). *Dermatol Online J*. 2005;11:21.
13. Cairey-Remonnay S, Salard D, Algros MP, Laurent R. Multiple familial cutaneous leiomyoma. *Ann Dermatol Venerol*. 2003;130:1017-20.
14. Jaime TJ, Jaime TJ, Melo DF, Guaraldi BM, Bastos Júnior CS, Lerer C. Do you know this syndrome? Piloleiomyoma. *An Bras Dermatol*. 2011;86:1222-9.
15. Meszyńska E, Czop BB, Wcisło LB. Reed's syndrome: case report and review of literature. *Post Dermatol Alergol*. 2012;2: 139-142.
16. Kostopanagiotou G, Arvaniti C, Kitsiou MC, Apostolaki S, Chatzimichael K, Matsota P. Successful pain relief of cutaneous leiomyomata due to Reed syndrome with the combination treatment of pregabalin and duloxetine. *J Pain Symptom Manage*. 2009; 38: 3-5. [PMID: 19596180]