

# UC Davis

## Dermatology Online Journal

### Title

Chronic, severe onychocryptosis successfully treated with nail tube splinting in a 13-year-old girl with multiple prior failed matricectomies

### Permalink

<https://escholarship.org/uc/item/6cw147f0>

### Journal

Dermatology Online Journal, 22(6)

### Authors

Chitgopeker, Pooja  
Johnson-Jahangir, Hillary

### Publication Date

2016

### DOI

10.5070/D3226031321

### Copyright Information

Copyright 2016 by the author(s). This work is made available under the terms of a Creative Commons Attribution-NonCommercial-NoDerivatives License, available at <https://creativecommons.org/licenses/by-nc-nd/4.0/>

Peer reviewed

## Case Presentation

**Chronic, severe onychocryptosis successfully treated with nail tube splinting in a 13-year-old girl with multiple prior failed matricectomies**

**Pooja Chitgopeker MBChB, Hillary Johnson-Jahangir, MD, PhD**

**Dermatology Online Journal 22 (6): 9**

**Department of Dermatology, University of Iowa Hospitals and Clinic, Iowa City**

## Correspondence:

Pooja Chitgopeker, MBChB  
Department of Dermatology  
University of Iowa Hospitals and Clinic  
200 Hawkins Drive  
Pomerantz Family Pavilion  
Iowa City, IA 52240  
Email: pooja-chitgopeker@uiowa.edu

---

## Abstract:

Onychocryptosis, also known as ingrown toenail, is caused by growth of the lateral edge of the nail into the nail fold. This results in inflammation of the invaded tissue. It is a common problem with ~70% of cases occurring in people between the ages of 12-30 years and causes significant discomfort, pain, and restriction in activity [1]. There is no standard treatment for onychocryptosis and numerous methods have been used, from conservative approaches such as proper nail trimming techniques to more invasive surgical procedures. All techniques risk the possibility of damage to the nail apparatus, prolonged healing time, and recurrence of disease.

We describe a successful case of bilateral nail tube splinting in a pediatric patient with recurrent, severe onychocryptosis and history of multiple matricectomies.

**Keywords: onychocryptosis, ingrown toenail, nail tube splinting, gutter method, matricectomy**

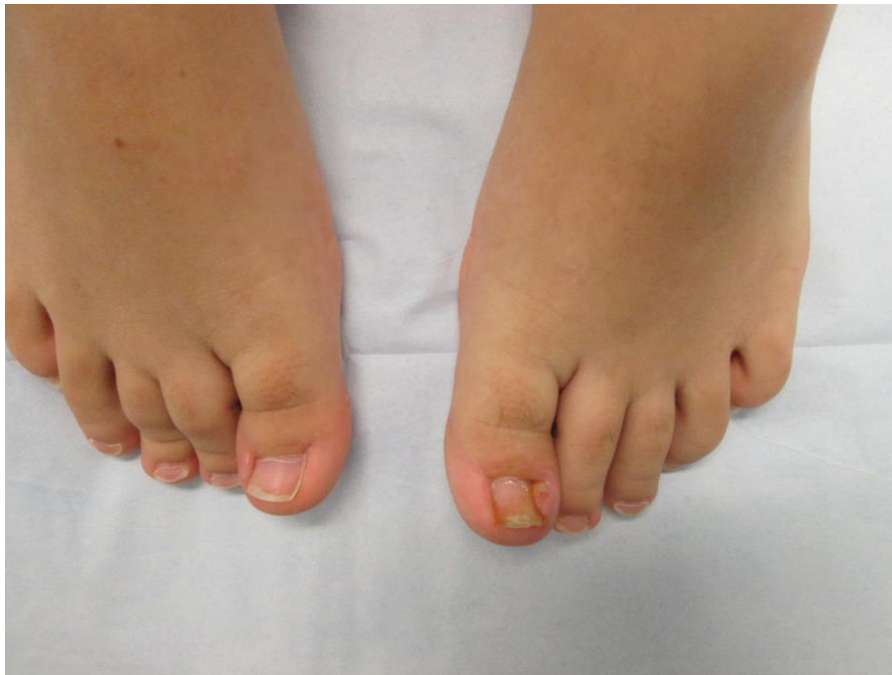## Introduction

Onychocryptosis is a common problem in which the lateral edge of the nail grows into the lateral nail fold, causing inflammation of the tissue [1]. Postulated causes of onychocryptosis include congenital malalignment of the great toenail, chronic trauma from narrow and tight shoes, incorrect nail trimming techniques, poor foot hygiene, hyperhidrosis, and obesity [2]. There is no gold standard for the treatment of ingrown toenails. Treatment options vary from conservative approaches to extensive surgical procedures that risk damage to the nail apparatus. Recurrence of disease is a challenge regardless of the treatment method. Nail tube splinting has been a well-utilized treatment method in Europe and recent case series demonstrate its effectiveness in the United States. We will review the nail tube splinting method (or Gutter method as it was first described) and highlight this non-invasive treatment of an ingrown toenail as a first-line treatment effective for all patients and for those recalcitrant to prior treatments.

## Case synopsis

We present a healthy 13-year old girl with recurrent onychocryptosis of the bilateral great toenails since the age of 6. Between the ages of 6 and 13, she underwent several matricectomies of the bilateral great toenails using phenol, electrodesiccation, or ablative CO2 laser performed by multiple dermatologists and podiatrists. Oral and topical antibiotics failed to resolve chronic inflammation of the nail folds. Recurrence of onychocryptosis after matricectomy continued to be a problem over years even though the width of nail plates had been reduced as expected from destruction of lateral horns of the nail matrices. The patient suffered significant pain and disruption of her daily life activities. She was unable to walk comfortably, wear closed toe shoes, or partake in sports or gym activities in school. Nail clipping had become increasingly difficult owing to the sensitivity, although proper nail care was a priority. Manipulation of the cuticles or repetitive traumatic injuries had not occurred. Family history was significant for severe onychocryptosis in the patient's mother, which had starting during pregnancy and was successfully treated with nail tube splinting.

Examination revealed erythematous, edematous nail folds of the bilateral great toes accompanied by malodor and scattered yellow discoloration of the nail plate. The left lateral nail fold at the medial aspect of the left great toe was most severely affected and exquisitely tender. Cuticles were largely intact with focal areas of retraction in areas of inflammation. Nail plates were noted to be brittle with tendency to have jagged edges. There was an absence of purulence. Multiple scars were present along the cuticle and nails folds from prior matricectomies (Figure 1). X-ray was negative for bony changes suggestive of osteomyelitis.



**Figure 1.**

Treatment was initiated in the fall of 2013 for each site of chronic onychocryptosis. First, the patient underwent nail tube splinting of the right medial toenail. On the same day, lateral nail fold excision of the left lateral toenail was performed. At the time, the severity of the nail fold overgrowth and inflammation at the left lateral toenail site led to the decision for excision rather than toenail splinting. All procedures were performed with local anesthesia in the office-based setting using standard surgical techniques.

Surgical debulking of the left lateral nail fold to the level of the distal phalanx was carried out and it was left to heal by second intention. After excision, the proximal lateral nail plate could be visualized and featured multiple small spicules. A modified technique for nail splinting using a flexible tube (from a #19 butterfly needle) secured using a suture was performed on the right great toenail, based on the description by Perez et al [3].

### **Modified technique for nail tube splinting:**

- The flexible plastic tube from the butterfly needle typically used for venipuncture was removed and a longitudinal cut made on one side with a blade to create a channel in the tube (Figure 2)



**Figure 2.**Preparation of the nail splint tube: The dashed yellow line depicts where the tube is cut for placement around the lateral nail plate

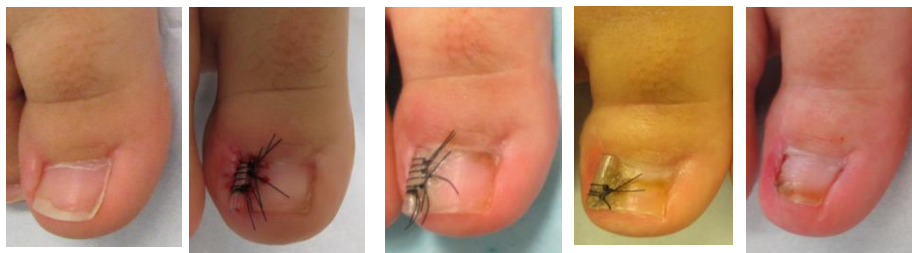
- A wing block at the distal interphalangeal joint combined with local infiltration using at most 2 ml of 1% lidocaine with 1:100,000 epinephrine per digit provided adequate anesthesia and the entire area was prepared with a chlorhexidine 4% soak for 10 minutes
- The lateral nail plate was freed using a nail elevator up to the outer edge of the matrix
- The longitudinal cut in the flexible tube was gently threaded over the lateral edge of the nail plate extending to the uppermost aspect of the nail plate near the nail matrix under the proximal nail fold
- The tube was then secured using superficial non-absorbable monofilament sutures extending from the lateral edge of the tube through the nail plate. A second pass through the flexible tube was added to create a second loop of suture for greater security

Wound care included dilute acetic acid soaks, routine cleansing with soap and water, and petrolatum covered by non-adherent dressings. A short course of oral cephalexin and acetaminophen with codeine was provided post-operatively. She was advised to wear soft, loose, opened toe footwear.

The patient was seen for follow-up monthly for trimming of the nail plate (including the distal edge of the flexible tube attached to the nail plate) along with empiric intradermal injections with triamcinolone (10 mg/ml) to prevent of inflammation. The nail folds continued to heal over time with dramatic initial improvement of onychocryptosis overall and pain relief. The right toenail site with nail tube splinting in place continued to improve over time. Unfortunately, onychocryptosis recurred at the left toenail lateral nail fold site 2 months after lateral nail fold excision and was concurrent with return of symptoms. Lateral nail fold hypertrophy of the periungual soft tissue, extending ovetop the nail plate surface prompted intervention with placement of a nail tube splint. The nail tube splints were each removed after 3 months. Photos over a 3-month course are shown in Figure 3. The patient is now 1.5 years out from treatment and both nails remain free of onychocryptosis. Her pain has resolved, she can wear normal shoes, and she participates in daily activities as well as sports.

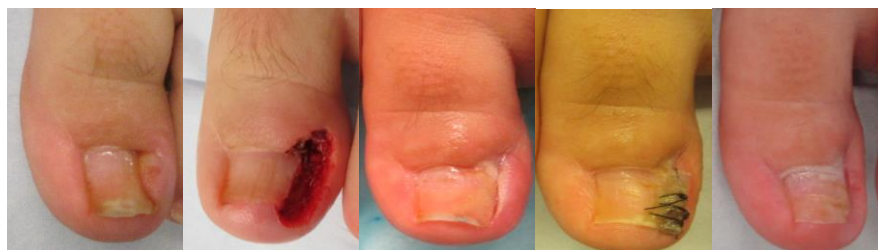**Right toe:**

Preoperative    Postoperative    1 month    2 months    3 months



**Left toe:**

Preoperative    Postoperative    1 month    2 months    3 months



**Figure 3.** Operative course of bilateral affected great toes

In our patient, nail tube splinting was a more successful method than lateral nail fold excision in this side-by-side case example. Intradermal triamcinolone injections did not prevent recurrence of onychocryptosis. We noted that the lateral nail plate deep to the proximal nail fold was brittle and spiculated. We postulate that this could be an inciting factor in triggering chronic onychocryptosis in addition to a putative familial component. It is unclear if brittle nails can initiate onychocryptosis or if prior surgeries generate nail spicules that chronically irritate and inflame the nail fold.

## Discussion

There is no consensus for treatment of onychocryptosis in pediatric patients. Management strategies vary including conservative measures for early inflammation (stage I) such as warm water soaks, topical antibiotics, and proper nail trimming techniques. Surgical procedures are reserved for ingrown toenails with infection, new periungual tissue (stage 2) or nail fold fibrosis (stage 3). Surgical techniques commonly employed are nail edge separation, wedge resection, partial or complete nail avulsion with or without matricectomy (using phenol or surgical destruction), and surgical resection of skin from the lateral aspect of the distal phalynx [4].

Although the nail tube splinting method has undergone various modifications over the years, the technique was first described by Wallace et al in 1979 and named 'The Gutter Method'. The aim was to create a method of treating ingrown toenails that could be carried out in a general practice setting [5]. The principal behind this is to use the gutter or sleeve to envelop the lateral nail plate as a means to relieve the periungual soft tissue of ongoing trauma from friction against nail spurs. It is left in place from 6 weeks up to 3 months, thus alleviating pain, allowing the lateral nail groove to heal spontaneously and preserve normal anatomy and function.

Several reports have suggested that the nail tube splinting technique is simple, non-invasive, and effective with low recurrence rates. Two recent comparative studies have reported similar 4-month recurrence rates for phenol matricectomy (0-24%) and the nail tube splinting method (0-28.6%). Despite similar recurrence rates, the authors of both studies supported the use of the nail tube splinting method. Ceren et al suggested that the nail tube splint be used as first line therapy for uncomplicated ingrown nails whereas phenol matricectomy be used in patients with hypertrophic granulation tissue and relapsing ingrown toenails [2,6]. Alghamdi et al concluded that whereas both methods are effective and have similar recurrence rates, the nail tube splint method may be better tolerated by the patient with greater comfort post operatively and provide better cosmetic results with greater matrix conservation and regrowth of normal nail with fewer signs of previous surgeries [6,7]. We propose that nail tube splinting may also be a successful first-line strategy for chronic and recurrent onychocryptosis.

## Conclusion

Our case highlights the value of the nail tube splinting method, which was the only successful treatment in a pediatric patient with chronic onychocryptosis recalcitrant to multiple matricectomies and lateral nail fold excision. The nail tube splint method may be attempted prior to repeating matricectomy and may be a useful alternative to invasive approaches such as lateral nail fold excision.

## References

1. Abby N, Roni P, Amnon B, Yan P. Modified Sleeve Method Treatment of Ingrown Toenail. *Dermatol Surg.* 2002 Sep;28(9):852-5 [PMID: 12269882]
2. Ceren E, Gokdemir G, Arıkan Y, Purisa S. Comparison of Phenol Matricectomy and Nail-Splinting With a Flexible Tube for the Treatment of Ingrown Toenails. *Dermatol Surg.* 2013 Aug;39(8):1264-9 [PMID: 23631560]
3. Perez CI, Maul XA, Catalina Heusser M, Zavala A. Operative technique with rapid recovery for ingrown nails with granulation tissue formation in childhood. *Dermatol Surg.* 2013 March;39(3 pt 1):393-7 [PMID: 23279567]
4. Gauldi G, Monari P, Crotti S, Calzavara-Pinton P. Surgical Treatment of ingrown toenail: the Monaldi technique, a new simple proposal. *Dermatol Surg.* 2014 Feb;40(2):208-10 [PMID: 24237640]
5. Wallace WA, Milne DD, Andrew T. Gutter treatment for ingrowing toenails. *British Medical Journal.* 1979 July 21;2(6183):168-71 [PMID: 466336]
6. Al Ghamdi KM, Khurram H. Nail Tube Splinting Method Versus Lateral Nail Avulsion With Phenol Matricectomy: A Prospective Randomized Comparative Clinical Trial for Ingrown Toenail Treatment. *Dermatol Surg.* 2014 Nov;40(11):1214-20 [PMID: 25322163]
7. Haricharan RN, Masquijo J, Betolli M. Nail-fold excision for the treatment of ingrown toenail in children. *J Pediatrics.* 2013 Feb;162(2):-398-402 [PMID: 22974574]