

UCLA

UCLA Previously Published Works

Title

Fungal perianal abscess as the initial presentation of disseminated coccidioidomycosis

Permalink

<https://escholarship.org/uc/item/7976c4hz>

Authors

Olivo-Freites, Christian
Gallardo-Huizar, Oscar E
Graber, Christopher J
et al.

Publication Date

2022

DOI

10.1016/j.idcr.2022.e01636

Peer reviewed



Case report

Fungal perianal abscess as the initial presentation of disseminated coccidioidomycosis

Christian Olivo-Freites^a, Oscar E. Gallardo-Huizar^{b,*}, Christopher J. Graber^{a,c}, Kevin Ikuta^{a,c}

^a Division of Infectious Diseases, Department of Medicine, David Geffen School of Medicine at the University of California, Los Angeles, CA, USA

^b Department of Internal Medicine, Olive View-UCLA Medical Center, Sylmar, CA, USA

^c Infectious Diseases Section, VA Greater Los Angeles Healthcare System, Los Angeles, CA, USA



ARTICLE INFO

Keywords:

Coccidioides

Coccidioidomycosis

Abscess

Perianal

ABSTRACT

Coccidioides is a dimorphic fungus that can cause various clinical presentations, mainly pulmonary, skin, musculoskeletal, and in the central nervous system; most reports are in the southwestern area of the USA. We present a case of a young male with a perianal abscess in the absence of any pulmonary or constitutional symptoms. Perianal abscess as initial manifestation is a novel presentation of coccidioidomycosis in the literature.

Introduction

Coccidioidomycosis, caused by the dimorphic fungi *Coccidioides immitis* and *Coccidioides posadasii*, is endemic to the southwestern United States and Mexico as well as Central and South America, respectively. Initial infection occurs predominantly by inhalation of aerosolized arthroconidia and rarely by direct cutaneous inoculation [1]. Coccidioidomycosis risk factors are living, working, or traveling in an area where *Coccidioides* is endemic. Immunocompromised persons (i.e., HIV, cancer, and transplant), pregnant women (particularly in their third trimester and immediately postpartum), individuals with diabetes mellitus, and with heart or lung conditions, are particularly at a higher risk of infection [2]. Based on epidemiological studies certain ethnicities are susceptible to disseminated coccidioidomycosis, especially those of Filipino and African American descent [2]. The literature classifies the condition into three categories: primary pulmonary infection (most common), extrapulmonary dissemination, and rarely, primary cutaneous coccidioidomycosis [3]. Usually, pulmonary coccidioidomycosis is a self-limited disease that does not require treatment in an otherwise healthy person [4]. Extra-thoracic disseminated disease occurs in less than 1% of infected persons and can affect any organ system or tissue [5]. Here we describe an unusual presentation of disseminated coccidioidomycosis that manifested as a perianal abscess.

Case

A 37-year-old male of Filipino descent who had lived in Bakersfield, California, for three years before presentation, with a history of Lynch syndrome, glucose 6-phosphate deficiency, hypertriglyceridemia, and essential hypertension, presents with a chief complaint of a perianal lesion that had started one month prior. He described the lesion as enlarging, extending to the scrotum with a “C” shape, and associated with rectal pain with poor response to analgesics. He denied having constitutional, neurologic, pulmonary, musculoskeletal, or urinary symptoms. Before this visit, he had a colonoscopy six years prior for his Lynch syndrome without abnormal findings. He denied the use of tobacco, alcohol, or illicit drugs. He was not sexually active, identified as heterosexual, denied a history of anal intercourse, and denied any trauma to the anal and perineal areas. His travel history included going to Pennsylvania one year before the visit, and he was studying for pilot school. He denied known exposures to tuberculosis.

His physical exam demonstrated vital signs within normal limits and a semicircular right firm perianal lesion extending into the perineal and scrotal area; it was erythematous, edematous, and tender to palpation. No masses on digital rectal examination (DRE) or bleeding were noted, with normal sphincter tone. The initial laboratories showed: a complete blood count, comprehensive metabolic panel, hemoglobin A1C within normal limits, and a 4th generation human immunodeficiency virus (HIV) test that was negative.

During the initial visit, he was prescribed seven days of

* Correspondence to: UCLA Olive View, Department of Medicine, room 2B-182, 14445 Olive View Dr., Sylmar, CA 91342, USA.

E-mail address: ogallardohuizar@mednet.ucla.edu (O.E. Gallardo-Huizar).

<https://doi.org/10.1016/j.idcr.2022.e01636>

Received 31 August 2022; Received in revised form 15 October 2022; Accepted 31 October 2022

Available online 1 November 2022

2214-2509/Published by Elsevier Ltd. This is an open access article under the CC BY-NC-ND license (<http://creativecommons.org/licenses/by-nc-nd/4.0/>).

ciprofloxacin. In his follow-up visit, he reported that the mass was growing, and an MRI was performed to evaluate it in detail. A pelvic MRI with contrast showed an extensive 8.6 cm multiloculated thick-walled fluid collection (Fig. 1) within the right perineum consistent with an abscess with inflammatory changes extending towards the left peritoneum, right ischio-anal fossa, and prostate. Focal fluid collections within the prostate were suggestive of abscesses. Several small anal fissures did not appear to communicate with the fluid accumulation. After those results returned, he was scheduled for a new appointment, although due to worsening pain, he decided to come to the emergency department (approximately 3 weeks later after the initial visit), and an emergent surgery was performed. The surgery team performed an incision and drainage. The right perianal abscess cavity tracked anteriorly with induration surrounding and within the anal canal. The bacterial culture grew *Klebsiella pneumoniae* (susceptible to all tested antibiotics in the antibiogram, including ciprofloxacin). Pathology studies from the abscess cavity demonstrated skin and subcutaneous tissue with marked acute and chronic inflammation and reactive changes. The primary team did not order fungal stains in the tissue sample. He was discharged home on ciprofloxacin 500 mg orally twice daily and metronidazole 500 mg thrice daily. After his discharge, he started to have generalized abdominal pain and increased (3 times a day) watery bowel movements without blood or mucus; the symptoms resolved without any new medication after two weeks. Fifteen days later, fungal cultures of the drained material grew *Coccidioides immitis*.

Coccidioides serologies resulted in a positive immunodiffusion test and complement fixation (CF) titer of > 1:4096. A chest tomography showed a right lung cluster of nodular opacities. A bone scan did not show any bone lesions; however, there was a pleural-based soft-tissue density in the medial right upper lung (16 × 15 mm) adjacent to the posterior right 6th rib. Based on his clinical presentation, serologic studies, and culture results, we presumed *Coccidioides* infection as the source of the pulmonary, pleural, and prostatic lesions. We started fluconazole 800 mg daily for disseminated coccidioidomycosis. After the incision and drainage, the patient reported immediate improvement in the pain and sensation of fullness. During his initial follow-up, he denied any pulmonary, constitutional, urinary, or recurrent perianal symptoms while on antifungal therapy. In the physical exam, the erythema and edematous appearance of the perineal skin resolved.

After starting fluconazole, he reported persistent nausea, abdominal pain, and dry oral mucosa. Due to this, the patient was changed to

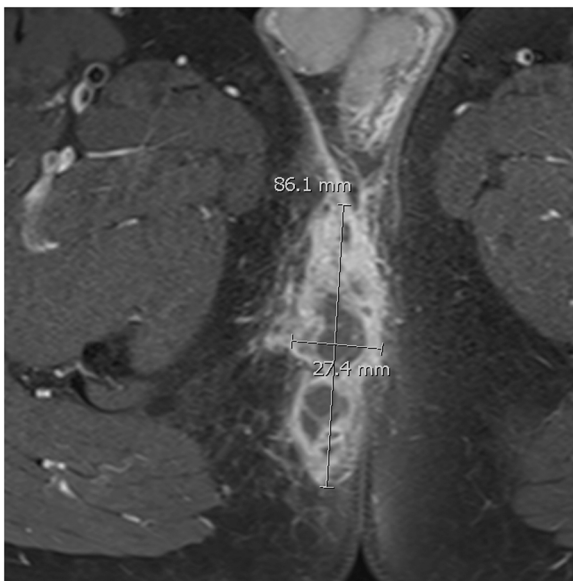


Fig. 1. Magnetic resonance with contrast of the pelvis showing an axial view of the perianal abscess.

posaconazole delayed-release tablets 300 mg daily. After one week (and approximately three months after initial perianal abscess drainage), the patient came to the emergency department with fevers, chills, conjunctival injection, and headaches and tested positive for SARS-CoV-2. After two weeks, most of the symptoms disappeared. Although the headache persisted, it was frontal and bilateral, not associated with changes in mental status, neck pain, neck stiffness, photophobia, changes in vision, focal motor/sensory deficits, rhinorrhea, or sinus pain. CT of the head without contrast did not show any abnormalities.

A lumbar puncture was performed and showed opening pressure, cell count, protein, and glucose within normal limits, with negative bacterial and fungal cultures. Serum *Coccidioides* complement fixation titer decreased to 1:1. One month later, the patient reported high blood pressure (170/80 mmHg) despite taking his medications appropriately. The posaconazole level was elevated (5.78 mcg/mL). We suspected posaconazole-induced pseudo hyperaldosteronism (PIPH) because of the elevated posaconazole level, hypertension, undetectable aldosterone blood levels, blood renin levels close to the inferior limit (0.6 ng/mL/hour), and potassium serum levels in the inferior border of the range (3.2 mEq/L).

We decreased the dose to 200 mg PO daily and his blood pressure subsequently normalized. The patient lost to follow-up after that visit. The patient was scheduled for a follow-up pulmonary study. However, it is unclear if he will come back.

If he returns to our institution, we will place the patient on 12–24 months of therapy. If his symptoms are absent and there is radiological resolution of the lesions after that interval, we would discontinue anti-fungal therapy and place him in a period of close observation to evaluate symptoms and CF titers. We would avoid indefinite therapy in the absence of CNS disease. If the patient requires immunosuppressive therapy or acquired/developed a cellular immunodeficiency, we will recommend secondary prophylaxis.

Discussion

Coccidioides can infect any organ, bone, and skin area in the human body. However, most exposures to the fungus result in asymptomatic infection. The most affected organ and common gate of entry is the lung [1]. Disseminated coccidioidomycosis can present with a broad spectrum of clinical manifestations, most commonly involving soft tissues, bone, and the central nervous system. Most patients are diagnosed via serology; this can be done through enzyme immunoassay (EIA), immunodiffusion (ID), and complement fixation (CF) [6]. Production of IgM usually starts within 1–3 weeks of symptom onset, followed by IgG production within 4–8 weeks [6]. The EIA and ID tests are usually used for screening, and CF titers are used for monitoring the disease. A *Coccidioides* antigen test is available, possibly valuable for immunocompromised individuals [1]. Any patient with persistent headaches or other CNS symptoms with suspicion of *Coccidioides* infection should undergo cerebrospinal fluid (CSF) testing to rule out meningitis. The diagnosis can be confirmed through histopathology (E.g., the presence of spherules and endospores) and fungal cultures [6]. Case reports have described the use of PET-CT scan in evaluating disseminated coccidioidomycosis; this diagnostic tool is helpful in clinically occult skeletal and soft tissue lesions. Coccidioidal pulmonary nodules take up significantly less fludeoxyglucose (FDG 18 F) than those due to malignancies; however, there is an overlap between granulomatous and malignant lesions at lower standardized uptake values (SUV) [7,8].

The decision to treat and duration of therapy depends on the clinical syndrome. International and American guidelines recommend a period of observation for individuals with pulmonary coccidioidomycosis because most patients can control the infection [4,6]. Treatment should be started in immunosuppressed patients, disseminated disease, those with substantial cardiopulmonary comorbidities, prolonged infection, and CF titers of 1:32 or higher. For those with pulmonary disease, treatment is suggested in the presence of associated 10% weight loss or

greater, night sweats for more than three weeks, and infiltrates > 50% of one lung or bilateral pulmonary disease [6]. First line therapy is typically fluconazole in most clinical presentations (including meningitis); disease refractory to fluconazole is treated with itraconazole, voriconazole, posaconazole, or Amphotericin B, depending on disease severity [6].

Enteric and skin flora commonly cause perianal abscesses [9]. This entity is more common in men. Certain conditions, like human immunodeficiency virus (HIV), inflammatory bowel disease (IBD), and smoking, are known risk factors [10]. Management of coccidioidomycosis in this setting involves abscess drainage and antifungal treatment. Due to the lack of data, the type and duration of antifungal therapy are not standardized. The differential diagnosis of unresolved perianal abscesses should include actinomycosis and Crohn's disease when fistulas and draining sinuses are present [11,12]. Furthermore, patients coming from specific geographical regions should raise the possibility of tuberculosis [13], endemic mycoses [14], and parasites [15] (E.g., *Enterobius vermicularis*); especially in immunocompromised hosts. In patients with high-risk sexual behavior sexually transmitted infections should be considered (E.g., HIV and Gonorrhoea) [12,16]. Other entities that should be explored are hidradenitis suppurativa [17], and immunodeficiencies (primary or acquired) [18].

We presumed the prostate abscess was also a manifestation of *Coccidioides* infection; no prostatic fluid analyses or urine culture was performed because we thought all the abnormal findings were related to *Coccidioides*; also, there were no urinary symptoms. In a review of coccidioidomycosis of the male genital tract, the prostate is the second most common site (second to the epididymis). Usually, it presents with prostatic enlargement, urinary obstruction, tenderness, and palpable nodules. In the study, they also noted that 13% had simultaneous pulmonary infections, 63% had positive urine cultures, and most cases were diagnosed incidentally during surgical procedures. Biopsies showed necrotizing granulomas in the infected tissues. There is no standard therapy, fluconazole, ketoconazole, and amphotericin B, have been used. There was a combination of approaches: surgical therapy only, medical and surgical therapy, and medical therapy only. The authors suggested that patients with symptoms require immediate antifungal therapy, and patients with minimal tissue involvement without systemic symptoms can be observed. In contrast, patients with more extensive organ involvement should receive antifungal therapy [19]. Of the azoles, fluconazole is the most studied antifungal agent in prostatic tissue and fluid. In a study, a group of patients being treated with oral fluconazole for cryptococcal meningitis was found to have prostatic fluid fluconazole concentrations between 59% and 89% of the serum value [20]. Because the patient was unable to tolerate fluconazole, we transitioned to the patient to posaconazole. Posaconazole was chosen based on our prior clinical experience and local expert opinion on its role as a salvage agent (particularly the new extended-release formulation) for coccidioidomycosis when clinical failure with fluconazole is suspected or intolerance of high-dose fluconazole is encountered.

Conclusion

Coccidioidomycosis perianal abscess could occur from a disseminated infection or as a primary infection. For large abscesses, drainage seems necessary as an adjunct to antifungal therapy. This novel presentation teaches the diversity of expressions that *Coccidioides spp* can cause in humans.

Funding

This research did not receive any specific grant from public, commercial, or not-for-profit funding agencies.

CRedit authorship contribution statement

Christian Olivo-Freites: Literature review, Writing – original draft, Supervision, Writing – review & editing of the final draft. **Oscar E. Gallardo-Huizar:** Literature review, Writing – original draft preparation. **Christopher J. Graber:** Writing – review & editing. **Kevin Ikuta:** Writing – review & editing.

Acknowledgments

We thank the patient for permitting us to publish this case report to help future patients with disseminated coccidioidomycosis.

Notes

Patient consent

Informed consent was obtained from the patient.

Potential conflicts of interest

All authors: No reported conflicts of interest.

References

- [1] Bays DJ, Thompson 3rd GR. Coccidioidomycosis. *Infect Dis Clin North Am* 2021; 35:453–69. <https://doi.org/10.1016/j.idc.2021.03.010>.
- [2] Brown J, Benedict K, Park BJ, Thompson 3rd GR. Coccidioidomycosis: epidemiology. *Clin Epidemiol* 2013;5:185–97. <https://doi.org/10.2147/CLEP.S34434>.
- [3] Kimes KE, Kasule SN, Blair JE. Pulmonary coccidioidomycosis. *Semin Respir Crit Care Med* 2020;41:42–52. <https://doi.org/10.1055/s-0039-3400998>.
- [4] Galgiani JN, Ampel NM, Blair JE, Catanzaro A, Geertsma F, Hoover SE, et al. Infectious Diseases Society of America (IDSA) Clinical Practice Guideline for the Treatment of Coccidioidomycosis. *Clin Infect Dis* 2016;63:e112–46. <https://doi.org/10.1093/cid/ciw360>.
- [5] Smith CE, Beard RR. Varieties of coccidioid infection in relation to the epidemiology and control of the diseases. *Am J Public Health Nations Health* 1946; 36:1394–402. <https://doi.org/10.2105/ajph.36.12.1394>.
- [6] Thompson 3rd GR, Le T, Chindamporn A, Kauffman CA, Alastruey-Izquierdo A, Ampel NM, et al. Global guideline for the diagnosis and management of the endemic mycoses: an initiative of the European Confederation of Medical Mycology in cooperation with the International Society for Human and Animal Mycology. *Lancet Infect Dis* 2021;21:e364–74. [https://doi.org/10.1016/S1473-3099\(21\)00191-2](https://doi.org/10.1016/S1473-3099(21)00191-2).
- [7] Foerter J, Sundell J, Vroman P. PET/CT: first-line examination to assess disease extent of disseminated coccidioidomycosis. *J Nucl Med Technol* 2016;44:212–3. <https://doi.org/10.2967/jnmt.115.170449>.
- [8] Reyes N, Onadeko OO, Luraschi-Monjagatta MDC, Knox KS, Rennels MA, Walsh TK, et al. Positron emission tomography in the evaluation of pulmonary nodules among patients living in a coccidioid endemic region. *Lung* 2014;192: 589–93. <https://doi.org/10.1007/s00408-014-9589-2>.
- [9] Xu RW, Tan K-K, Chong C-S. Bacteriological study in perianal abscess is not useful and not cost-effective. *ANZ J Surg* 2016;86:782–4. <https://doi.org/10.1111/ans.13630>.
- [10] Sahnan K, Adegbola SO, Tozer PJ, Watfah J, Phillips RK. Perianal abscess. *BMJ* 2017;356:j475. <https://doi.org/10.1136/bmj.j475>.
- [11] Dosis A, Khan A, Leslie H, Musaad S, Smith A. Perianal actinomycosis: a surgeon's perspective and review of literature. *Ann Coloproctol* 2021;37:269–74. <https://doi.org/10.3393/ac.2021.00332.0047>.
- [12] Adamo K, Sandblom G, Brännström F, Strigård K. Prevalence and recurrence rate of perianal abscess—a population-based study, Sweden 1997–2009. *Int J Colorectal Dis* 2016;31:669–73. <https://doi.org/10.1007/s00384-015-2500-7>.
- [13] Sasahara K, Kitahama K, Aiko S, Namkoong H. Anal tuberculosis presenting as refractory perianal abscess. *Clin Case Rep* 2021;9:e04177. <https://doi.org/10.1002/ccr3.4177>.
- [14] Wheelwright M, Yousaf H, Plummer R, Cartwright D, Gaertner W, Amin K. Perianal Histoplasmosis Presenting as a Mass Suspicious for Malignancy: A Case Report with Review of Gastrointestinal Manifestations of Histoplasmosis. *Am J Case Rep* 2019; 20:1740–4. <https://doi.org/10.12659/AJCR.918220>.
- [15] Shelat VG, Ng SR, Sim R. Perianal abscess secondary to *Enterobius vermicularis* infestation. *Ann Acad Med Singap* 2011;40:149.
- [16] El-Dhuwaib Y, Ammori BJ. Perianal abscess due to *Neisseria gonorrhoeae*: an unusual case in the post-antibiotic era. *Eur J Clin Microbiol Infect Dis* 2003;22: 422–3. <https://doi.org/10.1007/s10096-003-0958-7>.
- [17] Nomura Y, Nomura T, Sakai K, Sasaki K, Ohguchi Y, Mizuno O, et al. A novel splice site mutation in NCSTN underlies a Japanese family with hidradenitis suppurativa.

- Br J Dermatol 2013;168:206–9. <https://doi.org/10.1111/j.1365-2133.2012.11174.x>.
- [18] Lejkowski M, Maheshwari A, Calhoun DA, Christensen RD, Skoda-Smith S, Dabrow S. Persistent perianal abscess in early infancy as a presentation of autoimmune neutropenia. J Perinatol 2003;23:428–30. <https://doi.org/10.1038/sj.jp.7210952>.
- [19] Sohail MR, Andrews PE, Blair JE. Coccidioidomycosis of the male genital tract. J Urol 2005;173:1978–82. <https://doi.org/10.1097/01.ju.0000158455.24193.12>.
- [20] Luzzati R, Gatti G, Lazzarini L, Limonta D, Vento S, Concia E. Fluconazole penetration into the prostatic fluid of patients with AIDS-associated cryptococcal meningitis. J Antimicrob Chemother 1998;41:423–4. <https://doi.org/10.1093/jac/41.3.423>.