

UC Davis

UC Davis Previously Published Works

Title

Detection of Relapse by Tumor Markers Versus Imaging in Children and Adolescents With Nongerminomatous Malignant Germ Cell Tumors: A Report From the Children's Oncology Group

Permalink

<https://escholarship.org/uc/item/9dr4132z>

Journal

Journal of Clinical Oncology, 37(5)

ISSN

0732-183X

Authors

Fonseca, Adriana
Xia, Caihong
Lorenzo, Armando J
et al.

Publication Date

2019-02-10

DOI

10.1200/jco.18.00790

Peer reviewed

Detection of Relapse by Tumor Markers Versus Imaging in Children and Adolescents With Nongerminomatous Malignant Germ Cell Tumors: A Report From the Children's Oncology Group

Adriana Fonseca, MD¹; Caihong Xia, PhD²; Armando J. Lorenzo, MD, MSc¹; Mark Krailo, MD^{2,3}; Thomas A. Olson, MD⁴; Farzana Pashankar, MD, MBBS⁵; Marcio H. Malogolowkin, MD⁶; James F. Amatruda, MD, PhD⁷; Deborah F. Billmire, MD⁸; Carlos Rodriguez-Galindo, MD⁹; A. Lindsay Frazier, MD¹⁰; and Furqan Shaikh, MD¹

PURPOSE To investigate relapse detection methods among children and adolescents with nongerminomatous malignant germ cell tumors (MGCTs) and to determine whether tumor markers alone might be sufficient for surveillance.

METHODS We retrospectively reviewed all patients enrolled in a phase III, single-arm trial for low-risk and intermediate-risk MGCTs. The method used to detect relapse was assessed based on case report forms, tumor markers, imaging, and pathology reports. Relapses were classified into one of two categories on the basis of whether they were (1) detectable by tumor marker elevation or (2) not detectable by tumor markers.

RESULTS A total of 302 patients were enrolled, and 284 patients had complete data for review. Seven patients had normal tumor markers at initial diagnosis, and none experienced a relapse. At a median follow-up of 5.3 years, 48 patients (16.9%) had experienced a relapse. After central review, 47 of 48 relapses (98%) were detected by tumor marker elevation. Of the 47 patients, 16 (33.3%) had abnormal tumor markers with normal/unknown imaging, 31 patients (64.6%) had abnormal tumor markers with abnormal imaging, and one patient (2.1%) had abnormal imaging with unknown marker levels at relapse.

CONCLUSION Tumor marker elevation is a highly sensitive method of relapse surveillance, at least among children and adolescents with tumor marker elevation at initial diagnosis. Eliminating exposure to imaging with ionizing radiation may enhance the safety of relapse surveillance in patients treated for MGCT.

J Clin Oncol 37:396-402. © 2018 by American Society of Clinical Oncology

INTRODUCTION

Tumor markers in malignant germ cell tumors (MGCTs) have been demonstrated to be highly sensitive and specific diagnostic and monitoring tools. Their appropriate decline with treatment has been shown to be prognostic in adult patients, and serial measurements are an integral part of monitoring response to therapy and relapse surveillance.¹⁻⁵

In addition to tumor marker measurements, current pediatric North American MGCT protocols include cross-sectional imaging with computed tomography (CT) scans of the chest, abdomen, and pelvis for surveillance after completion of therapy. Specifically, most protocols recommend repeating CT scans every 3 months for the first year, every 6 months during the second year, and annually thereafter for up to 5 years post-treatment. However, it is worth noting that the current practice of using CT scanning as part of routine surveillance for children and adolescents with MGCT is

itself not based on any particular scientific evidence. This strategy may deliver significant cumulative radiation dose. Each scan provides approximately 10 to 15 millisievert of ionizing radiation, the equivalent of 5 years of background radiation.⁶⁻⁸ The diagnostic interventions used can result in deleterious health effects⁹; the repeating schedule of these scans significantly increases radiation exposure in a young patient population with an otherwise long life expectancy and may contribute to an increased risk of second malignant neoplasms (SMNs), as suggested by population-based studies.^{10,11} Miglioretti et al¹¹ reported the lifetime attributable risk of cancer per 10,000 CT scans to be between 0.5 and 30.5, with the highest risk of radiation-induced solid tumor development with abdomen/pelvic CT, which is frequently used in the surveillance of MGCTs. For example, in girls, a radiation-induced solid cancer is projected to result from every 300 to 390 abdomen/pelvis CT scans and every 330 to 480 chest CT scans.

ASSOCIATED CONTENT

Data Supplement

Author affiliations and support information (if applicable) appear at the end of this article.

Accepted on November 6, 2018, and published at [jco.org](https://doi.org/10.1200/JCO.18.00790) on December 21, 2018; DOI <https://doi.org/10.1200/JCO.18.00790>

Furthermore, in young children, CT scans often require sedation or general anesthesia, with potential deleterious effects in neurocognitive outcomes.^{12,13} False-positive results, such as nonspecific lung nodules, are commonly encountered and can contribute to parental anxiety or additional investigations. Last, CT scanning increases the overall cost and resource use of MGCT treatment.

Children and adolescents with MGCTs have excellent outcomes with modern combination therapy.¹⁴ The Pediatric Intergroup Germ Cell studies¹⁵ included three risk groups and therapeutic strategies. For the low-risk (LR) group, the 6-year event-free survival (EFS) and overall survival was 81.8% and 100%, respectively. The intermediate-risk (IR) and high-risk groups were treated with adjuvant bleomycin, etoposide, and cisplatin chemotherapy; the 6-year EFS and overall survival were 90.2% and 86.9%, respectively. With such low probability of relapse, it is important to minimize radiation exposure during surveillance.

We hypothesized that MGCTs with elevated tumor markers at diagnosis would be amenable to monitoring with serial alpha-fetoprotein (AFP) and beta-human chorionic gonadotropin (β -HCG) measurements, thus allowing a reduction or avoidance of ionized radiation-based imaging. To explore this hypothesis, we sought to determine the detection method of all relapses in a recent MGCT trial conducted by the Children's Oncology Group (COG).

METHODS

Clinical trial data from patients enrolled from 2003 to 2011 in the COG AGCT0132 ([ClinicalTrials.gov](https://clinicaltrials.gov/ct2/show/study/NCT00053352) identifier: NCT00053352) study were retrospectively reviewed. This phase III single-arm trial enrolled patients with LR and IR MGCTs, and the main results have been previously reported.¹⁶⁻¹⁸ Patients with ovarian and extragonadal tumors were age 21 years or younger, and patients with testicular tumors were younger than 15 years of age at diagnosis. The LR arm included stage I ovarian and testicular germ cell tumors and was prescribed an observation-alone strategy, with chemotherapy given only to patients who subsequently relapsed. Patients in the IR arm were prescribed adjuvant chemotherapy and had stage II to IV testicular tumors, stage II to III ovarian tumors, and stage I to II extragonadal tumors or were initially enrolled in the LR arm and experienced relapse or progression on observation. Eligibility required the presence of at least one of the following elements: yolk sac tumor (YST), choriocarcinoma, or embryonal carcinoma. Patients with stage IV ovarian MGCTs ($n = 1$), pure seminoma/dysgerminoma ($n = 8$), and pure immature teratoma ($n = 4$), and those with somatic malignant transformation ($n = 1$) were excluded. Institutional review board approval was obtained at all participating institutions.

Per protocol, patients with a persistent elevation of tumor markers of at least five times the upper limit of normal were to undergo a complete radiologic evaluation of the primary site and other clinically relevant sites of disease. We identified each patient's first relapse (patients with second or subsequent relapses and disease progression while receiving therapy were excluded from this analysis) and determined their detection method per institutional report. Data for all patients who experienced a relapse were centrally reviewed, including case report forms, imaging, pathology, and tumor marker levels. Laboratory data were assessed to ascertain whether tumor markers were performed and their status within 10 days of the date of relapse.

Patients who experienced a relapse were classified into five initial categories on the basis of whether they were detected by (1) abnormal tumor markers, unknown imaging, (2) abnormal tumor markers, normal imaging; (3) abnormal tumor markers, abnormal imaging, (4) normal tumor markers, abnormal imaging, and (5) unknown tumor markers, abnormal imaging. The flow of the patients during the central review is shown in [Figure 1](#).

Statistical Analyses

Data current to March 2015 were used in this analysis. EFS was defined as the time from enrollment until disease progression, SMN, death, or last patient contact, whichever occurred first. The survivor function for EFS was estimated using the Kaplan-Meier method.¹⁹ Median follow-up time was obtained according to the Kaplan-Meier estimate of potential follow-up method.²⁰ For the primary outcome measure, we identified patients who had a relapse per the protocol and determined the proportion of relapses that were detectable by tumor marker elevation among all relapsed patients. We obtained measures in two overall categories: (1) detectable by tumor markers and (2) not detectable by tumor markers. Only patients who experienced a relapse were considered for the primary outcome measure.

Continuous variables were summarized descriptively using medians; categorical variables were reported using percentages. All analyses were performed using STATA statistical software (version 15; STATA, College Station, TX).

RESULTS

The LR arm of AGCT0132 enrolled 104 patients and the IR arm enrolled 181 patients, for a total of 285 eligible patients. For this analysis, one patient from the IR arm was excluded because the patient moved immediately into a second-line therapy on the basis of persistent elevated tumor markers and hence never entered a surveillance phase.

The median follow-up as determined by the Kaplan-Meier estimate of potential follow-up method was 5.3 years, with a 95% CI of 4.1 to 5.5 years. Fifty-two patients

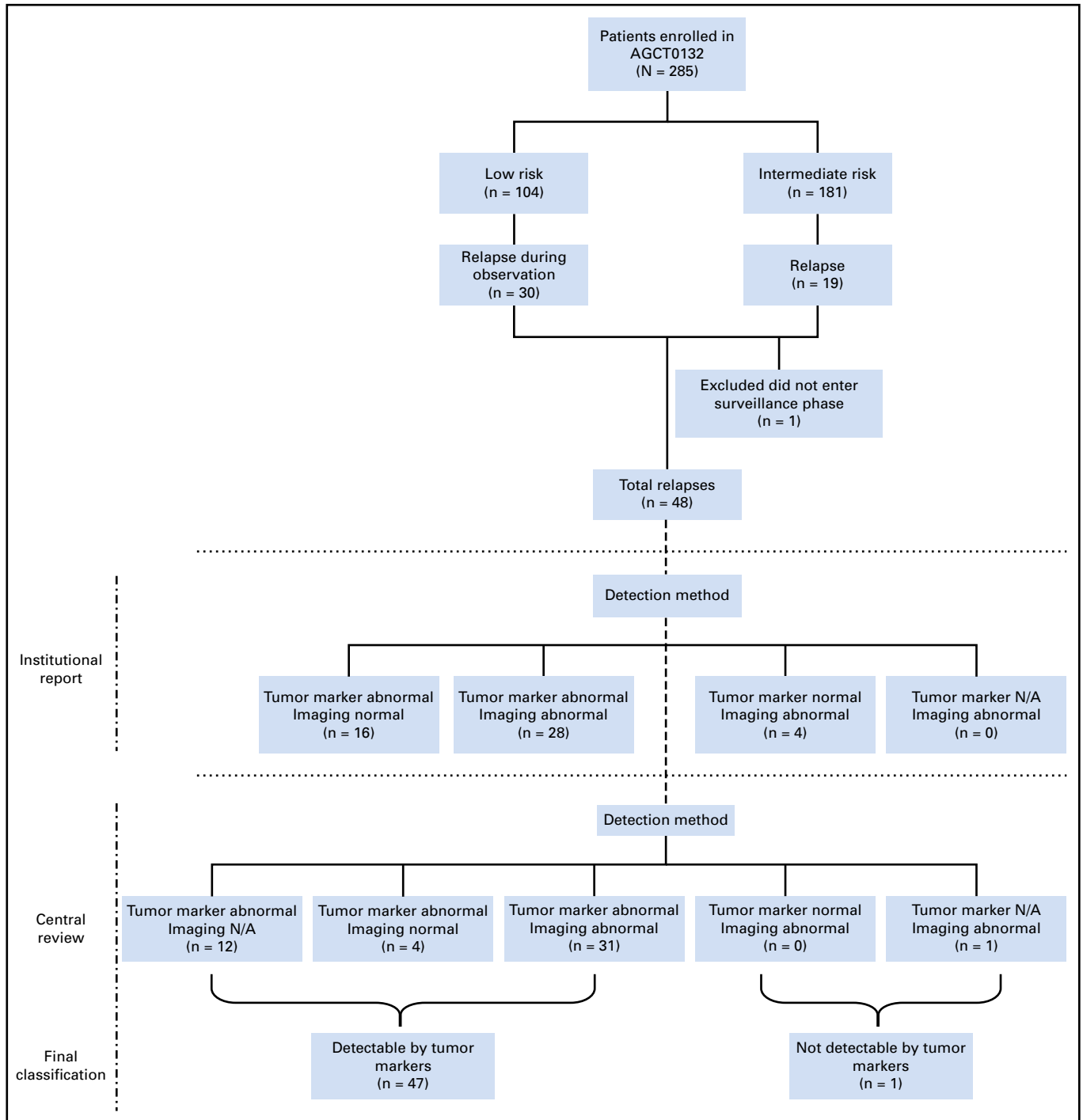


FIG 1. Consort diagram of flow of patients through the study. AGCT0132 ([ClinicalTrials.gov](https://clinicaltrials.gov/ct2/show/study/NCT00053352) identifier: NCT00053352), N/A, not available.

experienced an event, of which three were SMNs and 49 were first relapses. There were 30 relapses among patients in the LR arm and 19 relapses among patients in the IR arm.

Patient characteristics for the 284 patients enrolled in the trial are listed in [Table 1](#). A total of 122 patients (43%) were male, 107 tumors (37.7%) were testicular, 138 tumors

(48.6%) were ovarian, and 39 tumors (13.7%) were extragonadal. The most frequent histology was pure YST, observed in 117 patients (41.2%), followed by mixed MGCT in 78 patients (27.5%). Tumor markers were elevated at diagnosis in 277 patients (97.5%), and only seven patients (2.5%) did not have tumor marker elevation. Of the patients without tumor marker elevation, the most common

TABLE 1. Patient Characteristics

Characteristic	AGCT0132
Total No.	284
Age, years	
Median (range)	10 (0-20)
< 11	151 (53.2)
≥ 11	133 (46.8)
Sex	
Male	122 (43)
Female	162 (57)
Site	
Testes	107 (37.7)
Ovary	138 (48.6)
Extragenadal	39 (13.7)
Stage	
I testicular	82 (28.9)
I ovarian	29 (10.2)
I extragenadal	14 (4.9)
II testicular	7 (2.5)
II ovarian	47 (16.6)
II extragenadal	25 (8.8)
III testicular	6 (2.1)
III ovarian	62 (21.8)
III extragenadal	—
IV testicular	12 (4.2)
IV ovarian	—
IV extragenadal	—
Histology	
YST	117 (41.2)
YST plus teratoma	74 (26.0)
YST plus germinoma	9 (3.2)
EC plus teratoma	2 (0.7)
Mixed MGCT*	78 (27.5)
Germinoma†	1 (0.4)
Teratoma†	3 (1)
Tumor markers at diagnosis	
Either TM elevated	208 (73.3)
Both TMs elevated	69 (24.2)
No TM elevated	7 (2.5)
Elevated AFP, median (range), ng/mL	3,364 (9-7,475,001)
β-HCG elevated median (range), mIU/mL	550 (06.1-200.00)
Outcome	
Relapse	48 (16.9)
No relapse	236 (83.1)

NOTE. Data presented as No. (%) unless otherwise indicated.

Abbreviations: AGCT0132, [ClinicalTrials.gov](https://clinicaltrials.gov) identifier: NCT00053352; AFP, alpha-fetoprotein; β-HCG, beta-human chorionic gonadotropin; EC, embryonic carcinoma; MGCT, malignant germ cell tumor; TM, tumor marker; YST, yolk sac tumor.

*Mixed MGCTs are neoplasms containing combinations of two or more malignant germ cell elements.

†Histology is based on central review. Three patients with immature teratoma and one patient with germinoma were considered eligible based on institutional pathology reviews that observed malignant histology.

histology was teratoma, with a small component of YST of less than 5% (YST plus teratoma); two patients had mixed MGCT. Of the seven patients who had normal tumor markers at initial diagnosis, none experienced a relapse.

Forty-eight patients experienced a relapse; their characteristics are listed in [Table 2](#). The median time to relapse was 134.5 days, with a range of 19 to 440 days from enrollment. Among these patients, 31 had AFP elevation, two had β-HCG elevation, and 15 had both AFP and β-HCG elevation at diagnosis. At relapse, 39 patients (81%) had AFP elevation, one (2%) had β-HCG elevation, seven (15%) had both tumor markers elevated, and one did not have tumor marker data available. Therefore, after central review, 47 of 48 relapses (98%) were detectable by tumor marker elevation. The most common histology among relapsed tumors was mixed pure YST (41.7%), followed by mixed MGCT (37.5%). Sixteen patients (33%) had no reported site of relapse, with elevated tumor markers being the indication of relapse. In the subset of 20 prepubertal patients (younger than 11 years of age), all had AFP elevation at relapse. β-HCG was concurrently elevated in two of them, 19 patients had tumors with an extensive YST component at diagnosis, and one patient had microscopic YST. All relapsed patients received additional therapy per institutional preference.

Four relapses (8.3%) were initially reported to be detected by imaging only, according to their institutional report. However, on additional central review, three of four relapses were reported to be detected by imaging alone but in fact had tumor markers elevated along with imaging findings at relapse. The fourth patient had no tumor marker levels available at relapse. Nonetheless, this patient's primary tumor was 98% choriocarcinoma. Given that choriocarcinoma is almost universally associated with elevated levels of β-HCG, it is probable that this patient's tumor marker levels would have been elevated at the time of relapse.

Of the three patients with SMNs, one developed an undifferentiated sarcoma in the peritoneum 1.3 years after enrollment, one developed treatment-related acute myeloid leukemia 2.4 years after enrollment, and one developed a lymphangiosarcoma in the peritoneum 7.3 years after enrollment. Tumor markers were not elevated in any of these patients at the time of SMN diagnosis.

No teratoma relapses were reported in this trial because only relapses of malignant tumors were required to be reported. However, we conducted a central review of all the patients who underwent additional surgery or biopsies during their surveillance, and no patients with teratoma were reported.

DISCUSSION

The current study evaluated the detection method of relapses in children and adolescents with MGCTs after

TABLE 2. Characteristics of Patients Who Relapsed

Characteristic	All Patients	Detectable by TM Alone or Imaging N/A*	Detectable by TM and Imaging
Age, years	48	16	31
Median (range)	12 (0-18)	10 (1-16)	13 (0-18)
< 11	20 (41.7)	8 (50)	19 (38.7)
≥ 11	28 (58.3)	8 (50)	19 (61.3)
Sex			
Male	26 (54.2)	11 (68.8)	15 (48.4)
Female	22 (45.8)	5 (31.2)	16 (51.6)
Primary site			
Testes	26 (54.2)	11 (68.8)	15 (48.8)
Ovary	22 (45.8)	5 (31.2)	16 (51.6)
Stage			
I testicular	19 (39.6)	7 (43.8)	12 (38.7)
I ovarian	11 (22.9)	4 (25)	7 (22.6)
I extragonadal	—	—	—
II testicular	1 (2.1)	—	1 (3.2)
II ovarian	5 (10.4)	1 (6.2)	4 (12.9)
II extragonadal	—	—	—
III testicular	1 (2.1)	1 (6.2)	—
III ovarian	6 (12.5)	—	5 (16.1)
IV testicular only	5 (10.4)	3 (18.8)	2 (6.5)
Histology			
YST	20 (41.7)	5 (31.2)	15 (48.4)
YST plus teratoma	7 (14.6)	5 (31.2)	2 (6.5)
YST plus germinoma	1 (2.1)	—	1 (3.2)
EC plus teratoma	1 (2.1)	1 (6.4)	—
Immature teratoma	1 (1.2)	—	1 (3.2)
Mixed MGCTs†	18 (37.5)	5 (31.2)	12 (38.7)
Relapse detection			
By imaging	1 (2.0)	—	—
TMs at the time of relapse			
AFP elevated	39 (83)	11 (68.8)	28 (90.3)
β-HCG elevated	1 (2.1)	1 (6.2)	—
Both elevated	7 (14.9)	4 (25)	3 (9.7)
Site of relapse			
Local	7 (14.6)	—	7 (22.6)
Regional	6 (12.5)	—	5 (16.1)
Distant	9 (18.8)	—	9 (29.0)
Lymph nodes NOS	1 (2.1)	—	1 (3.2)
Regional lymph nodes	8 (16.7)	—	8 (25.8)
Distant lymph nodes	1 (2.1)	—	1 (3.2)
TMs only	16 (33.3)	16 (100)	—

NOTE. Data presented as No. (%) unless otherwise indicated. Local includes ovary and scrotum. Regional: includes pelvis, peritoneum, and abdomen. Distant includes lung, liver, and spleen; Regional lymph nodes include retroperitoneum, para-aortic, and intra-abdominal lymph nodes. Distant lymph nodes are intrathoracic.

Abbreviations: AFP, alpha-fetoprotein; β-HCG, beta-human chorionic gonadotropin; EC, embryonic carcinoma; MGCT, malignant germ cell tumor; N/A, not available; NOS, not otherwise specified; TM, tumor marker; YST, yolk sac tumor.

*TM alone or imaging N/A includes four patients with negative imaging and 12 patients where imaging was not available.

†Mixed MGCTs are neoplasms containing combinations of two or more malignant germ cell elements.

‡Excludes one patient without tumor markers at relapse and detected by imaging.

therapy. The key finding was that serum tumor markers were elevated at relapse in 98% of relapsed patients enrolled in the COG AGCT0132 study. These findings suggest that monitoring of tumor markers is a sensitive and effective strategy for detecting relapses in patients who presented with elevated tumor markers at diagnosis. Our results suggest that it may be appropriate to use tumor marker monitoring as the main surveillance strategy after therapy for patients with positive tumor markers at diagnosis.

If the 284 patients enrolled in this trial each had the nine CT scans prescribed by protocol for surveillance, they would have collectively undergone 2,556 CT scans of the chest, abdomen, and pelvis. Using the estimates proposed by Miglioretti et al,¹¹ that a radiation-induced solid cancer is projected to result from every 300 to 390 abdomen/pelvis CT scans and every 330 to 480 chest CT scans in girls, we appreciate the significant risks associated with this surveillance schedule, especially when nearly all patients could have had their relapse detected by tumor markers alone. Only one patient in this study had the relapse determined to be detected by imaging alone, but this patient had no tumor marker information available at relapse, and on the basis of histologic findings, likely would have had an elevated β -HCG.

Our study has several limitations. All patients who relapsed in this trial had elevated tumor markers at initial diagnosis. Thus, the results of our study cannot be extrapolated to patients without elevated tumor markers at diagnosis, such as patients with pure embryonal carcinoma or seminoma/germinoma. These patients should continue to have imaging-based surveillance. Such patients would be more common among adolescents and young adults and would be uncommon among young children. Furthermore, because this trial enrolled only children with LR and IR MGCTs, the

conclusion should be extrapolated with caution to patients with high-risk MGCTs, although the underlying principles may be similar. Although the clinical trial was a prospective trial, the current study was a secondary analysis conducted as a retrospective review of collected data. Last, our study did not assign patients to two different surveillance strategies to determine which was superior, but rather compared the detection methods of all patients on a single strategy and determined which components were most useful.

Surveillance imaging has been studied in other areas of pediatric oncology. In particular, the use of CT scans for relapse surveillance in neuroblastoma and Wilms tumor has demonstrated significant radiation exposure and a relative lack of benefit in relapse disease detection.²¹⁻²³ Voss²⁴ recently found that CT scanning is overused in patients with Hodgkin lymphoma, with a majority of relapses being detectable by clinical and laboratory findings.

Our results suggest that in patients with MGCTs presenting with elevated tumor markers at diagnosis, the number of imaging studies required could be significantly reduced by using tumor markers as the primary surveillance method for disease recurrence. Imaging studies may still be required to evaluate for the presence of residual teratoma or SMNs, even in patients with marker-secreting tumors, but this may not necessarily require frequent ionizing radiation-based imaging. For those patients with negative tumor markers at diagnosis, such as patients with seminoma/dysgerminoma or embryonal carcinoma, surveillance with serial imaging will still be indispensable. On the basis of this retrospective review, we propose to evaluate in a prospective clinical trial the value added of frequent surveillance imaging in children, adolescents, and young adults with marker-positive versus marker-negative MGCTs.

AFFILIATIONS

¹The Hospital for Sick Children, University of Toronto, Toronto, Ontario, Canada

²Children's Oncology Group, Monrovia, CA

³University of Southern California, Los Angeles, CA

⁴Emory University, Atlanta, GA

⁵Yale University School of Medicine, New Haven, CT

⁶University of California Davis Comprehensive Cancer Center, Sacramento, CA

⁷University of Texas Southwestern Medical Center and Children's Medical Center Dallas, Dallas, TX

⁸Riley Hospital for Children, Indianapolis, IN

⁹St Jude Children's Research Hospital, Memphis, TN

¹⁰Dana-Farber Cancer Institute and Harvard Medical School, Boston, MA

CORRESPONDING AUTHOR

Adriana Fonseca, MD, Division of Haematology Oncology, University of Toronto, The Hospital for Sick Children, 555 University Ave, Toronto, Ontario, Canada, M5G 1X8; Twitter: @qzaradri; e-mail: adriana.fonseca@sickkids.ca.

AUTHORS' DISCLOSURES OF POTENTIAL CONFLICTS OF INTEREST AND DATA AVAILABILITY STATEMENT

Disclosures provided by the authors and data availability statement (if applicable) are available with this article at DOI <https://doi.org/10.1200/JCO.18.00790>.

AUTHOR CONTRIBUTIONS

Conception and design: Adriana Fonseca, Armando J. Lorenzo, Thomas A. Olson, Marcio H. Malogolowkin, James F. Amatruda, Carlos Rodriguez-Galindo, A. Lindsay Frazier, Furqan Shaikh

Administrative support: Thomas A. Olson

Provision of study materials or patients: Thomas A. Olson, Marcio H. Malogolowkin

Collection and assembly of data: Adriana Fonseca, Mark Krailo, Marcio H. Malogolowkin, Deborah F. Billmire, Furqan Shaikh

Data analysis and interpretation: Adriana Fonseca, Caihong Xia, Armando J. Lorenzo, Mark Krailo, Farzana Pashankar, Marcio H. Malogolowkin, James F. Amatruda, Deborah F. Billmire, Furqan Shaikh

Manuscript writing: All authors

Final approval of manuscript: All authors

Accountable for all aspects of the work: All authors

REFERENCES

1. Murphy BA, Motzer RJ, Mazumdar M, et al: Serum tumor marker decline is an early predictor of treatment outcome in germ cell tumor patients treated with cisplatin and ifosfamide salvage chemotherapy. *Cancer* 73:2520-2526, 1994
2. Mazumdar M, Bajorin DF, Bacik J, et al: Predicting outcome to chemotherapy in patients with germ cell tumors: The value of the rate of decline of human chorionic gonadotrophin and alpha-fetoprotein during therapy. *J Clin Oncol* 19:2534-2541, 2001
3. Fizazi K, Pagliaro L, Laplanche A, et al: Personalised chemotherapy based on tumour marker decline in poor prognosis germ-cell tumours (GETUG 13): A phase 3, multicentre, randomised trial. *Lancet Oncol* 15:1442-1450, 2014
4. Fizazi K, Culine S, Kramar A, et al: Early predicted time to normalization of tumor markers predicts outcome in poor-prognosis nonseminomatous germ cell tumors. *J Clin Oncol* 22:3868-3876, 2004
5. Mosbech CH, Svingen T, Nielsen JE, et al: Expression pattern of clinically relevant markers in paediatric germ cell- and sex-cord stromal tumours is similar to adult testicular tumours. *Virchows Archiv* 465:567-577, 2014
6. Lam D, Wootton-Gorges SL, McGahan JP, et al: Abdominal pediatric cancer surveillance using serial computed tomography: Evaluation of organ absorbed dose and effective dose. *Semin Oncol* 38:128-135, 2011
7. Kost SD, Fraser ND, Carver DE, et al: Patient-specific dose calculations for pediatric CT of the chest, abdomen and pelvis. *Pediatr Radiol* 45:1771-1780, 2015
8. Ahmed BA, Connolly BL, Shroff P, et al: Cumulative effective doses from radiologic procedures for pediatric oncology patients. *Pediatrics* 126:e851-e858, 2010
9. Voss SD, Reaman GH, Kaste SC, et al: The ALARA concept in pediatric oncology. *Pediatr Radiol* 39:1142-1146, 2009
10. Smith-Bindman R, Lipson J, Marcus R, et al: Radiation dose associated with common computed tomography examinations and the associated lifetime attributable risk of cancer. *Arch Intern Med* 169:2078-2086, 2009
11. Miglioretti DL, Johnson E, Williams A, et al: The use of computed tomography in pediatrics and the associated radiation exposure and estimated cancer risk. *JAMA Pediatr* 167:700-707, 2013
12. Kanal E, Tweedle MF: Residual or retained gadolinium: Practical implications for radiologists and our patients. *Radiology* 275:630-634, 2015
13. Rappaport BA, Suresh S, Hertz S, et al: Anesthetic neurotoxicity—clinical implications of animal models. *N Engl J Med* 372:796-797, 2015
14. Frazier AL, Hale JP, Rodriguez-Galindo C, et al: Revised risk classification for pediatric extracranial germ cell tumors based on 25 years of clinical trial data from the United Kingdom and United States. *J Clin Oncol* 33:195-201, 2015
15. Rogers PC, Olson TA, Cullen JW, et al: Treatment of children and adolescents with stage II testicular and stages I and II ovarian malignant germ cell tumors: A Pediatric Intergroup Study—Pediatric Oncology Group 9048 and Children's Cancer Group 8891. *J Clin Oncol* 22:3563-3569, 2004
16. Rescorla FJ, Ross JH, Billmire DF, et al: Surveillance after initial surgery for stage I pediatric and adolescent boys with malignant testicular germ cell tumors: Report from the Children's Oncology Group. *J Pediatr Surg* 50:1000-1003, 2015
17. Billmire DF, Cullen JW, Rescorla FJ, et al: Surveillance after initial surgery for pediatric and adolescent girls with stage I ovarian germ cell tumors: Report from the Children's Oncology Group. *J Clin Oncol* 32:465-470, 2014
18. Shaikh F, Cullen JW, Olson TA, et al: Reduced and compressed cisplatin-based chemotherapy in children and adolescents with intermediate-risk extracranial malignant germ cell tumors: A report from the Children's Oncology Group. *J Clin Oncol* 35:1203-1210, 2017
19. Kalbfleisch JD, Prentice RL: *The Statistical Analysis of Failure Time Data*. New York, NY, John Wiley and Sons, 2002
20. Schemper M, Smith TL: A note on quantifying follow-up in studies of failure time. *Control Clin Trials* 17:343-346, 1996
21. Owens C, Li BK, Thomas KE, et al: Surveillance imaging and radiation exposure in the detection of relapsed neuroblastoma. *Pediatr Blood Cancer* 63:1786-1793, 2016
22. Federico SM, Brady SL, Pappo A, et al: The role of chest computed tomography (CT) as a surveillance tool in children with high-risk neuroblastoma. *Pediatr Blood Cancer* 62:976-981, 2015
23. Kaste SC, Brady SL, Yee B, et al: Is routine pelvic surveillance imaging necessary in patients with Wilms tumor? *Cancer* 119:182-188, 2013
24. Voss SD: Surveillance imaging in pediatric Hodgkin lymphoma. *Curr Hematol Malig Rep* 8:218-225, 2013



AUTHORS' DISCLOSURES OF POTENTIAL CONFLICTS OF INTEREST

Detection of Relapse by Tumor Markers Versus Imaging in Children and Adolescents With Nongerminomatous Malignant Germ Cell Tumors: A Report From the Children's Oncology Group

The following represents disclosure information provided by authors of this manuscript. All relationships are considered compensated. Relationships are self-held unless noted. I = Immediate Family Member, Inst = My Institution. Relationships may not relate to the subject matter of this manuscript. For more information about ASCO's conflict of interest policy, please refer to www.asco.org/rwc or ascopubs.org/jco/site/ifc.

Mark Krailo

Consulting or Advisory Role: Merck Sharp & Dohme

Travel, Accommodations, Expenses: Merck Sharp & Dohme

Carlos Rodriguez-Galindo

Honoraria: Novimmune

A. Lindsay Frazier

Consulting or Advisory Role: Decibel Therapeutics

No other potential conflicts of interest were reported.