

UC Davis

UC Davis Previously Published Works

Title

Spinal epidural empyema in seven dogs

Permalink

<https://escholarship.org/uc/item/0z88s3qz>

Journal

Veterinary Surgery, 35(2)

ISSN

0161-3499

Authors

Lavelly, J A
Vernau, karen M
Vernau, W
et al.

Publication Date

2006-02-01

Peer reviewed

Spinal Epidural Empyema in Seven Dogs

JAMES A. LAVELY, DVM, Diplomate ACVIM (Neurology), KAREN M. VERNAU, DVM, Diplomate ACVIM (Neurology),
WILLIAM VERNAU, BVMS, DVSc, PhD, Diplomate ACVP, ERIC J. HERRGESELL, DVM, Diplomate ACVR,
and RICHARD A. LECOUTEUR, BVSc, PhD, Diplomate ACVIM (Neurology)

Objective—To characterize the clinical signs, diagnostic and surgical findings, and outcome in dogs with spinal epidural empyema (SEE).

Study Design—Retrospective study.

Animals—Seven dogs.

Methods—Dogs with SEE between 1992 and 2001 were identified from a computerized medical record system. Inclusion criteria were: neurologic examination, vertebral column radiographs, myelography, antimicrobial culture and susceptibility of material collected surgically from the vertebral canal, a definitive diagnosis of SEE confirmed by surgery, and microscopic examination of tissue from the vertebral canal.

Results—Common signs were lethargy, fever, anorexia, apparent spinal pain, and paraparesis/plegia. Common laboratory abnormalities were peripheral neutrophilia, and neutrophilic pleocytosis in cerebrospinal fluid (CSF). Three dogs had concurrent discospondylitis and 1 of these had vertebral luxation. On myelography, extradural spinal cord compression was focal (2 dogs), multifocal (3), or diffuse (2). Bacteria were isolated not from CSF but from blood, surgical site, pleural fluid, or urine in 6 dogs. Dogs were administered antibiotics and had surgical decompression by hemilaminectomy. Five dogs improved neurologically and had a good long-term outcome. Two dogs were euthanized, 1 because of worsening of neurologic signs and pneumonia, and the other because of herniation of a cervical intervertebral disc 1 month postoperatively, unrelated to the SEE.

Conclusion—Dogs with SEE may have a good outcome when treated by surgical decompression and antibiotic administration.

Clinical Relevance—SEE should be included in a list of possible causes for dogs with fever, apparent spinal pain, and myelopathy.

© Copyright 2006 by The American College of Veterinary Surgeons

INTRODUCTION

SPINAL EPIDURAL EMPYEMA (SEE), also referred to as spinal epidural abscess, is a suppurative, septic process within the epidural space of the vertebral canal. Infection results from either the hematogenous spread of bacteria, or by direct local extension.^{1–6} Purulent, septic material accumulates within the epidural space resulting in apparent spinal pain and fever. Severe signs of neurologic dysfunction such as paresis, plegia,

and incontinence develop as the disease progresses and spinal cord compression increases.^{2,6} When accompanied by severe neurologic signs, SEE in humans is considered a neurosurgical emergency. SEE is rare in dogs and humans, and is associated with substantial morbidity and mortality. Before the 1930s, SEE in humans was largely a necropsy diagnosis; 81% of affected persons died. Since then, rapid and improved diagnostics, surgical intervention, and use of broad spectrum antibiotics have reduced mortality to about 15%.^{6,7} SEE often is not included in

From the Departments of Surgical and Radiological Sciences, and Pathology, Microbiology, and Immunology, School of Veterinary Medicine, University of California, Davis, CA.

Presented at the 20th Annual American College of Veterinary Internal Medicine Forum, Dallas Texas, May 29–June 1 2002.

Dr. Lavelly's current address is The Animal Care Center 6620 Redwood Dr., Rohnert Park, CA 94928-3000

Address reprint requests to Karen M. Vernau, DVM, Diplomate ACVIM (Neurology), Department of Surgical and Radiological Sciences, School of Veterinary Medicine, University of California, Davis, CA 95616. E-mail: kmvernau@ucdavis.edu.

Submitted December 2004; Accepted March 2005

© Copyright 2006 by The American College of Veterinary Surgeons
0161-3499/04

doi:10.1111/j.1532-950X.2006.00129.x

an initial list of possible causes of spinal cord dysfunction in people or dogs.^{1,6} Delay in diagnosis permits progression of clinical signs, and is associated with a worse outcome, despite appropriate therapy.^{1,2,5,6,8}

To our knowledge, of the 10 dogs with SEE that have been reported^{2,5,9-13}; only 5 dogs survived.^{5,10,12} Our purpose was to characterize the clinical signs, diagnostic and surgical findings, and long-term outcome of 7 dogs with SEE.

MATERIALS AND METHODS

Dogs with SEE, between 1992 and 2001, were identified retrospectively by a computerized medical record search. Inclusion criteria were: neurologic examination; spinal radiographs; myelography; and a definitive diagnosis of SEE by surgery and histopathology or necropsy. Nine dogs fulfilled the inclusion criteria; however 2 dogs previously reported² were excluded from this study.

Surgical Management

In 7 dogs the spinal cord was approached by hemilaminectomy, and 1 dog also had a dorsal laminectomy. Two dogs had affected vertebrae stabilized using pins and polymethylmethacrylate. Liquid purulent material, when identified in the vertebral canal, was collected and submitted for microbial culture. The purulent material was then removed by gentle suction and lavage. When there was abnormal epidural tissue in the vertebral canal, as much as possible, this material was removed, usually in a piecemeal fashion, until the spinal cord was decompressed. This material was collected for microbial culture and susceptibility testing, histopathology, and in some cases, cytology. An autologous fat graft was placed over the laminectomy defect; wound closure was in 4 layers.

RESULTS

History and Clinical Signs (Table 1)

On admission, the most common clinical signs were apparent spinal pain (7 dogs), acute paraparesis or paraplegia (5), lethargy (3), and anorexia (3). Before admission, 4 dogs (1-3, 7) were administered antibiotics for 2 weeks-4 months, and 4 dogs (1, 3, 6, 7) were administered glucocorticoids. Four of 5 dogs were febrile (102.6-104.0°F); 1 dog not febrile on admission had an elevated temperature (105.0°F) the previous week. All dogs had neurologic deficits and apparent spinal pain.

Hematologic Results (Table 2)

Six dogs that had a CBC had leukocytosis, and 5 dogs (2-6) had a neutrophilia; dog 3 had a left shift. Neutrophils were slightly toxic in dogs 3 and 5.

Urinalysis (Table 2)

Three dogs (4-6) had 2+ proteinuria and dog 6 had pyuria. Urine protein:creatinine ratio (UPC) was within the normal reference interval (<1) for dogs 4 (0.6) and 6 (0.51), whereas UPC in dog 3 was 4.48 (proteinuria was not noted).

Cerebrospinal Fluid (CSF) Analysis (Table 2)

CSF was abnormal in 4 of 5 dogs (1-3, 5, 6), but bacteria were not observed. CSF was collected from lumbar and cisternal sites in dogs 1 and 5, from the lumbar site in dogs 2 and 6, and from the cisterna magna in dog 3. Mean cisternal CSF protein concentration was 37.3 mg/dL (range, 31-44 mg/dL; reference value, <25 mg/dL); mean total nucleated cell count (TNCC) was 15.3/μL (range, 5-30/μL; reference value, <3 nucleated cells/μL). Mean lumbar CSF protein concentration was 212.5 mg/dL (range, 10-726 mg/dL; reference value, <35 mg/dL); mean TNCC was 145.7/μL (range, 40-342/μL; reference value, ≤ 3 cells/μL). On cytology, except in dog 6, all CSF had a neutrophilic pleocytosis.

Diagnostic Imaging (Table 3)

Dog 5 had mild, diffuse bronchointerstitial pulmonary changes compatible with chronic lower airway disease; no abnormalities were detected on lateral and dorsoventral thoracic radiographs of all other dogs. On abdominal ultrasonography of dog 3, a soft tissue, sublumbar mass, with complex echotexture was identified. The mass had both anechoic and hyperechoic regions, that were interpreted as consistent with a sublumbar abscess and possible foreign body. A small renal cyst of unknown significance was observed in dog 5. Abdominal ultrasound findings were within normal limits in dogs 1 and 6.

Three dogs (4, 6, 7) had discospondylitis. On lumbar myelography, with contrast filling to the level of the first cervical vertebra (C1), extradural spinal cord compression was noted in all dogs. Compressive lesions were focal (dogs 3, 7), multifocal (1, 5, 6), or diffuse (2, 4); 4 dogs (1-3, 7) had compression of the lumbar spinal cord (Fig 1), and dogs 4-6 of the thoracic spinal cord. Dog 7 had discospondylitis, vertebral luxation, and extradural spinal cord compression (Fig 2). Four dogs (1-3, 7) had compressive spinal cord lesions at lumbar vertebrae 2 and 3 (L2-3). Computed tomography (CT) images of the lumbar spine in dog 1 after myelography revealed left sided, extradural compression at L3 and L6; however vertebral lysis was not apparent.

Table 1. Signalment, History and Clinical Signs in 7 Dogs with Spinal Epidural Empyema

Dog	Signalment	History	Previous Treatment	Clinical Signs	Neuroanatomic Localization
1	7-month-old, F, Labrador Retriever	2 weeks lethargy, back pain, and restlessness	Dex 15 mg Cephalexin 14 days Aspirin 14 days	T—104.0 F Ambulatory paraparetic, lumbar and cervical pain	T3–L3 myelopathy ± multifocal
2	3-year-old FS, Great Dane	5 months intermittent lethargy, 4 months back pain, acute paraparesis	Amoxicillin 7–14 days Clavamox [®] 7 days × 2 courses Enrofloxacin 10 days	T—102.8 F Non-ambulatory paraparetic, pain T–L palpation	T3–S3 myelopathy
3	6-year-old, MC, Australian Cattle Dog	1-month intermittent anorexia, lethargy, cough, pneumonia, fever (105 F), acute paraparesis	Clavamox [®] 7 days Famotidine, sucralfate Carprofen Enrofloxacin MPSS	T—101.8 F Paraplegia with superficial pain perception present, lumbar pain	T3–L3 myelopathy
4	11-year-old, MC, Rhodesian Ridgeback	Anorexia 3 days, apparent pain 2 days, acutely non-ambulatory	None	T—not reported Non-ambulatory paraplegic, pain apparent on palpation near T12	T3–L3 myelopathy
5	13-year-old, F, Mixed-Breed Dog	Seasonal allergies, dental disease, dyspnea, pacing 1 day, anorexia 1 day, acutely non-ambulatory paraparetic	None	T—103.9 F IV/VI cardiac murmur, non-ambulatory paraparetic, severe apparent spinal pain on T–L palpation	T3–L3 myelopathy
6	7-year-old, FS, Bernese Mountain Dog	6 months of progressive gait abnormality and difficulty rising, elbow dysplasia Lt and Rt, leukocytosis	Carprofen 8 weeks Prednisone 7 days	T—102.6 F ambulatory tetraparetic, pain cervico-thoracic, pelvic limbs more paretic than thoracic limbs	C1–C5 myelopathy ± T3–L3 myelopathy
7	8-year-old, FS, Labrador Retriever	Anal gland impaction 1 month prior	Unknown antibiotic × 30 days Prednisone 21 days	T—not recorded Acute non-ambulatory paraplegia, apparent spinal pain, Schiff-Sherrington posture	T3–L3 myelopathy

F, female; FS, female spayed; MC, male castrate; T, rectal temperature; Clavamox[®] (Pfizer Inc., New York, NY), amoxicillin/clavulanic acid; MPSS, methylprednisolone sodium succinate; Dex, dexamethasone; Lt, left; Rt, right; C, cervical; T, thoracic; L, lumbar.

Surgical Procedures (Table 3)

During hemilaminectomy, dogs were administered cefazolin intravenously (22–25 mg/kg). Dorsal laminectomy was also performed, at L6–7 in dog 1, and multiple hemilaminectomies were completed in dogs 1, 4, and 5. In dogs 6 and 7, vertebrae were stabilized by Steinman pins and polymethylmethacrylate cement. Purulent material was noted around the spinal cord in 3 dogs (2–4); in 2 dogs (2, 3) purulent material was seen between the articular processes and/or within the paraspinal musculature. In 4 dogs (1, 3, 6, 7) reddish, friable tissue surrounded the dura mater; in dog 5 the epidural fat appeared hemorrhagic and gelatinous. In dog 3, exploratory celiotomy after hemilaminectomy was used to drain a retroperitoneal abscess. There were petechiae in the peritoneum at the attachment between the left diaphragmatic crus and the lumbar spine. A tract containing purulent material similar to that observed during hemilaminectomy was

identified; however, a foreign body (e.g., grass awn) was not identified.

Cytology

Purulent inflammation was observed in cytologic specimens collected at surgery in dogs 3, 4, and 5. Pyogranulomatous inflammation was observed in dog 1. In dogs 3 and 5, low numbers of rods were noted, whereas in dogs 1 and 4 organisms were not identified.

Histopathology (Table 4)

Inflammation was identified in tissue collected from the vertebral canal during surgery in all dogs. Suppurative steatitis was observed in dogs 3–6. Fibrinopurulent meningitis was diagnosed in dog 2, and pyogranulomatous tissue was noted around the spinal

Table 2. Laboratory Test Results of 7 Dogs with Spinal Epidural Emyema

Dog	CBC, Chemistry, Urinalysis	CSF:Cisternal (C); Lumbar (L)	Cytology	Culture
1	WBC 17,200/ μ L Stress leukogram; chemistry and UA wnl	C: protein 44 mg/dL, TNCC 11/ μ L, RBC < 1/ μ L 72% N, 6% lymph, 22% M L: protein 726 mg/dL, TNCC 200/ μ L, RBC 43/ μ L, 71% N, 22% lymph, 7% M, lymphoid reactivity on cytology L: protein 75 mg/dL, TNCC 40/ μ L, RBC 240/ μ L, 62% N, 11% lymph, 27% M	Epidural tissue impression smear: pyogranulomatous inflammation	Granulation tissue: <i>Klebsiella pneumoniae</i> , <i>Pasteurella hemolytica</i> CSF and epidural fluid: no growth Epidural fluid: <i>Hemolytic E. Coli</i> , <i>Bacteroides</i> spp./ <i>Prevotella</i> spp. Pleural fluid: <i>Hemolytic E. coli</i>
2	WBC 28,515/ μ L with mature neutrophilia 22,527/ μ L, anemia, HCT 28.4%, Ca 8.0 mg/dL, albumin 1.4 g/dL, CK 7370 IU/L, AST 394 IU/L, no urine collected	C: protein 31 mg/dL, TNCC 5/ μ L, RBC 8/ μ L, 34% N, 3% lymph, 63% M	Pleural fluid: SG—1.0147, TP—2.9 g/dL, TNCC—34,000/ μ L	CSF, blood, urine, abdominal mass, epidural tissue: no growth Paraspinal fluid: <i>Bacteroides</i> spp./ <i>Prevotella</i> spp.
3	WBC 56,400/ μ L, neutrophilia 35,532/ μ L, 6204/ μ L bands, slight toxicity, monocytosis 13,536/ μ L, platelets 107,000/ μ L, albumin 2.0 g/dL, Ca 8.9 mg/dL, ALP 438 IU/L, ALT 435 IU/L, AST 698 IU/L, urine SG 1.020, UPC 4.48	C: protein 37 mg/dL, TNCC 30/ μ L, RBC 30/ μ L 70% N, 1% lymph, 29% M L: Protein 40 mg/dL, TNCC 342/ μ L, RBC 40,800/ μ L 98% N, 1% lymph, 1% M L: protein 10 mg/dL, TNCC < 1/ μ L, RBC < 1/ μ L, 73% lymph, 27% M	Paraspinal purulent fluid: small number of rods, degenerate neutrophils, severe septic purulent inflammation	CSF, blood, urine, abdominal mass, epidural tissue: no growth Paraspinal fluid: <i>Bacteroides</i> spp./ <i>Prevotella</i> spp.
4	WBC 24,800/ μ L, neutrophilia 22,320/ μ L, lymphopenia 496/ μ L, monocytosis 1736/ μ L, anemia, HCT 27.0%, ALP 284 IU/L, ALT 93 IU/L, AST 354 IU/L, albumin 1.9 g/dL, UA: SG 1.021, 2 + protein, UPC 0.6	CSF not collected	Epidural fluid Direct smear: moderate numbers of neutrophils	Blood: <i>Streptococcus canis</i> Urine and epidural fluid: no growth
5	WBC 19,900/ μ L, neutrophilia 18,308/ μ L, bands 199/ μ L, slightly toxic N, reticulocytosis 94,080/ μ L, HCT 40.3%, ALP 264 IU/L, ALT 109 IU/L, AST 281 IU/L, 2 + proteinuria	C: protein 37 mg/dL, TNCC 30/ μ L, RBC 30/ μ L 70% N, 1% lymph, 29% M L: Protein 40 mg/dL, TNCC 342/ μ L, RBC 40,800/ μ L 98% N, 1% lymph, 1% M L: protein 10 mg/dL, TNCC < 1/ μ L, RBC < 1/ μ L, 73% lymph, 27% M	T9-10 epidural mass: septic purulent inflammation and small numbers of rods	CSF: no growth
6	WBC 38,000/ μ L, neutrophilia 29,640/ μ L, monocytosis 4940/ μ L, anemia, HCT 31.5%, 8100 reticulocytes/ μ L, albumin 2.2 g/dL, globulin 4.7 g/dL, urine SG 1.012, 2 + protein, UPC 0.51	CSF not collected	Not done	Epidural tissue, epidural fat: no growth Blood: <i>Staphylococcus intermedius</i> Urine: <i>E. coli</i> Blood: <i>Staphylococcus intermedius</i>
7	UA, PCV/TS/BG and electrolytes wnl	CSF not collected	Not done	Blood: <i>Staphylococcus intermedius</i> Urine: <i>E. coli</i> Blood: <i>Staphylococcus intermedius</i>

WBC, white blood cell count; TNCC, total nucleated cell count; N, neutrophils, lymph, lymphocytes; M, macrophages; HCT, hematocrit; SG, specific gravity; RBC, red blood cell count; TP, total protein; PCV, packed cell volume; BG, blood glucose; UPC, urine protein/creatinine ratio; wnl, within normal limits.

Reference intervals: WBC (6000–17,000/ μ L), neutrophils (3000–11,500/ μ L), lymphocytes (1000–4800/ μ L), monocytes (150–1350/ μ L), HCT (37–55%), Ca (9.9–11.4 mg/dL), albumin (2.9–4.2 g/dL), ALP (15–127 IU/L), ALT (19–70 IU/L), AST (15–43 IU/L), UPC < 1. CSF, TNCC \leq 3/ μ L, protein (cisternal) < 25 mg/dL, (lumbar) < 35 mg/dL.

Table 3. Imaging and Surgical Findings in 7 Dogs

Dog	Plain Radiographs	Advanced Imaging	Surgical Findings
1	Initial: no osseous lesions 2 and 4 months post-operation: osteomyelitis L2–5 Infarction of: Lt ilial wing, Lt femur, Rt femur, Lt tibia, Rt ulna	Myelogram and CT: dorsolateral extradural lesion L3 and L6	Hemilaminectomy L2–3: large amount red friable tissue surrounded spinal cord Dorsal laminectomy L6–7: similar tissue covered conus medullaris and nerve roots. Small amount purulent material at cranial edge L6
2	Vertebral column: no significant abnormalities	Myelogram #1: lateral: dorsal contrast column displaced ventrally T2–12, thinned ventral column T10–L1 VD: bilateral column narrowing at L2 Myelogram #2 days post-op: similar in thoracic region—new focal extradural lesion at T4–5 and at conus medullaris	Hemilaminectomy L2–3: large amount of inspissated pus and purulent material oozing from vertebral canal
3	Vertebral column: no significant findings Soft tissue density in retroperitoneal space	Myelogram: Lt sided lesion L2–3 and thinning of lumbar contrast columns Abdominal U/S: sublumbar mass	Hemilaminectomy L2–3: purulent material ventral to T–L vertebral bodies, reddish granulation tissue around spinal cord Laparotomy: focal peritoneal petechiation at Lt crus diaphragmatic attachment to lumbar spine, retroperitoneal abscess—no foreign body noted
4	Vertebral column: discospondylitis T8–T11	Myelogram: diffuse extradural spinal cord lesion T10–13	Hemilaminectomy T9–L1: purulent material in vertebral canal
5	Vertebral column: no lytic lesions Thoracic radiographs: chronic airway disease	Myelogram: Lt sided extradural lesion at T9–10 and T12–13 Abdominal U/S: small renal cyst	Hemilaminectomies T9–10 and T12–13: hemorrhagic- gelatinous material mixed with epidural fat surrounded the spinal cord at each site
6	Vertebral column: discospondylitis T5–6, T9–11 Thoracic rads: sternal osteomyelitis Stifle DJD Rt > Lt	Myelogram: multifocal extradural lesion at T5–6 and T10–11, chronic ventral extradural lesion C6–7	Hemilaminectomy T10–11: thick yellow brown fibrous material covered spinal cord, luxation T10–11
7	Vertebral column: L2–3 luxation, discospondylitis L2–3	Myelogram: Rt extradural lesion L2–3	Hemilaminectomy L2–3: yellow brown fibrous material around spinal cord, L2–3 luxation

Lt, left; Rt, right; C, cervical; T, thoracic; L, lumbar; DJD, degenerative joint disease; CT, computed tomography; VD, ventrodorsal; PMMA, polymethylmethacrylate; U/S, ultrasound.

cord and articular processes of dog 7. Osteomyelitis was observed in dogs 1 and 6.

Microbial Culture and Serology (Table 4)

Bacteria were isolated from purulent material collected at surgery in 2 of 4 dogs (2, 3), and from granulation tissue around the spinal cord collected from 1 of 3 dogs (dog 1). A positive blood culture was obtained in 3 of 4 dogs (4, 6, 7). CSF culture was negative in 3 of 3 dogs. Urine culture was positive in 1 of 3 dogs (dog 6). Dog 2 developed pleural effusion 2 days after surgery; hemolytic *Escherichia coli* was isolated. Serology for *Brucella* spp. was negative in dog 4.

Thus 6 dogs had bacteria isolated. Hemolytic *E. coli* was cultured from 2 sites (epidural and pleural fluid) in dog 2 and from urine in dog 6. *Bacteroides* spp./*Prevotella* spp. was also isolated from epidural fluid in dog 2 and from a paraspinous abscess in dog 3. *Klebsiella pneumoniae* and *Pasteurella hemolytica* were isolated from epidural granulation tissue in dog 1 and *Streptococcus*

canis from blood in dog 4. *Staphylococcus intermedius* was isolated from blood in dogs 6 and 7.

Outcome (Table 4)

All dogs were administered broad-spectrum antibiotics for variable periods after surgery. Five dogs had a positive outcome because their neurologic status improved, and they were alive at follow-up examination ≥ 2 months after surgery. Four of 5 dogs that were non-ambulatory on admission became fully ambulatory; 2 were mildly paraparetic (3, 4), and 2 were neurologically normal (5, 7). Dog 6 was ambulatory after surgery and improved in the following weeks but at 1 month became non-ambulatory tetraparetic with a C1–5 myelopathy. Results of a myelogram completed at this time were consistent with acute disc herniation at C5–6 and the dog was euthanized at the owner's request.

Dog 1 was ambulatory with paraparesis on admission. The owners reported that the dog had improved a lot after surgery, but was reluctant to jump. On neurologic examination there was delayed conscious proprioception

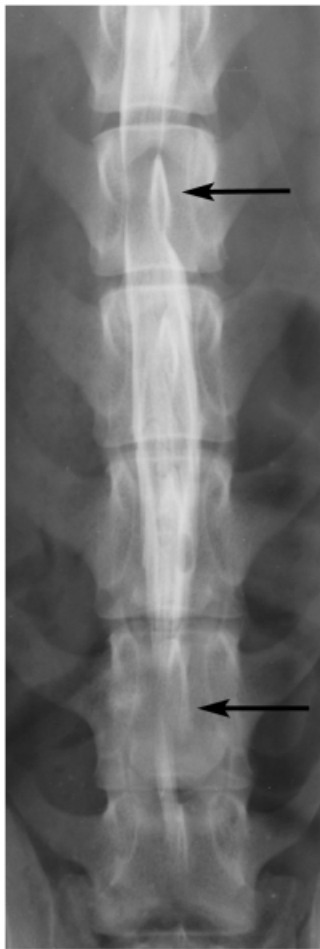

Fig 1. Ventrordorsal myelogram of dog 1. Note the left-sided extradural lesions over the L3 and L6 vertebral bodies (arrows).

(CP) in the pelvic limbs. Repeat spinal radiographs at 2 months demonstrated lytic changes on the articular processes of L2–5 consistent with osteomyelitis. No evidence of osteomyelitis was seen on the original survey vertebral radiographs or CT images. On re-examination at 4 months, the CP deficits had resolved, but a shifting leg lameness was observed. Repeat spinal radiographs, CT scan, and radiographs of the pelvic and right thoracic limbs were done. Evidence of L2–5 osteomyelitis was still evident and there was increased radiopacity in the left ilial wing, proximal aspect of the left femur, distal aspect of the right femur, and mottling of the proximal aspect of the left tibia. Radiographic changes were consistent with septic embolization. Bone biopsies from each site had a combination of hemorrhage, bone resorption, fibrosis, and lymphoplasmacytic inflammation. These findings were most consistent with infarction; microbial cultures of the biopsy sites were negative for bacteria and fungi. Blood cultures and *Coccidioides immitis* antibody titer also were negative. Antibiotics were administered for 8

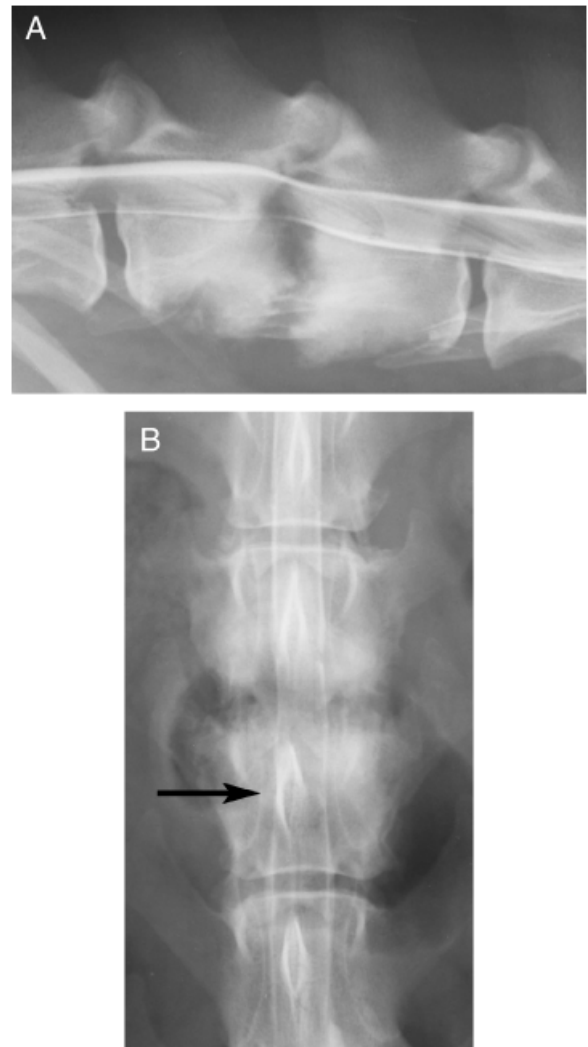


Fig 2. (A) Lateral myelogram of dog 7. Dorsal extrudal spinal cord lesion at L2–3 because of spinal luxation. Note the discospondylitis. (B) Ventrordorsal myelogram. Note the right-sided extradural lesion at L2–3 extending over the body of L3 (arrow).

months post-operatively, and 3.5 years after surgery the dog is reportedly normal.

Approximately 5 months after surgery, dog 5 was diagnosed with pituitary dependent hyperadrenocorticism that the owner elected not to treat. Neurologic examination at 27 months was normal except for mild discomfort, apparent on spinal palpation. At 29 months, this dog was euthanized for non-neurologic reasons, and necropsy was not permitted.

Dog 2 had a poor outcome. Neurologic deterioration and pleural effusion occurred during the first 2 days after surgery. Repeat myelography demonstrated additional sites of extradural spinal cord compression in the thoracic region and cauda equina. Because of the poor prognosis,

Table 4. Diagnosis, Treatment and Outcome of 7 Dogs

Dog	Pathologic Diagnosis	Treatment	Outcome
1	Severe, focally extensive, chronic pyogranulomatous osteomyelitis with extension to surrounding soft tissues	Hemilaminectomy L2-3 Dorsal laminectomy L6-7 Ampicillin 20 mg/kg PO t.i.d. Chloramphenicol 20 mg/kg PO t.i.d. Metronidazole 10 mg/kg PO b.i.d. × 2 weeks Carprofen 2 mg/kg PO b.i.d.	4 months post-operatively: neurologically normal Radiographic osteomyelitis shifting limb lameness Multifocal bone infarction; owner reports normal 3.5 years post-operatively
2	Marked fibrinopurulent meningitis Necropsy: diffuse pyogranulomatous epidural meningitis with multifocal axonal degeneration (spinal cord C6-Cd), epidural abscess T11, leukomalacia L5, pyogranulomatous pleuritis and pneumonia	Hemilaminectomy L2-3 Enrofloxacin 10 mg/kg IV b.i.d. Ampicillin 25 mg/kg IV t.i.d. Metronidazole 10 mg/kg IV b.i.d.	Deterioration 2 days post-operatively; repeat myelogram: diffuse spinal cord compression Euthanasia and necropsy
3	Epidural fat: multifocal to coalescing, suppurative steatitis	Lt hemilaminectomy L2-3 Enrofloxacin 5 mg/kg PO b.i.d. Clavamox [®] 21 mg/kg PO b.i.d.	6 months post-operatively: ambulatory, mild paraparesis
4	Acute severe suppurative steatitis	Hemilaminectomy T9-L1 Cephalexin 22 mg/kg PO b.i.d. × 3 months Metronidazole 7.5 mg/kg t.i.d. × 1 month	2 months post-operatively: ambulatory, paraparesis, resolving discospondylitis
5	Extradural tissue: severe, suppurative steatitis/cellulitis	Hemilaminectomies T9-10, T12-13 Enrofloxacin 6 mg/kg PO b.i.d. Clavamox 22 mg/kg PO t.i.d. Metronidazole 11 mg/kg PO t.i.d.	1 year post-operatively: ambulatory, mild paraparesis, pituitary-dependent hyperadrenocortism, chronic airway disease mitral regurgitation (mild)
6	Granuloma, epidural steatitis, meningitis, osteomyelitis	Lt hemilaminectomy T10-11 with stabilization via pins and PMMA Cephalexin 22 mg/kg PO t.i.d. Carprofen 2.2 mg/kg PO b.i.d.	Euthanated 1 month post-operatively because of an acute C5-6 disc herniation
7	Granulation tissue, neutrophilic inflammation, discospondylitis	Rt hemilaminectomy L2-3 with stabilization via pins and PMMA Cephalexin 27 mg/kg PO t.i.d. Metronidazole 9 mg/kg PO t.i.d. Phenoxbenzamine 10 mg PO t.i.d.	Clinical and radiographic resolution 4 months post-operatively; owners report normal 9 years post-operatively until euthanated for unrelated problem; no necropsy

Rt, right; Lt, left; PMMA, polymethylmethacrylate; PO, orally; b.i.d., twice daily; t.i.d., three times daily.

the dog was euthanated. Epidural empyema at T11, diffuse pyogranulomatous meningitis with multifocal axonal degeneration spanning from C6 to the cauda equina, pyogranulomatous pleuritis, and a suppurative bronchopneumonia were found at necropsy.

In dogs 3 and 5, duration of antibiotic therapy was based on serial CSF examinations (Table 5). In both dogs, TNCC and percentage of neutrophils decreased markedly with time and antibiotic therapy; however total protein concentration varied over time. (Table 5)

DISCUSSION

Treatment of SEE in humans remains controversial. In dogs and humans, most authors advocate surgical decompression and drainage in combination with antibiotics,^{1,2,6,8,9,14} although medical management alone has reportedly been successful in humans.^{15,16} Guidelines for medical management alone in humans are: patients who are poor anesthetic/surgical candidates;

patients whose lesion extends a considerable length of the vertebral canal; patients without substantial neurologic deficits; and patients who have been paraplegic for >72 hours.^{3,8} These guidelines should be assessed with caution as neurologic status may decompensate rapidly.^{1,2,5}

Experimental studies inducing SEE in a rabbit model support a compressive rather than an ischemic cause for neurologic damage.¹⁷ With progression of SEE, venous compromise occurs. In humans, prognosis worsens with severe neurologic dysfunction at diagnosis.^{1,6,8} Early diagnosis and surgical intervention appear to be critical in limiting spinal cord damage¹⁷ and improving prognosis.^{1,2,6,8}

Signalment and Clinical Signs

In the 7 dogs with SEE described here, breed predilection, gender or age predominance were not apparent. The most common clinical signs at admission were apparent spinal pain, lethargy, and anorexia, which are

Table 5. Serial CSF Analyses

Dog	Initial CSF Sample	CSF First Recheck	CSF Second Recheck
3	C: protein 31 mg/dL, TNCC 5/ μ L, RBC 8/ μ L, 34% N, 3% lymph, 63% M	6 weeks post-operatively: C: protein 14 mg/dL, TNCC <1/ μ L, RBC 63/ μ L, 41% N, 34% lymph, 25% M L: protein 60 mg/dL, TNCC 2/ μ L, RBC 2120/ μ L, 55% N, 40% lymph, 4% M, 1% E	5 months post-operatively: C: protein 25 mg/dL, TNCC 1/ μ L, RBC <1/ μ L, 6% N, 71% lymph m, 23% M L: protein 52 mg/dL, TNCC 5/ μ L, RBC 365/ μ L, 8% N, 86% lymph, 6% M
5	C: protein 37 mg/dL, TNCC 30/ μ L, RBC 30/ μ L, 70% N, 1% lymph, 29% M L: protein 40 mg/dL, TNCC 342/ μ L, RBC 40,800/ μ L, 98% N, 1% lymph, 1% M	5 months post-operatively: C: protein 35 mg/dL, TNCC 4/ μ L, RBC 332/ μ L 29% N, 13% lymph, 57% M 1% E	8 months post-operatively: C: protein 37 mg/dL, TNCC 1/ μ L, RBC 0/ μ L, 0% N, 23% lymph, 77% M L: protein 186 mg/dL, TNCC 4/ μ L, RBC 650/ μ L, 13% N, 26% lymph, 61% M

TNCC, total nucleated cell count; N, neutrophils; lymph, lymphocytes; M, macrophages; E, eosinophils; RBC, red blood cell count; C, cisterna magna; L, lumbar.

Reference intervals for CSF: TNCC \leq 3/ μ L, protein (cisternal) <25 mg/dL, (lumbar) <35 mg/dL.

consistent with earlier reports; however, the duration of signs in other reports was shorter (<1 week).^{2,5,9,13} Fever occurs in 37%⁸–66%⁶ of humans with SEE. Five of the dogs reported here had either a history of fever or were febrile on admission. Eight of 10 previously reported dogs with SEE also had fever.^{2,5,9,10,12,13}

In 915 humans with SEE, 34% were paraparetic or paraplegic at admission⁶ and other smaller studies have reported a higher incidence of paresis/plegia ranging from 63–72%.^{1,3,8,18,19} Five of our dogs were non-ambulatory on admission and the other 2 were ambulatory, but parietic. Likewise, 7 previously reported dogs were non-ambulatory.^{2,5,12,13}

Hematologic Findings

Peripheral neutrophilia appears to be the most common laboratory finding in dogs with SEE, including 6 previously reported^{2,5,9,10,13} and 5 in the current report. These findings are consistent with SEE in humans where the prevalence of leukocytosis is 60%⁸–78%.⁶

CSF Analysis

CSF analysis results in this report supported a diagnosis of SEE. CSF with a predominance of neutrophils (>75%) is consistent with but not diagnostic for bacterial disease within the central nervous system.²⁰ Four of 5 dogs had moderate increases in both TNCC and protein concentration. Results of CSF analysis are reported only in 4 other dogs^{2,9,13} and were similar to those reported here. Many (73%) humans with SEE have CSF pleocytosis, which is most commonly neutrophilic and less commonly mononuclear¹; furthermore, 90% of those people had an elevated CSF protein concentration.

Imaging

Vertebral column imaging is essential in the diagnosis of SEE. Myelography was used in all of the dogs in this report, and in 8 of 10 dogs reported previously.^{2,5,9,12,13} Whereas myelographic changes associated with SEE in dogs in this report were distinctive, they were not necessarily diagnostic. Myelography allows observation of the entire spinal cord, permitting diagnosis of multifocal lesions, and extent of the lesion(s). It was particularly valuable in 1 dog where a second lesion, outside the original area of neuroanatomic lesion localization, was identified. In humans, concerns about the use of myelography include blockage of contrast flow as a result of adhesions or large compressive lesions¹; however this seemingly was not a problem in any of the dogs in this report. Another concern with myelography is the potential for spread of microorganisms into the subarachnoid space.⁶

Although MR imaging is the imaging modality of choice for the diagnosis of SEE in humans,⁶ myelography has been used in the past, and is still used in some people when MRI is not available or inappropriate.^{6,21,22} Myelography was abnormal in all 33 persons with SEE.¹ The combination of CT and myelography was 92% sensitive for diagnosis of SEE,⁴ whereas the sensitivity of MR imaging was 80–91%.^{1,4} Advantages of MR imaging include: relatively good sensitivity; ability to perform multiplanar imaging^{1,6}; ability to define the extent of SEE⁸; characterization of the epidural inflammatory mass,¹⁶ and its non-invasive nature^{1,6}; however, MR imaging has a tendency to overestimate the extent of bony involvement.⁸

CT imaging in dog 1 did not provide additional diagnostic information, but CT may be helpful in the diagnosis of osteomyelitis or discospondylitis in other dogs with SEE. Spiral CT technology allows rapid image acquisition combined with reformatted and reconstructed

views as multiplanar images. This permits better anatomic localization and evaluation of soft tissue and bone lesions associated with the spinal cord and vertebral column. With greater access to CT and MR imaging, use of these modalities in dogs suspected to have SEE should be considered.

Discospondylitis was identified in dogs 4, 6, and 7 (Fig 2), and 3 dogs in another report.¹² Discospondylitis occurs in 8.3% of humans with SEE.¹⁸ Although dog 1 had histopathologic evidence of vertebral osteomyelitis at surgery, radiographic changes consistent with osteomyelitis were not noted until 2 months later. The lack of radiographic or CT evidence of osteomyelitis at the time of surgery may have been because the dog had only a 2-week history of clinical signs before admission. Previously, radiographic evidence of osteomyelitis in association with SEE has been reported in only 1 dog.⁵ Radiographic evidence of osteomyelitis occurs in 23–44% of humans with SEE.^{1,6,18}

Microbiologic Observations

The most common pathogens isolated in this study were hemolytic *E. coli*, *Bacteroides* spp. or *Prevotella* spp., and *S. intermedius*. In 2 previously reported dogs, *S. canis*, *S. intermedius*, and *Clostridium perfringens* were isolated from the surgical site and from peripheral blood.² Isolation of *Enterococcus fecalis* and *E. coli* was reported in 1 dog with SEE after epidural analgesic administration.¹⁰ *E. fecalis* also was reported in a dog with concurrent discospondylitis.¹² Interestingly, organisms were not isolated from CSF in the dogs in this report, or in other reports of SEE in dogs. In humans with SEE, CSF microbial culture rarely is positive.¹

In the dogs in this report, the most successful sites for positive cultures were the lesion site and blood. In humans, culture of the surgical site is 90% sensitive.¹ Previous antibiotic therapy likely influences success of microbial isolation. In humans not administered antibiotics, culture success increased to 97%.¹ Interestingly, all 4 dogs previously administered antibiotics in this study had a positive culture from surgically collected samples. The perioperative cefazolin administered to all dogs in our study may have influenced the culture results from the material collected at the time of surgery. However, it would not have affected the CSF culture results, since the CSF was collected before surgery, and therefore before perioperative antibiotics were administered.

Type of bacteria isolated is likely dependent on the source or route of infection. Most SEE in humans is caused by *S. aureus* and *Streptococcus* spp.^{1,3,6–8,19}; bacteria most commonly associated with skin infection and osteomyelitis. Predisposing factors for SEE infection with these bacteria include invasive procedures (e.g., surgery)

or epidural catheterization, especially if catheters are in place for more than 3 days.¹⁹ Additional risk factors for developing SEE include diabetes mellitus, trauma, urinary tract infection, corticosteroid therapy, and immunocompromise.^{1,6,8} Dog 6 was later diagnosed with pituitary-dependent hyperadrenocorticism, and dog 3 had a retroperitoneal abscess at the time of SEE diagnosis. The cause of SEE in dog 3 was speculated to have been associated with migration of an inhaled foreign body (e.g., a grass awn) or by direct extension of the infected retroperitoneal tissue.

Surgical Treatment

The goal of surgery was to make a diagnosis by obtaining material for microbial culture/susceptibility testing and pathology; and to treat the dog by decompressing the spinal cord and stabilizing the vertebrae if luxation was present. Stabilization is occasionally required in people treated surgically for SEE.²³ In 5 dogs (1, 3–5, 7), laminectomy was done at the site of all myelographic extradural lesions. In the 2 other dogs (2, 6), the laminectomy was not done at all the sites of myelographic abnormalities. In dog 2, there was an extradural lesion from T2–12, L1 and L2. More extensive surgery was not performed because a large amount of pus was removed from the vertebral canal. In dog 6, the C6–7 extradural lesion was not addressed as it was determined to be chronic, most consistent with a type II disc protrusion. This lesion was not compatible with the dog's clinical signs because the dog was much more paretic in the pelvic limbs than the thoracic limbs. The T5–6 spinal cord compression was not treated surgically, because of concern for increasing morbidity after surgery for the T10–11 lesion. Both of these dogs had a poor outcome. The outcome of dog 6 is difficult to assess, as this dog was euthanized for an unrelated acute cervical disc problem (C5–6). It is possible that dog 2 may have had a better outcome had a more aggressive surgical decompression and drainage been performed.

Surgical stabilization was performed in dogs 6 and 7 using pins and polymethylmethacrylate. Vertebral luxation was noted preoperatively (dog 7) and intraoperatively (dog 6). The risk of placing an implant in an infected site was considered less than the potential risk of spinal cord trauma because of continued vertebral instability. Pins and polymethylmethacrylate were used instead of a plate, as a good bone–plate interface could not be achieved at these locations (T10–11 and L2–3) in these dogs.

Outcome

Five dogs improved markedly after surgical intervention and antibiotic therapy. Although dog 6 had a poor

outcome, this dog did improve postoperatively. Unfortunately, a month later, the owners euthanatized the dog because of acute intervertebral disc herniation. These findings support the importance of early detection and treatment to achieve a positive outcome.^{1,2,6,8}

Although a larger SEE patient population is needed to determine the relationship of neurologic status and outcome in dogs with SEE, it would appear that, as in people, severe neurologic dysfunction is correlated with a poor prognosis.^{1,2,6,8} In humans, SEE often is initially misdiagnosed as meningitis or intervertebral disc disease.⁶ In dogs, the combination of myelopathic signs in association with fever should lead clinicians to suspect an infectious or inflammatory process and thus include SEE in a list of differential diagnoses.

Little information is available about SEE in dogs. Fever, apparent spinal pain, and myelopathic signs should increase the index of suspicion for SEE. Although limited by the small number of dogs with SEE, the findings in this report suggest that rapid diagnosis, early surgical intervention and long-term antibiotic administration may contribute to a successful outcome.

REFERENCES

1. Darouiche RO, Hamill RJ, Greenberg SB, et al: Bacterial spinal epidural abscess. Review of 43 cases and literature survey. *Medicine (Baltimore)* 71:369–385, 1992
2. Dewey CW, Kortz GD, Bailey CS: Spinal epidural empyema in two dogs. *J Am Anim Hosp Assoc* 34:305–308, 1998
3. Grieve JP, Ashwood N, O'Neill KS, et al: A retrospective study of surgical and conservative treatment for spinal extradural abscess. *Eur Spine J* 9:67–71, 2000
4. Hlavin ML, Kaminski HJ, Ross JS, et al: Spinal epidural abscess: a ten-year perspective. *Neurosurgery* 27:177–184, 1990
5. Jerram RM, Dewey CW: Suspected spinal epidural empyema and associated vertebral osteomyelitis (phylisit) in a dog. *J Vet Emer Crit Care* 8:103–108, 1998
6. Reihnsaus E, Waldbaur H, Seeling W: Spinal epidural abscess: a meta-analysis of 915 patients. *Neurosurg Rev* 23:175, 2000 (discussion 205)
7. Mackenzie AR, Laing RB, Smith CC, et al: Spinal epidural abscess: the importance of early diagnosis and treatment. *J Neurol Neurosurg Psychiatry* 65:209–212, 1998
8. Rigamonti D, Liem L, Sampath P, et al: Spinal epidural abscess: contemporary trends in etiology, evaluation, and management. *Surg Neurol* 52:189–197, 1999
9. Cherrone KL, Eich CS, Bonzynski JJ: Suspected paraspinous abscess and spinal epidural empyema in a dog. *J Am Anim Hosp Assoc* 38:149–151, 2002
10. Remedios AM, Wagner R, Caulkett NA, et al: Epidural abscess and discospondylitis in a dog after administration of a lumbosacral epidural analgesic. *Can Vet J* 37:106–107, 1996
11. Ndikuwera J, Knottenbelt DC, Lawrence J, et al: Spinal abscess in a dog. *Vet Rec* 120:554–555, 1987
12. Adamo PF, Cherubini GB: Discospondylitis associated with three unreported bacteria in the dog. *J Small Anim Pract* 42:352–355, 2001
13. Nykamp SG, Steffey MA, Scrivani PV, et al: Computed tomographic appearance of epidural empyema in a dog. *Can Vet J* 44:729–731, 2003
14. Pereira CE, Lynch JC: Spinal epidural abscess: an analysis of 24 cases. *Surg Neurol* 63(Suppl 1): S26–S29, 2005
15. Ahl T, Hedstrom M, von Heijne A, et al: Acute spinal epidural abscess without concurrent spondylodiscitis. Successful closed treatment in 10 cases. *Acta Orthop Scand* 70:199–202, 1999
16. Tung GA, Yim JW, Mermel LA, et al: Spinal epidural abscess: correlation between MRI findings and outcome. *Neuroradiology* 41:904–909, 1999
17. Feldenzer JA, McKeever PE, Schaberg DR, et al: The pathogenesis of spinal epidural abscess: microangiographic studies in an experimental model. *J Neurosurg* 69:110–114, 1988
18. Akalan N, Ozgen T: Infection as a cause of spinal cord compression: a review of 36 spinal epidural abscess cases. *Acta Neurochir (Wien)* 142:17–23, 2000
19. Wang LP, Hauerberg J, Schmidt JF: Incidence of spinal epidural abscess after epidural analgesia: a national 1-year survey. *Anesthesiology* 91:1928–1936, 1999
20. Bailey CS, Vernau W: Cerebrospinal fluid, in Kaneko JJ, Harvey JW, Bruss ML (eds): *Clinical Biochemistry of Domestic Animals* (ed 5). San Diego, Academic Press, 1997, pp 785–827
21. Curry WT Jr., Hoh BL, Amin-Hanjani S, et al: Spinal epidural abscess: clinical presentation, management, and outcome. *Surg Neurol* 63:364, 2005 (discussion 371)
22. Soehle M, Wallenfang T: Spinal epidural abscesses: clinical manifestations, prognostic factors, and outcomes. *Neurosurgery* 51:79, 2002 (discussion 86–77)
23. Lohr M, Reithmeier T, Ernestus RI, et al: Spinal epidural abscess: prognostic factors and comparison of different surgical treatment strategies. *Acta Neurochir (Wien)* 147:159, 2005 (discussion 166)