

UCLA

UCLA Previously Published Works

Title

Treating Aortic Stenosis and Mitral Regurgitation With 1 Transcatheter Heart Valve 2
Birds With 1 Stone

Permalink

<https://escholarship.org/uc/item/1qz4g0xz>

Journal

Journal of the American College of Cardiology, 61(24)

ISSN

0735-1097

Authors

Suh, William M
Vorobiof, Gabriel
Shemin, Richard J
[et al.](#)

Publication Date

2013-06-01

DOI

10.1016/j.jacc.2012.12.059

Copyright Information

This work is made available under the terms of a Creative Commons Attribution License, available at <https://creativecommons.org/licenses/by/4.0/>

Peer reviewed

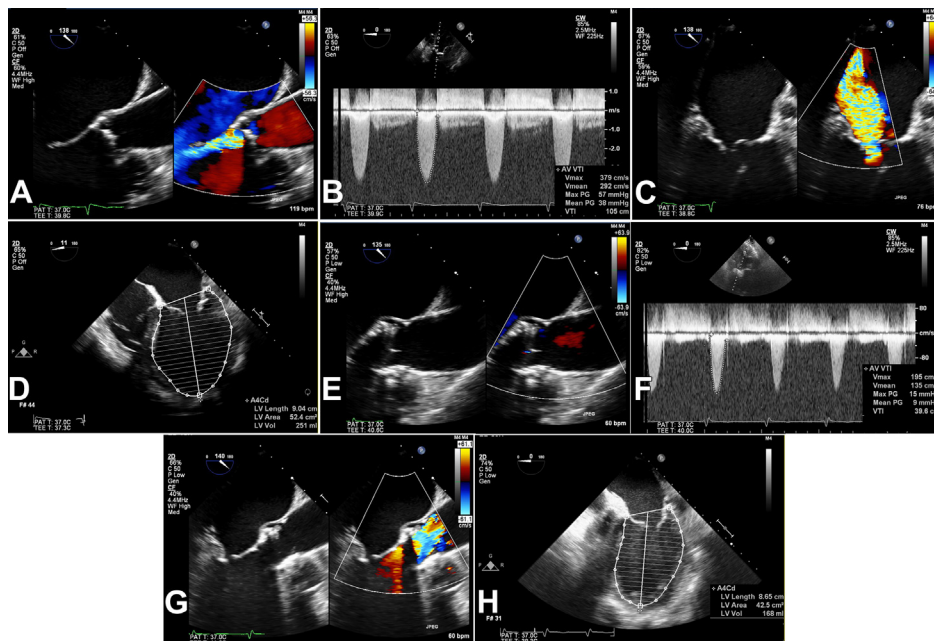
IMAGES IN CARDIOLOGY

Treating Aortic Stenosis and Mitral Regurgitation With 1 Transcatheter Heart Valve

2 Birds With 1 Stone

William M. Suh, MD,* Gabriel Vorobiof, MD,* Richard J. Shemin, MD,†
Murray H. Kwon, MD,† Melissa Fusari, MD,‡ Jonathan M. Tobis, MD*

Los Angeles and Irvine, California



From the *Division of Cardiology, David Geffen School of Medicine at UCLA, Los Angeles, California; †Division of Cardiothoracic Surgery, David Geffen School of Medicine at UCLA, Los Angeles, California; and ‡Edwards Lifesciences, Irvine, California. Dr. Vorobiof serves as a consultant for St. Jude Medical and Lantheus Medical Imaging; and is on the speakers' bureau for Toshiba America Medical Systems, Dr. Shemin serves as a consultant for Atricure and Edwards Lifesciences. Dr. Fusari is a full-time physician proctor employed by Edwards Lifesciences. Dr. Tobis serves as a consultant for St. Jude Medical. All other authors have reported that they have no relationships relevant to the contents of this paper to disclose. Manuscript received November 29, 2012; accepted December 11, 2012.

An 82-year-old woman with severe aortic stenosis and left ventricular ejection fraction (LVEF) of 20% was referred for transcatheter aortic valve replacement (TAVR). Aortic regurgitation was moderate (A, Online Video 1), mean gradient was 38 mm Hg (B), mitral regurgitation (MR) was severe (C, Online Video 2), and the LV was markedly dilated to 251 ml (D). TAVR with a 23-mm Edwards Sapien valve was performed with cardiopulmonary bypass for hemodynamic stability during valve implantation. After TAVR, there was trace central aortic regurgitation (E), mean gradient was reduced to 9 mm Hg (F), MR disappeared completely (G, Online Video 3), and LV volume was reduced to 168 ml (H) with an LVEF of 30%.

TAVR relieved the pressure and volume overload within the LV, with dramatic acute effects on LV performance. The immediate reversal in MR proved that the MR was functional due to dilation of the LV and its effects on the mitral valve annulus and apparatus. TAVR successfully eliminated 2 valvular abnormalities.