

UC Irvine

Journal of Education and Teaching in Emergency Medicine

Title

A Simulation Model for Extensor Tendon Repair

Permalink

<https://escholarship.org/uc/item/4147h7q9>

Journal

Journal of Education and Teaching in Emergency Medicine, 2(3)

Authors

Aronstam, Elizabeth
Overton, David T

Publication Date

2017

DOI

10.5070/M523035693

Copyright Information

Copyright 2017 by the author(s). This work is made available under the terms of a Creative Commons Attribution License, available at <https://creativecommons.org/licenses/by/4.0/>

Peer reviewed

A Simulation Model for Extensor Tendon Repair

Elizabeth Aronstam, DO* and David T Overton, MD*

*Western Michigan University Homer Stryker M.D. School of Medicine, Department of Emergency Medicine, Kalamazoo, MI

Correspondence should be addressed to David T Overton, MD at overton@med.wmich.edu

Submitted: November 4, 2016; Accepted: May 18, 2017; Electronically Published: July 14, 2017; <https://doi.org/10.21980/J8V57X>

Copyright: © 2017 Aronstam et al. This is an open access article distributed in accordance with the terms of the Creative Commons Attribution (CC BY 4.0) License. See: <http://creativecommons.org/licenses/by/4.0/>

ABSTRACT:

Audience: This simulation model is designed for use by emergency medicine residents. Although we have instituted this at the PGY-2 level of our residency curriculum, it is appropriate for any level of emergency medicine residency training. It might also be adapted for use for a variety of other learners, such as practicing emergency physicians, orthopedic surgery residents, or hand surgery trainees.

Introduction: Tendon injuries commonly present to the emergency department, so it is essential that emergency physicians be competent in evaluating such injuries. Indeed, extensor tendon repair is included as an ACGME Emergency Medicine Milestone (Milestone 13, Wound Management, Level 5 - "Performs advanced wound repairs, such as tendon repairs...").¹

However, emergency medicine residents may have limited opportunity to develop these skills due to a lack of patients, competition from other trainees, or preexisting referral patterns. Simulation may provide an alternative means to effectively teach these skills in such settings. Previously described tendon repair simulation models that were designed for surgical trainees have used rubber worms⁴, licorice⁵, feeding tubes, catheters^{6,7}, drinking straws⁸, microfoam tape⁹, sheep forelimbs¹⁰ and cadavers.¹¹ These models all suffer a variety of limitations, including high cost, lack of ready availability, or lack of realism. We sought to develop an extensor tendon repair simulation model for emergency medicine residents, designed to meet ACGME Emergency Medicine Milestone 13, Level 5. We wished this model to be simple, inexpensive, and realistic.

Objectives: By the end of this educational session, the learner will be able to: 1) List the indications for extensor tendon repair in the emergency department, 2) recognize the indications for referral to orthopedic or hand surgery, 3) list the risks and benefits of emergency department extensor tendon repair, 4) perform an appropriate physical examination for a patient with a potential extensor tendon laceration, 5) list the maximum time limit of tourniquet application for this procedure, 6) list the materials needed for extensor tendon repair in the emergency department, 7) successfully repair a completely severed extensor tendon using four different techniques: horizontal mattress, figure of eight, modified Kessler and modified Bunnell, and 8) describe the appropriate splinting of a repaired extensor tendon.

INNOVATIONS

Methods: The learner responsible content/educational handout component of our innovation teaches residents about emergency department extensor tendon repair, and includes: 1) relevant anatomy 2) indications and contraindications for emergency department extensor tendon repair 3) physical exam findings 4) tendon suture techniques and 5) aftercare.

During their PGY-2year, emergency medicine residents are provided the learner responsible content/educational handout on a rotating basis. Residents are provided these materials approximately three weeks prior to a scheduled simulation lab session. The learner responsible content/educational handout are to be completed prior to the simulation lab session. The learner responsible content/educational handout are estimated to take residents one hour to complete.

During the scheduled lab session, each resident is supplied two whole pig feet and suture material. Under faculty supervision, residents dissect out extensor tendons and perform tendon repairs using four different tendon repair stitches: the modified Kessler, the modified Bunnell, the figure-of-eight, and the horizontal mattress stitch. The hands-on lab takes approximately one hour for residents to complete and requires the presence of a single supervising faculty member.

We developed an extensor tendon repair simulation model for emergency medicine residents, designed to meet ACGME Emergency Medicine Milestone 13, Level 5.¹ This model includes both an learner responsible content/educational handout component and a simulation model. This educational innovation is simple, inexpensive, realistic, and requires limited faculty time.

This simulation model has been well-received by our resident and faculty, and successfully addresses this particular ACGME Milestone.

Topics: Simulation training, tendon repair, extensor tendons of the finger, orthopedics, hand.



USER GUIDE

List of Resources:

Abstract	1
User Guide	3
Learner Materials	5
Extensor Tendon Laceration Repair in the Emergency Department	6

Learner Audience:

Interns, junior residents, senior residents, attending physicians

Time Required for Implementation:

Initial Preparation:

- Our instructional module required approximately ten hours of faculty time to develop. Once prepared, the same module has been used for each monthly cohort of residents, without revision. Office secretarial staff email the notifications to the involved residents each month.

Faculty Preparation:

- We utilize the same faculty member to give the simulation lab each month. Thus, after faculty have reviewed the preparatory materials and given the lab once, only a single hour of faculty time is required to teach the simulation each month.

Didactics:

- Each resident takes approximately one hour to review the online educational materials.
- The scheduled hands-on simulation also takes approximately one hour.

Learners per instructor:

- We typically schedule 3-4 PGY-2 residents to complete the simulation each month (although we have accommodated as many as five).

Topics:

Simulation training, tendon repair, extensor tendons of the finger, orthopedics, hand.

Objectives:

By the end of this educational session, the learner will be able to:

1. List the indications for extensor tendon repair in the emergency department.
2. Recognize the indications for referral to orthopedic or hand surgery.
3. List the risks and benefits of emergency department extensor tendon repair.
4. Perform an appropriate physical examination for a patient with a potential extensor tendon laceration.

Objectives con't:

5. List the maximum time limit of tourniquet application for this procedure.
6. List the materials needed for extensor tendon repair in the emergency department.
7. Successfully repair a completely severed extensor tendon using four different techniques:
 - horizontal mattress
 - figure of eight
 - modified Kessler
 - modified Bunnell
8. Describe the appropriate splinting of a repaired extensor tendon.

Linked methods and objectives:

The learner responsible content/educational handout component of our innovation teaches residents about emergency department extensor tendon repair, and includes: 1) relevant anatomy 2) indications and contraindications for emergency department extensor tendon repair 3) physical exam findings 4) tendon suture techniques and 5) aftercare. Residents are provided these materials approximately three weeks prior to a scheduled simulation lab session. The learner responsible content/educational handout are to be completed prior to the simulation lab session.

During the scheduled lab session, each resident is supplied two whole pig feet and suture material. Under faculty supervision, residents dissect out extensor tendons and perform tendon repairs using four different tendon repair stitches: the modified Kessler, the modified Bunnell, the figure-of-eight, and the horizontal mattress stitch. The hands-on lab takes approximately one hour for residents to complete and requires the presence of a single supervising faculty member.

Recommended pre-reading for instructor:

- We recommend that the instructor review the learner responsible content/educational handout: "Extensor Tendon Laceration Repair in the Emergency Department"
- Any book chapter or journal article on tendon laceration repair

Learner responsible content (LRC):

- Learners should review the learner responsible content/educational handout: "Extensor Tendon Laceration Repair in the Emergency Department" prior to the simulation lab.

Implementation Methods:

- Each resident is provided with:



USER GUIDE

- A suture set (scalpel, hemostat, needle driver and forceps)
- 5-0 nylon sutures, two packages
- One disposable underpad
- Nonsterile gloves
- Two pig feet (whole)
- Learners dissect out the pig's feet tendons
- Tendons are lacerated to allow for repair
- Tendons are repaired, we have found that the most logical sequence of teaching and performing the different repairs:
 - horizontal mattress stitch
 - figure-of-eight
 - modified Kessler
 - modified Bunnell

List of items required to replicate this innovation:

1. Two pig feet (whole)
2. 5-0 nylon suture, two packages
3. Suture set (scalpel, hemostat, needle driver and forceps)
4. One disposable underpad
5. Sharps disposal container
6. Nonsterile gloves

Approximate cost of items to create this innovation:

Pig feet are available from a variety of sources. Many grocery stores stock them in the meat section. They are commonly available from butchers and meat markets, as well. We pay approximately \$2 per foot locally.

Suture equipment should include a scalpel, hemostat, needle driver, and forceps, along with non-absorbable suture material. Suture sets needn't be sterile, and can be cleaned and reused. They are available online for as little as \$15 per set. Suture material costs approximately \$4 per learner.

Results and tips for successful implementation:

Pig feet, particularly those found in grocery stores, are often pre-cut in half. This is undesirable, as the tendons are often cut making them unsuitable for repair. Whole feet are preferred.

We have found that pig feet can be conveniently purchased in bulk and frozen. They can be thawed the day before the lab. We have found that soaking them in water overnight is very useful: it cleans and softens the skin and removes any objectionable odors.

Although we suggest that two feet be made available to each resident, we find that a given resident may only need to use one, depending on whether or not four suitable tendons can be located in one foot. Unused feet can be refrozen for future use.

We have found that the most logical sequence of teaching and performing the different suture techniques starts with the horizontal mattress stitch, and then moving to the figure-of-eight, the modified Kessler, and finally the modified Bunnell.

References/suggestions for further reading:

1. The Accreditation Council for Graduate Medical Education and The American Board of Emergency Medicine. The emergency medicine milestone project. <http://www.acgme.org/Portals/0/PDFs/Milestones/EmergencyMedicineMilestones.pdf>. Accessed November 3, 2016.
2. Baecher NB, Rosh AJ. Extensor tendon repair. In: Baecher NB, ed. Medscape. WebMD LLC. <http://emedicine.medscape.com/article/109111-overview-a7>. Updated March 13, 2017. Accessed November 4, 2016
3. Ewen B, Hart RG. Hand trauma. In: Stone C, Humphries RL, eds. *CURRENT Diagnosis & Treatment Emergency Medicine*. 7th ed. New York, NY: McGraw-Hill; 2011:422-466.
4. Ingraham JM, Weber FA, Weber RA. Utilizing a simulated tendon to teach tendon repair technique. *Hand (N Y)*. 2009; 4(2):150-155. doi: 10.1007/s11552-009-9184-9
5. Rufai SR. Simulation for tendon repair. *Ann R Coll Surg Engl*. 2013;95(5):374. doi: 10.1308/003588413X13629960046877
6. Flemming AF, Hoeyberghs JL. The flexor-tendon repair simulator. *Br J Plast Surg*. 2001;54(7):650. doi: 10.1054/bjps.2001.3654
7. Abdulal S, Onyekwelu O. An alternative model for teaching tendon repair and surgical skills in plastic surgery. *JPRAS Open*. 2016;7:12-15. doi: 10.1016/j.jpra.2015.11.003
8. Sheppard NN. A low-cost, convenient model for the teaching of tendon repair. *Ann R Coll Surg Engl*. 2011; 93(3):257-258. doi: 10.1308/003588411X12851639107395c
9. Elfaki A, Abreo N, Wilmot M, Murphy S, Gillespie P. Simulation of tendon repair using microfoam tape. *IJS* 2015;23(1):S104. doi: 10.1016/j.ijso.2015.07.486
10. Tan S, Power D, Rajaratnam V. Animal models for training in tendon surgery: sheep's forelimbs. *J Hand Surg Eur Vol*. 2010;35(2):152-3. doi: 10.1177/1753193409346908
11. Hassan S, Eisma R, Malhas A, Soames F, Harry L. Surgical simulation flexor tendon repair using Thiel cadavers: a comparison with formalin embalmed cadavers and porcine models. *J Hand Surg Eur Vol*. 2015;40(3):246-249. doi: 10.1177/1753193409346908



LEARNER MATERIALS

Extensor Tendon Laceration Repair in the Emergency Department

Procedure Module Learner Responsible Content

Objectives

- Understand the anatomy of the extensor tendons of the hand
- Recognize the indications for extensor tendon repair in the ED
- Recognize the indications for extensor tendon repair by a hand surgeon
- Perform a physical exam of the extensor tendons
- Become competent at extensor tendon repair with practice on pig tendons in the simulation lab

Anatomy

The first, second and 5th digits have 2 separate extensor tendons:

The thumb has 2 extensor tendons:

- Extensor pollicis longus (extends interphalangeal (IP) and metacarpophalangeal (MCP) joints)
- Extensor pollicis brevis (extends MCP joint)

The index finger has 2 extensor tendons:

- Extensor indicis
- Extensor digitorum

The little finger has 2 extensor tendons:

- Extensor digiti minimi
- Extensor digitorum

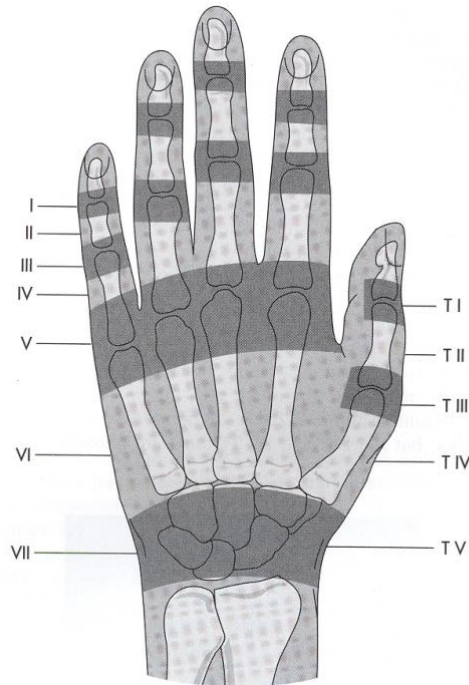
The extensor digitorum starts at the elbow and provides an extension mechanism for the 2nd through 5th digits.

The juncturae tendinum (connective tissue bands) distribute the work of tendons by interconnection of the 2nd-5th digits. Thus, an isolated tear of one tendon may not interrupt function due to the contributing work of an adjacent extensor tendon. However, pain with extension against resistance may indicate tendon damage.

At the MCP joint, the extensor tendon flattens and widens, creating a hood (extensor expansion/dorsal hood) that covers the distal metacarpal and proximal phalanx.



LEARNER MATERIALS



Kleinhart Zones

The extensor tendons of the hand begin just proximal to the extensor retinaculum. After exiting from under this encasing sheath, the tendons form an interconnected network as they cross the dorsum of the hand.

Kleinhart Zones 1, 2 and 3 of the long digits are difficult to repair and need to be done by a hand surgeon. Untreated Zone 3 lacerations may lead to a Boutonnière deformity (flexion at proximal interphalangeal joint (PIP) and hyperextension of distal interphalangeal (DIP) joint).

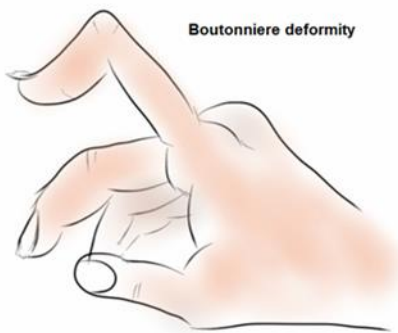


Illustration used with permission of Nazanin Firooz, MD, Rheumatologist, Westhills, CA



LEARNER MATERIALS

A Mallet finger results from a laceration or avulsion of the insertion of the extensor tendon on the distal phalanx. Often these are closed injuries from blunt trauma or forced flexion of the DIP. Treatment is splinting DIP in full extension for 6-8 weeks (padded dorsal splint or non-padded volar splint). Failure of treatment may result in a Swan neck deformity (hyperextension of the PIP and flexion of the DIP).

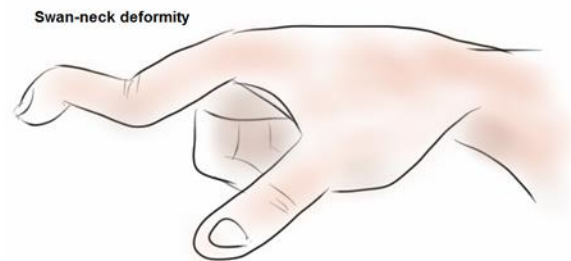


Illustration used with permission of Nazanin Firooz, MD, Rheumatologist, Westhills, CA

A Boxer's knuckle results from rupture of the dorsal hood of the MCP that leads to lateral displacement of the tendon. In the ED, the MCP is extended until the tendon relocates and the hand is splinted in that position. Follow-up is with hand surgery, as surgery is often needed for definitive repair.¹

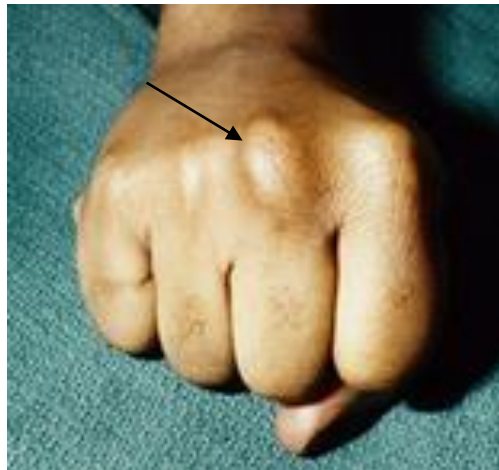

Illustration used with permission from HandSport®Surgery Institute, New York, NY

Boxer's knuckle

Indications for ED repair of extensor tendon

- Distal wrist to MCP laceration (Zone 4, 5, 6) of fingers
- Zone 2 and 4 of thumb
- Laceration >50% of tendon



LEARNER MATERIALS

Tendon lacerations <50% often do not need suture repair and many authors recommend splinting alone after standard wound care.^{2,3,4} Note, however, that the chapter in Tintinalli does recommend repair of lacerations <50%.⁵

Only repair in the emergency department (ED) if there is no fracture, no joint space penetration and no human bite. If these exist, irrigate wound, close skin loosely with simple interrupted sutures, splint and refer to ortho/hand surgery.²

Tendons must be repaired within 7 days of injury before tendon ends retract. If delayed closure is necessary, wound needs to be irrigated and debrided, and overlying skin loosely closed with simple interrupted sutures.¹

Zone 5 tendon lacerations often result from a human bite and need to be irrigated and left open. X-ray is needed to exclude fracture and foreign body. Antibiotics are also given for these injuries.

Minor isolated tendon sheath lacerations do not require repair. However, lacerations deep enough to violate the tendon sheath should prompt a careful search for a coexisting tendon injury. Subtle extensor weakness may be a tipoff. Carefully examine the wound through a full range of motion and maintain a low threshold for specialist referral.

When to consult hand surgery

- Highly contaminated injury
- Tendon injury to Zones 1-3 of long fingers and 1 and 3 of thumb
- Fracture
- Joint space penetration
- Lack of overlying skin
- Human bite
- Flexor tendon injury

Flexor tendon injuries are more complex and need to be repaired by a hand surgeon. Optimal repair is within 24 hours, but may be up to 7 days later. If surgery will be delayed, the wound is cleaned, closed and extremity is placed in a splint. Splint with wrist and MCP slightly flexed and PIP/DIP in slight extension.⁶

Evaluation

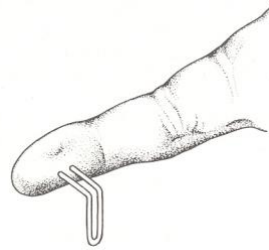
Neurovascular status:

- Check radial and ulnar pulses and assess distal capillary refill.
- Sensory testing with 2-point discrimination can be tested with a paperclip with the points 5mm apart. Normal 2-point discrimination is 2-5 mm at the fingertip, 7-10mm on the palm and 7-12mm on the dorsal aspect of hand. Start with the points 2cm apart and narrow the points until only one



LEARNER MATERIALS

point is felt. Compare the 2-point discrimination of injured digit with the unaffected digit on the other hand.



2-point discrimination

Motor and strength:

- Examine tendon in full range of motion and test motion against resistance. For 2nd-5th digits: flexion, extension, adduction and abduction. For thumb: flexion, extension, adduction, abduction and opposition.
- To test extension of 2nd-5th digits at the MCP you need to stabilize the wrist and have patient extend fingers. Extension of the IP joints are controlled by extensor tendons, the lumbricals, and the dorsal interossei muscles. See the following link for a video of the extensor tendon exam: [Extensor Tendon Exam](#)

Repair

Control bleeding with a tourniquet if needed (digital or blood pressure cuff), but not for more than 2 hours.

Risks to inform the patient about include further tendon damage, need for surgery if repair unsuccessful, diminished function, nerve damage, bleeding, and infection.

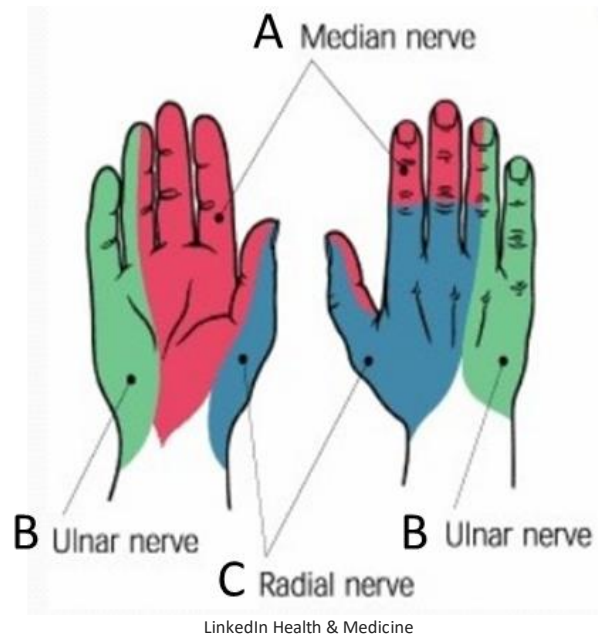
Irrigate with normal saline and clean and judiciously debride wound. Handle tendon ends carefully; cut ends if jagged. Avoid bluntly handling the cut end of tendon. Place hand in extension.

Suture material: 4-0, 5-0 or 6-0 **non-absorbable**, synthetic suture (Ethibond® or Mersiline®) for tendon repair. 5-0 nylon (Ethilon®) suture is used for skin closure.

Anesthesia: Use a digital or wrist block using a 25 or 27-gauge needle and 1% lidocaine (duration 30-60 min) or 1% mepivacaine (duration 45-90 min).



LEARNER MATERIALS



Sensory distribution of A) median B) ulnar and C) radial nerve

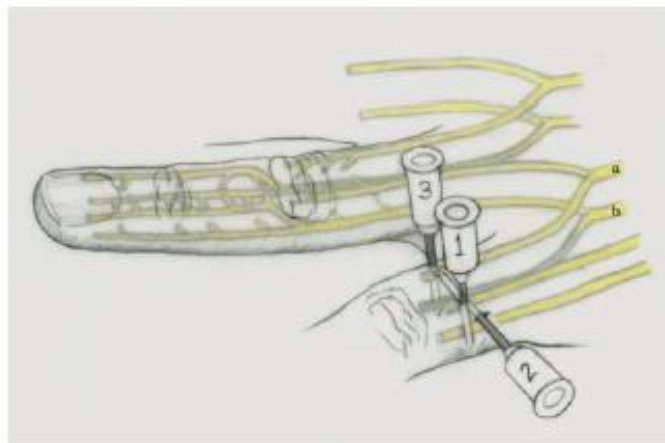


Illustration used with permission of Timothy Sweeney, MD

Digital block

Digital Block

1. Insert needle on dorsal surface of proximal phalanx toward volar side and inject 1ml of anesthetic.
2. Bring needle back to skin and redirect across dorsal aspect and inject 1 ml.
3. Repeat step one on the opposite side.



LEARNER MATERIALS

Wrist blocks

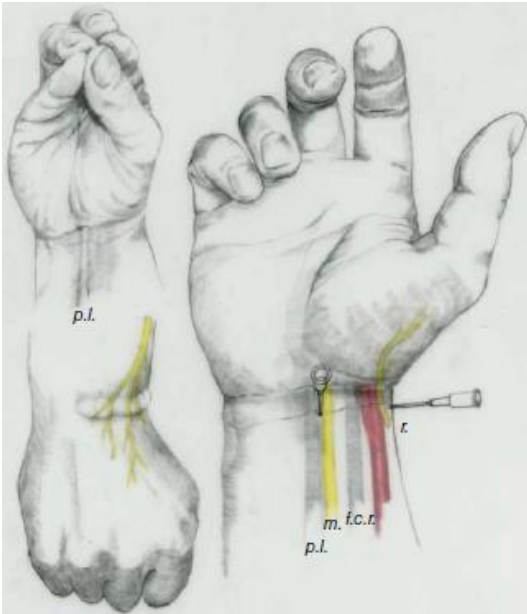
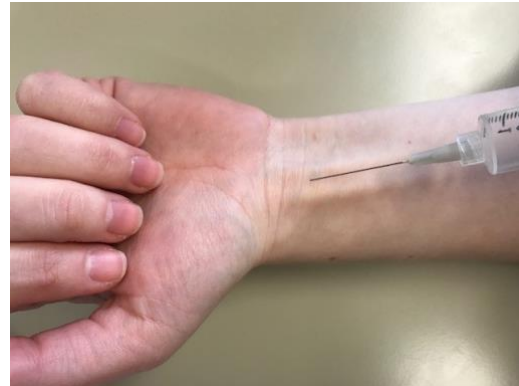

Illustration used with permission of Timothy Sweeney, MD

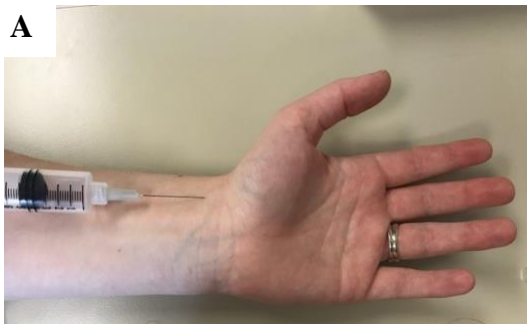


Source: L. Winfield, Western Michigan University Homer Stryker MD School of Medicine

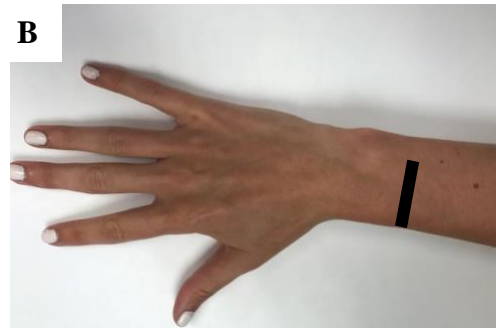Median and radial nerve block

Median nerve block:

The median nerve traverses between the flexor carpi radialis and the palmaris longus tendons. First raise a wheel of anesthetic in the subcutaneous space between the tendons. Then insert the needle between the tendons until you feel a “pop” of the fascia and insert 3-4 ml of anesthetic.



Source: L. Winfield, Western Michigan University Homer Stryker MD School of Medicine



Source: S. LaRue, Western Michigan University Homer Stryker MD School of Medicine

Radial nerve block

Radial nerve block:

- A. The needle is inserted at the proximal wrist crease just lateral to the radial artery and needle is advanced 0.5 cm. 1-2ml anesthetic injected.
- B. 5 ml of superficial injection on the dorsal wrist from wrist crease on radial side to 4th metacarpal.



LEARNER MATERIALS

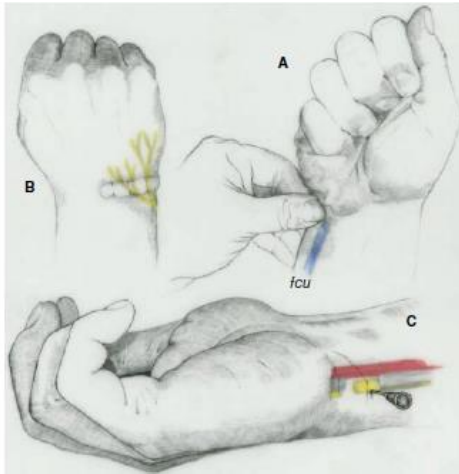
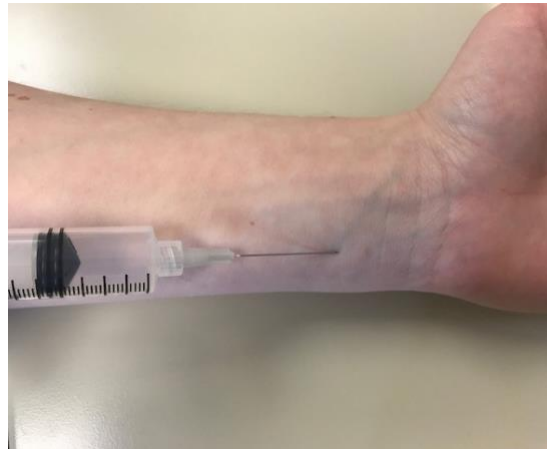

Illustration used with permission of Timothy Sweeney, MD



Source: L. Winfield, Western Michigan University Homer Stryker MD School of Medicine

Ulnar nerve block

Ulnar nerve block:

The ulnar nerve traverses deep to the flexor carpi ulnaris, which can be felt if the patient makes a fist. Make a wheel of anesthetic 2cm distal to wrist crease. Insert the needle underneath flexor carpi ulnaris, continue insertion until 0.5 cm past the tendon and insert 3ml of anesthetic.

Suture techniques

The modified Bunnell and modified Kessler are strong sutures, but work better with cord-like, more proximal tendons. The figure-of-eight or horizontal mattress stitches are better for flat, more distal tendons.

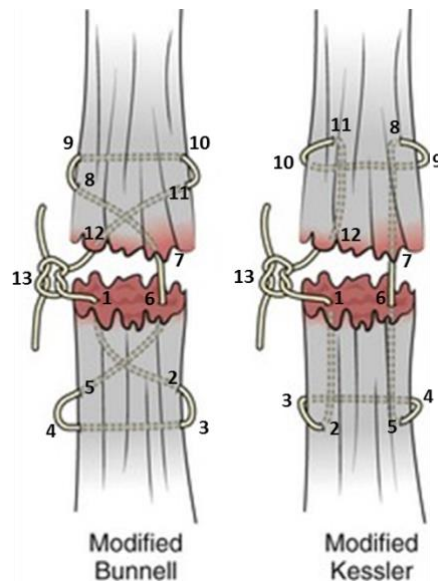


Illustration used with permission of Peter E. Sokolove, MD, FACEP and David K. Barnes, MD, FACEP

Modified Bunnell and Modified Kessler Sutures



LEARNER MATERIALS

Modified Bunnell:

- 1) insert needle into cut end of tendon 1/3 diameter on radial side.
- 2) pass the needle diagonally 1cm and exit tendon dorsally on ulnar side.
- 3) wrap suture underneath tendon.
- 4) re-enter tendon dorsally on radial side.
- 5) pull the suture diagonally through to exit on the ulnar side.
- 6) the needle should exit on the ulnar 1/3 of the tendon.
- 7) repeat the same on the other side: enter the tendon 1/3 diameter on ulnar side.
- 8) pass the needle 1cm diagonally and exit tendon dorsally on radial side.
- 9) wrap suture underneath tendon.
- 10) re-enter tendon dorsally on ulnar side.
- 11) pull the needle through the length of the tendon to exit the cut end.
- 12) the needle will exit on the radial side of the tendon.
- 13) the 2 free ends will be on the radial side of the tendon. Gently apply traction so that the ends come together. Do not apply too much traction or the ends will bunch up. Secure with a knot that will be buried between the 2 tendon ends².

Modified Kessler:

- 1) insert needle into cut end of tendon 1/3 diameter on radial side.
- 2) pass suture 1cm and exit tendon dorsally.
- 3) wrap suture underneath tendon.
- 4) reenter tendon dorsally on ulnar side, parallel to exit site on radial side.
- 5) pull the suture through.
- 6) the needle should exit on the ulnar 1/3 of the tendon.
- 7) repeat the same on the other side: enter the tendon 1/3 diameter on ulnar side.
- 8) pass suture 1cm and exit tendon dorsally.
- 9) wrap suture underneath tendon.
- 10) re-enter tendon dorsally on radial side, parallel to exit site on ulnar side.
- 11) pull the needle through the length of the tendon to exit the cut end.
- 12) the needle will exit on the radial 1/3 of the tendon.
- 13) the 2 free ends will be on the radial side of the tendon. Gently apply traction so that the ends come together. Do not apply too much traction or the ends will bunch up. Secure with a knot that will be buried between the 2 tendon ends².



LEARNER MATERIALS

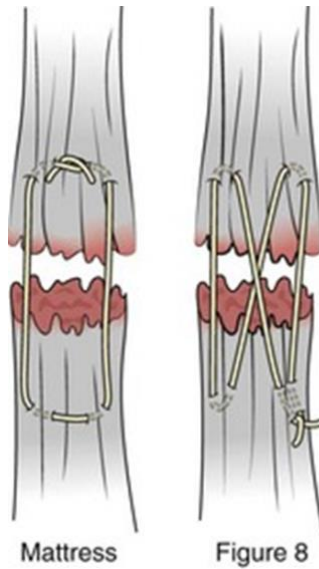


Illustration used with permission of Peter E. Sokolove, MD, FACEP and David K. Barnes, MD, FACEP
Horizontal Mattress and Figure-of-8 Sutures

If possible, you want to repair the tendon with 2 figure-of-8 or mattress sutures.

After Care

Update tetanus, if indicated.

Antibiotics for 3-5 days (tendon lacerations are a type of complex hand laceration)⁵.

- Keflex +/- Bactrim or Clindamycin.
- Dog bite: Augmentin, doxycycline, clindamycin+ciprofloxacin or clindamycin+sulfamethoxazole/trimethoprim.
- Human bite: Augmentin, clindamycin+ciprofloxacin or clindamycin+sulfamethoxazole/trimethoprim.

Splint affected digits or hand

- Zones 1-4: immobilized in IP full extension.
- Zones 5-8: immobilized in 30° wrist extension, 15° MCP flexion and IP full extension².

Follow up with hand/orthopedic surgeon in 24-48 hours. Early mobilization is needed for improved healing outcomes

Reasons to return to ED:

- Numbness/paresthesias
- If digits become cold or cyanotic
- Increased pain
- Signs/symptoms of infection



LEARNER MATERIALS

References

1. Simon RR, Sherman SC. Hand. In: Simon RR, Sherman SC, eds. *Simon's Emergency Orthopedics*. 6th ed. China: The McGraw-Hill; 2011:171-231.
2. Harper J, Harper S, Kalimuthu R. Extensor tendon repair. In: Reichman EF, ed. *Emergency Medicine Procedures*. 2nd ed. China: McGraw-Hill; 2013:490-495.
3. Ewen B, Hart, R. Hand trauma. In: Stone CK, Humphries RL, eds. *Current Diagnosis and Treatment Emergency Medicine*. 7th ed. New York, NY: McGraw-Hill; 2011:422-466.
4. Strauch R. Extensor tendon injury. In: Wolfe S, Hotchkiss R, Pederson W, Kozin S, eds. *Green's Operative Hand Surgery*. 6th ed. Philadelphia, PA: Elsevier; 2011:159-188.
5. Singer A, Hollander J. Postrepair wound care. In: Tintinalli JE, Stapczynski J, Ma O, Yealy DM, Meckler GD, Cline DM, eds. *Tintinalli's Emergency Medicine: A Comprehensive Study Guide*. 8th ed. New York, NY: McGraw-Hill; 2016:320-324.
6. Davenport M, Sotereanos. Injuries to the hand and digits. In: Tintinalli JE, Stapczynski J, Ma O, Yealy DM, Meckler GD, Cline DM, eds. *Tintinalli's Emergency Medicine: A Comprehensive Study Guide*. 8th ed. New York, NY: McGraw-Hill; 2016:1791-1800.

Resources

1. Levine B. *EMRA Antibiotic Guide*. 15th ed. Irving, TX: EMRA; 2013:64-78.
2. Ty J, Lattanza L. Extensor tendon injuries. In: Trumble TE, Rayan GM, Baratz M, eds. *Principles of Hand Surgery and Therapy*, 2nd ed. Philadelphia, PA: Saunders/Elsevier; 2010:229-243.