

# **UCLA**

## **UCLA Previously Published Works**

### **Title**

Ventricular structures must be understood during surgical restoration for heart failure

### **Permalink**

<https://escholarship.org/uc/item/8rp2s0ds>

### **Journal**

Scandinavian Journal of Surgery, 96(2)

### **ISSN**

1457-4969

### **Author**

Buckberg, G D

### **Publication Date**

2007

Peer reviewed

## VENTRICULAR STRUCTURES MUST BE UNDERSTOOD DURING SURGICAL RESTORATION FOR HEART FAILURE

G. D. Buckberg

Division of Cardiothoracic Surgery, David Geffen School of Medicine at UCLA,  
Los Angeles, California, U.S.A.  
California Institute of Technology, Pasadena, California, U.S.A.

Key words: Ventricular restoration; helical ventricular myocardial band; ischemic cardiomyopathy; non-ischemic cardiomyopathy; valvular cardiomyopathy; ventricular fiber orientation; SAVE; Pacopexy

### INTRODUCTION

The central theme of cardiac surgery is that alteration of structure improves function, and this concept is fundamental during surgical restoration of dilated hearts in cardiac failure. Adherence to this goal requires a clear knowledge of the normal conical ventricular form, recognition of how disease caused architectural deterioration towards a spherical shape that impairs performance, and why rebuilding structure returns function towards normal. The keynote knowledge governing surgical decisions relates to understanding how operative modifications affect left ventricle spatial relationships.

The conical pattern of normal cardiac size and shape is well known and the underlying spatial arrangements are closely linked to the helical ventricular myocardial band (1) comprised of a surrounding wrap of the basal loop with transverse fibers and an apical loop of reciprocal oblique fibers forming a spiral vortex at the apex as shown in Fig. 1A. The spherical configuration of the enlarged global ventricle widens the apical loop (Fig. 1B) by making the oblique apical loop fibers develop a transverse orientation that more closely resembles the horizontal fiber orientation of the basal loop.

The bioengineering infrastructure for this mechanical change in size and shape reduces ejection fraction, which is 60% with oblique fiber direction and lowered to 30% when fiber orientation is transverse (2). This architectural disadvantage limits deformation (or twisting capacity that is visible at operation

or by MRI recordings) to negatively impact the natural increment from mid wall to apex (3) and thus impair sequential contraction efficiency which limits performance by producing mechanical dyssynchrony. Furthermore, secondary mitral incompetence follows chamber widening and supplemental modifications during ventricular restoration that offset these changes will be described.

Symptoms of arrhythmia and cardiac failure, co-equal causes of mortality, worsen as ventricular size progressively increases. Surgical correction of the dilated heart requires changing the spherical configuration architecture into a more normal elliptical form (4), and simultaneously rebuilds more normal internal spatial components. The primary and secondary geometric events will be summarized and serve as the basis of developing procedures used to alter ventricular size, shape, the apical tip, papillary muscle inter space basal width, and inferior wall toward normal.

### THE DISEASE AND THE VENTRICLE AND SECONDARY MITRAL CHANGES

Enlarged ventricular size with the spherical shape becomes a *unifying theme of dilated cardiomyopathy*. (Fig. 2) The underlying pathologic processes responsible for spherical configuration range from a) ischemic disease causing an extensive postmyocardial infarction scar leading to secondary stretch of compensatory remote fibers within unscarred muscle, or global stretch from multiple small scars, but without a large asynergic region, b) non-ischemic disease causing distention stretch from volume loading following mitral or aortic valve incompetence, or c) non-ischemic cardiomyopathy destroying segments of regional myocardial fibers with secondary distention of remaining hypertrophied and thicker viable muscle.

The secondary changes that cause associated mitral incompetence include ventricular stretch that alters leaflet coaptation, widening of the mitral an-

---

#### Correspondence:

Gerald Buckberg, M.D.  
David Geffen School of Medicine at UCLA  
Division of Cardiothoracic Surgery  
62-258 Center for the Health Sciences  
Los Angeles, CA 90095-1701 U.S.A.  
Email: gbuckberg@mednet.ucla.edu

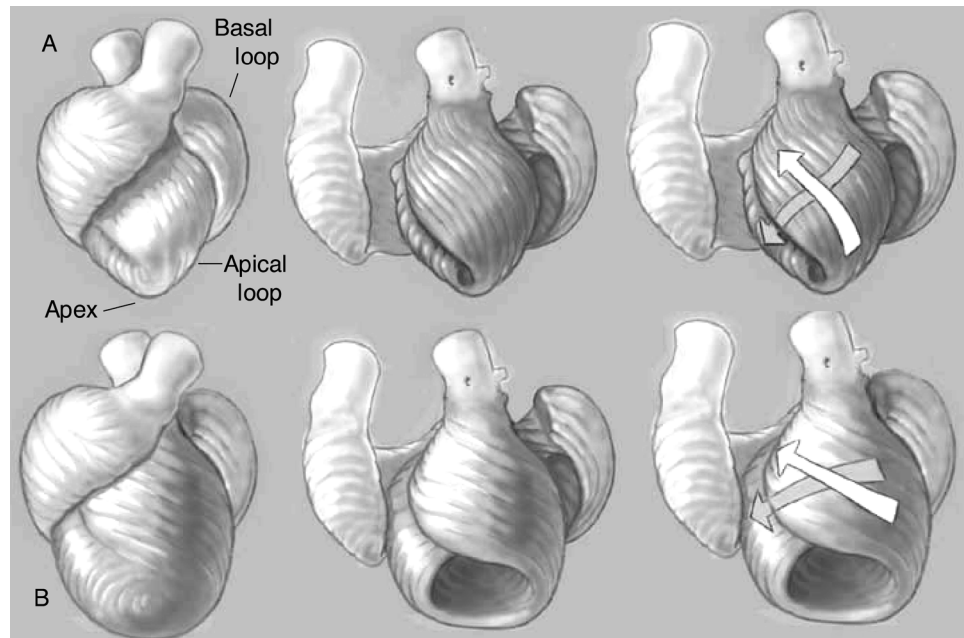


Fig. 1A. Cardiac configuration of the helical myocardial band. Note the transverse fibers of the basal loop and the oblique fibers of the apical loop. The arrows in the right figure show the  $\sim 60^\circ$  angulation in the normal heart. 1B. shows how the dilated heart changes the fiber angulation and the apical loop now has a more horizontal fiber angulation (shown by arrows), as demonstrated by the lower arrows.

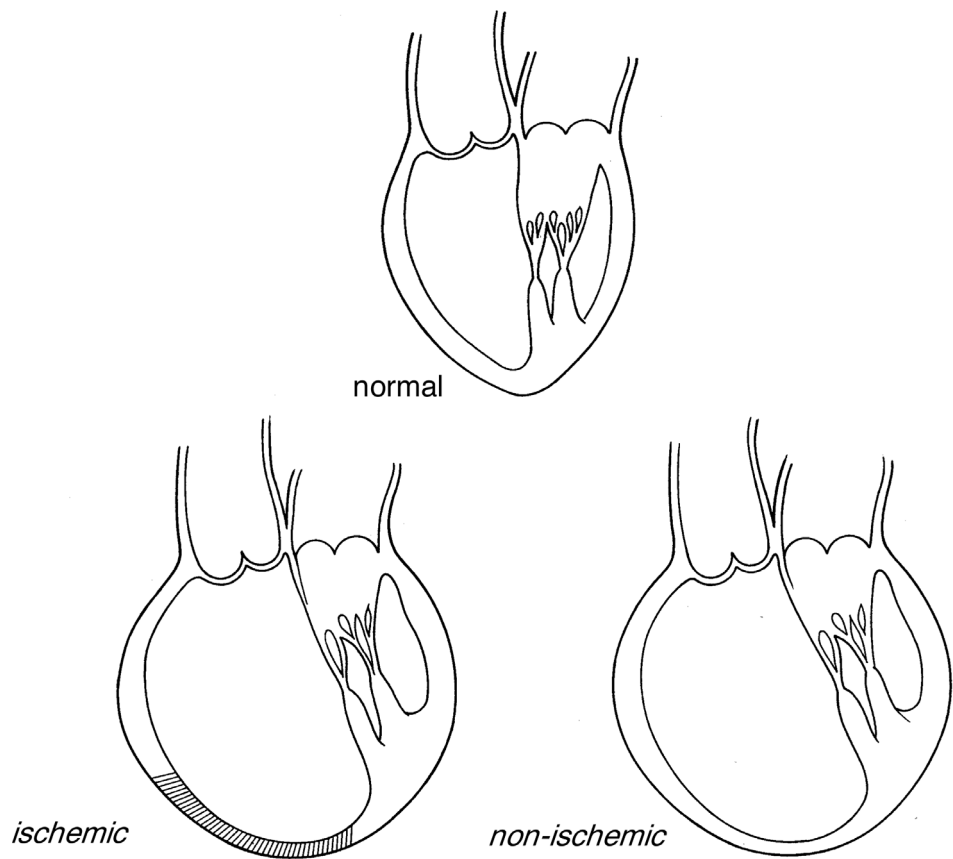


Fig. 2. Comparison between the normal elliptical shape (above) and the common spherical shape (below) that provides a unified form from ischemic (left) and non-ischemic (right) cardiomyopathy.

nulus that coincides with a larger cardiac base, and broadening the width between papillary muscle bases to amplify tethering to further limit leaflet coaptation. Each primary and secondary left ventricular alteration can be modified during surgical ventricular res-

toration, as the planning stage develops interventions that bring the altered spatial structure of ventricular size and shape back toward normal.

The concept that “form defines function” will be followed in describing how surgical structural

changes impact the functional consequences of cardiac failure (1). The "beating heart method" with higher perfusion pressure is used to rebuild the ventricular chamber, and integrated cardioplegia is employed for coronary grafting and valve repair before initiating ventricular reconstruction. Early improved cardiac efficiency occurs, since this myocardial protection strategy avoids cardiac damage during restoration.

#### ISCHEMIC DISEASE

Current surgical treatment of ischemic dilated cardiomyopathy addresses the disease-related causative factor. The scar perimeter identifies the junction between scar and surrounding normal muscle, and is the usual patch insertion positioning site. Selection of this structural position does not a) recognize the importance of ventricular chamber size, b) take into account that compensating remote muscle progressively stretches during the process of cardiac enlargement and, c) consider that long term prognosis worsens following restoration if preoperative end systolic volume index  $> 100\text{--}120\text{ ml/m}^2$  and post reconstruction LV volumes remain high (5). Furthermore, *dilated* hypokinetic left ventricles without scar do not currently undergo reconstruction, and late prognosis is poor despite coronary artery bypass grafting (CABG) since ventricular geometry is not approached at the initial procedure.

#### VALVE DISEASE

Valve replacement or repair alone is done in dilated hearts caused by mitral or aortic valve insufficiency. Although valve competence is successfully restored by replacement or repair procedures when preoperative ejection fraction is  $< 40\%$ , a progressively downward death trajectory exists during late follow-up in ischemic and non-ischemic disease (6). The mortality factors of progressive heart failure or sudden death from arrhythmias account for the discrepancy between "fixing the valve and losing the patient"; a symptom complex (CHF and sudden death) that precisely mirrors mortality factors after ischemic dilated cardiomyopathy.

#### NON-ISCHEMIC DISEASE

Non-ischemic cardiomyopathy from direct muscular involvement may stem from inflammation, sarcoidosis, idiopathic or other causes. Surgical restoration approaches have been virtually abandoned because partial left ventriculectomy (PLV) has led to early failure (7). The responsible mechanism may relate to the prior incorrect assumption that this was a homogeneous global disease, since the septum rather than the lateral wall is the predominant site disease site in 66% of patients that showed variability of disease distribution (8). Consequently, prior failure is likely related to excluding the wrong lateral wall segment, especially if it was the only healthy part. Current improved diagnosis skills by tagged MRI stud-

ies, and intraoperative echocardiographic testing (8) allows a) preresoration identification of predominant disease regions septum or lateral wall and, b) evolution of novel surgical protocols site specificity to determine how to rebuild ventricular form by excluding the septum or the lateral wall, as described by Suma and colleagues (9). The involved tissue contains *severely hypokinetic rather than akinetic or dyskinetic regions* and the procedure is called the Paco-pxy or Septal Anterior Ventricular Exclusion (SAVE) operation (8).

#### OPERATIVE PROCEDURES IN ISCHEMIC DISEASE

Transesophageal echocardiography is employed in all cases to assess regional wall movement and mitral valve function. The mitral valve is approached through an atrial incision after coronary revascularization in the cardioplegia-arrested heart. After coronary bypass and mitral valve intervention, the aortic cross-clamp is removed and the heart resumes contraction. Mean arterial pressure is maintained  $\geq 80$  mm Hg because of the empiric observation that contractility is optimum at these pressures. The *preoperative* functional assessment of the akinetic or dyskinetic ventricle determines the need for restoration, an intervention decision that is independent of normal epicardial surface and ventricular wall thickness, or cavity collapse during venting. Upon ventriculotomy, the scar may be trabecular, or absent in the early post-infarction phase. Consequently, it is sometimes impossible to make visual identification of the damaged area, and its point of connection to non-scarred muscle, but this distinction is made easily by palpation.

#### ANTERIOR VENTRICULAR RESTORATION

An incision is made anteriorly approximately 2.5 to 3.0 centimeters lateral to the left anterior descending artery and palpation is an easy way to determine the extent of myocardial necrosis (Fig. 3). A monofilament suture of 2-0 polypropylene, the so-called "Fontan suture" is passed through the endocardium of the left ventricle at the junction of contracting and non-contracting segments to create an oval opening or ledge onto which a patch can be secured (Fig. 3) after tightening, and its size measured (Fig. 4).

The oval opening can be closed with either the scar from the septal endocardium, or a Dacron or bovine pericardial patch. Sutures are placed in holders, similar to techniques employed during valve procedures, so that the methods are similar, but the vantage point is from the ventricle, rather than the aorta of left atrium. A pericardial patch with modifications of the sewing ring is used to secure homeostasis along the trabeculated ventricular surface (Fig. 4). Interrupted pledgeted braided 2-0 sutures are used to avoid tension as the patch is lowered toward the endocardial surface. Prior to securing the last sewing ring suture, the lungs are insufflated and the ventricular vent discontinued to permit filling of the

## Septal Exclusion

### Akinesia without Scar

Fig. 3a. Open left ventricle during restoration showing palpation to define the contracting and non-contracting muscle. 3b. shows Fontan suture in place and interrupted sutures through "neck" and into suture holders, quite similar to valve procedures.

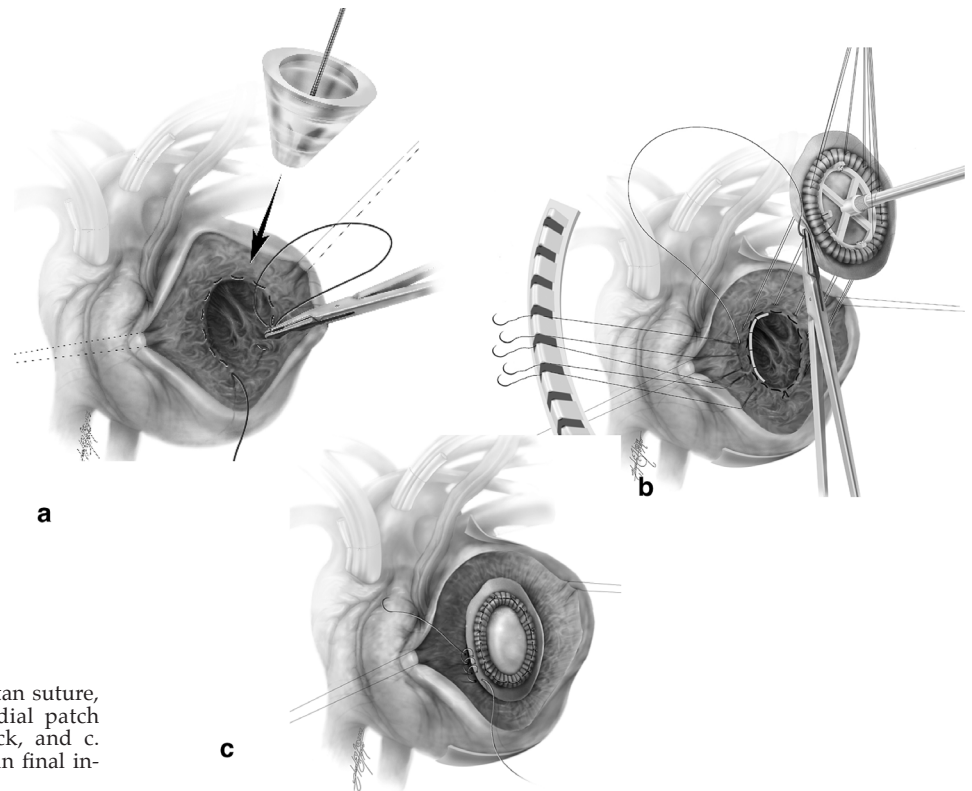
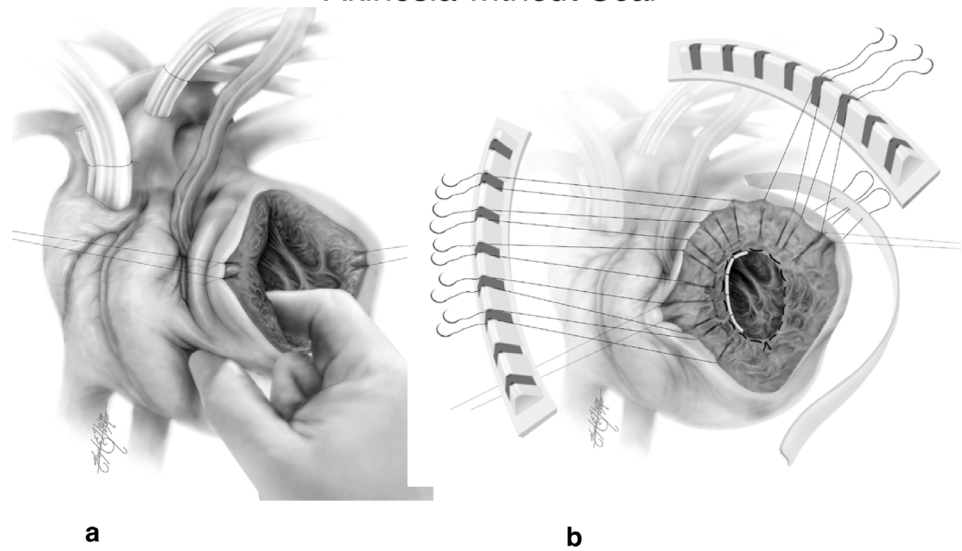


Fig. 4a. Sizing the oval from Fontan suture, b. shows placement of precardial patch with inner ring on surgical neck, and c. shows oblique pericardial patch in final intraventricular position.

ventricle. The rim of patch outside the sewing ring is then sewn to the endocardium with a running 3-0 polypropylene suture to further prevent leakage and the excluded muscle is closed in a vest over pants manner with a final running suture for hemostasis.

An important aspect of initial suture placement is recognition of the future alignment of the patch. In

order to achieve a final elliptical shape, the Fontan suture should be placed high onto the septum (Fig. 4). This creates an oblique orientation of the patch with respect to the mitral valve annulus. Failure to achieve this places the patch parallel to the mitral annulus creating a more spherical rather than elliptical ventricle that might alter subsequent function.

## Find Apex Match RV tip

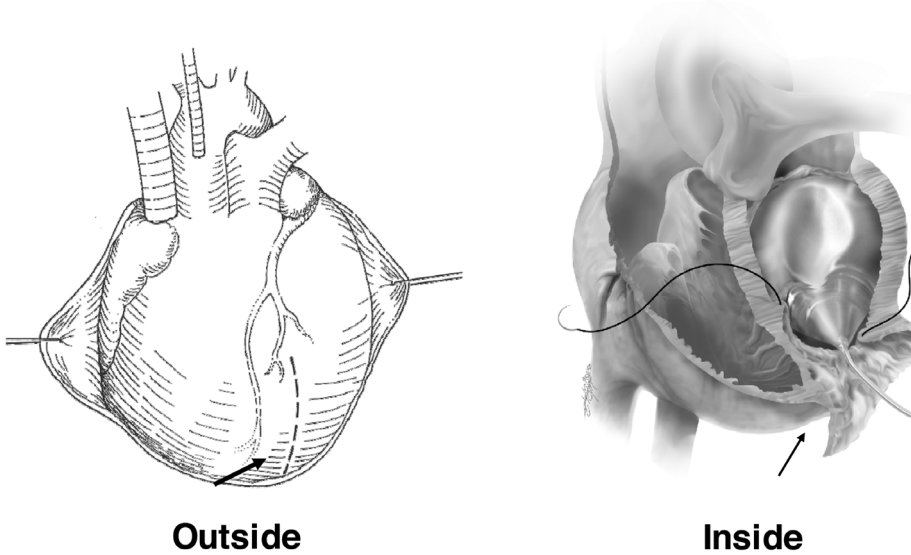


Fig. 5. Finding the left ventricular apex, either from the outside where it is adjacent to right ventricular apex, or from the inside with use of a conical intraventricular balloon.

## Create Apex

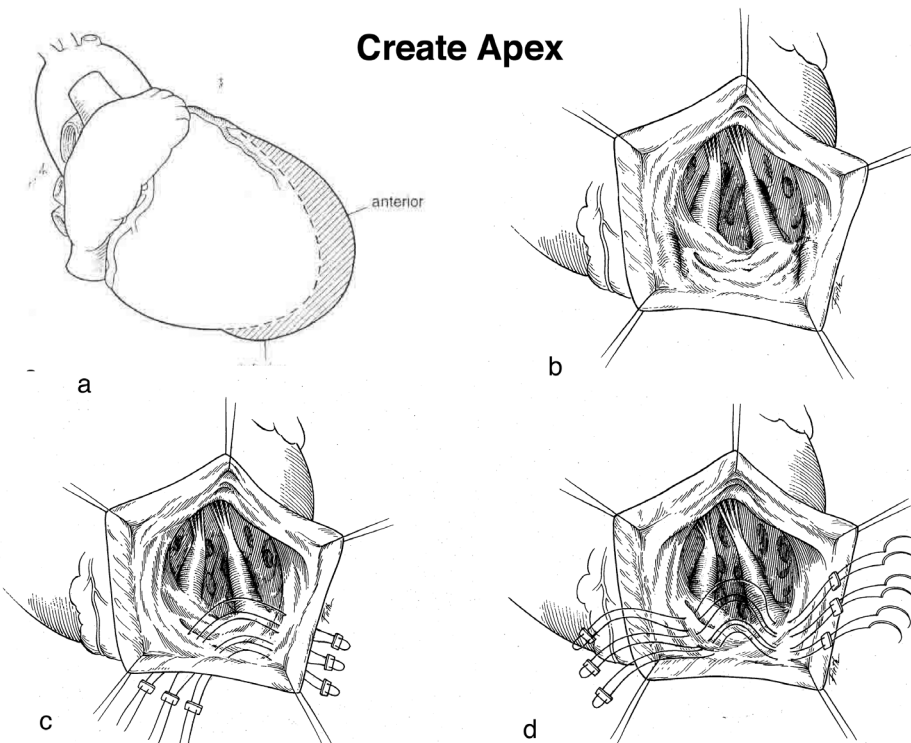


Fig. 6a. Wrap around anterior infarction and scar, 6b shows open left ventricle with inferior scar. Imbrication of the inferior wall from mattress sutures either the outside in 6c, or the inside in 6d.

### CREATION OF AN APEX

The left ventricular apex is identified by either recognizing that it is parallel to the right ventricle apex or by inserting a balloon device for apical site marking (Fig. 5). The standard technique is modified when the anterior scar extends beyond the apex to involve the

distal inferior wall, as occurs following infarction following occlusion of a long left anterior descending artery that wraps around the apex (Fig. 6). Identification of the inferior wall to be modified is made readily from visualization of the right anterior view after venticulography.

The incision is never extended beyond the apex,

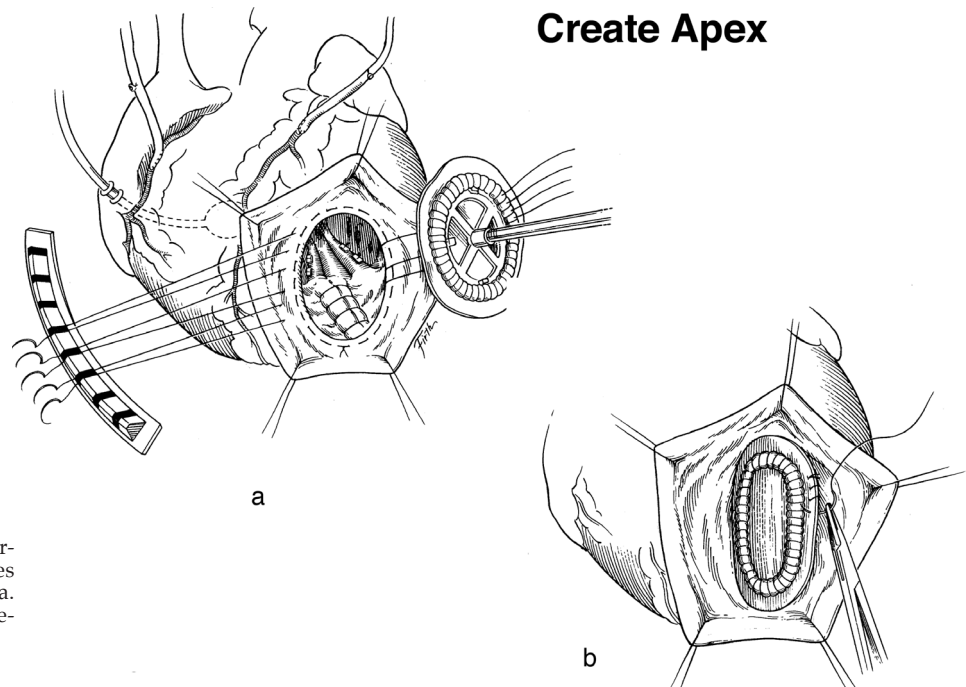


Fig. 7. Creation of LV apex by securing the imbricating inferior sutures and using the tip as the apex in 7a. Placement of oblique patch to rebuild a conical shape in 7b.

since inferior wall palpation defines the site to become excluded as described below. An elliptical ventricle is created by imbricating the inferior wall (Fig. 6) to create an apex either by placing sutures from outside to in or from inside to out to render an oblique area for the Fontan suture (Fig. 7). This imbrication suture may also narrow the widened papillary muscle insertion sites if the posterolateral papillary muscle is at the apex; and is an integral part of mitral valve repair since it increases leaflet coaptation surface.

#### NARROWING THE WIDENED BASES OF THE PAPILLARY MUSCLES

The bases of the papillary muscles are made broader and displaced in a posterior and cephalad direction with wrap around anterior infarctions (Fig. 8A) or following ventricular stretch from marked global dilation. Fig. 8B shows how treating this widening by placing sutures between the papillary muscles and stretched intervening muscle from within the ventricle will narrow the distance between papillary muscle bases and reform the normal architectural configuration.

This papillary muscle intervention deals with one of the geometric aspects that cause *secondary mitral insufficiency*. Ventricular restoration reduces chamber size and shape toward normal and simultaneously addresses the second component of leaflet tethering that is caused by chamber from dilation. The third component is a widened mitral annulus, whereby the extent of leaflet coaptation is impaired by stretching the annular attachment. Widening of the ventricular base is responsible for this secondary valve incompetence, and this alteration is evident by echo cardio-

graphic measuring of annular size preoperatively. Narrowing of the base is produced by downsizing the annulus by placing a 28 size annular ring to thereby compress the cardiac base (Fig. 9).

#### INFERIOR VENTRICULAR RESTORATION

Restoration of the inferior ventricle following large dominant right coronary artery infarction follows the same general principles, but addresses the geometric components of the base, free wall and septum (Fig. 10). Mitral regurgitation is frequent because the infarcted dilated base widens the mitral annulus, and may scar the papillary muscles; valve replacement rather than repair is usually selected. Cardiac retraction often causes aortic insufficiency, so the procedure is done using aortic clamping associated with either a) the beating heart by perfusing distal grafts, opening the mammary artery and giving retrograde blood (making the proximal connection later), or b) by employing integrated blood cardioplegia.

The incision (Fig. 10) is made lateral to the posterior descending artery and carried to within one centimeter of the mitral annulus and distally toward the apex, keeping on the septal side of the papillary muscle. The mitral valve may be replaced through this incision.

The operation excludes non-contracting segments including a portion of the septum either by direct closure or employing a triangular patch as described by Dor (10). We use Teflon-backed bovine pericardium. The defect is triangular and this cardiac defect is narrowed by a "retriangulation method" (Fig. 11), that is accomplished by placement of a series of imbricating sutures along the 3 edges of the scar to reduce its size and then covering this new triangular

Fig. 8A

**Widened PPM Dimension**

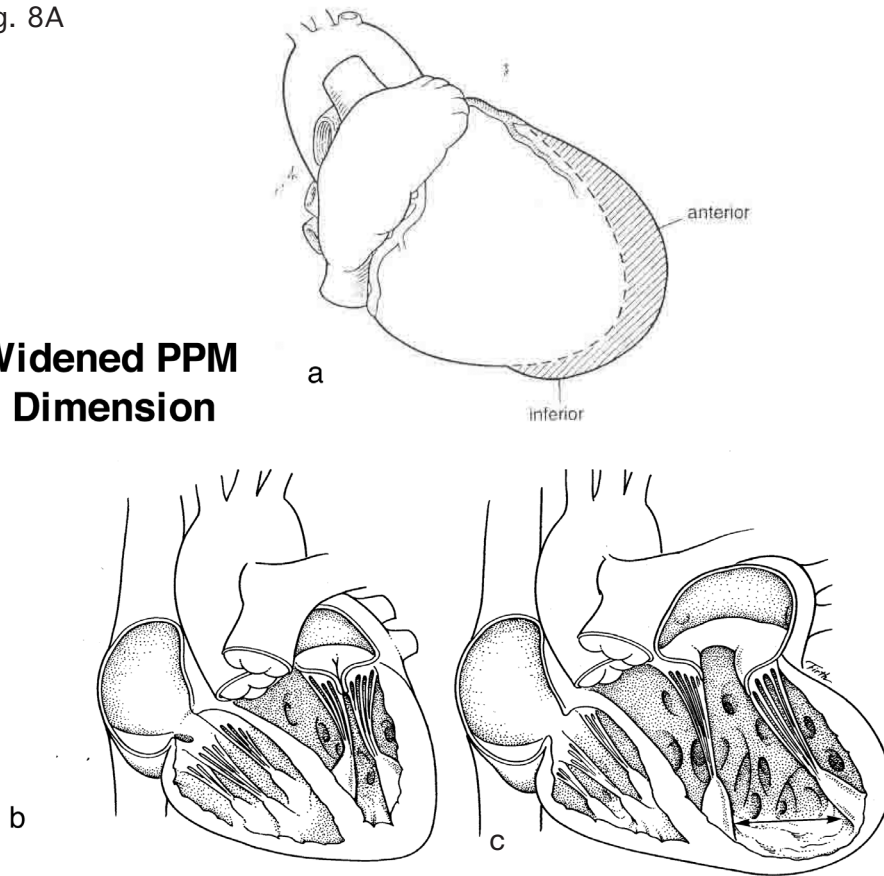


Fig. 8A. Wrap around anterior scar from a wrap around left anterior descending artery infarction in a. Demonstration of the normal width between papillary muscles in b, and widening from distance between papillary muscle bases is shown in c.

Fig. 8B

**Narrow PPM Dimension**

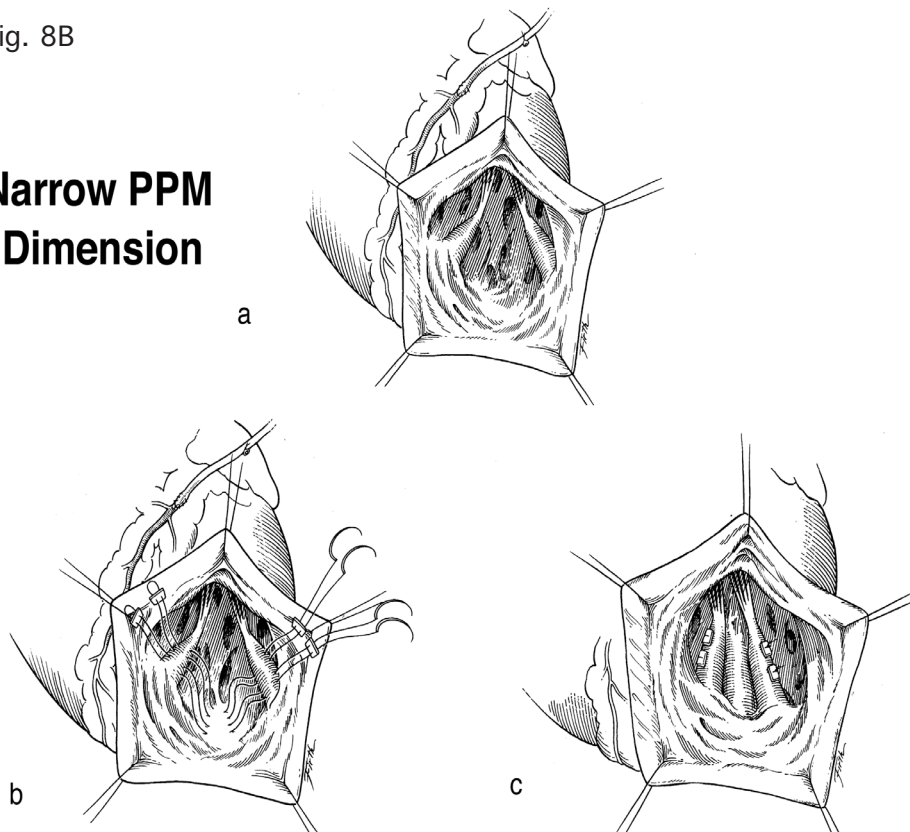


Fig. 8B. Narrowing of the widened dimension between bases of papillary muscles is shown in a. Placement of mattress sutures between the bases of the papillary muscles and the ventricular muscle between the bases in shown in b, and securing these sutures to restore the normal dimension between the papillary muscle bases in c.



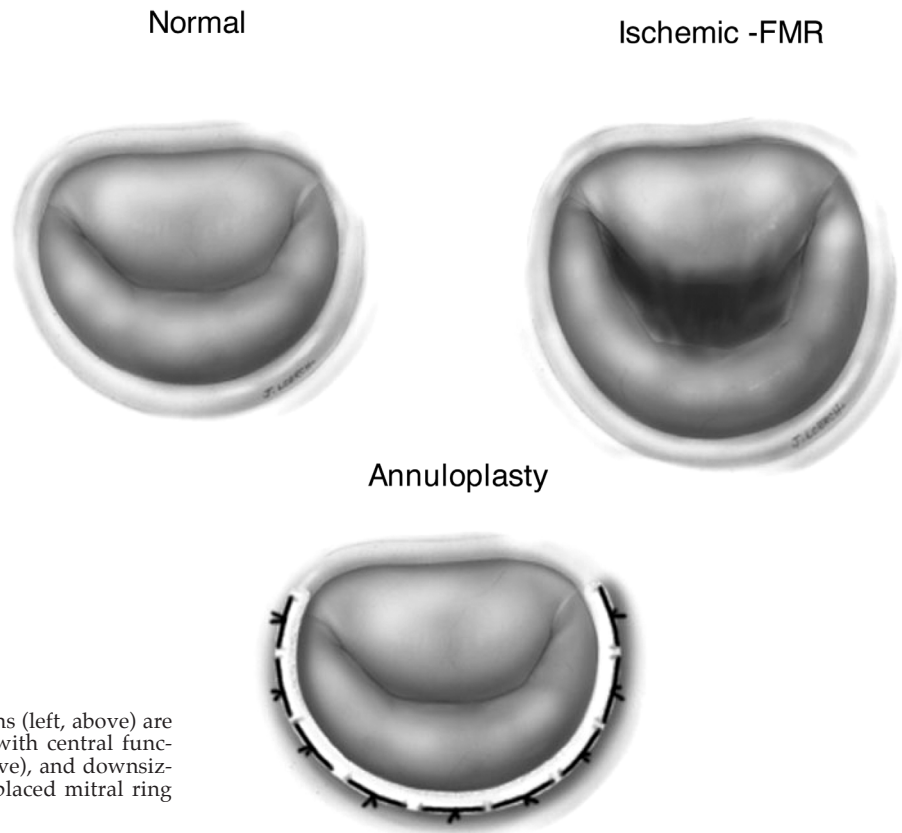


Fig. 9. The normal annular dimensions (left, above) are compared to the widened annulus with central functional mitral regurgitation (right above), and downsizing the annulus with a posteriorly placed mitral ring shown below.

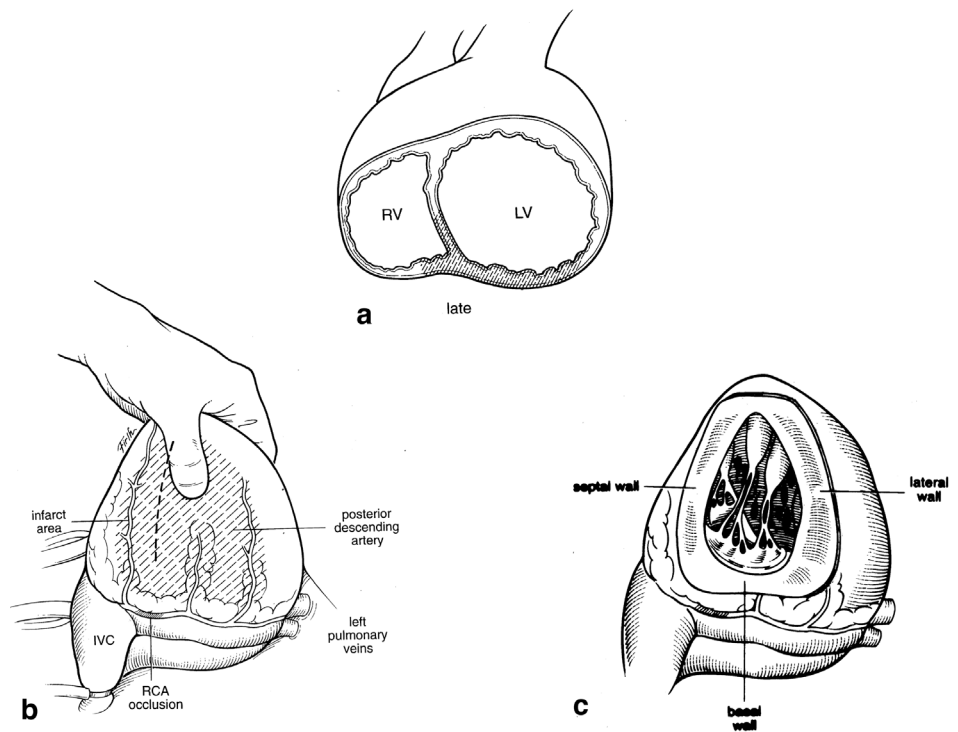


Fig. 10. Scar involving the base, septum and lateral wall following inferior infarction in a. Site of inferior wall incision parallel to posterior descending coronary artery in b. Exposure of intra-ventricular cavity following incision in c.

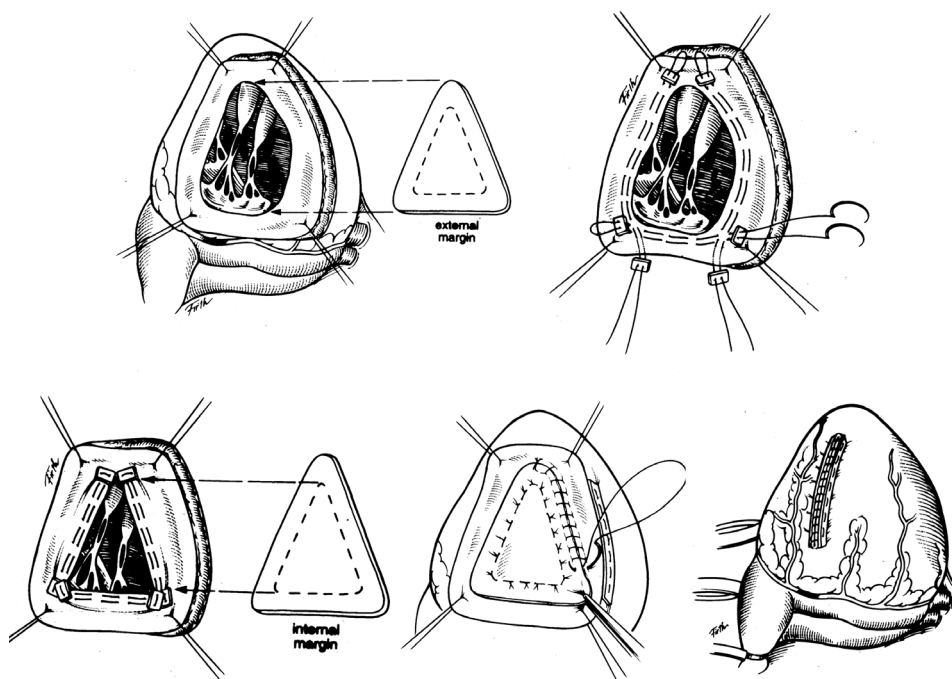


Fig. 11. Triangular patch that conforms to the base of the infarct region shown in upper left. Insertion of double arm imbricating sutures in base, septum and lateral wall in upper right. Securing the imbricating suture to make a smaller triangle (retriangulation) in lower left. Patch placement with sewing the patch rim for hemostasis (center) and ventricular closure on lower right.

opening with a patch that conforms to its new dimension (10) thereby returning ventricular geometry to a conical form.

#### RESTORATION AND CONICAL ARCHITECTURE; FORM VERSUS DISEASE

##### ISCHEMIC DISEASE WITH SCAR

Conventional goals during reconstruction of the left ventricle in ischemic disease are directed toward excluding scar. This objective does not account for the secondary stretch of remote muscle, the principal cause of progressive dilation with worsened function as stretching progresses. Retention of spherical shape may persist (Fig. 12) since extensively stretched remote muscle stretch is retained and postoperative ventriculograms may display a smaller, but spherical chamber.

An alternate approach in dilated ischemic cardiomyopathy after anterior infarction is insertion of an oblique patch between the apex and high septum (Fig. 12), just beneath the aortic valve to render a conical form that resembles the shape achieved by Pacopexy or SAVE procedures in non ischemic cardiomyopathy (Fig. 13). The result is placement of sutures in viable septum above the scar to render a conical shape that is similar to that reported by Suma, and displayed in Fig. 13. There is no dynamic action of the patch, which may become a "curtain within the LV chamber" that is covered by the viable muscle closed over its surface. The geometric objective aims to reconstruct form, instead of making visible disease become the sole guide to decision making.

##### ISCHEMIC DISEASE WITHOUT SCAR

The spherical geometry of the globally hypokinetic dilated failing heart resembles the shape changes noted with extensive scar. Malfunction is related to spherical global shape and is not improved by simply restoring blood supply so that consideration of vessel and ventricle must enter the decision process.

The surgical problem is restoration for form, not only correction of causative disease. Consequently, the suggested reconstructive procedure excludes marginally scarred muscle, rather than the normal muscle above the anterior scar that was previously described (Fig. 5). This more aggressive approach (Fig. 14) generates a conical chamber by using the same *oblique* patch angulation placement technique employed in a) the prior section with ischemic disease (Fig. 12) and b) during site selection for non ischemic disease (Fig. 13) and was successfully used clinically in a small series by Bockeria and associates at the Bakoulev Institute in Moscow (11).

##### VALVE DISEASE WITHOUT SCAR

Progressive spherical dilation is a hallmark event following prolonged volume loading after chronic aortic or mitral insufficiency, and is associated ~70% late mortality following AVR if <40% preoperative ejection fraction exists. (6) Chronic CHF and sudden death cause mortality, thereby reproducing the same fatal consequences of dilated hearts after non ischemic and ischemic disease. These adverse events occur despite histology showing only normal muscle with increased collagen.

Failure to change the natural time course of pro-

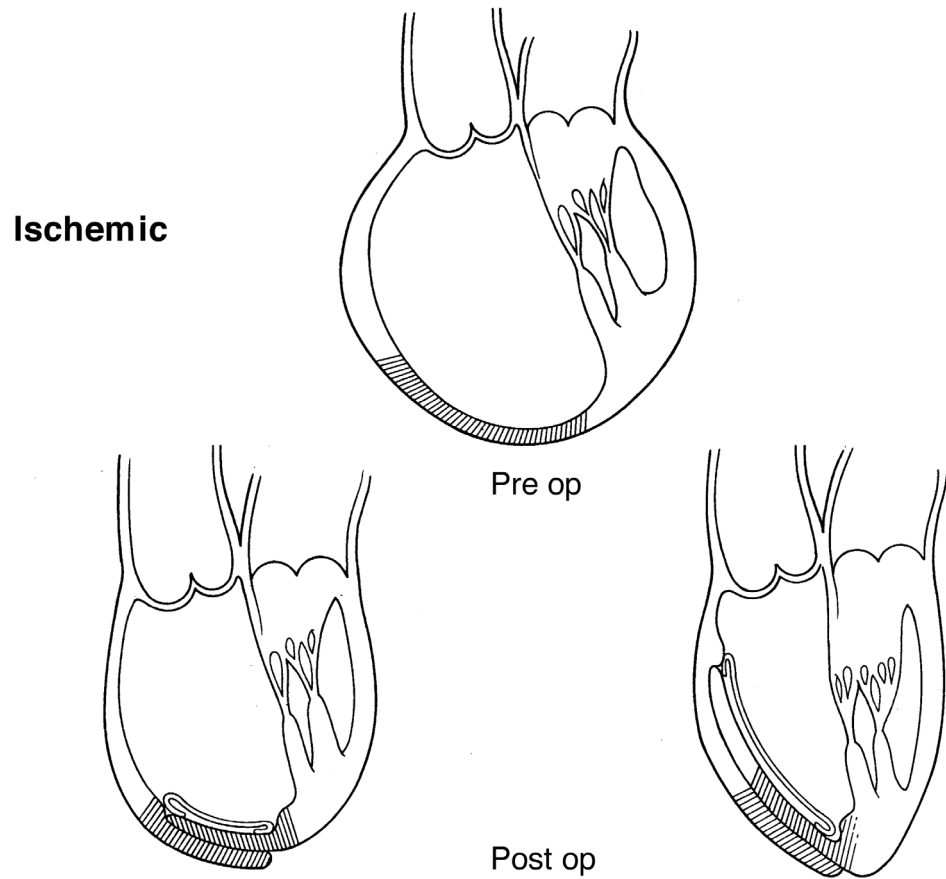


Fig. 12. Comparison of treatment of the dilated ischemic cardiomyopathy (above) by addressing the disease (lower left) and leaving a spherical shape, or doing the SAVE or Pacopexy (lower right) and rebuilding an elliptical shape. Note that the patch is placed into the septum that does not have scar, and the point of placement is above the scarred region in mid septum.

### Pacopexy / SAVE Procedure

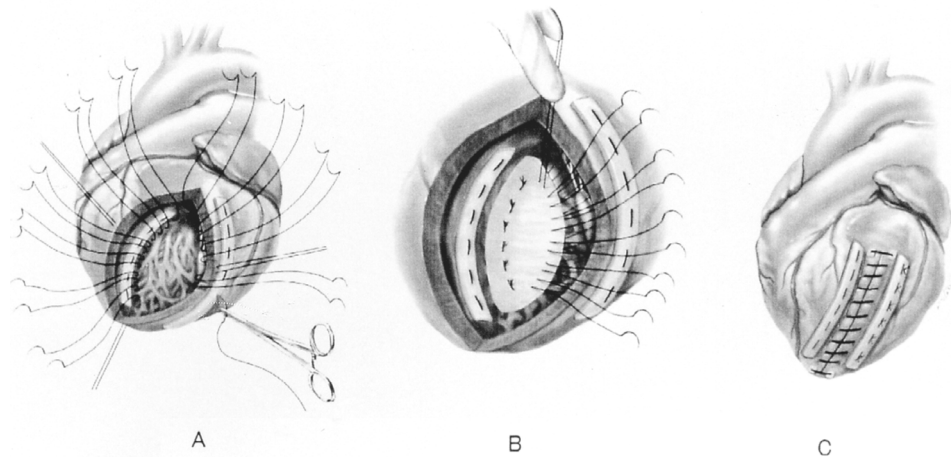


Fig. 13. Pacopexy or SAVE procedure with open left ventricle and interrupted mattress sutures in septum and LV free wall (A), insertion of oblique patch from apex to high septum, using Teflon strip in (B), and closure to rebuild a conical chamber in (C).

gression of heart failure by successful valve replacement, suggests a “*valve and ventricle*” approach should be considered that includes rebuilding the conical geometry (Fig. 15), rather than adhering to the conventional restriction that surgical correction should *only* address the valve disease. Consequently, appli-

cation of the SAVE or Pacopexy restoration method (found useful in ischemic and diffuse non-ischemic disease) might create a surgical solution. Insight into the value of adding restoration to valve correction is drawn from Batista, who observed best results after ventricular restoration in patients with dilated hearts

**Diffuse Ischemic**

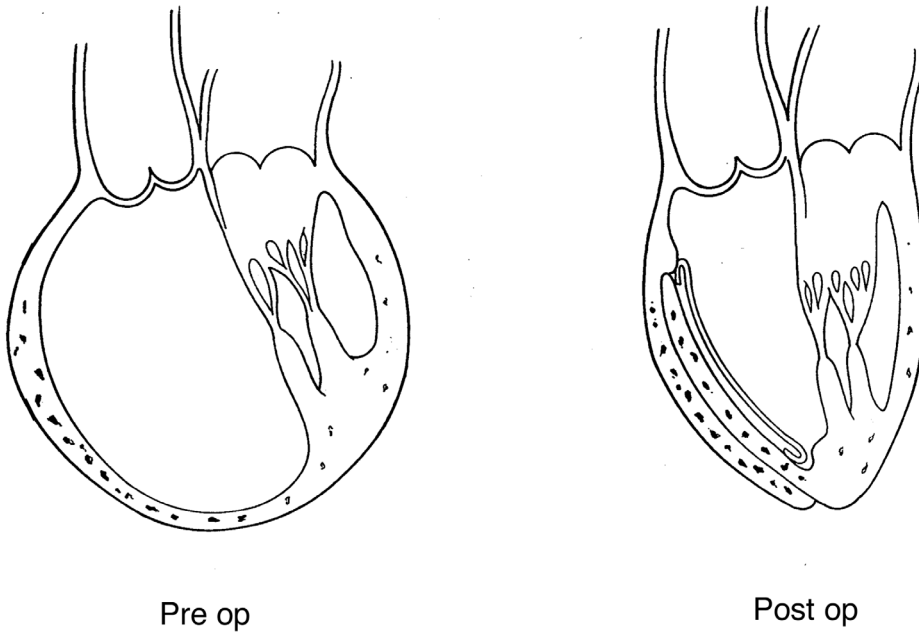


Fig. 14. Left ventricular restoration in dilated cardiomyopathy in ischemic disease without discrete scar. Note the SAVE or Pacopexy procedure is used to make the spherical chamber become elliptical. A patch is placed between the apex and septum to reconstruct a conical chamber.

**Unified Concept**

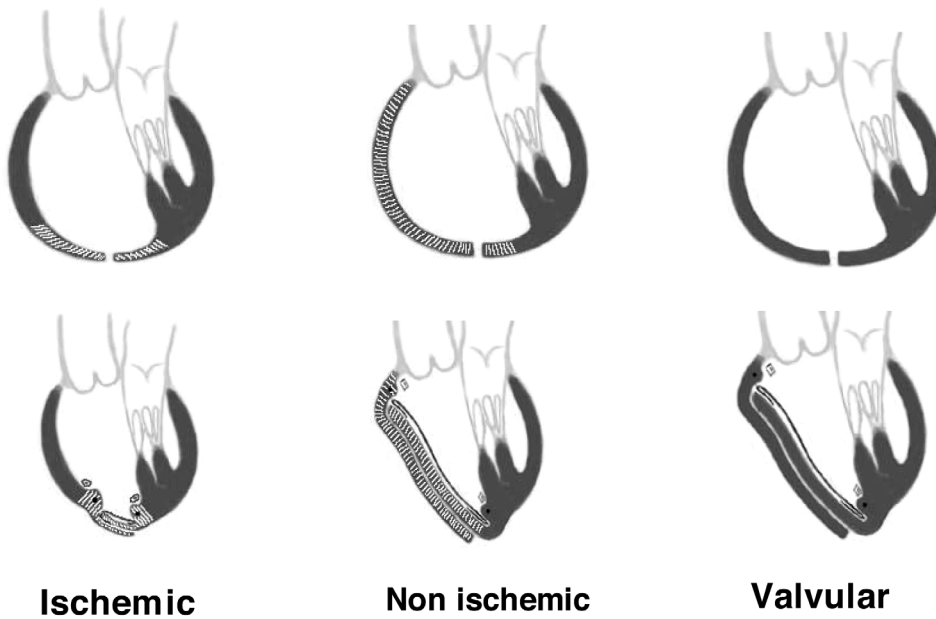


Fig. 15. Unified concept with the dilated spherical left ventricular shape in either ischemic, non-ischemic or valvular cardiomyopathy (above). Geometrically changing shape to create a conical of elliptical chamber in either ischemic, non-ischemic or valvular disease to alter structure toward normal as shown here.

with valve disease (12).

A novel *valve/ventricle approach* may evolve if this geometric solution provides a successful solution to the current adverse results of addressing only the valve in dilated valvular cardiomyopathy.

**IMPLICATIONS WITH HELICAL FIBER ORIENTATION**

The helical architecture of the normal heart has been confirmed by strain relationships using MRI (13), corrosion casts showing spiral architecture (11) and by

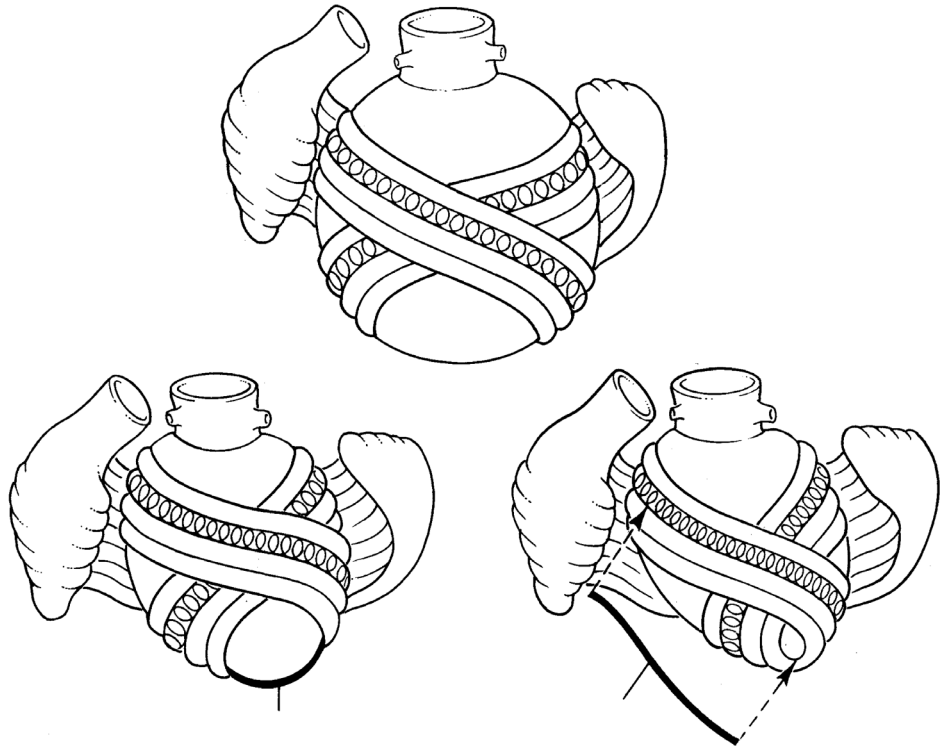


Fig. 16. Fiber orientation in dilated spherical ventricle (above), whereby the “coils within coils” fiber orientation is more transverse and leads to reduced function. Anticipated changes in fiber orientation are shown below. A spherical form may persist by placing the patch in a flatter (lower left), rather than oblique direction (lower right). This oblique configuration is the desired result of treating “form versus disease”.

sonomicrometry crystals (14); each pattern reflects the normal oblique fiber orientation that conveys maximum force during ejection and suction. These observations coincide with the helical heart configuration shown in Fig. 1A, and change when dilation alters this architecture (Fig. 1B) because of flattening of the double helical arms of the apical loop. These sequential shortening patterns make the fibers twist, like coils within coils (Fig. 16) to closely link with functional changes in ventricular shape following reconstruction, with methods that address “disease versus form”. Future comparisons of ventricular function by MRI tagging are needed to define the extent of deformation, and evaluate the validity of this form reconstruction objective.

#### CONCLUSIONS

Heart failure from dilated cardiomyopathy is associated with a geometric change in the size and shape toward larger volume and conversion from the normal conical to spherical configuration. The sphere becomes a unifying geometric (1) contour that may arise from ischemia, valve insufficiency or myocyte disease. Restoration of the conical contour is possible by decisions that alter ventricular configuration, thus becoming a supplement to correction of the underlying causative factor. Spatial knowledge of geometry allows development of intraoperative planning to change structure by restoring more normal apex and base size and shape dimensions as well as altering the architectural events that amplify secondary mitral insufficiency by rebuilding the cardiac base and papillary muscles and limiting ventricular stretch. Subse-

quent testing of these innovative procedures is needed to determine their validation beyond those established for ischemic disease. Understanding form and reconstructing more normal architecture is a surgical approach for heart failure that could change the future of cardiac surgery.

#### REFERENCES

1. Buckberg GD: Form versus disease: optimizing geometry during ventricular restoration. *Eur J Cardiothorac Surg* 2006;29 Suppl 1:S238–S244
2. Sallin EA: Fiber orientation and ejection fraction in the human ventricle. *Biophys J* 1969;9:954–964
3. Bogaert J, Rademakers FE: Regional nonuniformity of normal adult human left ventricle. *Am J Physiol Heart Circ Physiol* 2001;280(2):H610–H620
4. Buckberg GD, Coghlan HC, Torrent-Guasp F: The structure and function of the helical heart and its buttress wrapping. V. Anatomic and physiologic considerations in the healthy and failing heart. *Semin Thorac Cardiovasc Surg* 2001;13 (4):358–385
5. Di Donato M, Toso A, Maioli M, Sabatier M, Stanley AW Jr, Dor V, and the Restore Group: Intermediate survival and predictors of death after surgical ventricular restoration. *Semin Thorac Cardiovasc Surg* 2002;13 (4):468–475
6. Durate IG, Murphy CO, Kosinski AS, Jones EL, Craver JM, Gott JP, Guyton RA: Late survival after valve operation in patients with left ventricular dysfunction. *Ann Thorac Surg* 1997;64 (4):1089–1095
7. Starling RC, McCarthy PM, Buda T, Wong J, Goormastic M, Smedira NG, Thomas JD, Blackstone EH, Young JB: Results of partial left ventriculectomy for dilated cardiomyopathy: hemodynamic, clinical and echocardiographic observations. *J Am Coll Cardiol* 2000;36 (7):2098–2103
8. Suma H: Left ventriculoplasty for nonischemic dilated cardiomyopathy. *Semin Thorac Cardiovasc Surg* 2001;13 (4):514–521

9. Suma H, Horii T, Isomura T, Buckberg G: A new concept of ventricular restoration for nonischemic dilated cardiomyopathy. *Eur J Cardiothorac Surg* 2006; 29 Suppl 1:S207–S212
10. Menicanti L, Dor V, Buckberg GD, Athanasuleas CL, Di Donato M: Inferior wall restoration: anatomic and surgical considerations. *Semin Thorac Cardiovasc Surg* 2001;13 (4):504–513
11. Bockeria L, Gorodkov A, Dorofeev A, Alshibaya M, RESTORE Group: Left ventricular geometry reconstruction in ischemic cardiomyopathy patients with predominantly hypokinetic left ventricle. *Eur J Cardiothorac Surg* 2006;29 Suppl 1:S251–258
12. Kawaguchi AT, Ujiie T, Koide S, Batista RJV: The Curitiba experience – initial experience with partial left ventriculectomy. Eds. Akira T and Kawaguchi AT. *Partial left ventriculectomy: Its theories, results, and respectives*. pp. 59–75. 1998. Tokyo, Elsevier
13. Jung BA, Kreher BW, Markl M, Hennig J: Visualization of tissue velocity data from cardiac wall motion measurements with myocardial fiber tracking: principles and implications for cardiac fiber structures. *Eur J Cardiothorac Surg* 2006; 29 Suppl 1: S158–S164
14. Buckberg GD, Castella M, Gharib M, Saleh S: Structure/function interface with sequential shortening of basal and apical components of the myocardial band. *Eur J Cardiothorac Surg* 2006;29 Suppl 1:S75–S97

Received: March 7, 2007