

UC Davis
Cardiovascular Medicine

Title

Volumetric intracardiac echocardiography (VICE) is feasible for procedural guidance of transcatheter mitral edge-to-edge repair (mTEER)

Permalink

<https://escholarship.org/uc/item/00821283>

Authors

Tso, Jade
Pham, Tai
Singh, Gagan D

Publication Date

2023

Data Availability

The data associated with this publication are not available for this reason: N/A

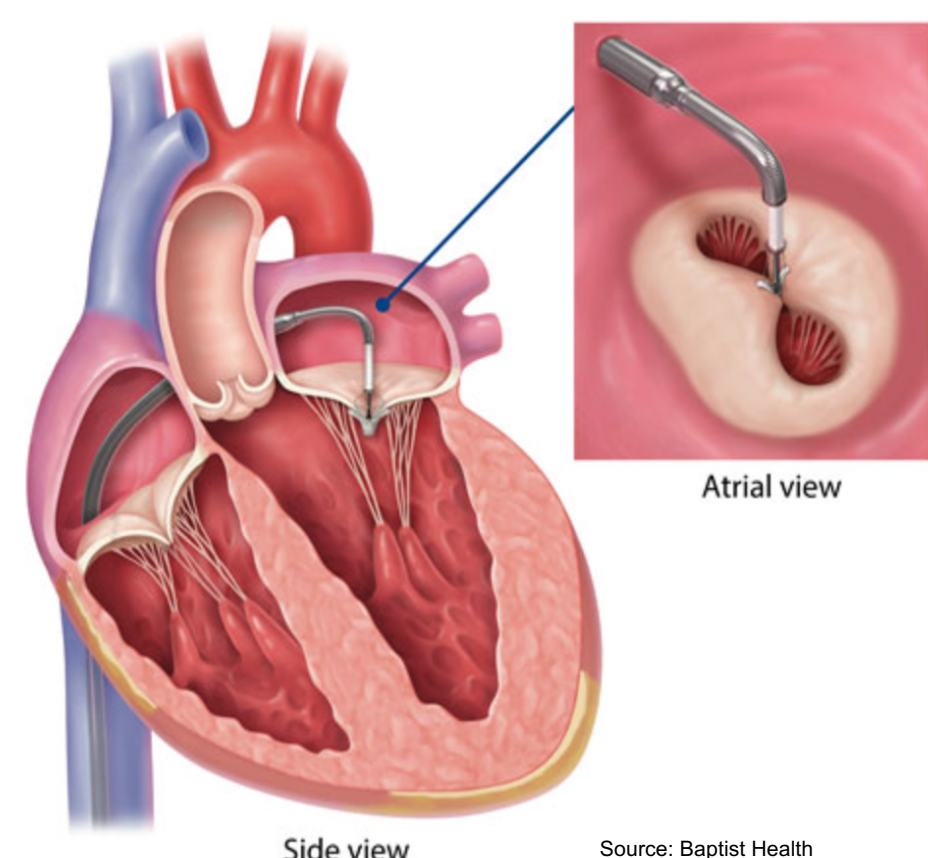
Volumetric intracardiac echocardiography (vICE) is feasible for procedural guidance of transcatheter mitral edge-to-edge repair (mTEER)

Jade Tso ^{1,2}, Tai Pham ², Gagan D. Singh ²

¹ University of California Davis, School of Medicine; ² University of California Davis, Division of Cardiovascular Medicine

Introduction

- Transcatheter mitral edge-to edge repair (mTEER) is a minimally invasive, catheter-based therapy used to treat mitral regurgitation
- Gold standard for intraprocedural guidance of mTEER is transesophageal echocardiography (TEE)
- 4-dimensional volumetric intracardiac echocardiography (vICE) is an alternative imaging modality that provides volumetric images with multiplanar reconstruction for guidance during structural heart procedures



mTEER is a transcatheter procedure using clips to improve co-aplaption as a treatment of mitral regurgitation, similar to surgical Alfieri stitch.

Design/Sample

- **Single arm retrospective case series**
- **Time Period:** June 2019 – March 2022
- **Population:** Data collected from 12 patients from a multicenter registry comprised of 3 different academic centers
- **Summary of Data Collected:**
 - Demographic data
 - Contraindications to TEE
 - Baseline echocardiogram
 - Procedural data
 - Post-mTEER assessment
 - Major adverse cardiovascular events
- **Statistical Analysis:** Data expressed as mean ± standard deviation for continuous variables and as a percentage for categorical variables.

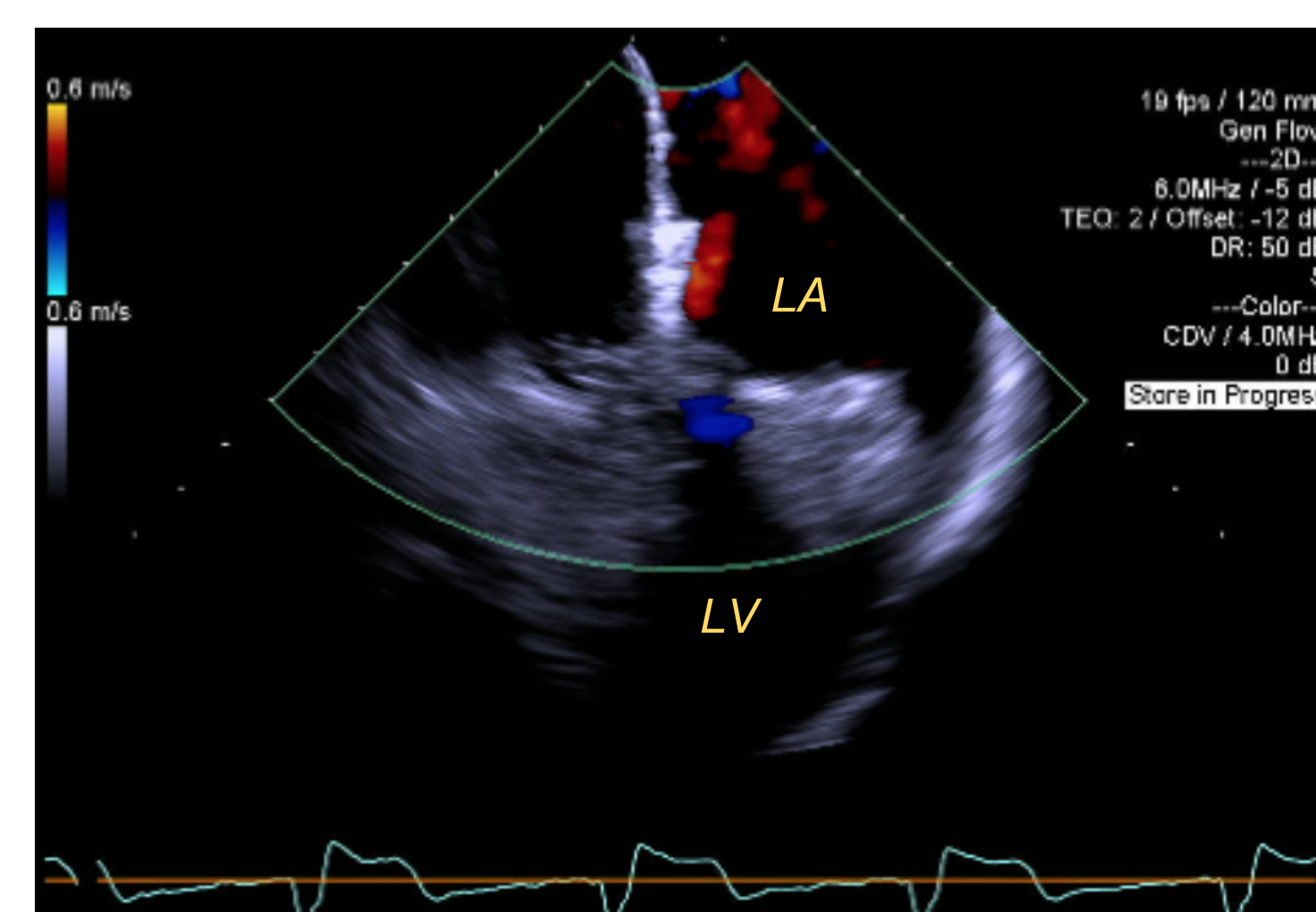
Results

Table 1: Demographics	N = 12
Age	71 ± 17
Male sex (%)	41.6
Hypertension (%)	83.3
Diabetes (%)	25
Hyperlipidemia (%)	58.3
Atrial Fibrillation (%)	41.7
Systolic Heart Failure (%)	16.7

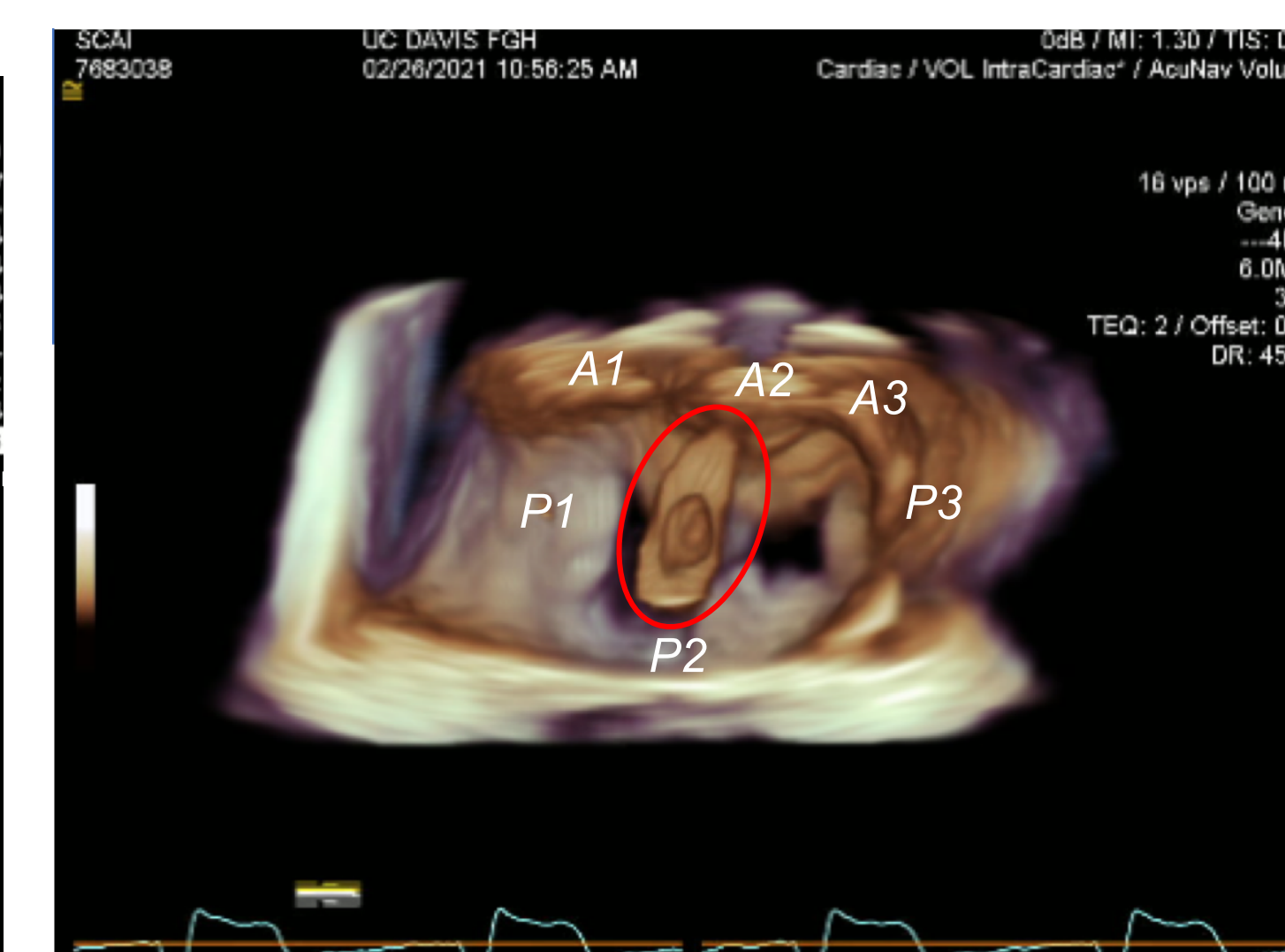
Table 2: Contraindications to TEE	
Spinal Disease (%)	16.7
Esophageal/Gastric Disease (%)	58.3
Sedation Complications (%)	8.3
Poor TEE Windows (%)	16.7

Table 3: Procedural Data	
ICE Catheter Manufacturer	75% AcuNav / 25% VeriSight
Procedural Success Rate	100%
Procedure time (Minutes)	72.8 ± 33.05
Fluoro Time (Minutes)	34.8 ± 10.9
Fluoroscopy Dose (mGy)	134.3 ± 59.8
Pre-Clip LA Pressure (mmHg)	16.8 ± 3.4
Device Location	100% Central
Number of Devices Used	75% 1 device / 25% 2 devices
Pre-Clip V-Waves (mmHg)	29.8 ± 9.2
Post-Clip LA Pressure (mmHg)	12.2 ± 2.8
Post-Clip V-Waves (mmHg)	16.8 ± 3.0

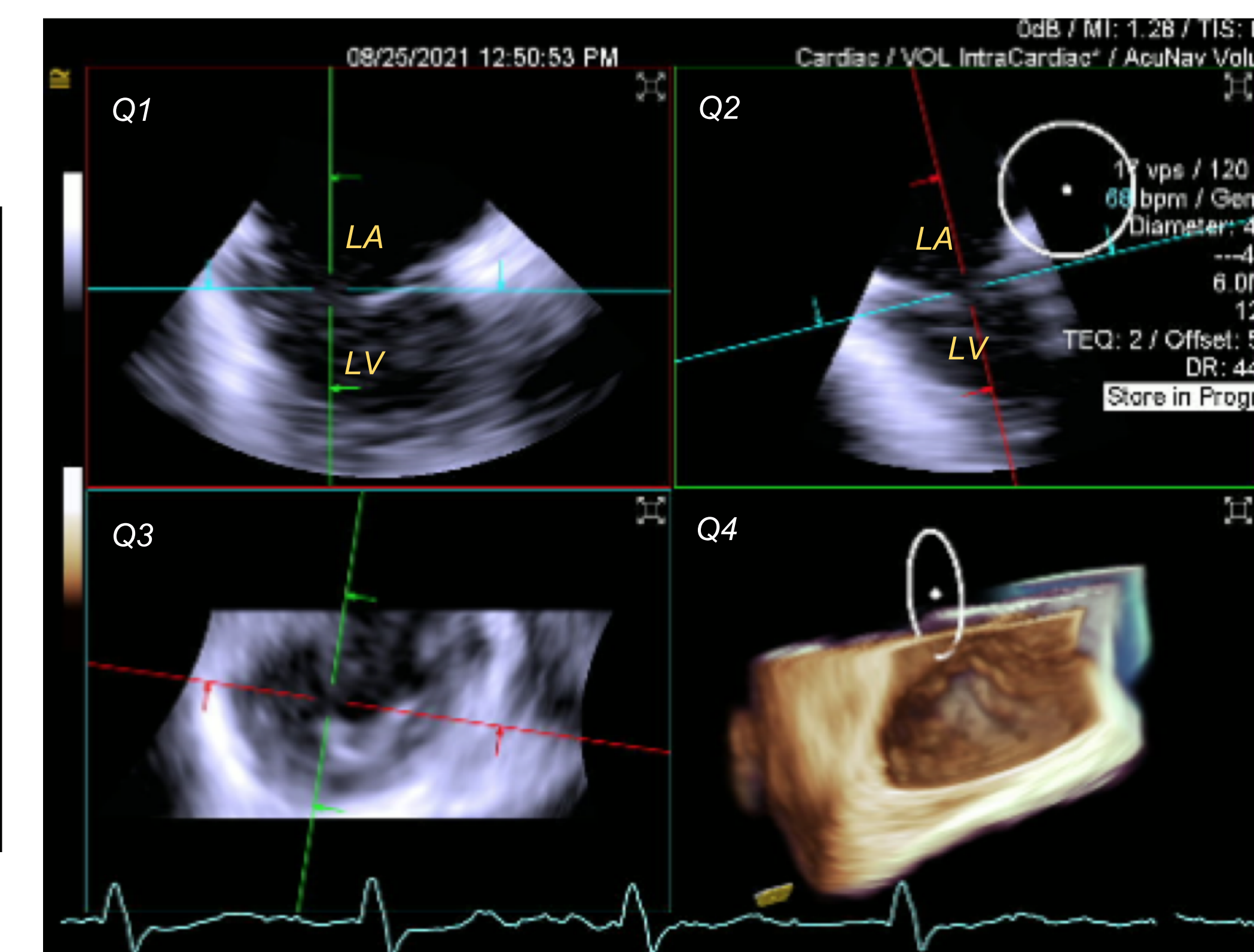
Major Cardiovascular Adverse Events: There were no major adverse events during hospitalization or during the 30 day follow up.



Left atrial vICE view with deployment of clips at A2/P2 scallops.



3D reconstruction of an face view with labelled scallops. The red oval indicates mitral clip delivery system. Segments of the anterior (A1, A2, and A3) and posterior (P1, P2, and P3) leaflets of the mitral valve are labelled.



Multiplanar reconstruction (MPR) of mitral valve apparatus. Q1 and Q2 are long axis views. Q3 and Q4 are en face views. Q4 shows the 3D reconstruction.

Summary

- Procedures were completed without any major adverse cardiovascular events related to vICE.
- Limitations include small sample size and homogenous MR location (central).
- Majority of patients had primary or mixed MR. Functional MR outcomes may differ.
- Data suggests that the threshold to use vICE for procedural guidance may be lowered
- Consideration of performing mTEER with monitored sedation and vICE is attractive as general anesthesia poses a risk to patients with advanced cardiomyopathy

Conclusions/Further Study

vICE guided mTEER was shown to be safe and feasible with a high rate of procedural success in patients with contraindications to TEE. As vICE imaging technology improves, it may be seen as a viable alternative to TEE in the future.

Acknowledgements

I would like to thank the UC Davis Health Division of Cardiology and my mentors, Dr. Gagan Singh and Dr. Tai Pham.