

UCSF

UC San Francisco Previously Published Works

Title

Acute nontraumatic subdural hematoma from ruptured accessory meningeal artery pseudoaneurysm.

Permalink

<https://escholarship.org/uc/item/0148g19g>

Authors

ONeill, Brannan

Wozny, Thomas

Uluc, Kutluay

et al.

Publication Date

2021

DOI

10.25259/SNI_50_2021

Peer reviewed



Case Report

Acute nontraumatic subdural hematoma from ruptured accessory meningeal artery pseudoaneurysm

Brannan E. O'Neill¹, Thomas Wozny², Kutluay Uluc¹, Jesse J. Liu¹

¹Department of Neurosurgery, Oregon Health and Science University, Portland, Oregon, ²Department of Neurosurgery, University of California at San Francisco, San Francisco, California, United States.

E-mail: *Brannan E. O'Neill - oneillb@ohsu.edu; Thomas Wozny - thomas.wozny@ucsf.edu; Kutluay Uluc - uluc@ohsu.edu; Jesse J. Liu - liu@ohsu.edu



*Corresponding author:

Jesse J. Liu,
Department of Neurosurgery,
Oregon Health and Science
University, Portland, Oregon,
United States.

liu@ohsu.edu

Received : 19 January 2021

Accepted : 01 April 2021

Published : 26 April 2021

DOI

10.25259/SNI_50_2021

Quick Response Code:



ABSTRACT

Background: Cerebral angiography including internal and external carotid artery injections is crucial in young patients with a spontaneous subdural hematoma.

Case Description: We present the first reported case of an accessory meningeal artery aneurysm in a 46-year-old male with a history of hypertension that led to a spontaneous nontraumatic acute subdural hematoma. A PubMed review of the literature was performed using a keyword search to identify cases examining nontraumatic spontaneous intracranial hematomas related to meningeal artery aneurysms. The literature review summarizes all published reports of middle meningeal artery aneurysms resulting in nontraumatic acute intracranial bleeds. The patient underwent successful coiling of the accessory meningeal artery.

Conclusion: We propose endovascular treatment for accessory meningeal artery aneurysms and emphasize the utility of angiography of internal and external carotid arteries in a patient with an unexplained intracranial hematoma.

Keywords: Angiography, Meningeal artery aneurysm, Spontaneous subdural hematoma

INTRODUCTION

A nontraumatic acute subdural hematoma can be caused by rupture of a vascular malformation or of an intracranial aneurysm into the subdural space. There are several reports of nontraumatic subdural hematomas secondary to aneurysms that have an internal carotid artery (ICA) distribution.^[4,18]

Aneurysms of external carotid artery distribution that is intracranial are rare. When present, they are diagnosed commonly in symptomatic patients. Few cases of middle meningeal artery (MMA) aneurysms leading to acute nontraumatic subdural hematoma have been described.^[1]

The case described here is the first report, to our knowledge, to detail a nontraumatic acute subdural hematoma secondary to rupture of a pseudoaneurysm of the accessory MMA. Subsequently, the case was managed with endovascular coiling. Cerebral angiography including internal and external carotid artery injections is crucial, especially in young patients with a spontaneous subdural hematoma. A literature review is also presented.

This is an open-access article distributed under the terms of the Creative Commons Attribution-Non Commercial-Share Alike 4.0 License, which allows others to remix, tweak, and build upon the work non-commercially, as long as the author is credited and the new creations are licensed under the identical terms.

©2021 Published by Scientific Scholar on behalf of Surgical Neurology International

CASE REPORT

A 46-year-old male with a history of hypertension was transferred to our facility after presenting with an 11-day history of nausea and vomiting after waking up with a right-sided sharp headache. The patient reported taking ibuprofen for the headache without significant relief. As a result of the ongoing headache, head computed tomography (CT) was obtained. The head CT revealed a right-sided acute subdural hematoma [Figure 1]. The patient denied any trauma, abrupt acceleration or deceleration.

A diagnostic cerebral angiogram including careful evaluation of the external and ICA circulations was undertaken. This revealed a small pseudoaneurysm of the right accessory MMA [Figure 2]. This was treated with endovascular embolization. Two platinum coils (Barricade, Irvine, CA) were placed proximal to the pseudoaneurysm, through a microcatheter (Headway Duo, Tustin, CA). He was discharged without any new medications, namely, he was not prescribed steroids or statins. Postprocedure angiography obtained at an outside facility confirmed obliteration of the aneurysm and the parent vessel. Postoperative follow-up head CT scan confirmed resolution of the subdural hematoma [Figure 3].

Literature analysis

A literature search of the PubMed/Medline databases was performed using the algorithm (“meningeal artery aneurysm” OR “spontaneous subdural hematoma” AND “nontraumatic”). Article titles and abstracts were then individually screened to populate articles of interest, and selected manuscripts were recorded digitally and tracked. To mitigate publication bias, referenced articles were utilized to identify other case reports and case series.

DISCUSSION

The first reported case of a MMA aneurysm was published by Berk in 1961; they described a 73-year-old female with Paget's disease who presented without trauma and endorsement of a 6-month headache.^[2] A left MMA aneurysm was identified and surgically resected. Since that time, nontraumatic MMA aneurysms have proven to be rare. We conducted a literature search, which resulted in <20 reports [Table 1].^[3-21] When identified, MMAs are most often accompanied by an underlying condition such as Paget's disease, moyamoya, meningioma, cavernous hemangioma, hypertension, posterior cerebral artery occlusion, dural arteriovenous malformation, or angioma.

To the best of our knowledge, there are no cases of an accessory meningeal artery aneurysm described in the literature. Given the rarity and unclear natural history of

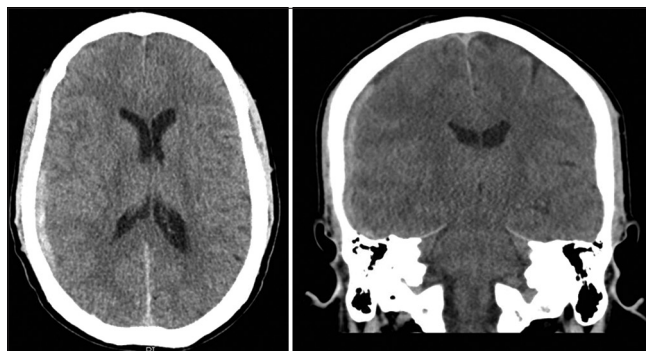


Figure 1: Outside hospital head computed tomography demonstrating a right convexity mixed density subdural hematoma, axial (left), and coronal (right) views.

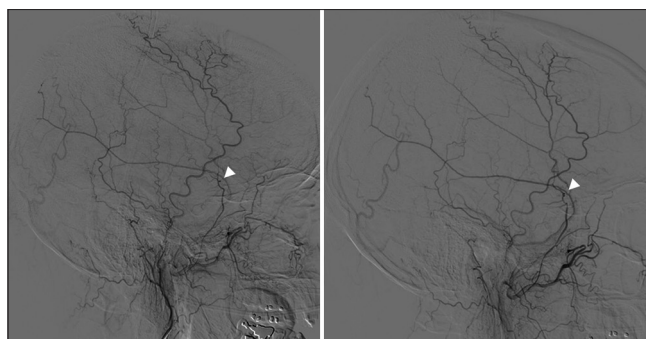


Figure 2: Lateral angiogram views showing pre (left) and post (right) embolization of the right accessory meningeal artery aneurysm.

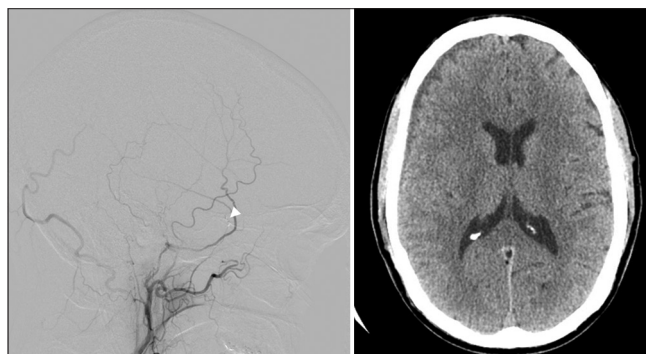


Figure 3: Follow-up angiogram at outside institution showing successful embolization of the lesion and the parent vessel opacified (left). Follow-up head computed tomography at outside institution showing significant improvement of the right convexity subdural hematoma (right).

the aneurysms of the external carotid artery circulation, clinical decision-making can be challenging. Several studies recommend endovascular treatment of these aneurysms due to bleeding risk.^[10] The evolving field of neurointerventional radiology, improvement in imaging quality, and increased frequency of superselective imaging has the potential to lead to increased identification of accessory meningeal artery

Table 1: Literature review of spontaneous nontraumatic intracranial bleeds due to middle meningeal artery aneurysms.

Authors, Year	Age (years)	Sex	Associated disease	Aneurysm location	Symptoms	Radiographic findings	Treatment	Outcome
Berk, 1961	73	F	Paget's	Left MMA	Headaches	ND	Resection	Not specified
Holland and Thomson, 1965	49	F	None	Right MMA, posterior branch	EDH	EDH	Resection	Intact
New, 1965	79	F	Paget's	-	Stroke	ND	-	-
Aggssat <i>et al.</i> , 1965	-	-	-	-	ICA occlusion	ND	-	-
New, 1967	57	F	Paget's	Right MMA, anterior branch	Headaches	ND	Ligation of ECA	No change
Sanchis <i>et al.</i> , 1975	59	F	Dural angioma	Right MMA	EDH	EDH	Resection	Improved
Bollati <i>et al.</i> , 1980	50	F	None	Left MMA	Epilepsy	Old SDH	Resection	Intact
Takahashi, 1980	10	F	M.Q.Y11119111.	MMA, unspecified	Incidental	ND		
Jin <i>et al.</i> , 1981	9	M	Asthma and MMA angioma	Left MMA, anterior branch	Headache and LOC	ND	Resection	Intact
Korosue <i>et al.</i> , 1988	66	F	None	Right MMA, posterior branch	SDH	Recurrent SDH	Resection	Intact
Ohta <i>et al.</i> , 1991	47	M	Cavernous hemangioma of skull	Right MMA, anterior branch	Incidental	ND	Resection	Intact
O'Neill, <i>et al.</i> , 1995	82	F	Meningioma	Right MMA	Incidental	ND	Coil placement	Improved
Ushikoshi <i>et al.</i> , 1996	69	M	Hypertension and PCA occlusion	Right MMA	IPH	ICH, IVH	Resection	Died, RF
Zubkov <i>et al.</i> , 1998	22	M	None	Right MMA, anterior branch	SAH	SAH	Resection	Intact
Sandin <i>et al.</i> , 1999	46	M	Mild hypertension	Right MMA	IPH	ICH	Resection	Intact
Nakahara <i>et al.</i> , 1999	58	F	Dural AVM	Right MMA	LOC	ICH		
Kobata <i>et al.</i> , 2001	77	F	Chronic heart failure	Left MMA, anterior branch	LOC	ICH, SAH	Resection	Not specified
Park <i>et al.</i> , 2010	43	F	b612.1111M11	Left MMA	Headache and LOC	ICH, SAH	Embolization	-

AVM: Arteriovenous malformation, ECA: External carotid artery, EDH: Extradural hemorrhage, ICA: Internal carotid artery, ICH: Intracranial hypertension, IPH: Intraparenchymal hematoma, IVH: Intraventricular hemorrhage, LOC: Loss of consciousness, MMA: Middle meningeal artery, ND: Not disclosed, PCA: Posterior cerebral artery, RF: Renal failure, SAH: Subarachnoid hemorrhage, SDH: Subdural hemorrhage

aneurysms. For true meningeal artery aneurysms, historical treatment was surgical resection of the abnormality or ligation of the external carotid artery. However, a push has been made for endovascular treatment of these aneurysms by embolization to lessen bleeding risk.^[14] We propose the same treatment for accessory meningeal artery aneurysms and emphasize the utility of angiography of internal and external carotid arteries in a patient with an unexplained intracranial hematoma.

CONCLUSION

To the best of our knowledge, this is the first reported case of an accessory meningeal artery aneurysm causing a nontraumatic acute subdural hematoma. Angiography of the external carotid arteries allowed for the detection of a small accessory meningeal artery pseudoaneurysm in this patient, and after successful embolization of the lesion, the vessel was obliterated and the hematoma improved significantly on follow-up imaging.

Declaration of patient consent

Patient's consent not required as patients identity is not disclosed or compromised.

Financial support and sponsorship

Nil.

Conflicts of interest

There are no conflicts of interest.

REFERENCES

1. Awaji K, Inokuchi R, Ikeda R, Haisa T. Nontraumatic pure acute subdural hematoma caused by a ruptured cortical middle cerebral artery aneurysm: Case report and literature review. *NMC Case Rep J* 2016;3:63-6.
2. BERK ME. Aneurysm of the middle meningeal artery. *Br J Radiol* 1961;34:667-8.
3. Bollati A, Galli G, Gandolfini M, Orlandini A, Gualandi GF. True aneurysm of the middle meningeal artery. Case report. *J Neurosurg Sci* 1980;24:89-92.
4. Gong J, Sun H, Shi XY, Liu WX, Shen Z. Pure subdural haematoma caused by rupture of middle cerebral artery aneurysm: Case report and literature review. *J Int Med Res* 2014;42:870-8.
5. Holland HW, Thomson JL. Aneurysm of the middle meningeal artery. *Clin Radiol* 1965;16:334-8.
6. Jin KH, Toyoda S, Kumagai K, Hashimoto T, Abe Y, Suzuki K. Non-traumatic middle meningeal aneurysm and angioma in a child. *Brain Dev* 1981;3:323-8.
7. Kähärä VJ. Middle meningeal artery aneurysm. Case illustration. *J Neurosurg* 1999;91:518.
8. Kobata H, Tanaka H, Tada Y, Nishihara K, Fujiwara A, Kuroiwa T. Intracerebral hematoma due to ruptured nontraumatic middle meningeal artery aneurysm--case report. *Neurol Med Chir (Tokyo)* 2001;41:611-4.
9. Korosue K, Kondoh T, Ishikawa Y, Nagao T, Tamaki N, Matsumoto S. Acute subdural hematoma associated with nontraumatic middle meningeal artery aneurysm: Case report. *Neurosurgery* 1988;22:411-3.
10. Nakahara I, Taki W, Kikuchi H, Sakai N, Isaka F, Oowaki H, *et al.* Endovascular treatment of aneurysms on the feeding arteries of intracranial arteriovenous malformations. *Neuroradiology* 1999;41:60-6.
11. New PF. True aneurysm of the middle meningeal artery, cranial Paget's disease and hypertension: A triad. *Clin Radiol* 1967;18:154-7.
12. New PF. True aneurysm of the middle meningeal artery. *Clin Radiol* 1965;16:236-40.
13. Ohta H, Tanazawa T, Osuka K, Ito Y, Fukatsu T. True aneurysms of the middle meningeal artery associated with cavernous hemangioma of the skull--case report. *Neurol Med Chir (Tokyo)* 1991;31:203-5.
14. O'Neill OR, Barnwell SL, Silver DJ. Middle meningeal artery aneurysm associated with meningioma: Case report. *Neurosurgery* 1995;36:396-8.
15. Park YS, Suk JS, Kwon JT. Repeated rupture of a middle meningeal artery aneurysm in moyamoya disease. Case report. *J Neurosurg* 2010;113:749-52.
16. Sanchis JF, Orozco M, Cabanes J. Spontaneous extradural haematomas. *J Neurol Neurosurg Psychiatry* 1975;38:577-80.
17. Sandin JA 3rd, Salamat MS, Baskaya M, Dempsey RJ. Intracerebral hemorrhage caused by the rupture of a nontraumatic middle meningeal artery aneurysm. Case report and review of the literature. *J Neurosurg* 1999;90:951-4.
18. Takada T, Yamamoto T, Ishikawa E, Zaboronok A, Kujiraoka Y, Akutsu H, *et al.* Acute subdural hematoma without subarachnoid hemorrhage caused by ruptured A1-A2 junction aneurysm. Case report. *Neurol Med Chir (Tokyo)* 2012;52:430-4.
19. Takahashi M, Saito Y, Konno K. Intraventricular hemorrhage in childhood moyamoya disease. *J Comput Assist Tomogr* 1980;4:117-20.
20. Ushikoshi S, Houkin K, Itoh F, Saitoh H, Nozaki M, Kuroda S, *et al.* Ruptured aneurysm of the middle meningeal artery associated with occlusion of the posterior cerebral artery. Case report. *J Neurosurg* 1996;84:269-71.
21. Zingesser LH, Schechter MM, Rayport M. Truths and untruths concerning the angiographic findings in extracerebral haematomas. *Br J Radiol* 1965;38:835-47.
22. Zubkov YN, Matsko DE, Pak VA. Saccular aneurysms of meningeal artery: Case report. *Neurosurgery* 1998;42:664-6.

How to cite this article: O'Neill BE, Wozny T, Uluc K, Liu JJ. Acute nontraumatic subdural hematoma from ruptured accessory meningeal artery pseudoaneurysm. *Surg Neurol Int* 2021;12:186.