

# UC Davis

## Dermatology Online Journal

### Title

Congenital drainage at the base of the neck

### Permalink

<https://escholarship.org/uc/item/02t8s1j5>

### Journal

Dermatology Online Journal, 19(8)

### Authors

Morais, Paulo  
Marques, Maria Ines  
Vieira, Fortunato  
[et al.](#)

### Publication Date

2013

### License

<https://creativecommons.org/licenses/by-nc-nd/4.0/> 4.0

Peer reviewed

**Photo Vignette**

**Congenital drainage at the base of the neck**

**Paulo Morais MD<sup>1</sup>, Maria Inês Marques MD<sup>2</sup>, Lúgia Peralta MD<sup>2</sup>, Fortunato Vieira MD<sup>3</sup>**

**José Matos MD<sup>1</sup>**

**<sup>1</sup>Department of Dermatology, <sup>2</sup>Department of Pediatrics, Centro Hospitalar Tondela-Viseu, Viseu, Portugal**

**<sup>3</sup>Histocit - Laboratório de Anatomia Patológica, Trofa, Portugal**

**Dermatology Online Journal 19 (8): 16**

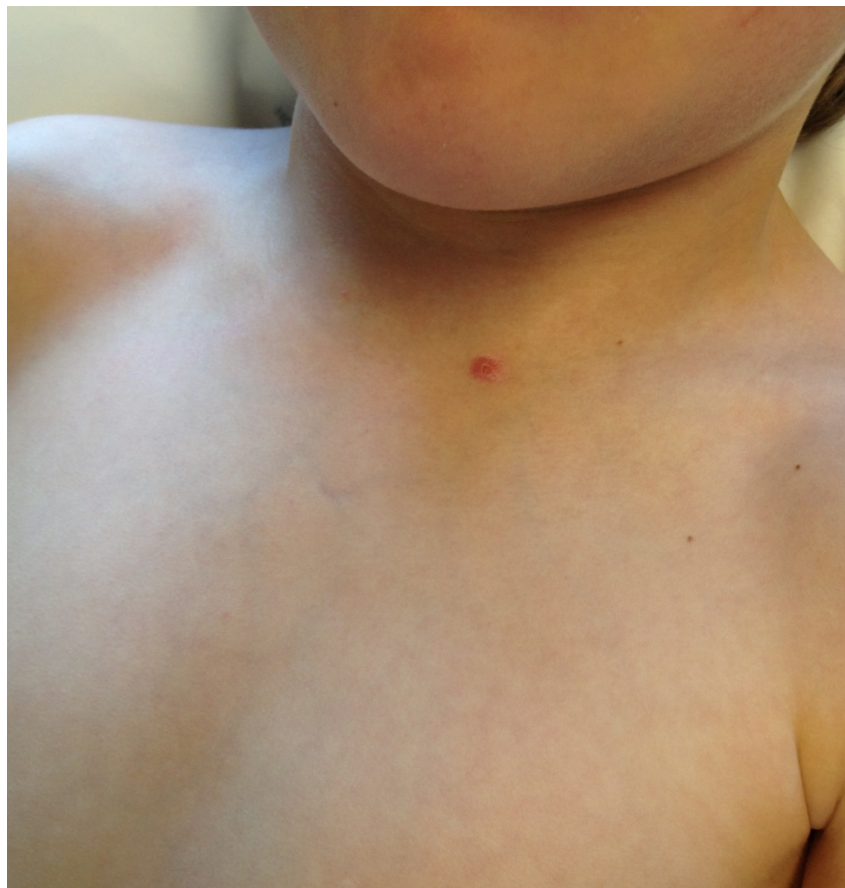**Correspondence:**

Paulo Morais, M.D.,  
Department of Dermatology, Centro Hospitalar Tondela-Viseu  
Av. Rei D. Duarte, 3504-509 Viseu, Portugal  
E-mail: paulomoraiscardoso@gmail.com.

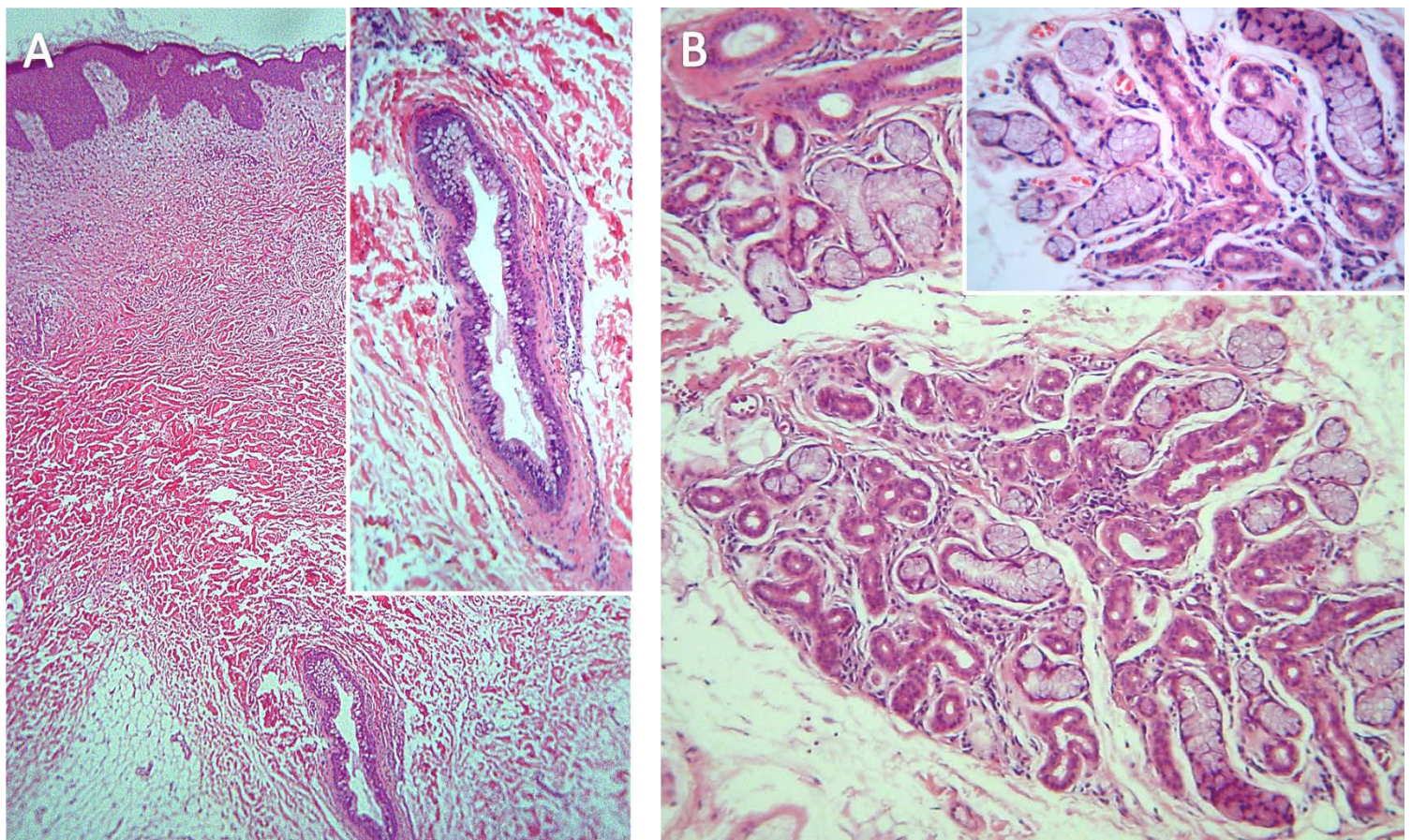
**Abstract**

Heterotopic salivary gland tissue consists of otherwise normal salivary tissue, but occurs at a site in which it is normally not present (outside of the major, minor, and accessory salivary glands), with absence of clinical and histological features of branchial cleft anomalies. We herein present a 7-year-old boy with drainage from a small, congenital cystic lesion located at the base of the neck, which was histologically confirmed as salivary gland tissue.

**Keywords: heterotopic salivary gland tissue, ectopic salivary gland, neck.**



**Figure 1.** Clinical appearance of the lesion, located in the patient's left lower neck.



**Figure 2.** (A, B) Histological image (H&E stain) of the lesion showing slight epidermal acanthosis and, below an area of cicatricial fibrosis of the dermis (secondary to previous curettage), a mucinous salivary gland with an associated ectatic draining duct is clearly observed. There is no cell atypia, and no other types of structures or developmental remnants are identified, namely lymphoid tissues with germinal centers and lining of respiratory or squamous epithelium.

## Case synopsis

A 7-year-old boy was referred to our dermatology clinic for drainage from a small cystic lesion located at the base of the neck. Since birth, his parents had noticed an intermittent clear, sticky, and odorless discharge from an opening located in his left lower neck, especially during meals. There was no history suggestive of acute infection at any time, including pain, purulent discharge, edema, or erythema. The lesion had been previously excised by curettage on suspicion of molluscum contagiosum, but relapse occurred. On physical examination, we observed a translucent cyst, approximately 6-mm in diameter, located 1-cm above the left sternoclavicular joint. A small central hole was observed, but there was no active drainage (**Figure 1**). There were no neck adenopathies or masses. The remainder of the skin examination was unremarkable. The lesion was excised and the specimen sent for histopathologic examination (**Figures 2A and 2B**), which confirmed heterotopic salivary gland tissue. The patient had a computed tomographic scan of the neck that excluded branchial cleft anomalies, such as cysts, sinuses or fistulae. At follow-up visit 3 months later, there was no recurrence of the lesion.

## Discussion

Salivary tissue occurring at a site that it is normally not present can arise in 1 of 3 forms: accessory salivary glands, salivary tissue associated with branchial cleft anomalies, and true heterotopic salivary gland tissue (HSGT) [1]. The last, also known as ectopic salivary gland or salivary choristoma, consists of otherwise normal salivary tissue found in an abnormal location outside of the major, minor, and accessory salivary glands, with absence of clinico-histological features of branchial cleft anomalies [2]. Cases generally present by early childhood as an opening draining mucoid or serous discharge or an asymptomatic nodule in the lower neck along the anterior border of the sternocleidomastoid muscle, with a right-sided predilection [2, 3, 4]. Other rarer locations have been reported including the pituitary, middle and external ear, mandible, gingiva, thyroglossal duct, thyroid and parathyroid glands, cervical lymph nodes, mediastinum, and rectum [1, 3]. Mucus retention can occur, producing ductal dilation and cyst formation, as observed in our patient.

The pathogenesis of HSGT of the neck remains uncertain. It probably arises sporadically from heteroplasia of ectodermal cells within a remnant of the pre-cervical sinus of His defectively closed. It is considered an error of development in the branchial apparatus [4]. HSGT may resemble branchial cleft fistulas or sinuses. Some differentiating features are the absence of a history of infection, a sense of fullness in the affected area during episodes of drainage, and an increase in the discharge with eating, mastication, or menstruation in the former [5]. Exclusion of HSGT would occur in the presence of lymphoid tissues with germinal centers, lining of respiratory or squamous epithelium, and compatible imaging studies or sinugram/fistulogram

in branchial cleft fistulas or sinuses [1]. The excision of HSGT is mandatory, not only for diagnostic and cosmetic reasons, but also to prevent complications such as infectious and inflammatory diseases or even neoplastic transformation (both benign and malignant) [6]. Despite its rarity, dermatologists should be aware of this condition and include it in the differential diagnosis of congenital draining sinuses or swelling of the neck.

## References

1. Cannon DE, Szabo S, Flanary VA. Heterotopic salivary tissue. *Am J Otolaryngol* 2012;33:493-496. [PMID: 22185684]
2. Lassaletta-Atienza L, Lopez-Rios F, Martin G, et al. Salivary gland heterotopia in the lower neck: a report of five cases. *Int J Pediatr Otorhinolaryngol* 1998;43:153-161. [PMID: 9578125]
3. Haemel A, Gnepp DR, Carlsten J, et al. Heterotopic salivary gland tissue in the neck. *J Am Acad Dermatol* 2008;58:251-256. [PMID: 18222321]
4. Youngs LA, Scofield HH. Heterotopic salivary gland tissue in the lower neck. *Arch Path* 1967;83:550-556. [PMID: 6024732]
5. Kim YS, Park CS, Lee JD, et al. Heterotopic salivary gland located in the middle neck. *Yonsei Med J* 1988;29:295-299. [PMID: 3195161]
6. Ferlito A, Bertino G, Rinaldo A, et al. A review of heterotopia and associated salivary gland neoplasms of the head and neck. *J Laryngol Otol* 1999;113:299-303. [PMID: 10474661]