

Foreign Body Granulomas after All Injectable Dermal Fillers: Part 1. Possible Causes

Foot

Gottfried Lemperle, M.D.,
Ph.D.

Nelly Gauthier-Hazan, M.D.

Marianne Wolters, M.D.

Marita Eisemann-Klein, M.D.

Ute Zimmermann, M.D.

David M. Duffy, M.D.

*San Diego and Los Angeles, Calif.;
Paris, France; and Frankfurt am Main
and Regensburg, Germany*

Summary Genuine granuloma formation following implantation of injectable dermal fillers is a rare complication, with incidences ranging from one in 100 patients (1 percent) to one in 5000 (0.02 percent). Foreign body granulomas occur several months to years after injection at all implantation sites at the same time. Without treatment, they may grow to the size of beans, remain virtually unchanged for some years, and then resolve spontaneously. Three clinical and histologic types of foreign body granulomas can be distinguished:

1. Cystic granulomas (synonyms: inflammatory, palisading, collagenolytic): these are caused mainly by injected biological gels such as collagens and hyaluronic acids. Their clinical signs are fluctuation (sterile abscess), extreme redness, and induration. Cystic granulomas are small and superficial, occur within the first year, and disappear spontaneously within another year. They are surrounded by a significant number of giant cells.
2. Edematous granulomas (synonym: lipogranuloma): these are caused by artificial fluids such as silicone and polyacrylamides. They appear suddenly years after injection with extensive swelling and are surrounded and infiltrated by mononuclear and inflammatory cells.
3. Sclerosing granulomas (synonyms: sarcoidal and xanthelasmic): these are caused by particulate injectables composed of polymethylmethacrylate, polylactic acid, hydroxyethylmethacrylate, calcium-hydroxylapatite, or dextran microspheres. Sclerosing granulomas occur generally 6 months to 3 years after implantation and are visible, often bluish confined nodules. Histologically, the implant is infiltrated by many macrophages and giant cells, fibroblasts, and collagen fibers but few inflammatory cells.

Permanent implants are not characterized by a higher rate of foreign body granuloma per se than temporary implants; however, their clinical appearance is more pronounced and their persistence longer if not treated adequately. (*Plast. Reconstr. Surg.* 123: 1, 2009.)

The increasing use of dermal filler substances in the treatment of wrinkles, the immense variety of new products, and the introduction of new names without proper disclosure of their chemical contents make any overview difficult.¹ The general lack of reliable scientific description and trustworthy clinical data and publications—positive or negative—meet a general lack of scientific interest and criticism on the part of the injecting physician. The sudden occurrence of a complication then leads to astonishment, neg-

ligence, blame directed at the product, and often wrongful treatment of these troublesome complications.

The injectable dermal filler market has been undergoing a dynamic growth since the public became aware of nonsurgical approaches leading to wrinkle-free skin. Resorbable and nonresorbable materials have been made injectable and are

From the Division of Plastic Surgery, University of California, San Diego; private practice; the Department of Plastic Surgery, Caritas-Hospital St. Josef; the Private Institute of Histopathology; and the Department of Dermatology, University of Southern California, Los Angeles.

Received for publication June 14, 2007; accepted October 18, 2007.

Copyright ©2009 by the American Society of Plastic Surgeons

DOI: 10.1097/PRS.0b013e31818236d7

Disclosure: *Gottfried Lemperle, M.D., Ph.D., is not an employee, consultant, agent, or representative of Artes Medical, Inc., which is the manufacturer of ArteFill. The opinions expressed in the article are not the opinions of Artes Medical, Inc. Dr. Lemperle is a shareholder of Artes Medical, Inc. None of the other authors has a financial interest in any of the products, devices, or drugs mentioned in this article.*

AQ: 1

AQ: 1

introduced beneath wrinkles and in skin depressions. In general, all injectable substances exerting a positive effect may be expected to also cause negative side effects. All current dermal fillers are associated with adverse effects.^{2,3} Biological substances such as collagen or hyaluronic acids may cause lumps, allergies, long-lasting redness, sterile abscesses, and eventually early foreign body granulomas. Longer lasting artificial substances, such as many polymers used in medicine, may cause lumps, persistent redness, and late foreign body granulomas.

The incidence of foreign body granulomas appears to vary according to the chemical nature of the injectable, its surface structure and properties, its content of impurities, but not its primary biocompatibility or the volume injected. A strong histologic foreign body reaction within the first months following injection is not an indicator for an increased possibility of late foreign body granulomas. The trigger for the sudden occurrence of a granuloma has not been uncovered. Anecdotal reports suggest severe systemic bacterial and viral infections in the months before the onset of a granuloma. Only proper education of physicians and patients will draw a realistic picture of this new field of injectables, presently filled with enthusiasm, negligence, warnings, hypotheses, widespread happiness, but also some disasters.

The following calculations and opinions are based on the joint experience of the authors with various injectable filler substances and their complications and a thorough review of the existing literature. The problem of statistics is obvious: late adverse events after filler injections do not have to be reported to the manufacturer or to the health authorities in most countries. This accounts for the low rate of foreign body granulomas claimed by manufacturers. Until official statistics are available, one has to rely on those of single physicians. To obtain reliable numbers, calculations in the statistical tables were limited to reports on case numbers above 500. Why can these injectable dermal fillers all cause late and sudden foreign body reactions in very rare patients after months and years of inconspicuous integration in the skin?

DESCRIPTION OF A FOREIGN BODY GRANULOMA

The word granuloma is a compound of the Latin *granulum* (little grain) and the Greek *onkoma* (tumor or nodule). In histopathology, it describes a granulomatous tissue reaction to bacteria (e.g., tuberculosis, leprosy, and dental granuloma), fungi (*Actinomyces*), eggs of dermal parasites, un-

known stimuli (e.g., lymphogranulomatosis, erythema nodosum, granuloma annulare, granulomatous lymphoma, pyogenic, and eosinophilic granuloma), or foreign bodies (e.g., spines or stings, sutures, fat necrosis, surgical powder, tattoos, and injectable filler substances). It is the body's attempt to get rid of the intruded material. Histologically, granulomas consist of an inflammatory infiltrate composed of histiocytes and epithelioid cells. They differ mainly by the proportion and arrangement of lymphocytes, plasma cells, neutrophils, eosinophils, and multinucleated giant cells, and the amount of polymorphous exudates and sometimes the presence of necrosis.

CLINICAL APPEARANCE OF FOREIGN BODY GRANULOMAS

Irrespective of its histologic picture, a true foreign body granuloma is and remains a clinical diagnosis. It can develop slowly or rapidly in certain patients after the injection of any dermal filler such as collagen, hyaluronic acid, silicone, polyacrylamides, and particulate polymers. It occurs significantly less often after implantation of microspheres with smooth surfaces (Artecoll, New-Fill/Scultra) than after implantation of particles with irregular or edged surfaces (Bioplastique, Dermalive). Its appearance is less dramatic after resorbable implants (e.g., collagen, hyaluronic acid) (Fig. 1) than after long-lasting fluidal implants (e.g., polyacrylamide gel, silicone fluid).

The time between injection and the first appearance of a foreign body granuloma is usually 6 to 24 months; however, sudden occurrence of foreign body granuloma has been described up to 10 years after implantation.^{4,5} Some granulomas developed only after a second or third implantation and some developed even years after the material had long been absorbed.⁶ After an uneventful and satisfying period of many months or years, one of the implanted areas suddenly increases in size and ends up as a painless, plump but rather soft, non-confined nodule. Clinically, such granulomas may be accompanied by an uncomfortable tension and persistent or transitory edema, erythema, or purplish pigmentation. They may show periods of "flare-ups" and temporary regressions. Soon, all other implantation sites develop a similar growth. This is the major differentiation from a nodule of a normal implant (Table 1).

True foreign body granulomas increase in size over a certain time. Congested dermal capillaries widen and give the lump a bluish appearance. If not treated intralesionally with corticosteroids, they may increase to the size of a pea or bean,

AQ: 2

F1

T1

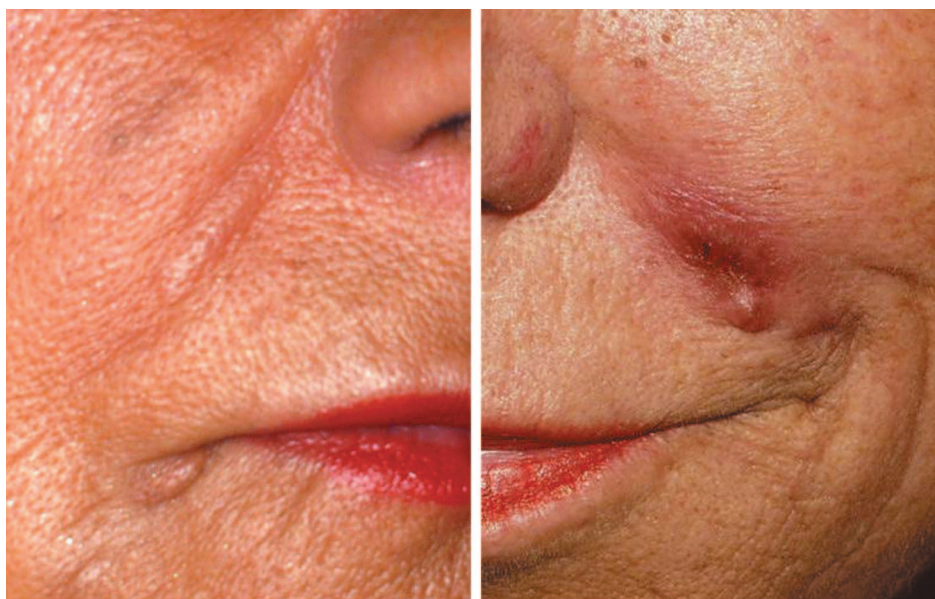


Fig. 1. (Left) Implantation of a filler (here Restylane) that is too superficial (intradermal) may cause a long-lasting ridge or nodule. (Right) Cystic or inflammatory granulomas in both nasolabial folds appeared 3 months after injection (Restylane). The upper cyst had drained spontaneously.

Table 1. Difference between Granuloma and Implant Nodules

	Granulomas	Nodules
Appearance	Suddenly, 6–24 mo after injection	1–2 mo after injection, after swelling vanishes
Location	At all injected sites at the same time	Single nodules, close to facial muscles, particularly in the lips
Size	Growing to the size of a bean, with skin discoloration, edema	Remain the same size of a lentil or a pea
Borders	Grow fingerlike into surrounding tissue	Well confined by fibrous capsule
Persistence	If untreated, they disappear after 1–5 yr	Until absorption (or permanent)
Histology	Foreign body granuloma; particles or microspheres are scattered	Foreign body reaction; particles or microspheres form aggregates
Treatment	React well to intralesional or systemic corticosteroids	Little effect of corticosteroids; must wait for absorption or excision
Cause	Still unknown	Technical error

remain unchanged in their clinical appearance, and resolve spontaneously after some years.⁷ Because the reasons for the development of a granuloma in an individual patient are not yet known, prediction of patients at risk or preselection of patients is not yet possible.

Foreign body granulomas occur rarely but at a rate ranging from one in 100 to one in 5000 patients (1.0 to 0.02 percent) after injection, according to surface structure and chemistry of various dermal filler substances such as collagen,⁶ hyaluronic acid,^{8,9} Artecoll,¹⁰ New-Fill,¹¹ fluid silicone,^{4,5} polyacrylamides,^{12,13} and Dermalive¹⁴ (Table 2).^{10,11,15–28} In general, foreign body granulomas are of nonallergenic origin: we have tested two former granuloma patients, years after suc-

cessful injections, with the same material and they did not form granulomas at the test sites. Therefore, a typical foreign body granuloma (Fig. 1, right) is not a late allergic granulomatous reaction of type IV.²⁹ The unequivocal diagnosis of foreign body granuloma is based on histologic evidence but mainly on clinical appearance.³⁰

DIFFERENTIATION OF NODULES FROM GRANULOMAS

All injectables bear the danger of being over-injected, remodeled, or dislocated when deposited into or close to a facial muscle. Similar to a mussel forming a pearl, constant muscle movement in a patient may form a nodule or “grain” from an incorrectly deposited strand. This may be

T2, AQ:3

Table 2. Rates of Foreign Body Granulomas Associated with Various Dermal Fillers in Cohorts of 450 or More Patients

Product	References	Data Collection	FBG/No. of Patients	Calculated FBG Rate	
				Individual (%)	Overall (%)
Collagen gel	Cooperman et al. ¹⁵	1975–1984	15† in 5109	0.3	~0.34
	Charriere et al. ¹⁶	1986–1988	8† in 656	1.2	
	Castrow and Krull ¹⁷	1981–1982	21* in ~7000	0.3	
	Hanke ^{18*}	1981–1989	‡ in ~470,000	0.04	
Hyaluronic acid gel	Lowe et al. ¹⁹	1996–2000	3† in 709	0.4	~0.4
	André ²⁰	1997–2001	18† in 4320	0.4	
	Friedman et al. ^{21*}	1999	Some in ~144,000	0.07	
	Friedman et al. ^{21*}	2000	Rare in ~262,000	0.02	
PMMA microspheres	Lemperle et al. ¹⁰	1989–1993	15 in 587	2.5	~1.51
	(Arteplast)				
	Gauthier (Arteplast)	1993–1994	9 in ~1000	0.9	
	Gauthier (Artecocoll)	1995–1999	3 in ~2000	0.15	
	Lemperle (Artecocoll)	1994–1998	7 in ~3500	0.24	
	Dansereau‡	1998–2005	2 in ~2000	0.10	
	Canderm Canada*‡	1998–2005	14 in ~50,000	0.03	
	Hafod China*‡	2002–2005	2 in ~30,000	0.01	
	TRM Korea*‡	1996–2005	9 in ~60,000	0.01	
	Jansen and Graivier ²²	2002–2004	>1 in 609	0.16	
Calcium-apatite microspheres	BioForm Medical*‡	2002–2005	>3 in ~35,000		~0.001
PLA microspheres	Gauthier (3-ml dilution)	1999–2002	15 in ~1500	1.0	~1.0
	Gauthier (5-ml dilution)	2002–2005	2 in ~1500	0.13	
	Bauer ²³	2000–2004	5 in 722	0.7	
	Vleggaar ²⁴	2000–2003	3 in 2131	0.14	
pHEMA particles	Aventis Germany*‡	1999–2004	? in ~150,000	0.2	~0.2
	DeGoursac‡	1998–2000	17 in >800	2.1	
	Bergeret-Galley et al. ¹¹	1998–2000	9 in 455	2.0	
	Harrer‡	1998–2004	10 in 1630	0.6	
Silicone oil	Dermatech France*‡	1998–2005	? in ~170,000	0.225	~0.22
	Greenberg ²⁵	1980–1990	1 in ~1000	0.10	
	Orentreich ²⁶	Since 1985	1 in ~5000	0.02	
	Fulton ²⁷	2002–2005	5 in 608	0.82	
	Jones et al. ²⁸	2003–2005	1 in 500	0.20	

FBG, foreign body granuloma; PMMA, polymethylmethacrylate; PLA, poly-L-lactic acid; pHEMA, poly-hydroxyethyl-methacrylate.

*Numbers of the manufacturers based on units of product sold (averaging 2 cc per patient).

†Based on our interpretation of granulomas used in this presentation, we classified “sterile abscess” and “chronic inflammation” as granulomas if they occur at least 2 months after injection at all sites at approximately the same time.

‡Personal communications with physicians and manufacturers in 2005.

especially obvious in the corners of the mouth and in the soft tissues of the lips (Fig. 1, *right*, and Fig. 2, *above*), where the microdroplet technique may eventually circumvent this.³⁰ The formation of these nodules must be blamed on inadequate implantation technique and must not be confused with genuine foreign body granulomas. Nodules occur rather often while a given physician is learning to inject by means of a new technique or with a new implant. This highlights the importance of thorough training for all injection techniques.

Nodules are isolated single lumps in the implanted area that do not grow, and their fibrous capsule confines them well from the surrounding tissue. Often, they are white and harder than a genuine granuloma (Fig. 2, *below*) because they contain fewer cellular elements and are palpable or visually evident a few weeks after injection (Ta-

ble 1). Intralesional corticosteroid injections are rather difficult because of the hardness of the nodules and are often ineffective because of little cellular reaction. In the lips, they are best excised from the inside.^{30,31}

The histology of implant nodules reveals the appearance of a dense foreign material, macrophages, and giant cells, a normal, deliberate foreign body “reaction” similar to that described as foreign body granulomas.^{29,32} Giant cells per se are not the typical sign of granulomas but of foreign material too large to be engulfed by macrophages, which fuse into giant cells to be more powerful (Fig. 3). Eppley et al.³³ called giant cells therefore “frustrated macrophages.” Unfortunately, the pathologic misdiagnosis of an intended normal foreign body reaction adds to the confusion of clinicians.

F2

F3

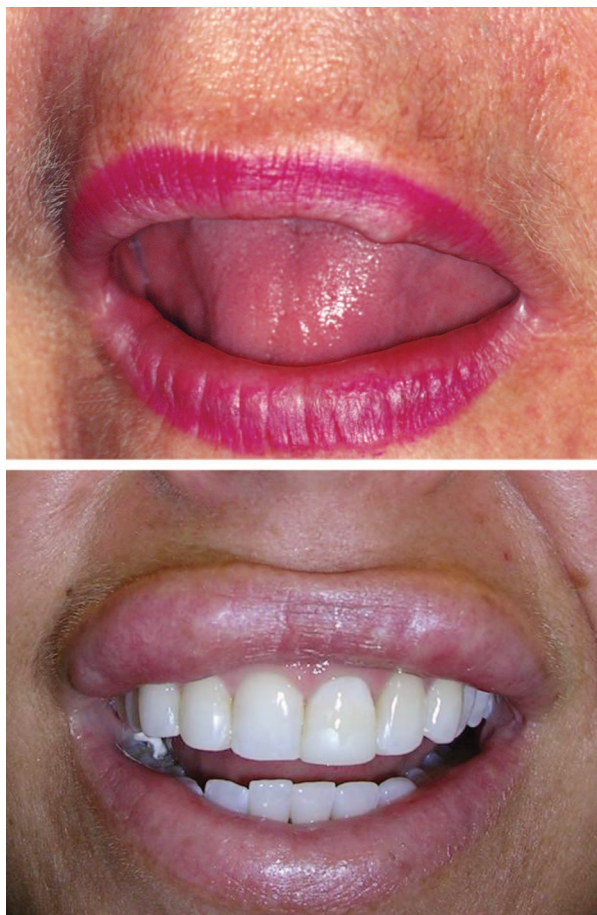

Fig. 2. (Above) Nodules in the lips from compressed Radiesse strands do not react to steroid injections but can be excised. (Below) Sclerosing granulomas of the entire upper lip (Dermalive) react preferably to intralesional steroid injections.

The article by Hubmer et al.³⁴ contains a good example of a simple nodule and not a granuloma as stated in the text. They describe a single nodule in the lips occurring after the insertion of polytetrafluoroethylene threads, one of them causing constant irritation. Histologic examination showed an envelope of scattered giant cells, fibroblasts, and dense collagen bands, a normal foreign body reaction as described for polytetrafluoroethylene threads.²² Rudolph et al.²³ also show an image of a normal foreign body reaction to Artecoll but describe it as a granuloma.

Another common misdiagnosis occurs when a dermal filler containing microspheres has been implanted too superficially into the dermis (instead of at the dermal-subdermal junction). In some cases, a hyperreaction of the skin may take place 2 or 3 months after implantation that clinically and histologically resembles a hypertrophic scar or a keloid, with the typical coloring of the

skin. The predominant components present in such cases are fibroblasts and broad collagen strands that are pushing the particles to clusters, not macrophages and giant cells as in foreign body granuloma. These “hypertrophic scars” react well to intralesional corticosteroid injections.³⁰

HISTOLOGY OF NORMAL IMPLANT MATERIAL

Because foreign body granulomas caused by dermal fillers have not been introduced yet in modern textbooks of pathology and are rarely mentioned in the pathology literature,³⁵ most histopathologists will diagnose a normal and deliberate foreign body reaction to particulate material as a foreign body granuloma.^{23,36,37} The confusion stems from the fact that particulate materials are implanted intentionally to stimulate a foreign body reaction (i.e., the ingrowth of cells and the encapsulation of each particle or microsphere with fibrous tissue, thus ensuring a softer and more pliable implant).

All injected substances cause an initial influx of mononuclear cells. In the case of fillers containing particles, macrophages are initially attached to the particles or microspheres, converting occasionally into giant cells (five to 10 giant cells in a field at 100× magnification is normal). If these particles are not constantly irritating, most giant cells have disappeared by 6 months, and the histologic picture will remain stable, as the microspheres are permanent.³⁶

In other resorbable implants such as Sculptra, Dermalive, or Radiesse, the hyaluronic acid or methylcellulose carrier dissipates soon after injection and leaves the particles or microspheres packed with little space for tissue ingrowth.³⁶ The resorbable particles or microspheres are broken down enzymatically and are subsequently phagocytized by macrophages and giant cells within 6 to 12 months after injection.³⁶

HISTOLOGIC DIAGNOSIS OF TRUE FOREIGN BODY GRANULOMAS

Three different clinical and histologic types of foreign body granulomas may occur. Of course, there is a continuum between the three types, and certain granulomas sometimes are a blend of two types.

Cystic Granuloma

Cystic granulomas (synonyms: inflammatory, collagenolytic, necrobiotic, palisading) can develop superficially after intradermal collagen and

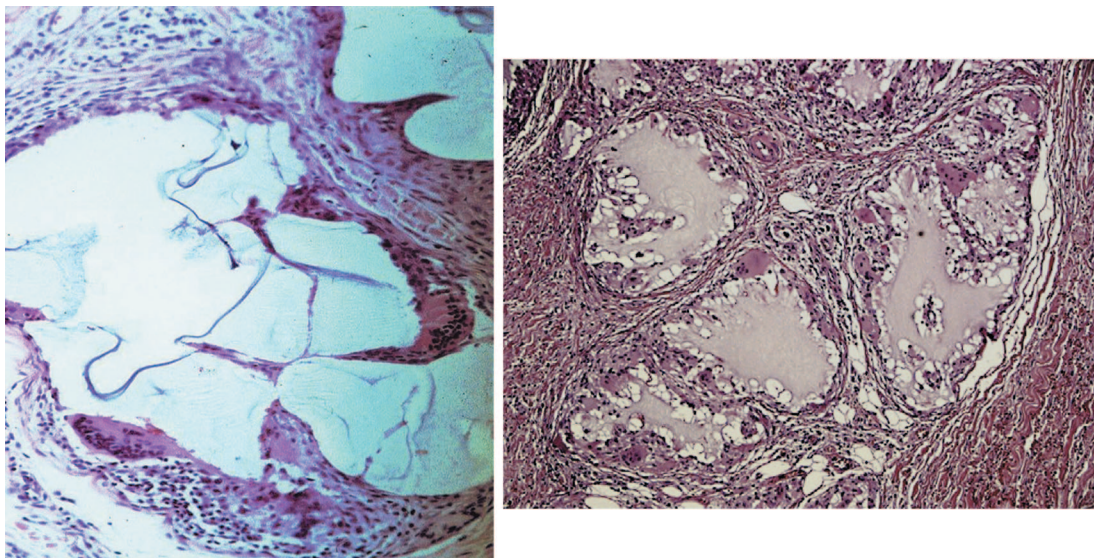


Fig. 3. (Left) Palisading giant cells are a typical sign cystic granulomas (Restylane) (hematoxylin and eosin; original magnification, $\times 40$). (Right) Fluid fillers (Bio-Alcamid) can also cause sclerosing granulomas with strong fibrosis (hematoxylin and eosin; original magnification, $\times 100$). (Courtesy Dr. J. J. Hage.)

F4
F5

hyaluronic acid injection and may last for 2 to 12 months if not treated (Fig. 1, right, Fig. 4, above, and Fig. 5). Inflammation, swelling, and pain are the predominant clinical signs (Fig. 4). Although implantation of bovine collagen is considered to be one of the least toxic and least irritating biomaterials known,³⁷ its late complications have been described as “palisaded foreign body granuloma”³⁸ surrounded by a zone of neutrophils, lymphoid cells, macrophages, and a significant number of giant cells (Fig. 3), which are uncharacteristic of a bacterial abscess.³⁹ “Necrobiotic granuloma” has also been used to describe the collagen implant, with collagen floating in a sea of neutrophils.^{39–42} Some believe that this form of granuloma is a manifestation of cell-mediated delayed hypersensitivity reaction³⁹ and that these patients may have elevated collagen antibody titers⁴³ and a positive reaction at a second test site.^{35,40} In our own experience, none of the patients with cystic foreign body granuloma showed positive skin tests against collagen or hyaluronic acid at the time of onset. Bacterial cultures were uniformly negative.^{18,44}

A cystic granuloma is a serious and disturbing adverse event characterized by a slowly developing induration and erythema. In contrast to sclerosing granulomas, fluctuation may be present at all injected sites approximately 1 to 3 months after injection (Fig. 5). The term “sterile abscess”^{18,37,43} is not fully correct because induration and redness will persist for many months, even after puncture and extrusion of all contents, and residues of col-

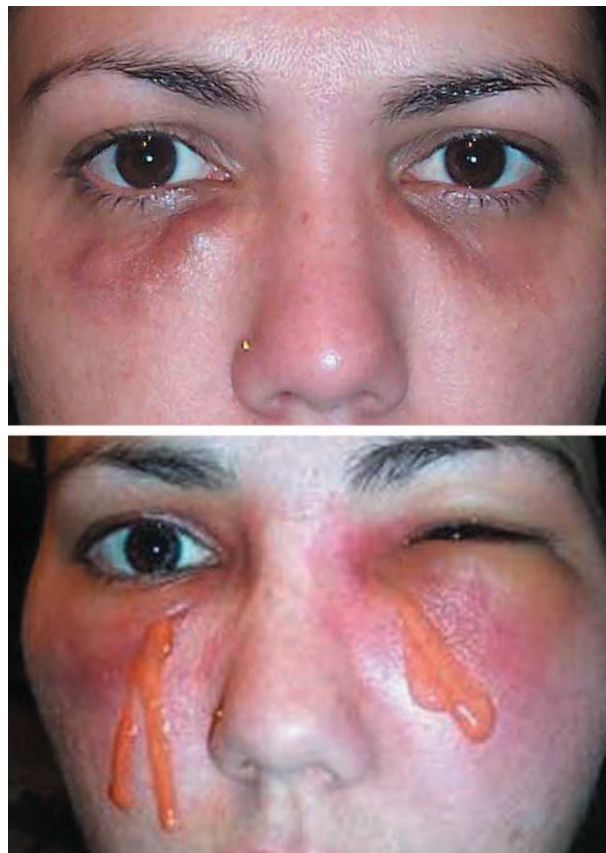

Fig. 4. (Above) Cystic (inflammatory) granuloma (Aquamid) developing 7 months after injection. (Below) Three days later, stab incisions revealed sterile pus on both sides.

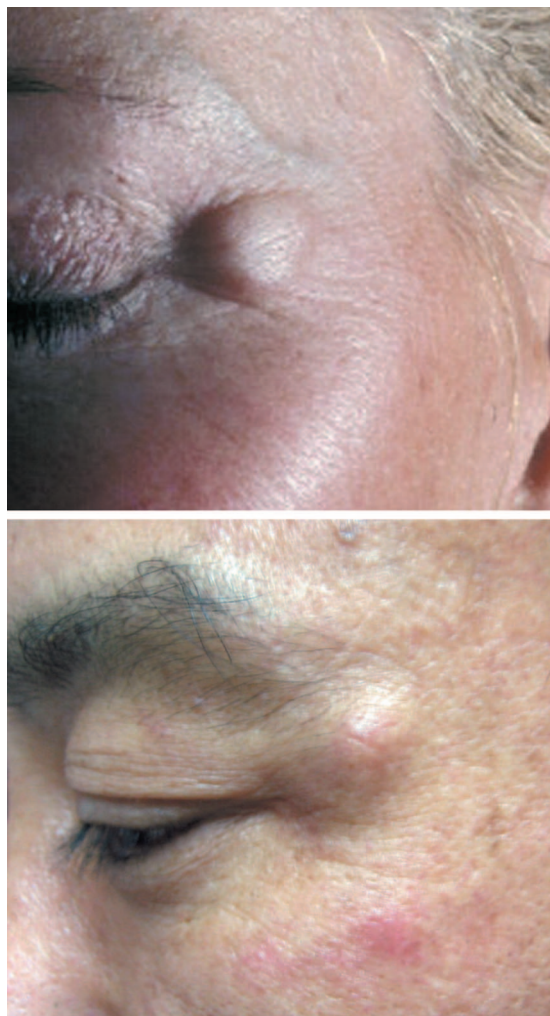

Fig. 5. (Above) Cystic granulomas (collagen) developed 4 months after injection of crow's feet on both sides. (Below) Sclerosing granuloma (Artecoll) developed 4 to 5 months after injection.

lagen or hyaluronic acid are lying within the center of a palisaded granuloma, lined with many giant cells (Fig. 3). The induration usually resolves spontaneously in less than 1 year.^{29,38,39,45} In contrast, granuloma-producing agents must persist within cells for a long time. Macrophages are assumed to be “memory cells” even if they move away once degradation is complete.⁴⁶

Edematous Granuloma

Edematous granuloma of “Swiss cheese pattern,”⁷ lipogranuloma,³⁸ or “honeycomb” appearance may develop suddenly many years after subdermal silicone fluid or acrylamide gel injections. If it occurs in the glabella or cheek, the eyelids are swollen over a period of months (Fig. 6)

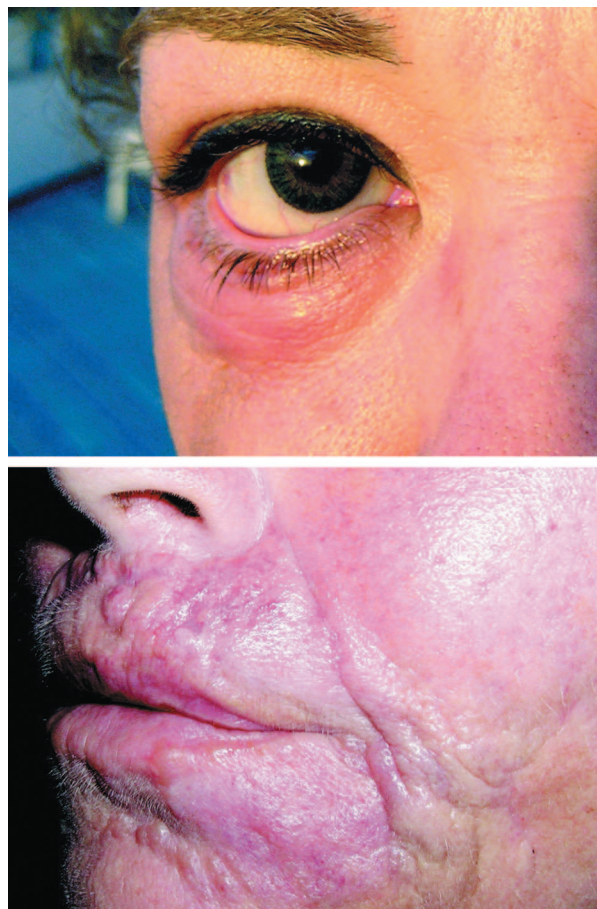


Fig. 6. (Above) Edematous granulomas (Interfall) at all injected sites approximately 9 months after injection. Resolution occurred not by puncture and suction but under local and systemic triamcinolone. (Below) Edematous granuloma (Dermalive) at all injected sites of the face 3 months after eruption.

soft rather than a hard tumor. Erythema of the implanted area is often present. Histologically, this type of foreign body granuloma represents an infiltration of the surrounding tissue, mainly by lymphocytes and macrophages but seldom by giant cells. The resultant swelling (Fig. 7, above) appears to facilitate the migration of inflammatory cells from the capillaries to the implant, which for one or another reason suddenly causes a hypersensitivity reaction after many years.⁷ Local injections into the inflammatory “capsule” sometimes combined with systemic corticosteroids are the therapy of choice.

Sclerosing Granuloma

Sclerosing granuloma (synonyms: sarcoidal, xanthelasmized) may occur after subdermal implantation of all types of particulate material (e.g., Artecoll, New-Fill/Sculptra, Dermalive, Radiesse,

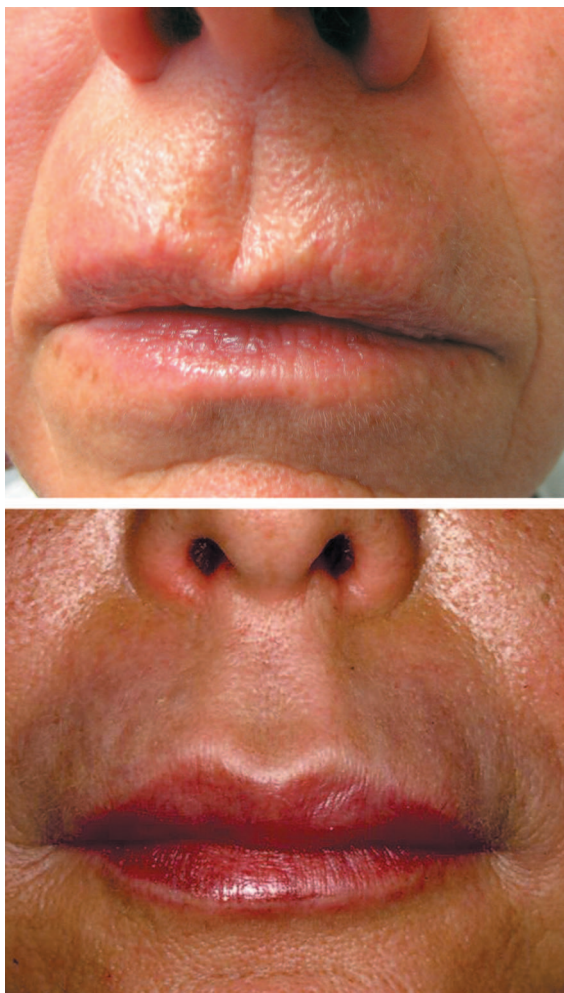

Fig. 7. (Above) Edematous granuloma (Interfall). (Below) Sclerosing granuloma occurring 3 years after injection of silicone into the vermilion. Intralesional prednisolone and systemic prednisone solved the problem within 4 months.

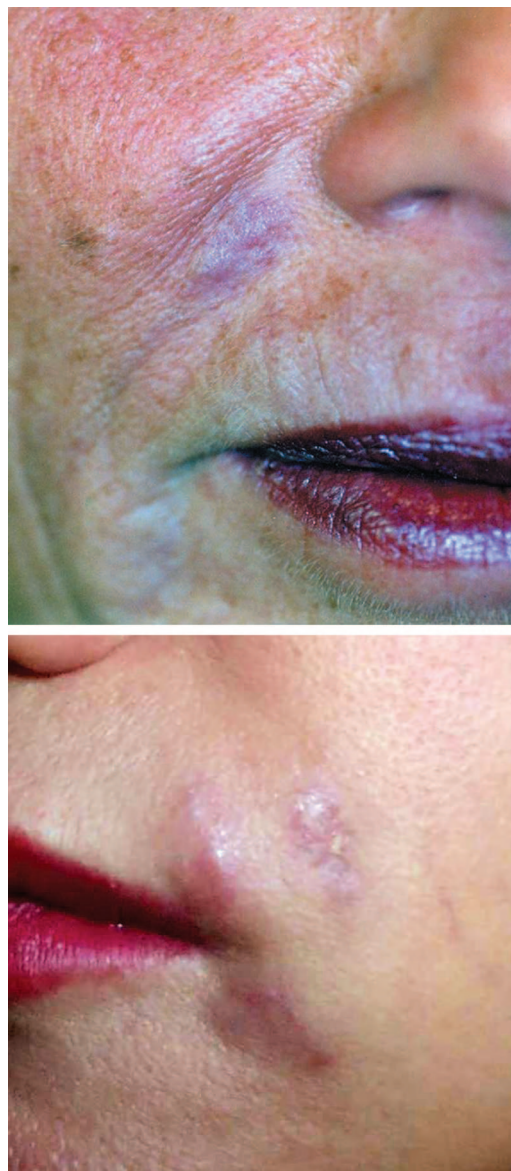

Fig. 8. (Above) Sclerosing granuloma (New-Fill) in both nasolabial folds. (Below) Sclerosing granuloma (Dermalive) with its typical bluish discoloration.

Matridex). “Sarcoid-like” granulomas^{35,47,48} (an outdated misnomer that threatens clinicians and patients) have also been related to a number of systemic diseases and/or proteins and chemical elements.⁴⁶ They can occur 6 to 24 months after injection and will remain for several years if left untreated. Clinically, the sclerosing foreign body granuloma is slowly developing with a mild inflammation (Figs. 2, 5, and 7, below). Over a few weeks, all implanted areas will appear visible, swollen, and rather hard and often bluish (Fig. 8).

The histologic signs of a genuine foreign body granuloma, however, are the widely separated spaces between the individual particles or microspheres, ranging from two to five times the diameter of a particle up to 100 μm (Fig. 9). The increasing number of invading macrophages and fibroblasts and the production of fibers cause a

wide separation of the particles or microspheres. This fact is important for the differential diagnosis of an implant nodule (Fig. 10), aside from the much higher number of giant cells in granulomas. Normal macrophages cannot phagocytize the larger particles or microspheres and fuse in the attempt to ingest the same particle.⁴⁶ Interestingly, the turnover rate of macrophages is striking: their half-life is only a few hours, whereas the half-life of a giant cell is approximately 7 days.⁴⁹ The granuloma infiltrates the surrounding tissue with fingerlike projections. There is no fibrous capsule surrounding the infiltrating granuloma and there-

F10

F8

F9

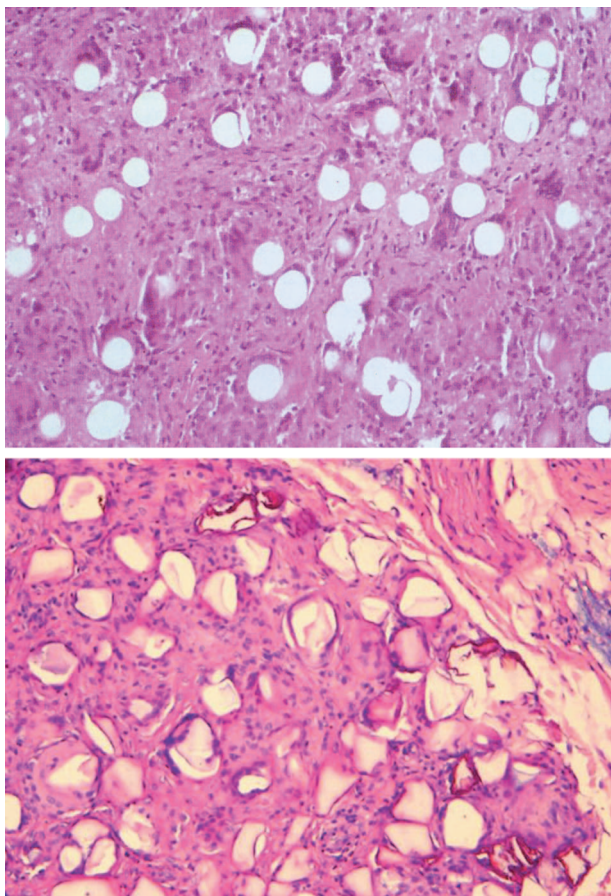


Fig. 9. (Above) Particulate fillers (Artecoll) can cause sclerosing granulomas. The spheres are pushed apart by the invading granulation tissue (hematoxylin and eosin; original magnification, $\times 100$). (Below) The number of (dark) giant cells is significantly increased in sclerosing granulomas (Dermalive) (hematoxylin and eosin; original magnification, $\times 100$).

fore no physical barrier between it and normal dermal elements. This single histologic feature is the best means for obtaining the correct diagnosis of a developing nodule or a true foreign body granuloma in the face. The identification of the type of injected filler⁵⁰ may be further supported by polarized light, which helps to differentiate birefringent (New-Fill) and nonbirefringent materials (e.g., collagen, hyaluronic acid, silicone, Artecoll, and Dermalive).

GRANULOMAS AFTER DIFFERENT FILLER SUBSTANCES

This section reviews the literature on granulomas secondary to various fillers. Although estimates of granuloma rates are presented in this section and in Tables 2 and 3, it is difficult to obtain reliable data for several reasons: (1) the number of patients treated was often only an es-

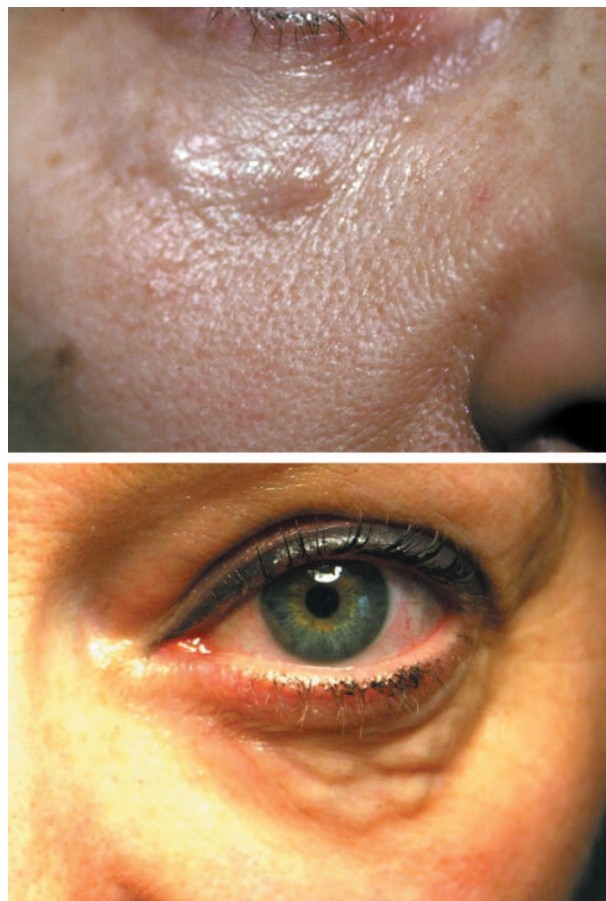


Fig. 10. (Above) Sclerosing granulomas (Sculptra) in both lower lids 5 months after injection. (Below) Typical implant nodules (Restylane) after subdermal instead of correct epiperiosteal injection in shadowed eyelids.

timate by the manufacturer based on the units of product sold; alternatively, the number of patients was sometimes based on a clinician's recollection of patients treated; (2) physicians are not required to report late adverse events to manufacturers or health authorities in most countries; and (3) the descriptions of adverse events in the literature are often anecdotal and incomplete. Therefore, the estimates given in Tables 2 and 3 are open to interpretation, and we invite commentary on these important data. For the purposes of this article, granulomas are defined as chronic inflammatory responses that appear at all injected sites at the earliest at 2 months and last for at least 2 months.

Silicone Fluid

Dow Corning introduced medical grade silicone oil (polydimethylsiloxane), also called liquid injectable silicone with a viscosity of 350 cS (100 cS

Table 3. Persistence of Implants from Literature, Estimated Numbers of Treated Patients from Manufacturers, and Granuloma Rates from Table 2*

Product	Persistence	Patients	Markets	Granuloma Rates	
				Authors	Manufacturers
Collagen (Zyderm, Zyplast)	6 mo	>5 million	United States, 1982 WW, 1983	~1:300	~1:2500
Hyaluronic acid (Restylane, Hylaform)	6 mo	>3 million	Europe, 1998 WW, 2001 United States, 2004	~1:250	~1:2500
PLA microspheres (Sculptra/New-Fill)	>12 mo	>250,000	Europe, 1999 United States, 2004	~1:400 (in 5 ml suspension)	~1:500
Ca-Ha microspheres (Radiance/Radiesse)	>12 mo	>150,000	United States, 2002 Europe, 2004	~1:600	Very few
pHEMA particles (Dermalive)	>12 mo	>200,000	Europe, 1998 Canada, 2003	~1:100	~1:500
PMMA microspheres (Artecoll)	Permanent	>400,000	Europe, 1994 WW, 1998 United States, 2006	~1:650	~1:5000
Silicone gel (3.5 cS)	Permanent	>400,000	United States, 1953 Banned, 1992	~1:1000	~1:1000
Polyacrylamide gel (Aquamid, Bio-Alcamid)	Permanent	>200,000	Russia, 1983 China, 1998 Europe, 2002	No data	~1:5000

WW, worldwide; PLA, poly-L-lactic acid; Ca-Ha, calcium hydroxylapatite; pHEMA, poly-hydroxyethyl-methacrylate; PMMA, polymethylmethacrylate.

*All numbers are open to discussion and debate.

is the viscosity of water), in the late 1950s for soft-tissue augmentation.^{5,41,42,51,52} It was approved by the U.S. Food and Drug Administration in 1964 but was banned in the United States and some other countries in 1967. The currently marketed silicone gels Silikon 1000 (Alcon Labs, Fort Worth, Texas) and Silskin (Richard-James, Inc., Peabody, Mass.) have a viscosity of 1000 cS and have to be judged differently. However, these viscous silicone gels still contain a certain amount of low molecular polymers to keep them pliable. Adatosil 5000 (Bausch & Lomb, Rochester, N.Y.) and Silikon 1000 have U.S. Food and Drug Administration approval for intraocular injections for the reattachment of the retina, but are not approved by the U.S. Food and Drug Administration for cosmetic purposes. However, the U.S. Food and Drug Administration's Modernization Act of 1997 allows the off-label use of approved materials for other indications such as the treatment of human immunodeficiency virus-associated lipodystrophy,¹⁵ wrinkles, and lip augmentation.⁵² Liquid injectable silicone appears to be safe when applied in small quantities using the microdroplet technique.

Public pressure for longer lasting fillers and the introduction of the microdroplet technique have led to a revival of silicone gels and their off-label use in cosmetic surgery in the United States.^{5,28,51-53} Jones et al.²⁸ have reported that their patients have not yet experienced foreign body granulomas after using the serial puncture tech-

nique to administer liquid injectable silicone. In Europe, the wide use of liquid injectable silicone in small quantities for lip augmentation seems to have yielded the lowest rate of foreign body granulomas in the lip compared with other permanent fillers.

Histologically, silicone fluid stimulates only a very-thin-walled fibrous capsule so that dislocation by gravity along fascia and muscle planes can occur in patients with loose connective tissue³⁶ ("migration" is a misnomer because nonliving silicone droplets cannot migrate). Late sclerotic reactions (Fig. 7, below, and Fig. 11, left) can develop around free silicone oil,⁵⁴ as they are well known after "bleeding" from earlier breast implants. A silicone foreign body granuloma shows the typical vacuolated spaces measuring 1 to 30 μm in diameter, surrounded by numerous histiocytes (macrophages), lymphocytes, plasma cells, some eosinophils, and scattered giant cells.⁵⁵ Macrophages and giant cells contained multiple cytoplasmic vacuoles with Swiss cheese pattern.

In 10 volunteers who were injected with 350 cS silicone,³² lymphocytic infiltration with characteristic delayed hypersensitivity was observed. Immunohistologically, small local deposits of immunoglobulin G and immunoglobulin A were observed around the walls of small vessels. In later biopsy specimens, the inflammation had progressed to a fibroblastic reaction. In addition, the implanta-

F11

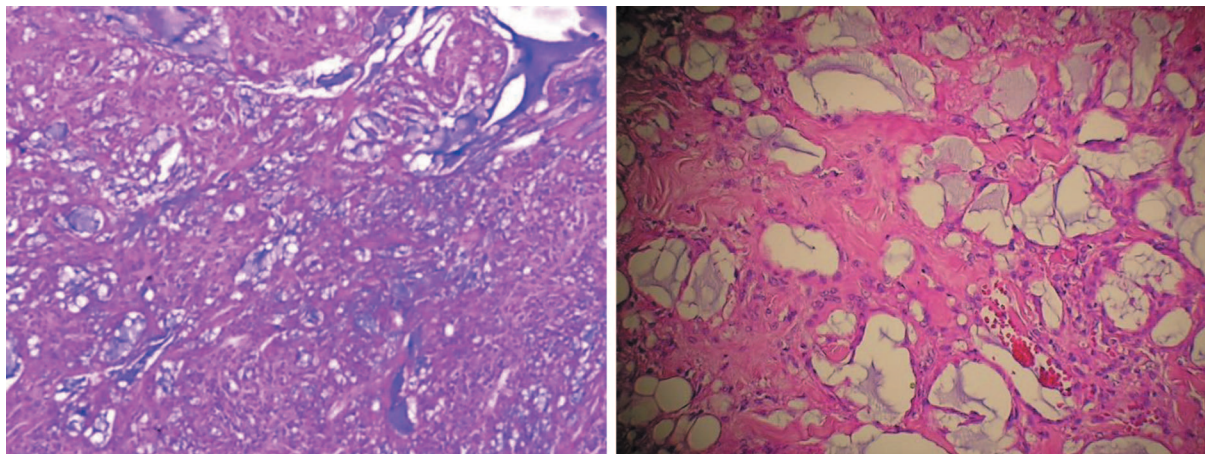


Fig. 11. (Left) Fluid implants (silicone 350) can cause sclerosing granulomas as well. The droplets are slowly phagocytized (hematoxylin and eosin; original magnification, $\times 40$). (Right) Sclerosing granulomas after fluid filler (Aquamid) can appear like those after particulate fillers (hematoxylin and eosin; original magnification, $\times 100$).

tion of large doses appeared to provoke giant cell granuloma.³²

The amount of early literature on complications after liquid injectable silicone injections is quite remarkable.⁵⁶⁻⁵⁹ Clinically, the edematous granulomas appeared suddenly, like an allergic reaction, with redness and extreme swelling and multiple areas of firm, fixed, but rather soft nodules (Fig. 12). No pain was involved, but submandibular adenopathy was often disturbing and palpable. However, what was more impressive was the rather late onset of foreign body granuloma at 10

F12,AQ:5

to 15 years after injection.^{5,56,60,61} Therefore, the U.S. Food and Drug Administration limited liquid injectable silicone use in 1965 to a certain number of patients of selected investigators.^{51,57} The outcome of this clinical trial on patients with hemifacial atrophy, however, was disappointing. A report of Dow Corning to the U.S. Food and Drug Administration in 1990 stated two foreign body granulomas in 128 patients.⁵² The clinical use of silicone fluids continued in Latin America, Europe, and Asia^{51,60,61} with some serious late reactions.^{38,42,56-59} Silicone foreign body granu-

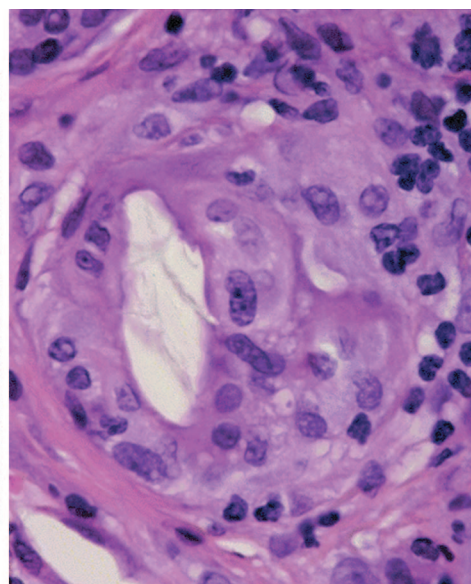
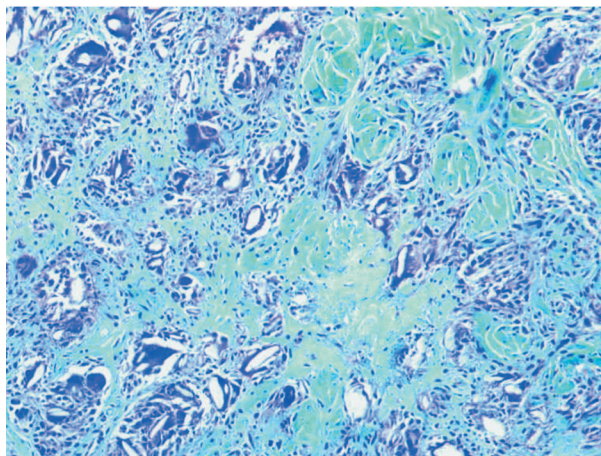


Fig. 12. (Left) Massive fibrosis is a typical sign of sclerosing granulomas (New-Fill) (Masson trichrome; original magnification, $\times 100$). (Right) A microsphere (New-Fill) in the process of absorption is surrounded by giant cells and lymphocytes (hematoxylin and eosin; original magnification, $\times 200$).

loma developed even at the entry points after acupuncture with siliconized needles.⁶²

For a long time, the early, rather high rates of foreign body granuloma after silicone fluid injections were blamed on non-medical-grade silicones^{28,61} and adulterants (the Japanese formula) intended to keep the silicone from migrating by stimulating the formation of a fibrous capsule.³⁸ However, even medical-grade fluid silicone applied in small droplets caused foreign body granulomas.^{62,63}

Bovine Collagen (Zyderm and Zyplast)

Bovine collagen in Zyderm and its cross-linked form Zyplast (Allergan-Inamed Aesthetics, Santa Barbara, Calif.) were introduced in 1981 and 1983, respectively. Both have maintained their safety standards and are still considered the standard of injectable dermal fillers.¹⁸ Collagen is one of the least toxic and least irritating biomaterials known. Histologically, nonliving bovine collagen differs from native collagen by staining paler and being less fibrillar and by its nonbirefringence under polarized light. After bovine collagen injection, there is a mild perivascular lymphohistiocytic infiltrate, which appears as early as 7 days and gradually resolves by 3 months.³⁶ There is little evidence of active cellular degradation or foreign body reaction to bovine collagen but, at the same time, it is not colonized by active fibroblasts. Even if bovine or human collagen implants are the least toxic and least irritating injectable biomaterials known,³⁷ erythematous dermal nodules can develop at the implantation sites.^{6,15,16,64,65} They often convert into localized tissue necrosis (Figs. 1, below, and 5, above) and occur in approximately one in 1000 patients.³⁹ In a report on more than 5000 patients receiving injectable collagen, 67 (1.3 percent) developed adverse reactions.¹⁵ Of these, 15 were clear late foreign body granulomas (0.3 percent), which resolved under steroid therapy within 1 year. In contrast, a questionnaire sent to 36 physicians using Resoplast, the denatured bovine collagen used in Artecoll, revealed only one questionable allergic reaction among 1280 patients (Rofil 1997, data on file). In another clinical trial of bovine Atelocollagen (Koken Ltd., Tokyo, Japan), eight of 656 (1.2 percent) patients reacted with an "abscess" of long persistence.¹⁶ The same reaction of an indurated papule containing macrophages and giant cells has been described after the injection of human collagen (Dermalogen).⁶⁵ In this case, it disappeared after 2 months, and a second test injection showed no positive reaction.

One patient experienced polyarthralgia over the entire period of the bovine collagen effect³⁵ and another patient developed a histologically similar granuloma annulare at the site of the collagen test injection.⁶⁴

Hyaluronic Acid (Restylane)

The human body contains only approximately 15 g of hyaluronic acid, which is found mainly in the connective tissue and whose primary function is to bind water. The half-life of an injected molecule is only 1 to 2 days. Therefore, manufacturers have cross-linked molecules to achieve up to 3 to 6 months' duration with injectable hyaluronic acid. Restylane (Q-Med, Uppsala, Sweden; and Medicis, Scottsdale, Ariz.) was introduced in 1997 and has become the number one filler worldwide. There is no statistical proof that it lasts longer than the collagen products. It is absorbed by mechanisms similar to those of collagen, mainly by hydrolytic enzymes, some macrophages, and scattered giant cells.³⁶ Early reported complications such as longer lasting erythema and induration have been blamed on fermentation residues from *Streptococcus equi*.^{2,8,9,21} Similar products of bacterial origin are Captique (Allergan-Inamed Aesthetics, Santa Barbara, Calif.) and Juvederm (Allergan-Inamed) in the United States, now Surgiderm in France (Corneal Laboratories, Pringy, France).

Late complications of cross-linked hyaluronic acids appear to be similar to those reported for collagen. A number of publications between 2000 and 2006^{8,19,66-75} describe more than 60 anecdotal late adverse events such as localized granulomatous inflammations (Fig. 1, right). André²⁰ reported a granuloma rate of one in 240 patients (0.4 percent), but Bergeret-Galley⁶⁶ refers to a rate of 12 foreign body granulomas in 10,000 patients (0.1 percent) before further cleaning of Restylane during manufacturing was implemented in 2000, and four cases in 10,000 patients (0.04 percent) since 2000. Friedman et al.²¹ mention "rare" reports of localized granulomatous reactions and acneiform and cystic lesions in an early review of 406,000 patients treated with Restylane worldwide. The number of patients was the same as the number of syringes sold. This shows the difficulty of calculating any relation between granulomas and injected patients. Lowe et al.¹⁹ found three late reactions (0.4 percent) among 709 of their own patients. A less realistic number is provided by a single author,⁷² who saw 10 Restylane patients among 500 developing late granulomas (2 percent) and a 0.4 percent incidence of early inflam-

matory reactions. Late foreign body granulomas after hyaluronic acid developed 2 to 11 months after injection and lasted 2 to 10 months without treatment.^{20,75}

Histologically, hyaluronic acid foreign body granulomas consist of a palisaded granulomatous tissue with macrophages and giant cells (Fig. 3),⁶⁹ often encapsulating the injected hyaluronic acid like a sterile abscess or a cystic granuloma, which prevents hyaluronic acid from absorption. Whether these are delayed hypersensitivity reactions or a special type of foreign body granuloma has yet to be determined. In some cases,^{19,67,71} histologic examination showed predominantly lymphocytic and plasma cell infiltrates with scattered giant cells. An impressive histologic photograph is shown by Fernandez-Acenero et al.⁷¹

Hyaluronic acids (Hylan G-F 20, Synvisc; Genzyme Corp., Cambridge, Mass.) are also injected into osteoarthritic knee joints. Several cases of granulomatous inflammation with palisading granulomas and prominent histiocytic and giant cell cuffing required synovectomy.⁷⁶

Polymethylmethacrylate Microspheres (Arteplast/Artecoll)

Artecoll (Rofil Medical B.V., Breda, The Netherlands) was a 20% suspension of microspheres of polymethylmethacrylate in bovine collagen. Two similar successor products are Artesense (European Medical Contract Manufacturer, B.V., Nijmegen, The Netherlands) and BeautySpheres (Rofil Medical). Polymethylmethacrylate powder has been used as bone cement for over 50 years in millions of patients. The microspheres are round, 30 to 42 μm in diameter, and have a smooth surface. The collagen is replaced first by a granulation tissue and then later by a fibrous tissue. The microspheres act as a stimulus for constant tissue regeneration so that, ultimately, the Artecoll implant consists of 80 percent of the patient's own connective tissue.¹⁰

Artecoll's predecessor, Arteplast (Artepharma, Frankfurt, Germany), contained a high number of small particles ($<20 \mu\text{m}$) that became adherent to the microspheres by static electricity during dry sieving. This was the cause for the high (2.5 percent) rate, until 1994, of foreign body granulomas.⁷⁷⁻⁷⁹ When the dry sieving process was changed to wet sieving in 1994, the number of nanoparticles in Artecoll was reduced drastically and the rate of granulomas dropped below 0.2 percent between 1995 and 2002.¹⁰ In January of 2003, the U.S. Food and Drug Administration be-

gan requiring even stricter controls on the purity of the microspheres for U.S. clinical testing. One of the byproducts of these stricter controls is ArteFill, a third-generation polymethylmethacrylate-based filler that has substantial improvements, including microspheres that have enhanced uniformity and consistency, compared with the second-generation polymethylmethacrylate product Artecoll.

True sclerosing foreign body granulomas after Artecoll implantation (Figs. 5, *below*, and 13, *above*) have been reported since 1994^{7,10,36,50,77-83} and, from all the cases reported to the manufacturers worldwide, the occurrence is estimated at 0.02 percent (Tables 2 and 3). Rofil calculated that 400,000 patients had received Artecoll so far. Since 1994, the developer of Artecoll (G.L.) has collected a total of 52 foreign body granulomas from Rofil's files, the literature, and his worldwide contacts, including seven among his calculated 3500 patients. Recently, Alcalay et al.,⁸⁰ Kim et al.,⁸¹ and Carruthers and Carruthers⁸² described granuloma formation in glabellar, nasolabial, and horizontal neck folds, which finally resolved after Kenalog (Bristol-Myers Squibb, New York, N.Y.) injections or even spontaneously. In one patient,⁸² a longstanding lesion after a pencil poke of graphite in the forehead became inflamed at the same time as the onset of granuloma.

Clinically, the foreign body granuloma develop many months or years after implantation. In a matter of weeks and at approximately the same time, all injected areas show a mild inflammation. Nodules become visible, rather hard, and often bluish, with congested dermal capillaries on their surface.

The pathologists Requena et al.⁵⁰ and Lombardi et al.⁷ gave a detailed description of Artecoll foreign body granulomas. Histologic examination reveals round, empty vacuoles (after dissolution of the polymethylmethacrylate in alcohol) widely separated from one another, spanning two to three times the diameter of a microsphere, instead of the usual 0.5- to 1-fold distance (Fig. 9, *above*). The tissue between the vacuoles consists of many multinucleated giant cells and macrophages attached to the vacuoles, with many fibroblasts and collagen fibers. Occasionally, lymphocytic infiltrates and epithelioid cells are seen.

Polylactic Acid Microspheres (New-Fill/Sculptra)

Sculptra (formerly New-Fill) is a 3% suspension of microspheres of 40 to 63 μm in diameter,

F13

AQ: 6

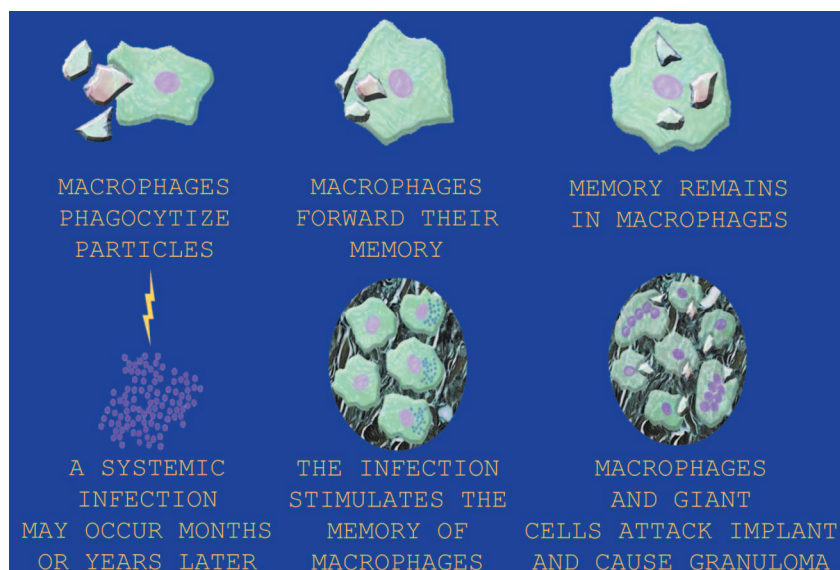


Fig. 13. Hypothesis of a possible mechanism of late granuloma formation. The chemical structure of the filler substance is stored in the macrophages, which transfer their memory to the next generations. Sudden local or systemic bacterial or viral infections can stimulate this memory and prompt a new attack.

composed of 150 mg crystalline poly-L-lactic acid, and suspended in methylcellulose (Aventis/Dermik, Berwyn, Pa.). It was introduced to the European market in 1999 with recommendations to dilute the lyophilisate in 3 ml of water for injection and to implant it intradermally and subdermally. By 2002, intradermal implantations were abandoned and the dilution was raised to a minimum of 5 ml, resulting in a lower rate of granulomas. Sculptra was introduced to the U.S. market in 2004.

In surgery, aliphatic polyesters have been used safely and widely in absorbable suture materials [Vicryl (Ethicon, Inc., Somerville, N.J.) and Dexon (Tyco International, Inc., Princeton, N.J.)], which are absorbed within 3 to 6 months by hydrolytic enzymes and a few macrophages, lymphocytes, and scattered giant cells.^{7,84} Larger quantities of crystalline poly-L-lactic acid suspension injected into cheeks and temples of human immunodeficiency virus–positive individuals with facial lipodystrophy may last for up to 2 years.^{85,86} A relatively high number of these patients (10 to 44 percent) developed many palpable but nondisturbing nodules of 3 to 5 mm in size in their cheeks after months, which lasted over the entire observation period of 96 weeks.

It might well be that suspending the microspheres in 5 ml and using the microdroplet technique prevents this common nodule formation, which may be attributable to clumping of the beads right after injection and late tissue in-

growth. Poly-L-lactic acid is dissolved partly by hydrolysis and partly by phagocytosis. The lactate enters the Krebs cycle and is metabolized to carbon dioxide and water. Injected poly-L-lactic acid microspheres cause a typical foreign body reaction (Fig. 12, right), which is the true histologic basis of the filling effect and not fibrosis as reported^{85,86}: the moment the last poly-L-lactic acid bead is absorbed, the induced fibrosis recedes as well.³⁶ Poly-L-lactic acid has an excellent biocompatibility profile, but the occurrence of foreign body granuloma to poly-L-lactic acid suture materials, usually in form of extrusions, is well known to surgeons. In orthopedic surgery, poly-L-lactic acid in absorbable plates and screws may produce delayed hypersensitivity reactions, resulting in the development of foreign body granuloma.

Similarly, anecdotal cases of foreign body granuloma after New-Fill injections have been reported.^{3,72,81,87–95} These develop within 6 to 24 months after implantation (Fig. 8, above) and generally respond to high doses of intralesional triamcinolone. If left untreated, they remain for 2 to 5 years. The occurrence and description of foreign body granuloma varies from one author to another,^{24,72,87,96} and an estimated rate of 0.25 percent appears to reflect the reality (Table 2). The rate is expected to further diminish because the dilution of the beads has been raised to 5 ml. In general, poly-L-lactic acid nodules are rather small, with compressed microspheres, and there-

fore do not react well to steroid injections. In other cases with extreme granulation tissue (Fig. 12) and as shown in Figure 1 of the article of Wolfram et al.,⁹⁷ steroids will reduce the granulomas significantly. Histologically, one finds numerous translucent particles of irregular shape and size, which can no longer be called microspheres (Fig. 12). Some of these are very small and spiky because of hydrolysis of the surface. The particles are birefringent in polarized light and are surrounded by macrophages and mild lymphocytic infiltrates. Some giant cells contain asteroid bodies.⁷

Poly-Hydroxyethyl-Methacrylate Particles (Dermalive)

Dermalive (Dermatech S.A., Paris, France) is a 40% suspension of resorbable poly-hydroxyethyl-methacrylate fragments (10 to 60 μm) in cross-linked hyaluronic acid of bacteriologic origin.¹⁴ Dermalive was a byproduct of the manufacture of intraocular lenses sorted out from those used for refractory purposes and was introduced in the European market in 1998. Because of a rather high incidence of foreign body granulomas, it is now used mainly in the form of DermaDeep, with hydroxyethyl-methacrylate fragments 80 to 110 μm in size, used for deep dermal and epiperiosteal implantation. Inside the implant, the poly-hydroxyethyl-methacrylate particles are packed closely,³⁶ probably because of diminished viscosity of the carrier medium hyaluronic acid. This carrier dissipates from the particles just after implantation of Dermalive and is found in separate lakes outside of the clusters of particles.³⁶

The great advantage of collagen as a suspension medium for filler substances is its high viscosity, which still keeps the particles or microspheres apart weeks after implantation.³⁶ Because little host tissue formation is stimulated, more Dermalive has to be injected compared with other fillers. In contrast, poly-hydroxyethyl-methacrylate has a free hydroxyl group, which should stimulate macrophage activity. Endogenous esterases in serum and liver break down poly-hydroxyethyl-methacrylate. Interestingly, the amount of tissue reaction is not an indication of the rate of granuloma formation. Dermalive causes the least foreign body reaction after injection, but reports indicate that it causes the highest rate of late foreign body granulomas (Figs. 2, 6, and 8, *below*) in Europe (Tables 2 and 3). The 0.1 percent incidence (1.2 in 1000 patients) of side effects¹⁴ reflects the claims of the manufacturer. Foreign body granulomas can occur 4 months to 3 years after Dermalive injections^{7,48,97-102} and probably later.

The histologic characteristics of Dermalive appear promising within the first few months because the hydrophilic polygonal, translucent, non-birefringent particles swell and round up.³⁶ Tissue ingrowth is absolutely normal and resembles the picture of an ideal biocompatible substance. The carrier hyaluronic acid separates from the particles within the first days after injection and is found in lakes nearby. If granuloma formation occurs, lymphocytic infiltrates increase and the fibrillar network thickens (Fig. 9, *below*). Giant cells appear suddenly, some of them containing asteroid bodies, and form islands in a more patchy distribution.^{7,50} Some patients react with discoloration and telangiectasia (Fig. 8, *below*); others, with edematous sclerosis in the surrounding dermis (Fig. 6, *below*).

Calcium-Hydroxylapatite Microspheres (Radiance/Radiesse)

Microspheres of this well-known constituent of bone and teeth suspended in methylcellulose had been developed for the treatment of urinary incontinence³⁷ and received U.S. Food and Drug Administration approval for injection into a paralyzed vocal cord, as a tissue marker, and as onlay grafts in oral surgery. Since October of 2001, Radiance FN (now Radiesse), a suspension of round, smooth, 25- to 45- μm calcium-hydroxylapatite microspheres suspended in methylcellulose, has been used off-label in the United States for wrinkle treatment and lip augmentation. It received U.S. Food and Drug Administration approval for human immunodeficiency virus-associated lipodystrophy and nasolabial folds in 2006.

Although Radiesse is well tolerated beneath wrinkles, it should not be recommended for lip augmentation. The concomitant movement of the orbicularis muscle in patients during chewing compresses every injected strand to a lump (Fig. 2, *above*). A relatively high incidence of nodule formation¹⁰³⁻¹⁰⁵ has led to caution in its use in lip augmentation; however, true granuloma formation in the above sense has been reported only twice to the main clinical investigator (M. H. Graivier) in approximately 35,000 patients treated between 2002 and 2004 in the United States. Two male patients with acne received Radiesse in many depressed scars in both cheeks and developed foreign body granulomas mainly in three areas of $3 \times 2 \times 0.5$ cm, dimensions that were far beyond those of the injected sites. Low doses of steroids up to 15 mg caused only short-lived improvement, and as a result, the largest inflamed area was ex-

AQ:7

cised. This may be attributable to its extreme biocompatibility [e.g., a scarce cellular reaction and few macrophages but no giant cells (“osteoclasts”) that Radiesse stimulates³⁶] and to the dissolution of the calcium microspheres through predominantly enzymatic activity.

The only study on long-term effects and adverse events of 609 patients after Radiesse treatment¹⁰⁰ revealed 42 of 338 subjects (12.4 percent) with lip nodules. However, histologic examination of one excised nodule (their Fig. 5) clearly shows a foreign body granuloma—and not “densely packed” microspheres as histologic examination of a normal Radiesse specimen does.³⁶ On normal histologic examination, the calcium hydroxylapatite microspheres do not “provide a scaffold for tissue infiltration consistent with the form of the surrounding tissue.” Because of little tissue ingrowth and absence of granulation tissue,³⁶ triamcinolone injections into Radiesse nodules will be ineffective and should be avoided. In some patients, however, Radiesse microspheres may induce a type of foreign body reaction, which of course will react to intralesional corticosteroids.¹⁰⁴

Polyacrylamide Gels (Aquamid and Bio-Alcamid)

Polyacrylamides are used as flocculents in industrial water clarification, such as dextran beads, and in protein electrophoresis. Aquamid is a clear, 2.5%, crosslinked gel of polyacrylamide (polymethylmethacrylate) (Contura International S.A., Copenhagen, Denmark). It is approved in Europe but not in the United States. The manufacturer of a similar product, Bio-Alcamid (Polmekon, Milan, Italy), reveals its chemical formula as polyalkylimide.¹⁰⁶ The basic component of Bio-Alcamid is probably the Russian polyacrylamide but crosslinked with imide-amide and an additional alkylene group (U.S. patent 20,040,209,997). It is approved in Europe, Israel, and Mexico. The U.S. Environmental Protection Agency classified the monomer acrylamide as a medium-hazard probable human carcinogen¹⁰⁷ because its oral application caused stomach tumors in animals. However, orally consumed monomers of acrylamide have no negative effect in humans.¹⁰⁸

The use of polyacrylamide as an injectable filler material was initiated in 1983 and applied clinically in Russia in 1990 as Formacryl^{12,13} (Interfall Ltd., Kiev, Ukraine, now relocated to Bulgaria) and in China as Interfall or “Amazing Gel” (FuHua Aesthetics Ltd., Shenzhen, China) in thousands of patients. Since Interfall’s European

patent expired, at least five European companies are marketing polyacrylamides as dermal filler substances: Formacryl, Interfall, Argiform (contains antibacterial silver ions), OutLine (absorbable), Aquamid, Evolution (contains nonresorbable microspheres in fast absorbing polyacrylamide,³⁶ and Bio-Alcamid. They differ in molecular weight, cross-linking, and viscosity.

In Russia and China, Formacryl and Interfall have been injected in large quantities for breast, buttock, and calf augmentation, and in facial lipodystrophy and congenital malformations.¹² Results of large volumes are durable in the majority of patients. It reportedly has a half-life in the human body of more than 20 years. This may be true for large quantities; however, the injection of 0.1 cc of Aquamid was absorbed in human skin within 9 months.³⁶

Its clinical and histologic behavior is very similar to that of silicone fluid. In patients with very loose connective tissue, larger quantities can “migrate” or, more accurately, dislocate from the face to the neck, from the breast to the groin, and from the buttock to the hollow of the knee.¹⁰⁹ In an early stage after implantation, it can be withdrawn through a 14-gauge needle if overcorrection or dislocation should occur. The reason for its ease in dislocation is its good biocompatibility, which does not stimulate much capsule formation and even less cellular ingrowth.¹⁰⁹ It would be the ideal filler (like silicone fluid) if it were not followed by a rather high rate of late complications.

Polyacrylamide foreign body granuloma are in general of the inflammatory or edematous type (Figs. 6 and 7, *above*). They begin often with a granulomatous stage containing basophilic mononuclear cells and giant cells (Figs. 3 and 11, *right*). This stage of delicate capsule formation is followed by a seromatous stage, with fluid accumulation within the capsule and consequent pressure, pain, and surrounding edema.¹¹⁰ Perivascular and focal aggregates of lymphoid cells form an anti-inflammatory wall around the endoprotheses. Together with macrophages that have phagocytosed polymethylmethacrylate, these walls can lead to sterile abscess, necrosis, and perforation.¹¹⁰ Stab incisions led generally to fistula formation (Fig. 4). The presence of bacteria in the biofilm surrounding polyacrylamide¹¹¹ has been suggested as a cause of foreign body granuloma, but proof of this is still insufficient. Why should a wall of macrophages succumb to bacterial infection?

It is estimated that approximately 30,000 patients in Kiev¹¹⁰ received polyacrylamide injections. There have been approximately 20 articles in

the Russian, Chinese, and Polish literatures^{109–112} published in the past 4 years with figures and descriptions of dislocated, perforated, and hardened endoprostheses, which are difficult to remove. The Russian authors describe severe side effects after polyacrylamide injections,^{109–112} of which three-fourths of the reported complications were palpable indurations, probably all foreign body granulomas. Other complications reported were enlarged and palpable lymph nodes in 12 percent, migration of gel in 3 percent, and edema in 2 percent.¹¹³ The onset of 10 infections and eight granulomas after polyalkylimide (Bio-Alcamid) injections ranged from 1 month to 3 years.¹¹⁴

The Chinese articles mention an overall complication rate of 1.4 to 18.2 percent,^{115–117} among which palpable indurations and aseptic inflammations are the most frequent. The total incidence of complications was 12 percent among 800 patients treated in Foshan, China.¹¹⁶ Among another 42 patients with complications in Wuhan were 24 with indurations and 10 with aseptic inflammation, though all were eventually resolved.¹¹⁶ In our own experience with Aquamid (M.W.) in 35 patients, one developed a foreign body granuloma after 5 months. The first two patients with foreign body granulomas after Aquamid injections in the United States have been described recently.¹¹⁸ Apparently, polyacrylamides have recently been banned as injectables in Russia and Bulgaria,¹⁰⁹ and China is considering a similar step.¹¹⁹

Dextran Microspheres (Reviderm Intra and Matridex)

Another synthetic substance, used as a urinary bulking agent against incontinence, is also a dermal filler and composed of dextran microspheres suspended in hyaluronic acid as Reviderm Intra (Rofil Medical) and Matridex (Biopolymer GmbH, Montabaur, Germany). The latter is in clinical trials in the United States (AART, Inc., Reno, Nev.). Both stimulate heavy granulation tissue³⁶ but have been on the market for too short a time to provide an idea of late complications. A dextran granuloma has been described causing urinary obstruction.¹²⁰

POSSIBLE CAUSES OF GRANULOMA FORMATION

The volume of injected dermal fillers^{5,28} has been considered as one cause of foreign body granuloma formation, even though a macrophage 10 to 20 μm in diameter cannot recognize whether the foreign material it is supposed to phagocytize is 2 mm or 2 cm in diameter. Repeated injections

using the microdroplet technique produce a much larger surface area than single injections of 1 ml of gel or fluid; thus, this technique would theoretically stimulate many more macrophages. Also, there is no proof today that the additional injection of a different filler into the same location will trigger or activate a foreign body granuloma of the prior one.

The impurities within a filler substance²⁸ have been blamed as a reason for later granuloma formation. In the case of Arteplast/Artecoll/ArteFill, the significant decrease of granulomas correlated well with the drastic decrease in the number of small particles (<20 μm) in each product.¹⁰ Obviously, phagocytosis and therefore the immunologic memory of macrophages are stimulated far more efficiently by many small particles than by a few large ones (Fig. 13).

Concerning possible impurities implicated in injectable fluids such as silicone and polyacrylamide, the use of the term “medical grade” does not mean fewer impurities. In reality, a medical-grade product has the same composition as the industrial-grade version but has been subjected to more biological testing (e.g., toxicity, pyrogenicity, histology) and has been submitted in a master file to the U.S. Food and Drug Administration.¹²¹

Interestingly, the extent of early foreign body reaction does not relate at all to later formation of foreign body granulomas, as seen in the cases of Dermalive, silicone, and acrylamides, which show the same lack of cellular ingrowth as Radiesse³⁶ during the first months after injection. In contrast, the irregularity of the particle surface does appear to be a cause for increased granuloma formation: the best examples are the polytetrafluoroethylene flakes, the Bioplastique “dermal diamonds,” and the Dermalive particles with pointed edges and corners (Fig. 9, *below*).

The only events that have been determined so far to cause foreign body granulomas are severe systemic infections.^{10,26,57,122,123} Patients with permanent injectables should be warned and antibiotic intake at the onset of a severe infection should be recommended for the next 10 years after implantation.

One of us (N.G.-H.) saw foreign body granulomas on Artecoll implantation occur 1 month after an episode of severe bronchitis, another after surgery for sinusitis, and 2 after acute abdominal infections. In one case, the foreign body granuloma developed 2 years after Artecoll injection and 3 months after the diagnosis of an autoimmune thyroiditis. Another patient with hyperthyreosis diagnosed 2 years after Artecoll injec-

tions also developed foreign body granuloma, which disappeared with thyreostatic treatment.¹²⁴ One patient injected with liquid injectable silicone for lip augmentation developed a silicone foreign body granuloma 6 years after the procedure and 8 months after the onset of a systemic sarcoidosis. After New-Fill implantation, one patient developed a granuloma right after the discovery of an advanced breast cancer (N.G.-H.), another one at the onset of a vocal cord tumor, and one at the onset of hormone replacement therapy. Christensen et al.¹²⁵ described a patient who had a face lift 2 months before onset of a foreign body granuloma. One of us (G.L.) saw a woman who developed temporary redness and swelling of all Artecoll implantation sites each time she took pyritinol (Encephabol; Merck & Co., Whitehouse Station, N.J.).

Bergeret-Galley et al.¹⁴ report that the 12 percent of their patients who developed foreign body granulomas did so during or after infections (bronchitis, pharyngitis, sinusitis) or severe psychological shock. Bigata et al.⁴ described a patient who developed a granulomatous lip 8 months after silicone injections and 1 week after a flu-like syndrome. A case of pleurisy as the cause of granulomas with scleromyxedema of the skin after hyaluronic acid injection has also been described.¹⁹ Another patient developed severe flu with pyelonephritis and subsequent inflammatory redness at all injected sites. She refused antibiotics and steroids because she was lactating. However, the redness and infiltration in her face subsided when she subsequently took antibiotics and steroid injections.

Fischer et al.¹²⁶ described a patient with hepatitis C who was treated with interferon (peginterferon alfa-2a) and antiviral riboflavin. Ten weeks after she began therapy, she developed facial edema and a cystic granuloma in areas that were injected with Arteplast/Artecoll 10 years before. From this one case, the authors conclude that immunostimulatory medications can lead to an exacerbation of low-grade inflammation and granuloma formation of permanent fillers. As a counterpoint to their conclusion, it should be noted that Sculptra is used extensively on human immunodeficiency virus-positive patients who are under some type of immunostimulants.

Obviously, granuloma formation is a single event triggered by an infectious, traumatic, or pharmacologic stimulus (Table 4).^{2,10,11,17,19,25,26,57,71,118,122,125-128} If it is treated early and with sufficient high doses of corticosteroids, it does not recur.

Table 4. Anecdotal Cases Pointing to Possible Causes of Granulomas*

Causes of Granuloma	References
Systemic infections	10, 17, 57, 122, 125
Acute sinusitis	11, 122
Pharyngitis	11
Otitis media	122
Dental abscess	122
Bronchitis	11, N.G.-H.
Pneumonia	M.W.
Pleurisy	19
Enteritis	N.G.-H.
Flu-like syndrome	2
Cystic acne	25
Furuncle	118
Vaccination	G.L.
Multiple injections	127
Severe flu	M.W.
Hyperthyreosis	26, M.W.
Colitis ulcerosa	125
Morbus Crohn	125
Pemphigus	125
Sarcoidosis	N.G.-H.
Breast cancer	N.G.-H.
Psychological shock	11
Encephabol	G.L.
Facial trauma	G.L.
Face-lift operation	125
Autoimmune thyrosis	N.G.-H.
Herpes labialis	71
Interferon	126
Pregnancy	128

*Reported possible correlations to infections or trauma that occurred 3 to 6 months before the clinical onset of foreign body granuloma.

CONCLUSIONS

The pathogenesis of foreign body granulomas is still not known. The injection of large volumes as a causative reason has been discussed^{5,28} but is still lacking statistical proof. The same is true for the microdroplet technique, which may theoretically prevent lumping and hardening but not foreign body granulomas. Chemical and particulate impurities have been blamed convincingly^{10,26,28} because the foreign body granuloma rate of almost all filler substances has decreased as product improvements have been developed over the years.^{10,66}

Dormant allergens with low immunogenicity are able to produce a clinical response during the boost in the immune system that occurs with infections and with highly active antiretroviral therapy (immune reconstitution syndrome). The memory of macrophages and the mechanism of a later trigger such as infection or drugs could explain the unpredictability of foreign body granuloma (Fig. 13), even many years after the absorption of the implant.⁶ Macrophages are known to be memory cells even if they move away once degradation is complete.⁴⁶ In contrast, the lack of later

proof of antibodies, eosinophilic cells, and positive skin tests does not exclude the possibility that the trigger of certain foreign body granulomas may be a late (type IV) cellular allergic reaction.

Longer and wider use of an injectable produces more patient exposures and the potential for a higher number of reported side effects. A recent collection of 1200 foreign body granulomas in Brazil¹²⁹ revealed 106 from Metacril and other polymethylmethacrylate products, 158 from collagen injections, 171 from hyaluronic acids, 50 from Interfall, 452 from Dermalive, and 263 from other injectables. Calculated estimates of the rate of foreign body granulomas vary between one in 100 and one in 25,000 patients, depending on the credibility of the reported adverse events of the injectables used (Table 3).

On both sides of the debate surrounding absorbable versus nonabsorbable fillers, the medical community has adherents of almost religious-like fervor. Unfortunately, the effect of autologous fat injections¹³⁰ still lacks even one report with statistical data. One fact, however, is undisputable: the deeper the implants are injected, the less the possibility of foreign body granuloma formation (see Bioplastique/Macropastique or Dermalive/DermaDeep). The dermis by far is the organ most sensitive and prone to immunologic reactions. Therefore, subdermal injections into the dermal-subdermal junction will cause fewer foreign body granulomas than intradermal injections.

All filler materials have side effects that can be diminished but not eliminated. We as physicians should be aware of the rate of adverse events of each injectable filler substance and should not rely on the claims of the manufacturers, but eventually on the reports of an independent central registry of dermal fillers that is still to be established. Better knowledge of the basics and honesty in reporting will bring improvement and safety and effective treatment of side effects into this expanding field.

Gottfried Lemperle, M.D., Ph.D.
302 Prospect Street
La Jolla, Calif. 92037
glemperle@aol.com

REFERENCES

- Rohrich RJ, Rios JL, Fagien S. Role of new fillers in facial rejuvenation: A cautious outlook. *Plast Reconstr Surg.* 2003; 112:1899.
- Lowe N. New filler agents: What can we learn from Europe? *Pract Dermatol.* 2004;6:29.
- André P, Lowe NJ, Clerici TH, Zimmermann U. Adverse reactions to dermal fillers: A review of European experiences. *J Cosmet Laser Ther.* 2005;7:171.
- Bigata X, Ribera M, Bielsa I, Ferrándiz C. Adverse granulomatous reaction after cosmetic dermal silicone injection. *Dermatol Surg.* 2001;27:198.
- Duffy DM. Tissue injectable liquid silicone: New perspectives. In: Klein AW, ed. *Tissue Augmentation in Clinical Practice: Procedures and Techniques.* 2nd ed. New York: Taylor & Francis; 2005:159.
- Moscona RR, Bergman R, Friedman-Birnbaum R. An unusual late reaction to Zyderm I injections: A challenge for treatment. *Plast Reconstr Surg.* 1993;92:331.
- Lombardi T, Samson J, Plantier F, et al. Orofacial granuloma after injection of cosmetic fillers: Histopathologic and clinical study of 11 cases. *J Oral Pathol Med.* 2004;33:115.
- Lupton JR, Alster TS. Cutaneous hypersensitivity reaction to injectable hyaluronic acid gel. *Dermatol Surg.* 2000;26:135.
- Shafir R, Amir A, Gur E. Long-term complications of facial injections with Restylane (injectable hyaluronic acid). *Plast Reconstr Surg.* 2000;106:1215.
- Lemperle G, Romano JJ, Busso M. Soft tissue augmentation with Artecoll: 10-year history, indications, techniques, and complications. *Dermatol Surg.* 2003;29:573.
- Laglenne S. Un nouveau produit de comblement des rides, entièrement resorbable. *Dermatologie.* 2000;54:30.
- Christensen LH, Breiting VB, Aasted A, Jørgensen A, Kebuladzé A. Long-term effects of polyacrylamide hydrogel on human breast tissue. *Plast Reconstr Surg.* 2003;111:1883.
- Mazzoleni F, Dominici C, Lotti T, et al. Formacrylfr: Un nuovo biopolimero al servizio della medicina "più un endoprotesi che un filler." *Dermatologia.* 2000;1:13.
- Bergeret-Galley C, Latouche X, Illouz YG. The value of a new filler material in corrective and cosmetic surgery: DermaLive and DermaDeep. *Aesthetic Plast Surg.* 2001;25: 249.
- Cooperman LS, Mackinnon V, Bechler G, Pharriss BB. Injectable collagen: A six-year clinical investigation. *Aesthetic Plast Surg.* 1985;9:145.
- Charriere G, Bejot M, Schnitzler L, Ville G, Hartmann DJ. Reactions to a bovine collagen implant: Clinical and immunologic study in 705 patients. *J Am Acad Dermatol.* 1989; 21:1203.
- Castrow FF, Krull EA. Injectable collagen implant: Update. *J Am Acad Dermatol.* 1983;9:889.
- Hanke CW. Adverse reactions to bovine collagen. In: Klein AW, ed. *Tissue Augmentation in Clinical Practice: Procedures and Techniques.* New York: Marcel Dekker; 1998:145-154.
- Lowe NJ, Maxwell A, Lowe P, Duick MG, Shah K. Hyaluronic acid skin fillers: Adverse reactions and skin testing. *J Am Acad Dermatol.* 2001;45:930.
- André P. Evaluation of the safety of a non-animal stabilized hyaluronic acid (NASHA, Q-Medical, Sweden) in European countries: A retrospective study from 1997 to 2001. *J Eur Acad Dermatol Venereol.* 2004;18:422.
- Friedman PM, Mafong EA, Kauvar NB, Geronemus RG. Safety data of injectable nonanimal stabilized hyaluronic acid gel for soft tissue augmentation. *Dermatol Surg.* 2002; 28:491.
- Maas CS, Gnepp DR, Bumpous J. Expanded polytetrafluoroethylene (Gore-Tex soft tissue patch) in facial augmentation. *Arch Otolaryngol Head Neck Surg.* 1993;119:1008.
- Rudolph C, Soyer HP, Schuller-Petrovic S, Kerl H. Foreign body granulomas due to injectable aesthetic microimplants. *Am J Surg Pathol.* 1999;23:113.
- Vleggaar D. Soft-tissue augmentation and the role of poly-L-lactic acid. *Plast Reconstr Surg.* 2006;118(3 Suppl.):46S.
- Greenberg JH. Information postal survey of selected physicians in dermatology. Presented at the American Academy

- of Dermatology Meeting, Dallas, Texas, December 7–12, 1991.
26. Orentreich DS. Liquid injectable silicone: Techniques for soft tissue augmentation. *Clin Plast Surg*. 2000;27:595.
 27. Fulton JE, Jr, Porumb S, Caruso JC, Shitabata PK. Lip augmentation with liquid silicone. *Dermatol Surg*. 2005;31:1577.
 28. Jones DH, Carruthers A, Orentreich D, et al. Highly purified 1000-cSt silicone oil for treatment of human immunodeficiency virus-associated facial lipoatrophy: An open pilot trial. *Dermatol Surg*. 2004;30:1279.
 29. Shapiro PE. Noninfectious granulomas. In *Lever's Histopathology of the Skin*. 8th ed. Philadelphia: Raven; 1997:317–340.
 30. Lemperle G, Rullan PP, Gauthier-Hazan N. Avoiding and treating dermal filler complications. *Plast Reconstr Surg*. 2006;118(3 Suppl.):92S.
 31. Niechajev A. Lip enhancement: Surgical alternatives and histologic aspects. *Plast Reconstr Surg*. 2000;105:1173.
 32. Naoum C, Dasiou-Plakida D, Pantelidaki K, Dara C, Chrisanthakis D, Perissios A. A histological and immunohistochemical study of medical-grade fluid silicone. *Dermatol Surg*. 1998;24:867.
 33. Eppley BL, Summerlin D-J, Prevel CD, Sadove AM. Effects of positively charged biomaterial for dermal and subcutaneous augmentation. *Aesthetic Plast Surg*. 1994;18:413.
 34. Hubmer MG, Hoffmann C, Popper H, Scharnagl E. Expanded polytetrafluoroethylene threads for lip augmentation induce foreign body granulomatous reaction. *Plast Reconstr Surg*. 1999;103:1277.
 35. Garcia-Domingo MI, Alijtas-Reig J, Cistero-Bahima A, Tresserra F, Enrique E. Disseminated and recurrent sarcoid-like granulomatous panniculitis due to bovine collagen injection. *J Investig Allergol Clin Immunol*. 2000;10:107.
 36. Lemperle G, Morhenn VB, Charrier U. Human histology and persistence of various injectable filler substances for soft tissue augmentation. *Aesthetic Plast Surg*. 2003;27:354.
 37. Stegman SJ, Chu S, Armstrong RA. Adverse reactions to bovine collagen implant: Clinical and histologic features. *J Dermatol Surg Oncol*. 1988;14:39.
 38. Morgan AM. Localized reactions to injected therapeutic materials. *J Cutan Pathol*. 1995;22:289.
 39. Hanke CW, Higley HR, Jolivet DM, Swanson NA, Stegman SJ. Abscess formation and local necrosis after treatment with Zyderm or Zylplast collagen implant. *J Am Acad Dermatol*. 1991;25:319.
 40. Barr RJ, King F, McDonald RM, Bartlow GA. Necrobiotic granulomas associated with bovine collagen test site injections. *J Am Acad Dermatol*. 1982;6:867.
 41. Brooks N. A foreign body granuloma produced by an injectable collagen implant at a test site. *J Dermatol Surg Oncol*. 1982;8:111.
 42. Rapaport MJ, Vinnik C, Zarem H. Injectable silicone: Cause of facial nodules, cellulites, ulceration, and migration. *Aesthetic Plast Surg*. 1996;20:267.
 43. Drake LA, Dinehart SM, Farmer ER, et al. Guidelines of care for soft tissue augmentation: Collagen implants. *J Am Acad Dermatol*. 1996;34:698.
 44. Baumann LS, Kerdel F. The treatment of bovine collagen allergy with cyclosporin. *Dermatol Surg*. 1999;25:247.
 45. Heise H, Zimmermann R, Heise P. Temporary granulomatous inflammation following collagen implantation. *J Craniomaxillofac Surg*. 2001;29:238.
 46. Williams CT, Williams WJ. Granulomatous inflammation: A review. *J Clin Pathol*. 1983;36:723.
 47. Maly A, Regev E, Maly B. Tissue reaction to liquid silicone simulating low-grade liposarcoma following lip augmentation. *J Oral Pathol Med*. 2004;33:314.
 48. Sidwell RU, McL Johnson N, Francis N, Bunker CB. Cutaneous sarcoidal granulomas developing after Artecoll facial cosmetic filler in a patient with newly diagnosed systemic sarcoidosis. *Clin Exp Dermatol*. 2006;31:208.
 49. Coleman DL, King RN, Andrade JD. The foreign body reaction: A chronic inflammatory response. *J Biomed Mater Res*. 1974;6:199.
 50. Requena C, Izquierdo MJ, Navarro M, et al. Adverse reactions to injectable aesthetic microimplants. *Am J Dermatopathol*. 2001;23:197.
 51. Duffy DM. Liquid silicone for soft tissue augmentation: Histological, clinical, and molecular perspectives. *Dermatol Surg*. 2007;31:1530.
 52. Hexsel DM, Hexsel CL, Iyengar V. Liquid injectable silicone: History, mechanism of action, indications, technique, and complications. *Semin Cutan Med Surg*. 2003;22:107.
 53. Rohrich RJ, Potter JK. Liquid injectable silicone: Is there a role as cosmetic soft-tissue filler? *Plast Reconstr Surg*. 2004;113:1239.
 54. Mupparapu M, Mozaffari E. Bilateral calcifications secondary to synthetic soft tissue augmentation of the cheeks: Report of a case. *Dentomaxillofac Radiol*. 2002;31:388.
 55. Zimmermann US, Clerici TJ. The histological aspect of fillers complications. *Semin Cutan Med Surg*. 2004;23:241.
 56. Salmi R, Boari B, Manfredini R. Siliconoma: An unusual entity for the internist. *Am J Med*. 2004;116:67.
 57. Achauer BM. A serious complication following medical grade silicone injections of the face. *Plast Reconstr Surg*. 1983;71:251.
 58. Schoeller T, Gschnitzer C, Wechselberger G, et al. Chronisch rezidivierende, local destruierende Silikonome nach Brustaugmentation durch fluessiges Silikonoe. *Chirurg*. 2000;71:1370.
 59. Spira M. Failure to remove soft tissue injected with liquid silicone with the use of suction and honesty in scientific medical reports. *Plast Reconstr Surg*. 2000;105:1909.
 60. Maas CS, Papel ID, Greene D, Stoker DA. Complications of injectable synthetic polymers in facial augmentation. *Dermatol Surg*. 1997;23:871.
 61. Ficarra G, Mosqueda-Taylor A, Carlos R. Silicone granuloma of the facial tissue: A report of seven cases. *Oral Surg Oral Med Oral Pathol*. 2002;94:65.
 62. Alani RM, Busam K. Acupuncture granulomas. *J Am Acad Dermatol*. 2001;45:225.
 63. Senet P, Bachelez H, Ollivaud L, Vignon-Pennamen D, Dubertret L. Minocycline for the treatment of cutaneous silicone granulomas. *Br J Dermatol*. 1999;140:985.
 64. Rapaport MJ. Granuloma annulare caused by injectable collagen. *Arch Dermatol*. 1984;120:837.
 65. Moody BR, Sengelmann RD. Self-limited adverse reaction to human-derived collagen injectable product. *Dermatol Surg*. 2000;26:936.
 66. Bergeret-Galley C. Comparison of resorbable soft tissue fillers. *Aesthetic Surg J*. 2004;24:33.
 67. Raulin C, Greve B, Hartschuh W, Soegding K. Exudative granulomatous reaction to hyaluronic acid (Hylaform). *Contact Dermatitis*. 2000;43:178.
 68. Distanto F, Bandiera A, Bellini R, et al. Studio multicentrico italiano sull'efficacia e la tollerabilita dell'acido ialuronico di origine non animale (Restylane) nel trattamento degli inestetismi del volto. *Gio Ital Dermatol Venerol*. 2001;136:293.

69. Micheels P. Human anti-hyaluronic acid antibodies: Is it possible? *Dermatol Surg.* 2001;27:185.
70. Hoening JF, Brink U, Korabiowska M. Severe granulomatous allergic tissue reaction after hyaluronic acid injection in the treatment of facial lines and its surgical correction. *J Craniofac Surg.* 2003;14:197.
71. Fernandez-Acenero MJ, Zamora E, Borbujo J. Granulomatous foreign body reaction against hyaluronic acid: Report of a case after lip augmentation. *Dermatol Surg.* 2003;29:1225.
72. Saylan Z. Facial fillers and their complications. *Aesthetic Surg J.* 2003;23:221.
73. Dal Sacco D, Cozzani E, Parodi A, Rebora A. Scar sarcoidosis after hyaluronic acid injection. *Int J Dermatol.* 2005;44:411.
74. Edwards PC, Fantasia JE, Iovino R. Foreign body reaction to hyaluronic acid (Restylane): An adverse outcome of lip augmentation. *J Oral Maxillofac Surg.* 2006;64:1296.
75. Ghislanzoni M, Bianchi F, Barbareschi M, Alessi E. Cutaneous granulomatous reaction to injectable hyaluronic acid gel. *Br J Dermatol.* 2006;154:755.
76. Chen AL, Desai P, Adler EM, Di Cesare PE. Granulomatous inflammation after Hylan G-F 20 viscosupplementation of the knee: A report of six cases. *J Bone Joint Surg (Am.)* 2002;84:1142.
77. Mang WL, Sawatzki K. Fremdkoerperreaktion nach Implantation von PMMA (Polymethylmethacrylat) zur Weichteilaugmentation. *Z Hautkr.* 1998;73:42.
78. Hoffmann C, Schuller-Petrovic S, Soyer HP, Kerl H. Adverse reactions after cosmetic lip augmentation with permanent biologically inert implant materials. *Am Acad Dermatol.* 1999;40:100.
79. Reisberger E-M, Landthaler M, Wiest L, Schröder J, Stolz W. Foreign body granulomas caused by polymethylmethacrylate microspheres. *Arch Dermatol.* 2003;139:17.
80. Alcalay J, Alcalay R, Gat A, Yorav S. Late-onset granulomatous reaction to Artecoll. *Dermatol Surg.* 2003;29:859.
81. Kim KJ, Lee HW, Lee MW, Choi JH, Moon KC, Koh JK. Artecoll granuloma: A rare adverse reaction induced by microimplant in the treatment of neck wrinkles. *Dermatol Surg.* 2004;30:545.
82. Carruthers A, Carruthers JD. Polymethylmethacrylate microspheres/collagen as a tissue augmenting agent: Personal experience over 5 years. *Dermatol Surg.* 2005;31:1561.
83. Conejo-Mir JS, Sanz Guirado SS, Angel Muñoz M. Adverse granulomatous reaction to Artecoll treated by intralesional 5-fluorouracil and triamcinolone injections. *Dermatol Surg.* 2006;32:1079.
84. Giordano GG, Chevez-Barrios P, Refojo MF, Garcia CA. Biodegradation and tissue reaction to intravitreal biodegradable poly(D,L-lactic-co-glycolic) acid microspheres. *Curr Eye Res.* 1995;14:761.
85. Valantin M-A, Aubron-Olivier C, Ghosn J, et al. Poly lactic acid implants (New-Fill) to correct facial lipoatrophy in HIV-infected patients: Results of the open-label study VEGA. *AIDS.* 2003;17:2471.
86. Moyle GJ, Lysakova L, Brown S, et al. A randomized open-label study of immediate versus delayed poly lactic acid injections for the cosmetic management of facial lipoatrophy in persons with HIV infection. *HIV Med.* 2004;5:82.
87. Bauer U. Improvement of facial aesthetics at 40 months with injectable poly-L-lactic acid (PLLA). Poster presentation at the at the International Society of Aesthetic Plastic Surgery Congress, Houston, Texas, August 28–31, 2004.
88. Beljaards RC, de Roos K-P, Bruins FG. NewFill for skin augmentation: A new filler or failure? *Dermatol Surg.* 2005;31:772.
89. van der Lei B, Cromheecke M. Response to “New-fill injections may induce late-onset foreign body granulomatous reaction.” *Plast Reconstr Surg.* 2006;118:265.
90. Oppel T, Schaller M, Flaig M, Korting HC. Fremdkoerpergranulome nach dermalen Injektion eines auf Polymilchsaure basierenden Implantates zur Behandlung von Falten. *J Deutsche Dermatol Ges.* 2003;1:220.
91. Pons-Giraud A. Actualisation des effets secondaires des produits de comblement des rides. *Nouv Dermatol.* 2003;22:205.
92. Corbiget-Escalier F, Petrella T, Janin-Magnificat C, et al. Episodes d'angio-oedemes de la face avec nodules de granulomes a corps etrangers deux ans apr s des injections d'un produit de comblement des rides: Probable responsabilite du New-Fill. *Nouv Dermatol.* 2003;22:136.
93. Dijkema SJ, van der Lei B, Kibbelaar RE. New-Fill injections may induce late-onset foreign body granulomatous reaction. *Plast Reconstr Surg.* 2005;115:1415.
94. Wildemore JK, Jones DK. Persistent granulomatous inflammatory response induced by injectable poly-L-lactic acid for HIV lipoatrophy. *Dermatol Surg.* 2006;32:1407.
95. Apikian M, Roberts S, Goodman GJ. Adverse reactions to polylactic acid injections in the periorbital area. *J Cosmet Dermatol.* 2007;6:95.
96. Burgess CM, Quiroga RM. Assessment of the safety and efficacy of poly-L-lactic acid for the treatment of HIV-associated facial lipoatrophy. *Dermatol Surg.* 2005;52:233.
97. Wolfram D, Tzankov A, Piza-Katzer H. Surgery for foreign body reactions due to injectable fillers. *Dermatology.* 2006;213:300.
98. Waris E, Pakkanen M, Lassila K, et al. Alloplastic injectable biomaterials for soft tissue augmentation: A report of 2 cases with complications associated with a new material (DermaLive) and a review of the literature. *Eur J Plast Surg.* 2003;26:350.
99. Sidwell RU, Dhillon AP, Butler PEM, Rustin MHA. Localized granulomatous reaction to a semi-permanent hyaluronic acid and acrylic hydrogel cosmetic filler. *Clin Exp Dermatol.* 2004;29:630.
100. Steenkiste E, Marien K, van den Oord J. Dermalive granuloma: A lesion with distinctive histological features. *J Dermatol.* 2005;3:1.
101. Vargas-Machuca I, Gonzalez-Guerra E, Angulo J, del Carmen Farina M, Martin L, Requena L. Facial granulomas secondary to Dermalive microimplants: Report of a case with histopathologic differential diagnosis among the granulomas secondary to different injectable permanent filler materials. *Am J Dermatopathol.* 2006;28:173.
102. Angus JE, Affleck AG, Leach IH, Millard LG. Two cases of delayed granulomatous reactions to the cosmetic filler Dermalive, a hyaluronic acid and acrylic hydrogel. *Br J Dermatol.* 2006;155:1077.
103. Zide BM. Radiance: Short-term experience. *Aesthetic Surg J.* 2004;23:495.
104. Jansen DA, Graivier MH. Evaluation of a calcium hydroxylapatite-based implant (Radiess) for facial soft-tissue augmentation. *Plast Reconstr Surg.* 2006;118(3 Suppl.):22S.
105. Sklar JA, White SM, Radiance FN. A new soft tissue filler. *Dermatol Surg.* 2004;30:764.
106. Casavantes LC, Izabel JM. Estabilidad, tolerancia y seguridad de polialquilimida gel (BioAlcamid), endoproteisis inyectable para la correccion de defectos mayores en tejidos blandos. *Dermatología Cosmética Médica y Quirúrgica.* 2004;2:98.

107. Ruden C. Acrylamide and cancer risk: Expert risk assessments and the public debate. *Food Chem Toxicol.* 2004;42:335.
108. Pelucchi C, Galeone C, Levi F, et al. Dietary acrylamide and human cancer. *Int J Cancer.* 2006;118:467.
109. Evstatiev D. Late complications after injections of hydrogel in the breast. *Plast Reconstr Surg.* 2004;113:1878.
110. Adamyan AA, Svetukhin AM, Skuba N, et al. Polyacrylamide mammary syndrome: Clinical features, diagnosis and treatment. *Ann Plast Reconstr Aesthet Surg (Moscow).* 2001;4:20.
111. Milanov NO, Donchenko EV, Fisenko EP. Plastic contour correction with polyacrylamide gels. Myth and reality. *Ann Plast Reconstr Aesthet Surg (Moscow).* 2000;4:63.
112. Niedzielska I, Pajak J, Drugacz J. Late complications after polyacrylamide hydrogel injection into facial soft tissues. *Aesthetic Plast Surg.* 2006;30:377.
113. Breiting V, Aasted A, Jorgensen A, Opitz P, Rosetzky A. A study on patients treated with polyacrylamide hydrogel injection for facial corrections. *Aesthetic Plast Surg.* 2004;28:45.
114. Karim RB, Hage JJ, van Rozelaar L, Lange CA, Raaijmakers J. Complications of polyalkylimide 4% injections (Bio-Alcamid): A report of 18 cases. *J Plast Reconstr Aesthet Surg.* 2006;59:1409.
115. Cheng NX, Wang YL, Wang JH, Zhang XM, Zhong H. Complications of breast augmentation with injected hydrophilic polyacrylamide gel. *Aesthetic Plast Surg.* 2002;26:375.
116. Xiaoling F, Yi C, Zhang Y, et al. Analysis of the complications induced by polyacrylamide hydrogel injection. *Plast Reconstr Surg.* 2004;114:261.
117. Xie PB, Shi AP. Application of polyacrylamide hydrogel in augmentation mammoplasty (in Chinese). *Di Yi Da Xue Bao.* 2002;22:648.
118. Amin SP, Marmur ES, Goldberg DJ. Complications from injectable polyacrylamide gel, a new nonbiodegradable soft tissue filler. *Dermatol Surg.* 2004;30:1507.
119. Qiao Q, Wang X, Sun J. Management of postoperative complications of breast augmentation by injected polyacrylamide hydrogel. *Aesthetic Plast Surg.* 2005;29:156.
120. Bedir S, Kilciler M, Oezgoek Y, Deveci G, Erduran D. Long-term complication due to dextranomer based implant: Granuloma causing urinary obstruction. *J Urol.* 2004;172:247.
121. Winn A. Factors in selecting medical silicones. *Med Plast Biomater.* 1996;3:16.
122. Duffy DM. The silicone conundrum: A battle of anecdotes. *Dermatol Surg.* 2002;28:590.
123. Rongioletti F, Cattarina G, Sottofattori E, Rebora A. Granulomatous reaction after intradermal injections of hyaluronic acid gel. *Arch Dermatol.* 2003;139:815.
124. Wolters M, Lampe H. Nicht-operative Faltenbehandlung im Gesicht. *Plast Chir.* 2003;2:69.
125. Christensen L, Breiting VB, Janssen M, Vuust J, Hogdall E. Adverse reactions to injectable soft tissue permanent fillers. *Aesthetic Plast Surg.* 2005;29:34.
126. Fischer J, Metzler G, Schaller M. Cosmetic permanent fillers for soft tissue augmentation: A new contraindication for Interferon therapies. *Arch Dermatol.* 2007;143:507.
127. Bardazzi F, Ruffato A, Antonucci A, Balestri R, Tabanelli M. Cutaneous granulomatous reaction to injectable hyaluronic acid gel: Another case. *J Dermatolog Treat.* 2007;18:59.
128. Al-Qattan MM. Late Artecoll granulomas aggravated by pregnancy. *Ann Plast Surg.* 2007;58:592.
129. Barcaro Machado BH. Complicacoes de implantes e preenchimentos em face e corpo. Presented at Forum Implantes, Inclusoes e Preenchimentos, Sao Paulo, Brazil, July 1-2, 2005.
130. Coleman SR. Structural fat grafting: More than a permanent filler. *Plast Reconstr Surg.* 2006;118(3 Suppl.):108S.

AUTHOR QUERIES

AUTHOR PLEASE ANSWER ALL QUERIES

1

AQ1: AUTHOR—Affiliation footnote: Is “the Private Institute of Histopathology” as wanted as an affiliation? If not, please supply the correct name of the institution.

AQ2: AUTHOR—Original table numbering was restored. Citations of tables that appeared out of order (Tables 2 and 3) were replaced with the text “the statistical tables” by the editorial office.

AQ3: AUTHOR—Starting with Table 2, references were renumbered throughout according to order of citation in text and tables, per Journal style.

AQ4: AUTHOR—Okay to leave “necrobiotic” here? It was deleted in the abstract. Please confirm that it should left in the text here.

AQ5: AUTHOR—The editorial office has the following question with regard to Figure 12: The legend refers to cystic granuloma (on the left) and sclerosing granuloma (on the right), but the sentence in the text refers to edematous granuloma. Please check.

AQ6: AUTHOR—The word “nanoparticles” was changed to “small particles” in the first sentence in this paragraph, but it was left as “nanoparticles” in the third sentence. Please confirm that this is as wanted.

AQ7: AUTHOR—Please confirm that “hydroxyethyl-methacrylate” is wanted here, without “poly-” as in the other two places in this paragraph.