

UCLA

UCLA Previously Published Works

Title

Right Heart Thrombus in Transit Diagnosed by Bedside Ultrasound

Permalink

<https://escholarship.org/uc/item/0459t2f3>

Journal

Journal of Emergency Medicine, 48(4)

ISSN

0736-4679

Authors

Martires, Joanne S

Stein, Susan J

Kamangar, Nader

Publication Date


2015-04-01

DOI

10.1016/j.jemermed.2014.11.011

Peer reviewed

AUTHOR QUERY FORM

 ELSEVIER	Journal: JEM Article Number: 10200	Please e-mail or fax your responses and any corrections to: E-mail: corrections.esi@elsevier.tnq.co.in Fax: +31 2048 52789
--	---	---

Dear Author,

Please check your proof carefully and mark all corrections at the appropriate place in the proof (e.g., by using on-screen annotation in the PDF file) or compile them in a separate list. Note: if you opt to annotate the file with software other than Adobe Reader then please also highlight the appropriate place in the PDF file. To ensure fast publication of your paper please return your corrections within 48 hours.

For correction or revision of any artwork, please consult <http://www.elsevier.com/artworkinstructions>.

Any queries or remarks that have arisen during the processing of your manuscript are listed below and highlighted by flags in the proof.

Location in article	Query / Remark: Click on the Q link to find the query's location in text Please insert your reply or correction at the corresponding line in the proof
Q1	<p>If there are any drug dosages in your article, please verify them and indicate that you have done so by initialing this query</p>
Q2	<p>It appears that you have a video clip to accompany this article, but it is not mentioned in the text. Please add a mention of this video in the text.</p>
Q3	<p>Do you mean "equivalent" here? Please correct if necessary</p>
Q3	<p>Please confirm that given names and surnames have been identified correctly.</p>
	<p>Please check this box or indicate your approval if you have no corrections to make to the PDF file</p> <div style="border: 1px solid black; width: 50px; height: 30px; margin-left: auto; margin-right: auto;"></div>

Thank you for your assistance.



<http://dx.doi.org/10.1016/j.jemermed.2014.11.011>

Visual Diagnosis in Emergency Medicine

RIGHT HEART THROMBUS IN TRANSIT DIAGNOSED BY BEDSIDE ULTRASOUND

Joanne S. Martires, MD, Susan J. Stein, MD, and Nader Kamangar, MD

Division of Pulmonary and Critical Care Medicine, Department of Medicine, UCLA-Olive View Medical Center,
 UCLA Geffen School of Medicine, Sylmar, California

Reprint Address: Nader Kamangar, MD, MS, FACP, FCCP, FCCM, Division of Pulmonary and Critical Care Medicine, Department of Medicine,
 UCLA-Olive View Medical Center, UCLA Geffen School of Medicine, 14445 Olive View Drive, Room 2B-182, Sylmar, CA 91342

INTRODUCTION

Right heart thrombi in transit represent deep venous thrombi that have mobilized and become lodged in the right heart en route to the pulmonary arteries, with the potential to migrate and lead to additional embolic complications. Due to their increased risk for mortality, right heart thrombi in transit represent a severe form of venous thromboembolism. In addition, in patients with patent foramen ovale (PFO) or atrial septal defect (ASD), right heart thrombi in transit can lead to systemic thromboembolism. Once diagnosed, right heart thrombi in transit require consideration of emergent treatment such as thrombolytics, surgical thromboembolectomy, or catheter-based intervention, due to the potential of the clot to fragment or migrate leading to further vascular obstruction and hemodynamic compromise.

CASE REPORT

A 32-year-old man with no significant medical history presented with left-sided pleuritic chest pain and dyspnea

on exertion for approximately 12 days. His symptoms began shortly after a 6-h flight. The patient also experienced myalgias, vomiting, and fatigue and had spent several days in bed with what he believed was a viral illness.

Vital signs on arrival to the emergency department were as follows: heart rate: 113 beats/min (regular); blood pressure: 101/85 mm Hg; respiratory rate: 25 breaths/min; oxygen saturation, 93% on 4 L oxygen via nasal cannula. Physical examination revealed an ill-appearing man with marked cyanosis and mottling of the lower extremities. Jugular venous pressure was elevated to 14 cm and cardiac examination revealed an increased intensity of the pulmonic component of the second heart sound. The remainder of the physical examination was otherwise normal.

Complete blood count was remarkable for a leukocytosis of 14 and a hematocrit of 49.6%. Chemistry findings were normal, with the exception of the creatinine (1.67 mg/dL). Cardiac troponin (cTnI) was mildly elevated at 0.153 mg/mL. Electrocardiogram was remarkable for right ventricular strain.

Point of care cardiac ultrasound was immediately performed and revealed a moderately dilated right ventricle with reduced systolic function. In addition, there was a large, mobile, snake-like echodensity within the right atrium, extending into the right ventricle, where it appeared to be moving back and forth (Figure 1). The patient was immediately taken to computed tomography (CT) pulmonary angiography, where a serpiginous

Streaming video: One brief real-time video clip that accompanies this article is available in streaming video at www.journals.elsevierhealth.com/periodicals/jem. Click on Video Clip 1.

RECEIVED: 16 July 2014; FINAL SUBMISSION RECEIVED: 10 October 2014;
 ACCEPTED: 16 November 2014

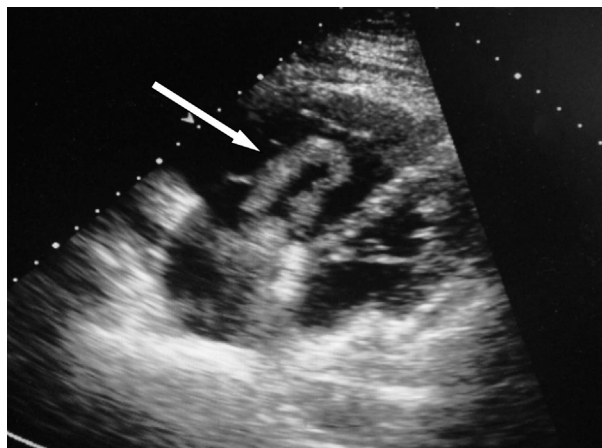


Figure 1. Bedside cardiac ultrasound showing a serpiginous, mobile mass in the right atrium representing a right heart thrombus in transit.

density in the right heart and a saddle pulmonary embolism (PE) with extension into the right and left main pulmonary artery, as well as interlobar, lobar, and segmental arteries were visualized (Figure 2).

Recombinant tissue plasminogen activator (t-PA) 10 mg via intravenous bolus was immediately administered, followed by 90 mg infusion over 2 h, in order to treat the patient's right heart thrombus in transit and severe PE. Shortly after administration of t-PA, the patient's oxygen saturation improved to 99% on room air and his extremities became warm and well-perfused. Upon arrival to the intensive care unit, the patient developed an episode of epistaxis that required nasal packing. Six hours after t-PA administration, a formal transthoracic echocardiogram showed complete resolution of the right heart thrombus in transit (Figure 3).

The patient continued to do well clinically and was placed on anticoagulation with heparin. Repeat formal echocardiography showed marked improvement of right ventricular dilatation and right ventricular systolic func-

tion, with near normalization of the pulmonary artery pressures. Lower-extremity ultrasonography demonstrated an extensive left femoral vein thrombus extending into the popliteal vein. Placement of an inferior vena cava filter was considered, but ultimately one was not placed because the patient was able to tolerate anticoagulation. The patient remained hemodynamically stable and was eventually bridged from heparin to warfarin and discharged from the hospital once his international normalized ratio was therapeutic.

DISCUSSION

Right heart thrombi in transit are often found in the setting of severe bilateral PEs (1,2). Dyspnea, chest pain, and syncope are the most common presenting symptoms. Patients with right heart thrombi in transit often have higher heart rates, lower blood pressures, and exhibit more right ventricular dysfunction compared with patients who present with PE without right heart thrombi in transit (1). Patients can also present in cardiogenic shock. The reported incidence in patients with PE is between 3.6% and 18% (1–3).

The diagnosis of right heart thrombi in transit is usually made by echocardiography or CT pulmonary angiography. Point of care ultrasound, as in our case, can lead to a more prompt diagnosis. On these imaging modalities, a right heart thrombus in transit has been described as a highly mobile, coiled, or serpiginous mass, usually in the right atrium with prolapse into the ventricle (3,4).

A right heart thrombus in transit is an ominous manifestation of venous thromboembolism that requires a more aggressive and emergent management approach, as nearly all deaths occur within the first 24 h (5). However, the optimal treatment remains somewhat controversial. Thrombolytics and surgical embolectomy are the most described and well-validated treatment modalities. Successful treatment with anticoagulation alone has been

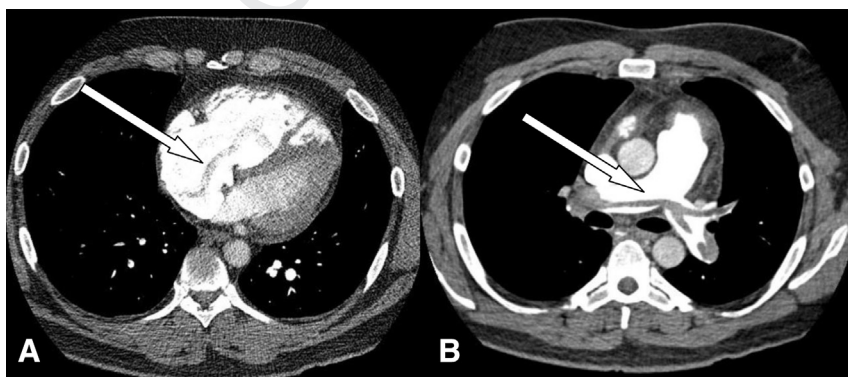


Figure 2. Computed tomography pulmonary angiogram demonstrating (A) serpiginous density in the right heart and (B) saddle pulmonary embolus.

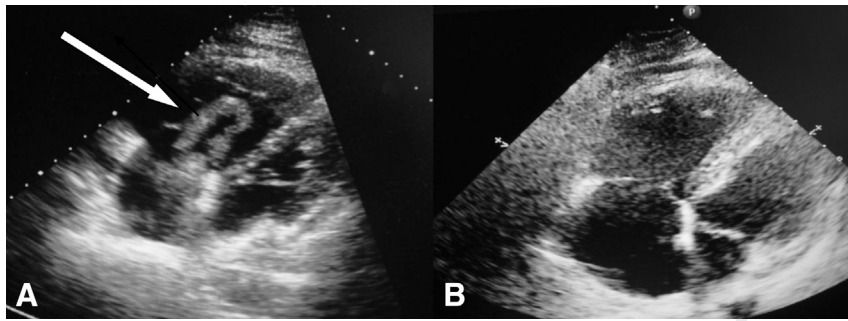


Figure 3. (A) Initial bedside cardiac ultrasound demonstrating a serpiginous mass in the right atrium and right ventricle. (B) Transthoracic echocardiogram done 6 h after the administration of thrombolytics demonstrating complete resolution of right heart thrombus in transit.

documented, but there is substantial evidence that this treatment is inadequate and, in some studies, equivocal to no treatment (1,4). In addition, anticoagulation may have a slow onset of action and lead to fragmentation and embolization of a right heart thrombus in transit.

Although the presence of right heart thrombi in transit is associated with increased mortality, little is known about optimal management of this difficult clinical situation. In addition to anticoagulation, there are several other therapeutic options that should be considered for the management of right heart thrombi in transit. These includes systemic thrombolysis, surgical embolectomy, and catheter-based treatments. Thrombolytics have been shown to dissolve right heart thrombi in transit and lead to improvements in right heart strain, pulmonary vascular resistance, and pulmonary hemodynamics. Urokinase, streptokinase, or t-PA are typically used; the dose of t-PA that is typically used for massive PE is 100 mg over 2 h (6). Treatment monitoring can be done effectively by serial echocardiography. Most right heart thrombi in transit resolve within 2 h of administration of thrombolytics, but occasionally have been known to take up to 12 or even 24 h to resolve (7). The major risk associated with thrombolytic therapy is significant bleeding and it should therefore be avoided in patients with contraindications, including recent surgery or stroke.

Surgical embolectomy is considered a classic treatment for right heart thrombi in transit and may be the treatment of choice when the need for a repair of a PFO simultaneously exists to prevent paradoxical emboli, or when thrombolytic therapy is contraindicated (5). Surgical embolectomy allows for rapid removal of thrombi from the right heart and both of the pulmonary arteries. This procedure has the potential advantage of repairing a PFO or a septal defect, if present.

There have been case reports documenting the use of percutaneous catheterization to retrieve right heart thrombi in transit (8,9). During this procedure, a sheath is introduced into the femoral vein and into the right heart. From there, the right heart thrombus in transit is attached

to the sheath using the negative pressure from a syringe or a basket device is used to capture the thrombus and move it into the inferior vena cava (IVC) and an IVC filter is placed, in theory preventing the thrombus from re-entering the right heart. Transesophageal echocardiography may be used to provide visualization during the procedure. The risks of percutaneous retrieval include further embolization of the right heart thrombus or perforation of vital cardiovascular structures. Although this strategy has been shown to be technically feasible, it is not meant to be an alternative to thrombolytics or surgery and its purpose is to serve as a salvage treatment for those with contraindications to both of these treatments.

The diagnosis of right heart thrombi in transit carries poor prognostic significance. In-hospital mortality has been reported to be as high as 45% (10). Treatment with surgery or thrombolytics has been shown to significantly reduce mortality when compared to treatment with anticoagulation alone. There are no randomized controlled trials comparing surgery to thrombolytics but, in a meta-analysis, there was improved survival rate in patients treated with thrombolytics (4). Patients with right heart thrombi in transit who survive hospitalization generally have a favorable prognosis after discharge.

In cases of acute PE, evidence of right heart thrombi in transit on bedside echocardiography portends a poor prognosis and identifies patients who may benefit from immediate, aggressive treatment modalities. The detection of right heart thrombi in transit during point of care echocardiography may have significant diagnostic and therapeutic implications. Additionally, formal echocardiography may identify a PFO or ASD, which can further increase the morbidity and mortality associated with right heart thrombi in transit. Although the optimal therapy remains controversial, thrombolysis and embolectomy appear effective, while anticoagulation alone appears insufficient. The risks and benefits of thrombolytics, surgical embolectomy, and catheter-based interventions should be considered when selecting the ideal therapeutic modality for this high-risk subset of patients with PE.

REFERENCES

1. Torbicki A, Galie N, Covezzoli A, et al. Right heart thrombi in pulmonary embolism: results from the International Cooperative Embolism Registry. *J Am Coll Cardiol* 2003;41:2245–51.
2. Casazza F, Bongarzone A, Centonze F, et al. Prevalence and prognostic significance of right-sided cardiac mobile thrombi in acute massive pulmonary embolism. *Am J Cardiol* 1997;79:1433–5.
3. Farfel Z, Schechter M, Vered Z, et al. Review of echocardiographically diagnosed right heart entrapment of pulmonary emboli-in-transit with emphasis on management. *Am Heart J* 1987;113:171–8.
4. Rose PS, Punjabi NM, Pearse DB. Treatment of right heart thromboemboli. *Chest* 2002;121:806–14.
5. Chapoutot L, Nazeyrollas P, Metz D, et al. Floating right heart thrombi and pulmonary embolism: diagnosis, outcome, and therapeutic management. *Cardiology* 1996;87:169–74.
6. Greco F, Bisignani G, Serafini O, et al. Successful treatment of right heart thromboemboli with IV recombinant tissue-type plasminogen activator during continuous echocardiographic monitoring: a case series report. *Chest* 1999;116:78–82.
7. Ferrari E, Benhamou M, Berthier F, et al. Mobile thrombi of the right heart in pulmonary embolism: delayed disappearance after thrombolytic treatment. *Chest* 2005;127:1051–3.
8. Richartz BM, Werner GS, Ferrari M, et al. Non-surgical extraction of right cardiac “thrombus in transit.” *Catheter Cardiovasc Interv* 2000;51:316–9.
9. Mukharji J, Perterson JE. Percutaneous removal of a large mobile right atrial thrombus using a basket retrieval device. *Catheter Cardiovasc Interv* 2000;51:479–82.
10. Chartier L, Béra J, Delomez M, et al. Free- floating thrombi in the right heart: diagnosis, management, and prognostic indexes in 38 consecutive patients. *Circulation* 1999;99:2779–83.

SUPPLEMENTARY DATA

Supplementary data related to this article can be found online at <http://dx.doi.org/10.1016/j.jemermed.2014.11.011>.

Streaming video: One brief real-time video clip that accompanies this article is available in streaming video at www.journals.elsevierhealth.com/periodicals/jem. Click on Video Clip 1.