

# UC Irvine

## UC Irvine Previously Published Works

### Title

Laser VS. Suture Nerve Anastomosis

### Permalink

<https://escholarship.org/uc/item/04n5c8cx>

### Journal

Otolaryngology, 107(1)

### ISSN

0194-5998

### Authors

Huang, Thomas C  
Blanks, Robert H  
Berns, Michael W  
et al.

### Publication Date

1992-07-01

### DOI

10.1177/019459989210700103

### Copyright Information

This work is made available under the terms of a Creative Commons Attribution License, available at <https://creativecommons.org/licenses/by/4.0/>

Peer reviewed

# Laser vs. suture nerve anastomosis

THOMAS C. HUANG, MD, ROBERT H.I. BLANKS, PhD, MICHAEL W. BERNS, PhD, and ROGER L. CRUMLEY, MD,  
Orange and Irvine, California

The repair of injured or transected nerves is frequently encountered in head and neck surgery. Recently, CO<sub>2</sub> lasers with milliwatt capability and micrometer spot sizes have been developed that may be used in nerve anastomosis. A comparative study was performed between microsuture and CO<sub>2</sub> laser repair of transected sciatic nerves in rats. Nerve regeneration was measured in terms of morphology, electrophysiology, and function. Histologic studies revealed no difference in the size and number of regenerated axons, although there was less scar tissue formation at the anastomotic site with the laser repair. EMG and nerve conduction velocity were similar for the two repair methods. Functional recovery, as determined objectively using measurements of gait footprints, showed no difference between suture and laser repair. Laser-repaired nerves did have a higher dehiscence rate, although this problem can probably be prevented by splinting the rats postoperatively. However, laser repair was faster and simpler than suture repair and required less manipulation of the nerve. This study shows laser repair of peripheral nerves is possible with results comparable to conventional microsuture neurotaphy. Laser nerve anastomosis may be an effective alternative to suture nerve repair. (OTOLARYNGOL HEAD NECK SURG 1992;107:14.)

The repair of injured peripheral nerves is frequently encountered in head and neck surgery. Facial nerve reconstruction after radical parotidectomy, hypoglossal-to-facial nerve anastomosis for facial reanimation, and the repair of facial nerve transections are just a few examples that involve nerve anastomosis in the head and neck.

Nerve repair has conventionally been with fine epineurial or perineurial sutures using microsurgical techniques that require a certain level of proficiency to obtain consistent results. Even in the best hands, suture neurotaphy is often a time-consuming process. Also, especially in the head and neck region, there are often areas in which poor exposure or difficult surgical access precludes the placement of microsutures in nerve repair.

Different methods of nerve repair have been attempted over the years. Various nerve sheaths and tu-

bules have been tried,<sup>1,2</sup> as well as different tissue adhesives to reconnect nerves.<sup>3-5</sup> No method has yet proved to be consistently superior to suture repair.

Within the past decade, lasers have become an increasingly useful surgical tool, mainly because of their ability to precisely and hemostatically cut tissue while coagulating small vessels. At low powers, thermal lasers, such as CO<sub>2</sub>, argon, and YAG, can be used to "weld" tissue together by local protein coagulation. This property of the laser has already been successfully applied to vascular anastomosis.<sup>6,7</sup> Fischer et al.<sup>8</sup> attempted neural anastomosis using the CO<sub>2</sub> laser. Their study suggested laser repair produces less scar tissue formation and constriction at the repair site than suture repair.

The purpose of this study was to further examine the procedure of laser-assisted nerve anastomosis using the CO<sub>2</sub> laser and to use an objective method for comparing functional recovery between microsuture- and laser-repaired nerves.

## METHODS AND MATERIAL

The rat sciatic nerve model was used because objective behavioral measurements of the functional recovery of the rat sciatic nerve can be reliably quantified. The treatment of experimental animals was in full compliance with the *Guide for the Care and Use of Laboratory Animals*, published by the NIH.

**Surgical procedure.** Sprague-Dawley rats weighing 240 to 260 gm each were anesthetized using ke-

---

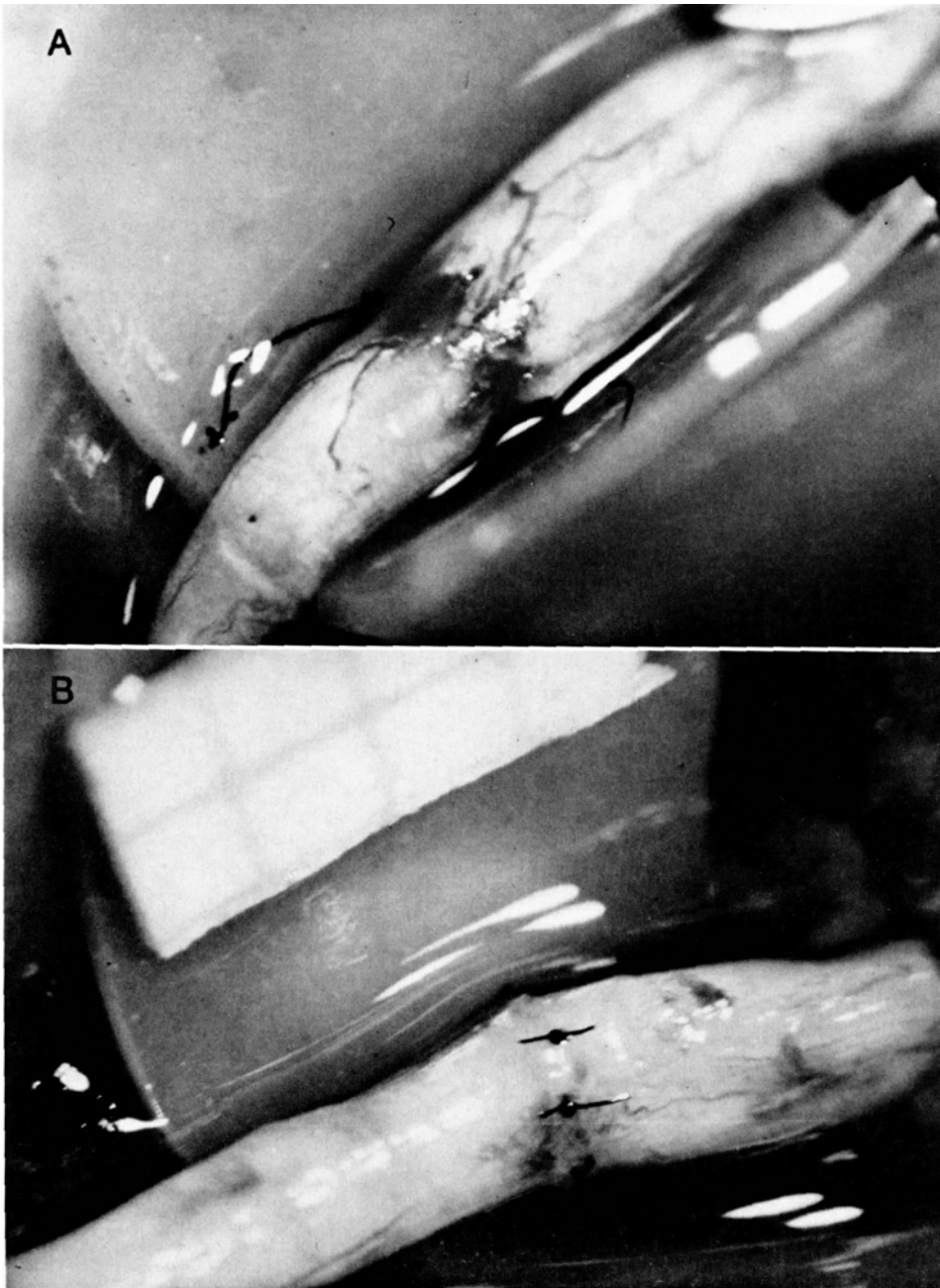
From the Department of Otolaryngology-Head and Neck Surgery, University of California, Irvine Medical Center (Drs. Huang, Blanks, and Crumley), and Beckman Laser Institute and Medical Clinic (Dr. Berns).

Presented at the Annual Meeting of the American Academy of Otolaryngology-Head and Neck Surgery, San Diego, Calif., Sept. 9-13, 1990.

Received for publication Aug. 19, 1991; revision received Nov. 18, 1991; accepted Nov. 22, 1991.

Reprint requests: Thomas C. Huang, MD, 1310 West Stewart Dr., Suite 308, Orange, CA 92668.

23/66/35116



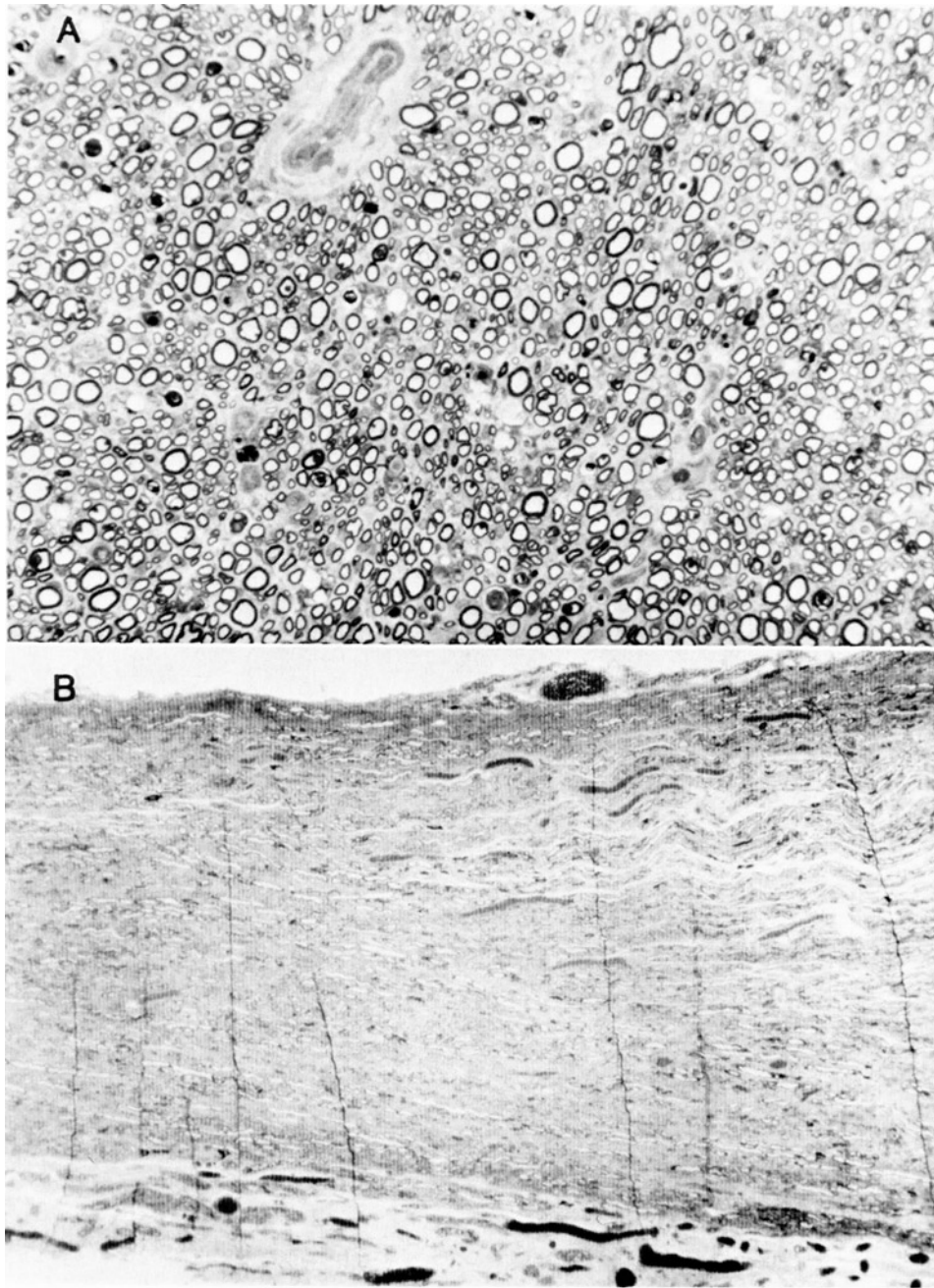
**Fig. 1. A,** Laser-repaired nerve shows good coaptation and thermal welding of the epineurium at the anastomotic site. The two sutures serve as markers. **B,** Suture-repaired nerve using six interrupted circumferential sutures of 10-0 nylon.

tamine (150 mg/kg) and xylazine (8 mg/kg). The left sciatic nerve was exposed and transected using sharp scissors 5 mm proximal to the trifurcation. Repairs were all performed by the same surgeon (T.C.H.) and were randomly divided into two groups:

1. *The Standard Microsuture Group.* Mushrooming of axonal contents from the cut ends of the nerve

was trimmed flat using sharp microscissors. The ends were then brought together and aligned using epineurial landmarks and fascicular pattern. Six evenly spaced sutures of 10-0 monofilament nylon on 75 micron needles were placed circumferentially to complete the microsuture repair.

2. *The Laser Weld Group.* After trimming and align-

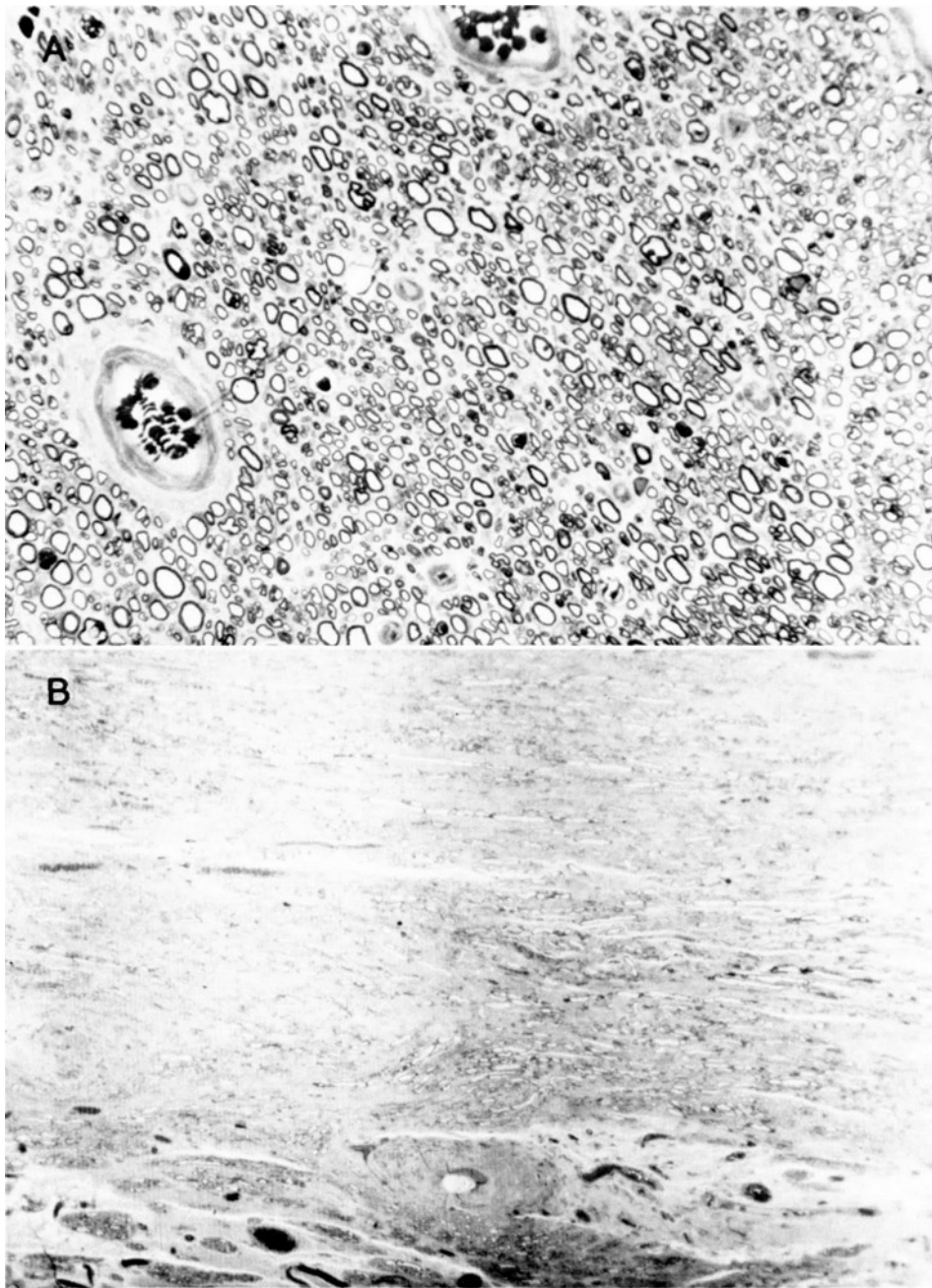


**Fig. 2.** Histologic sections of laser-repaired nerve. **A**, Cross-section shows good regeneration of myelinated and nonmyelinated axons of various sizes. **B**, Longitudinal section shows well-healed epineurium, with no evidence of charring or carbonaceous deposits.

ment of the nerve ends as described earlier, the CO<sub>2</sub> laser (Model XA-50, Xanar, Inc., Los Angeles, Calif.) was used to circumferentially weld together the epineurium of the two ends. Power was set at 120 to 150 mW continuous wave energy with a 0.5 mm spot size. Duration of lasing ranged from 30 to 60 seconds, until the epineurium was

fused together. Two epineurial sutures of 10-0 nylon were placed to serve as markers.

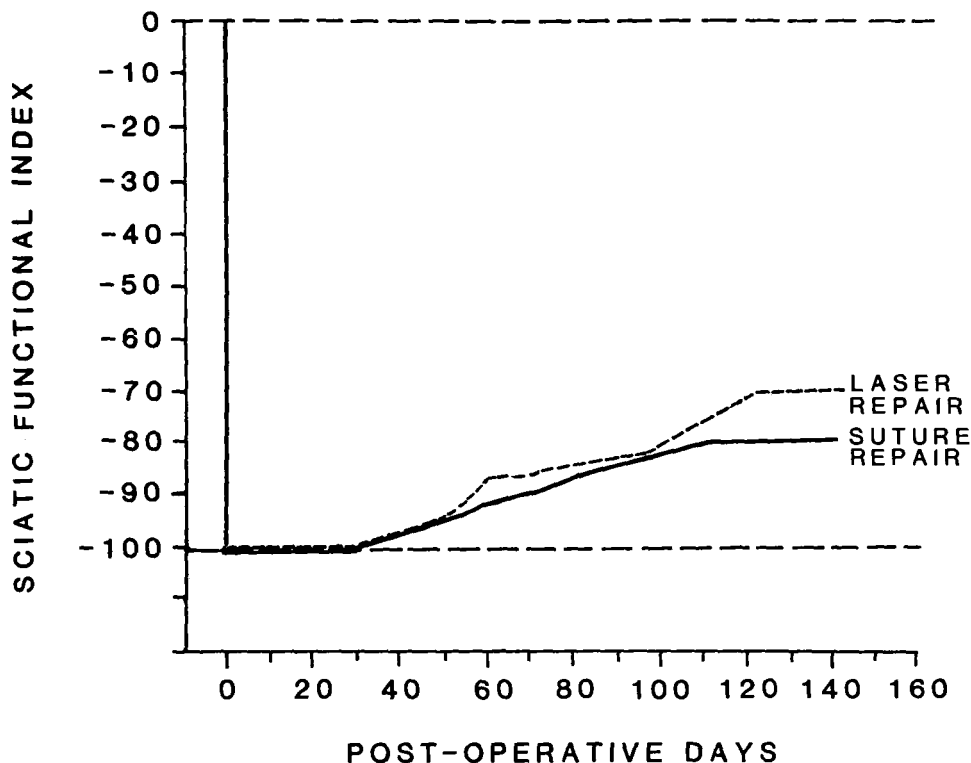
After nerve repair, the muscle and skin were closed in separate layers using 5-0 Dexon sutures. Topical antibiotic ointment was applied to the wound to prevent infection. No attempt was made postoperatively to immobilize the lower extremity of the animals.



**Fig. 3.** Histologic sections of suture-repaired nerve. **A**, Cross-section shows good axonal regeneration comparable to laser repaired nerve in Fig. 2. There are intraneural vessels that contain blood cells. **B**, Longitudinal section contains a suture granuloma that creates distortion of adjacent axon fibers.

**Functional recovery measurement.** Motor function of the sciatic nerve in rats can be reliably quantified by measurements based on walking footprints, as first described by de Medinaceli et al.<sup>9</sup> Footprint tracings were obtained by dipping the hindpaws of the rats in film developer solution and then having the conditioned rats walk down a narrow corridor lined with a strip of

unexposed x-ray film. The film was then fixed and dried to provide a permanent record for analysis. The “sciatic functional index” (SFI) was derived from eight measured parameters, reflecting footprint length and width, toe spread, and stride length of normal sides and sides operated on. The SFI gives a normalized score, with  $-100$  being total loss of function and  $0$  being normal



**Fig. 4.** Mean functional recovery, as measured by the sciatic functional index, shows 20% improvement with suture repair and 30% improvement with laser repair, with plateau reached at 120 days postoperatively. Though the laser group had slightly better function, the results were not statistically significant (Z-test,  $z = 1.22$ ,  $p = 0.22$ ).

baseline function. SFIs were measured preoperatively, then weekly for the first 2 months postoperatively, and then every other week until 4 months after nerve repair.

**Nerve conduction measurement.** At 4 months after repair, the rats were anesthetized as previously described, and the repaired sciatic nerve was re-exposed. Compound action potential recordings were obtained by placing the stimulating electrode on the nerve proximal and distal to the repair site on the tibial nerve. The recording electrode was placed on the foot muscles. Electrical stimulations consisting of 0.1 mg square-wave pulses were gradually increased in voltage until a maximum response was obtained. The responses were collected and stored in a computer. A waveform analysis program was used to calculate the nerve conduction velocity and amplitude. In some rats, the repair site was found to be dehiscient, and thus electrophysiologic recordings were not possible.

Each animal was numerically coded by the surgeon (T.C.H.). Data collection was performed by blinded observers.

**Morphologic study.** A 5 mm segment of the sciatic nerve surrounding the repair site was removed from

each rat for histologic processing. The nerve specimens were fixed in 4% buffered glutaraldehyde for 24 hours and then post-fixed in osmium tetroxide, dehydrated in graded alcohol and propylene oxide, and embedded in Poly/Bed 812 plastic embedding media (Polyscience, Inc., Warrington, Pa.). Half-micron sections were cut with a glass knife microtome. The sections were mounted on slides, stained with 1% methylene blue and azure dye, and examined under a photomicroscope.

## RESULTS

Laser nerve repair using epineurial welding and two anchoring sutures took approximately one-third less time than microsuture repair using six epineurial sutures. The laser-repaired nerves showed some thermal epineurial effects; however, there was good coaptation of nerve ends (Fig. 1).

Of the 19 rats in the laser group, one died postoperatively and another rat underwent autotomy of its foot and had to be excluded from the study, leaving 17 rats for analysis. On re-exploration, seven of the 17 rats (41%) had dehiscient nerves at the repair site, probably as a result of inadequate tensile strength of the anas-

tomosis immediately postoperatively. Of the 15 rats in the suture repair group, three died postoperatively and four others showed signs of autotomy and were excluded from the study, leaving eight animals for analysis. On re-exploration, all eight repaired nerves were intact.

**Electrophysiological recovery.** The mean nerve conduction velocity (NCV) of the sutured nerves was 25.0 m/sec. Mean NCV of the laser-repaired nerves was 24.1 m/sec. NCV correlates with the size of axon fibers and extent of myelination.

There was no significant difference between the two groups with regard to the transmission of electrical impulses along the nerves.

**Anatomic study.** In both groups, the gross appearance of the repaired nerves that remained intact at four months showed good approximation and healing at the anastomotic site. There was no external scarring visible in the laser-repaired nerves.

On histologic analysis, the laser-repaired nerve demonstrated good axonal regeneration (Fig. 2). The epineurium appeared well-healed, and there was no evidence of tissue charring or carbonaceous deposits. The regenerated axons were of smaller caliber and had less myelination compared to normal nerves. Good axonal regeneration was also found in suture-repaired nerves (Fig. 3). However, foreign body reactions were present surrounding the sutures and appeared to cause distortion of axon fibers and perineural fibrosis around the suture granulomas.

**Functional recovery.** Recovery of function, as measured by the rats' walking behavior using the sciatic functional index, showed no significant difference between the two groups (Fig. 4). The mean level of functional recovery for the suture group was 20%. The mean level of recovery for the laser group as 30%, which, though slightly higher, is not significantly different ( $Z$ -test,  $z = 1.22$ ,  $p = 0.22$ ).

In terms of return of function, nerves repaired by laser were comparable to nerves repaired by suture.

## DISCUSSION

Potential advantages of laser nerve repair include reduction in operative time without impairment of precision and the improvement of functional return by minimization of nerve manipulation and elimination of foreign body reactions to sutures. Suture neuroorrhaphy inevitably leaves small gaps in the epineurium between stitches. By completely sealing the epineurium with the laser, there is considerably less chance of scar tissue ingrowth and axonal escape, both of which inhibit nerve regeneration. The "water-tight" seal at the repair site may also create a more favorable local microenvironment for neurotrophic factors to function.<sup>3</sup>

Irradiation of nerves with laser energy does not appear to have any adverse effects on axonal regeneration. Morphometric analysis of myelinated axons around the repair site by Beggs et al.<sup>10</sup> and Maragh et al.<sup>11</sup> revealed no deleterious effects of the laser on the degree of retrograde axonal degeneration or regeneration as shown by the similar numbers and sizes of regenerated fibers present in the distal stump compared with suture repairs. Also, laser microbeam experiments on single nerve cells in tissue cultures have revealed no inhibition of neurite regeneration.<sup>12</sup> Thus, controlled laser energy at low powers does not appear to inhibit axonal growth.

Laser anastomosis of nerves requires precise control of the thermal effects of the laser to permit welding of the epineurium without damage to the delicate underlying axons. This method became technically feasible with the development of the CO<sub>2</sub> milliwatt laser, which can operate in power increments of 0.001 W while precise power stability is maintained. The first attempt at laser neuroorrhaphy by Fischer et al.<sup>8</sup> used a CO<sub>2</sub> laser at relatively high powers (5 watts in 0.5 second pulses). As a result, dense carbonaceous deposits surrounded by a mild inflammatory reaction were found at the repair site. No such carbon deposits were seen in this study with the use of the CO<sub>2</sub> milliwatt laser in the 120 to 150 mW range. This low thermal energy allows welding of superficial tissue without deep thermal penetration. The mechanism of laser welding appears to be by the homogenization of collagen and tumefaction of the supporting structures in the epineurium.<sup>13</sup>

One disadvantage of laser neuroorrhaphy is the lack of tensile strength at the anastomotic site. This was readily apparent from this study, which showed a 41% rate of nerve dehiscence, even with placement of two anchoring sutures. Other studies have shown dehiscence rates of 12% to 25%.<sup>8,11,14,15</sup> One possible solution is to temporarily immobilize the limb for 7 to 10 days postoperatively to allow adequate healing to occur before tension is allowed on the repaired nerve. Maragh et al.<sup>11</sup> showed that the tensile strength of laser-welded nerves became equal to sutured nerves at 8 days postoperatively. Using higher laser power may also increase tensile strength, though the increased thermal energy may have detrimental effects on the underlying axons. In the head and neck, however, the cranial nerves are not subjected to significant stretching or tension as occurs with peripheral nerves in the extremities. The dehiscence rate for laser-repaired nerves in the head and neck would be expected to be lower.

Electrophysiologic evaluation that involves nerve conduction velocity and amplitude produced no difference between laser- and suture-repaired nerves. This concurs with previous studies.<sup>8,11,14</sup> The ability of the repaired nerve to transmit electrical impulses correlates

with successful regeneration and myelination of axons across the repair site. This was confirmed by the histologic study, which showed a vigorous proliferation of axons distal to the repair site in both groups. The suture group did exhibit evidence of granuloma formation around sutures that appeared to distort the surrounding axons and may contribute to the misrouting of regenerating nerve fibers.

The sciatic function index has been shown to be a reliable, objective measurement of the sciatic nerve function in the rat.<sup>9</sup> The reliability of the method has been confirmed by other investigators.<sup>16,17</sup> This study shows no deleterious effect on functional recovery using laser repair compared to suture repair.

In conclusion, this study demonstrates that laser nerve repair is possible in rats, and the end results are comparable to conventional suture repair as measured by electrophysiologic, histologic, and behavioral data. CO<sub>2</sub> laser at low powers does not appear to have any deleterious effects on nerve regeneration. Advantages of laser repair are decreased surgical time and less manipulation of the nerve and surrounding tissue. It is also technically easier to perform than suture repair in narrow or deep operative sites. Disadvantages include increased cost of equipment and acquisition of technical skills. However, CO<sub>2</sub> lasers with milliwatt capability are already available in many hospitals. Most otolaryngologists are well-trained in laser procedures and may readily apply those skills to laser neuroorrhaphy. Laser nerve welding holds promise as an alternative to microsuture nerve repair.

#### REFERENCES

1. Almquist EE, Nachemson A, Auth D. Evaluation of the use of the argon laser in repairing rat and primate nerves. *J Hand Surg* 1984;9A:792-9.
2. Braun RM. Comparative studies of neuroorrhaphy and sutureless peripheral nerve repair. *Surg Gynecol Obstet* 1966;122:15-20.
3. Parker G, White T, Jenkins R. Surgical repair of extratemporal facial nerve: a comparison of suture repair and microfibrillar collagen repair. *Laryngoscope* 1984;94:950-3.
4. Siedentop KH, Lowey A. Facial nerve repair with tissue adhesives. *Arch Otolaryngol* 1979;105:423-5.
5. Egloff DV, Narakas A. Nerve anastomosis with human fibrin. *Ann Chir Main* 1983;2:101-15.
6. Okada M, Shimizu K, Ikuta H, Horii H, Nakamura K. An alternative method of vascular anastomosis by laser: experimental and clinical study. *Lasers Surg Med* 1987;7:240-8.
7. Neblett CR, Morris JR, Thomsen S. Laser-assisted microsurgical anastomosis. *Neurosurgery* 1986;19:914-34.
8. Fischer DW, Beggs JL, Kenshalo DL, Shetter AG. Comparative study of microepineurial anastomosis with the use of CO<sub>2</sub> laser and suture technique in rat sciatic nerves: Part I. *Neurosurgery* 1985;17:300-7.
9. de Medinaceli L, Freed WJ, Wyatt RJ. An index of the functional condition of rat sciatic nerve based on measurements made from walking tracks. *Exp Neurol* 1982;77:634-43.
10. Beggs JL, Fischer DW, Shetter AG. Comparative study of rat sciatic nerve microepineurial anastomosis made with carbon dioxide lasers and suture techniques: Part 2. *Neurosurgery* 1986;18:266-9.
11. Maragh H, Hawn RS, Gould JD, Terzis JK. Is laser nerve repair comparable to microsuture coaptation. *J Reconstr Microsurg* 1988;4:189-95.
12. Gross GW, Lucas JH, Higgins ML. Laser microbeam surgery: ultrastructural changes associated with neurite transection in culture. *J Neurosci* 1983;3:1979-93.
13. Schober R, Ulrich F, Sander T, Durselen H, Hessel S. Laser-induced alteration of collagen substructures allows microsurgical tissue welding. *Science* 1986;232:1421-2.
14. Bailes J, Quigley MR, Cerullo LJ, Kwaan HC. Review of tissue welding applications in neurosurgery. *Microsurgery* 1987;8:242-4.
15. Bailes JE, Quigley MR, Cerullo LJ, Kline DG, Saghal V. Sutureless CO<sub>2</sub> laser nerve anastomosis: histologic and electrophysiological analysis. *Lasers Surg Med* 1986;6:248-9.
16. Terzis JK, Smith KJ. Repair of severed peripheral nerves: comparison of the "de Medinaceli" and standard microsuture methods. *Exp Neurol* 1987;96:672-80.
17. Wikholm RP, Swett JE, Torigoe Y, Blanks RHI. Repair of severed peripheral nerve: a superior anatomic and functional recovery with a new "reconnection" technique. *OTOLARYNGOL HEAD NECK SURG* 1988;99:353-61.



held July 26-30, 1993, at the Tamarron Resort in Durango, Colorado.

This 28 hour review and update will encompass all the clinically important areas of MR imaging. Important new concepts and pathological/imaging correlations in the body, musculoskeletal system, ENT, head and neck, brain, and spine will be explored. Daily case presentations will supplement these lectures and will serve to test the registrants' diagnostic abilities in MR imaging.

This complete review of MR imaging will be presented by nationally recognized leaders in magnetic resonance imaging. As a result of this comprehensive review, registrants will become familiar with current applications of MR imaging and will be able to integrate many of these applications directly into their practice.

Program chairmen for this presentation will be Robert Quencer, MD (University of Miami), Victor Haughton, MD (Medical College of Wisconsin). Twenty-eight credits of Category I will be available.

For further information, please contact Marti Carter, CME, Inc., 11011 West North Ave., Milwaukee, Wisconsin 53226, or call (414) 771-9520.

#### **Ear, Nose, and Throat Diseases: 1993 Update**

Children's Hospital of Pittsburgh will hold its 18th Annual Symposium, "Ear, Nose, and Throat Diseases in Children: A 1993 Update." This symposium will be held July 30-31, 1993. CME credits will be awarded.

For further information, please contact the Department of Pediatric Otolaryngology, Children's Hospital of Pittsburgh, 3705 Fifth Avenue at DeSoto St., Pittsburgh, Pennsylvania 15213, or call (412) 692-8577.

#### **Twenty-fifth Annual Meeting – Head and Neck Oncologists**

The Association of Head and Neck Oncologists of Great Britain will sponsor the Twenty-fifth Annual Meeting of Head and Neck Oncology, to be held in Edinburgh, Scotland, United Kingdom, on August 23-26, 1993.

International and local faculty will present extensive social and family programs.

For further information, please contact Mr. P. J. Bradley, Honorary Secretary, Department of Otorhinolaryngology–Head and Neck Surgery, University Hospital, Queens Medical Centre, Nottingham, NG7 2UH, England, or phone 0602 421421.

#### **Sixth International Congress on Interventional Ultrasound**

The Sixth International Congress on Interventional Ultrasound will be held in Copenhagen, Denmark, on September 7-10, 1993.

For further information, please contact Christian Nolsoe, Congress Secretary, Department of Ultrasound, Herlev Hospital, University of Copenhagen, DK-2730 Herlev-Denmark, or call +45/ 44 53 53 00 ext. 3240.

## **CORRECTION**

The Supplement to the December 1992 issue of the *JOURNAL* (Volume 107, Number 6, Part 2), incorrectly listed Dr. Bruce R. Gordon as Chief of Otolaryngology at the Massachusetts Eye and Ear Institute. Dr. Joseph Nadol is Chief of Otolaryngology at the Massachusetts Eye and Ear Infirmary. Dr. Gordon is Chief of Otolaryngology at Cape Cod Hospital.