

UC Davis

UC Davis Previously Published Works

Title

Contemporary management of temporomandibular joint fractures in dogs and cats: review and expert insights on diagnostic imaging, treatment strategies, and long-term outcomes.

Permalink

<https://escholarship.org/uc/item/05x3b5wt>

Author

Arzi, Boaz

Publication Date

2023-06-01

DOI

10.2460/javma.23.04.0211

Copyright Information

This work is made available under the terms of a Creative Commons Attribution License, available at <https://creativecommons.org/licenses/by/4.0/>

Peer reviewed

Contemporary management of temporomandibular joint fractures in dogs and cats: review and expert insights on diagnostic imaging, treatment strategies, and long-term outcomes

Boaz Arzi, DVM, DAVDC, DEVDC, FF-AVDC-OMFS^{1,2*}

¹Department of Surgical and Radiological Sciences, School of Veterinary Medicine, University of California-Davis, Davis, CA

²Veterinary Institute for Regenerative Cures, School of Veterinary Medicine, University of California-Davis, Davis, CA

*Corresponding author: Dr. Arzi (barzi@ucdavis.edu)

Received April 21, 2023

Accepted May 30, 2023

doi.org/10.2460/javma.23.04.0211

ABSTRACT

Management of temporomandibular joint (TMJ) fractures is challenging and is a subject of ongoing discussions and controversies in both the veterinary and human medical fields. Regardless of the management strategy, obtaining precise diagnostic imaging in the form of conventional or cone-beam computed tomography and potentially magnetic resonance imaging is pivotal for medical and surgical decision-making and prognostic purposes. The main objective of TMJ fracture management is a rapid return to normal function via restoration of pretrauma occlusion, range of motion, and masticatory function. With that in mind, it is prudent to distinguish between surgical interventions, such as condylectomy and open reduction with internal fixation, or to elect a conservative management approach. Given the diversity in TMJ fracture and patient circumstances, such as age, concomitant trauma, financial situation, and availability of expertise, the formulation of an individualized treatment plan is recommended. Knowledge of potential short- and long-term complications such as infection, malocclusion, ankylosis, fibrosis, and osteoarthritis is essential during TMJ fracture management. Importantly, as our clinical and research knowledge on managing TMJ fractures in dogs and cats grows, we rely on comparative evidence-based overviews, and inspirations from human medical experts to advance the veterinary field. Hence, this review discusses contemporary approaches to managing TMJ fractures and the outcomes in dogs and cats from a one-health perspective.

Introduction

The temporomandibular joints (TMJ) are bilateral, synovial joints, lined by fibrocartilage, that facilitate a broad range of essential functions supporting life, such as mastication, airway patency, and social interactions.¹⁻³ The kinematics of the TMJ in the dog is a hinge-like motion. Minimal translation is also present in approximately 50% of individuals. In the cat, the TMJ motion is more restrictive.¹

Fractures of the TMJ may occur at the condylar process and the mandibular head and/or at the mandibular fossa of the squamous part of the temporal bone.⁴⁻⁷ One study⁴ demonstrated that within the realm of TMJ disorders in dogs and cats, TMJ fractures were the second most common disorder in the dog and the first most common TMJ disorder in the cat. In the dog, the frequency of fractures of the mandibular fossa of the temporal bone or condylar process of the mandible or both bones is reported to be similar.⁴ However, in the cat, the condylar process

of the mandible is reported to be the most fractured bone in the TMJ, with substantially lesser occurrence for the mandibular fossa of the temporal bone.^{4,6,8} Furthermore, intra-articular fractures tend to occur in most TMJ fractures of cats and to a lesser degree in dogs.^{6,7} It is recognized that the condylar process is a mechanically weak point of the mandible and is at high risk of fracture during trauma.^{9,10} Importantly, a recent study⁷ demonstrated that in immature dogs, rostral mandibular trauma (ie, symphyseal separation, rostral mandibular fractures) is significantly associated with articular surface fractures of the TMJ. It is speculated that trauma occurring with the mouth open facilitates the transmission of external force to the condylar process and the TMJ in general.¹⁰ However, when the mouth is closed, teeth in occlusion promote a defense against transmitting the trauma forces to the TMJ.¹⁰ Regardless, in fractures of the TMJ, the soft tissues associated with the joint and its proximity, such as the muscles of mastication surrounding the TMJ as well as the lateral

ligament and the joint capsule, govern the degree of displacement resulting from the trauma in addition to the magnitude of the trauma and its direction.¹⁰⁻¹²

Management of TMJ fractures is complex and requires a comprehensive observation that includes the patient's age (ie, stage of growth), dentition status, the degree of displacement, involvement of the articular surface, concurrent maxillofacial fractures, and occlusion.¹³ Importantly, imaging modalities and expertise available are crucial for formulating therapeutic plans and execution. The management of TMJ fractures can be roughly divided into "closed treatment" (ie, conservative or nonsurgical) and "open treatment" (ie, surgical).¹³⁻¹⁵ However, variations in the therapeutic approaches and combination therapy may also be selected.

This review covers current medical (ie, human and veterinary) literature pertinent to the contemporary management of TMJ fractures, from imaging to surgical planning and therapeutic approaches, including surgical and conservative methods. Finally, the outcome of TMJ fractures and their management will be discussed.

Diagnostic Imaging

The utilization of advanced diagnostic imaging following patient stabilization is fundamental in the diagnosis and management of maxillofacial trauma and, in particular, TMJ disorders.¹⁶ It has long been recognized that CT is superior to conventional radiographs in its ability to precisely identify anatomical structures of the skull and to detect maxillofacial injuries without superimposition.^{5,17,18} In addition, CT is helpful not only in the precise diagnosis of fractures but also in describing their morphology and spatial topography. Importantly, patients presented with maxillofacial trauma are at risk of having immediate or delayed concomitant neurologic, eye, and other soft tissue injuries.^{19,20} A recent study⁷ demonstrated that 32% of dogs with maxillofacial trauma also had concomitant injuries. Therefore, there should be a low threshold to obtaining a comprehensive trauma workup in the form of advanced imaging, even if the initial observation reveals an isolated injury.¹⁹ To further clarify, conventional CT with contrast, rather than cone-beam CT (CBCT), is recommended in situations where a neurologic injury is suspected, as it is valuable in identifying the presence of intracranial traumatic injuries such as intracranial hemorrhage and cerebral edema.²⁰

The use of CBCT for diagnosing TMJ injuries is on a high trajectory in veterinary medicine.¹⁶ It has relatively lower costs than conventional CT and less radiation while being faster. In addition, newer mobile CBCT machines may be used intraoperatively.²¹ Current limitations of its use are the lack of soft tissue details as compared to conventional CT and the limitation in its field of view (FOV).^{3,16} The choice of FOV affects image resolution such that a large FOV increases pixel size and decreases the resolution.¹⁷ Therefore, the FOV should be kept as small as possible for TMJ injuries while still

including pertinent anatomy that may be affected by the trauma.

Supplementing CT or CBCT images with 3-D reconstruction is helpful in understanding the spatial location of the fracture, characterization of the fracture fragments, and for surgical planning.^{7,16,22}

Magnetic resonance imaging is commonly utilized in people that sustained TMJ injury due to its high ability to detect soft tissue injuries such as disc displacement, retrodiscal tear, joint effusion, and hemarthrosis.^{3,19} While MRI has become widely available in veterinary medicine and is a gold standard for neuroimaging, its use for diagnosing TMJ injuries in dogs and cats is less common at this juncture, likely due to higher costs and length of the scan.¹⁶

In conclusion, the author recommends using conventional CT for maxillofacial trauma cases with clinical evidence or suspicion of neurologic injury of the brain or spinal cord. In situations where the neurologic injury is not evident or suspected, CBCT is recommended. Regardless, advanced diagnostic imaging is needed to identify and characterize the presence and extent of the TMJ injury as well as for patient management and follow-up.

Fracture Classification

TMJ fractures were found to be the second most common TMJ disorder in dogs and the first most common disorder in cats.⁴ The distribution of TMJ fractures differs significantly between dogs and cats.⁴ In dogs, there is a similar occurrence of fractures of the mandibular fossa of the temporal bone and the condylar process of the mandible and also when both bones were fractured. However, in cats, the pattern is different in that the condylar process of the mandible is fractured most with a rare concurrent fracture of the temporal bone.^{4,23} Another study⁶ evaluating TMJ fractures in cats found a similar pattern and that most condylar process fractures were intra-articular. Fractures of the condylar process are also the most common TMJ fracture in people.^{24,25}

A descriptive classification system exists following the topographical regions of the condylar process (ie, condylar base, condylar neck, and condylar head).²⁴ The author has adapted the Arbeitsgemeinschaft for Osteosynthese craniomaxillofacial classification system and modified it for the dog and the cat (**Figure 1**).^{13,24} Essentially, a condylar process fracture is a fracture that extends caudally to the mandibular notch. A mandibular head fracture is defined as a fracture that involves the mandibular head. Thus, a distinction between fractures of the mandibular head and the condylar process may not be clinically clear due to the various complexities of the fracture situation. In addition, the complexity of the fracture can identify as 1 of 3 levels: (1) no fragmentation, (2) minor fragmentation, and (3) major fragmentation. The terms "minor" and "major" refer to fractures with a pattern that preserves or compromises the mandibular head integrity. With regards to fracture displacement, the vertical apposition of the fragments can be classified as 0 = complete

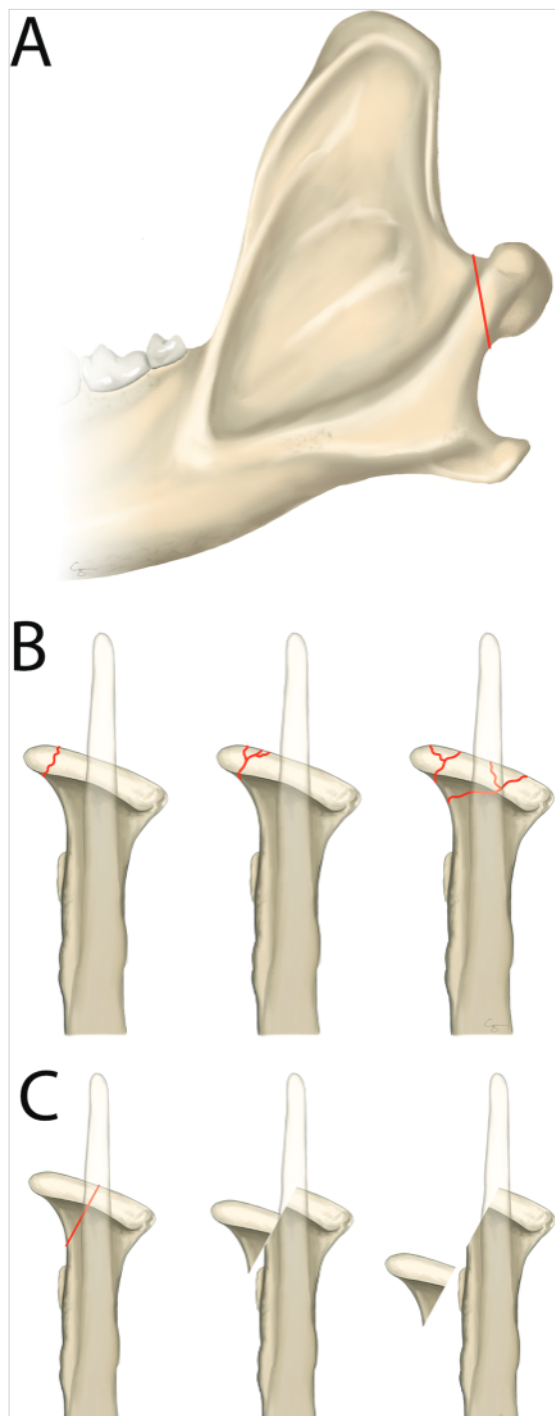


Figure 1—Modified TMJ fracture classification based on the Arbeitsgemeinschaft für Osteosynthese craniomaxillofacial classification system that was adapted by the author for the dog and the cat. A—condylar process fracture (ie, the entire condylar process and mandibular head are fractured). B—Classification is based on the complexity of the fracture from no fragmentation to minor fragmentation and up to major fragmentation. C—classification of fracture displacement from no displacement and up to complete displacement. Reprinted from *Oral and Maxillofacial Surgery in Dogs and Cats*. 2nd ed. Arzi B, Lantz GC (Authors). Fractures and luxation involving the TMJ: p. 368–376. Copyright 2020, with permission from Elsevier.

(ie, full surface contact), 1 = partial (ie, some surface contact), and 2 = loss or no contact (ie, complete displacement). In cases with several fractures, classification is made according to the worst fracture. As mentioned earlier, mandibular head fractures are mostly intra-articular. Finally, a similar classification as for the mandibular head can be followed for the mandibular fossa.

Management Decision-Making

Management of TMJ fractures should be planned in the context of other concomitant maxillofacial fractures and the objectives of a quick return to normal function, restoration of normal occlusion (ie, pretrauma occlusion), restoring range of motion (ROM), and masticatory function.^{19,26} As noted in the human medical field, TMJ fracture management is not devoid of ongoing controversies. Specifically, do we need to intervene surgically (ie, open reduction with internal fixation) or manage the fracture conservatively (ie, closed treatment)? Given the diversity in TMJ fracture and patient circumstances such as age, concomitant trauma, financial situation, and availabilities of expertise, formulation of the individualized treatment plan is required.

Closed Treatment

Utilizing closed management (ie, conservative or minimally invasive) of TMJ fractures has been the mainstay of TMJ fracture management in most circumstances in veterinary medicine, and to some extent, in the human medical field.^{13,19,27,28} Closed treatment means not opening the joint and using other minimally invasive methods such as a muzzle or rigid or elastic maxillomandibular fixation (MMF). Elastic MMF therapy means the utilization of intermaxillary screws or orthodontic buttons and elastic orthodontic chains to allow some movement of the jaws during the healing phases.¹³ The author prefers elastic therapy over a rigid one as it presumes to reduce the chance for fibrosis or ankylosis of the joint and its surrounding muscles and is likely to facilitate more blood supply to the healing site and maintain joint homeostasis. Elastic therapy was also reported as more tolerable as compared to a rigid one in children.²⁹ In situations where malocclusion is moderate to severe, initial management with rigid MMF for approximately 2 weeks followed by conversion to elastic therapy is a rational option.¹³ This should be accompanied by either using a feeding tube to bypass the oral cavity or a soft, pureed diet for 3 weeks. A detailed description of those minimally invasive methods is available elsewhere and is not within the scope of this review.¹³ Regardless of the closed treatment method, the goal is to facilitate bone healing while minimizing the chance for displacement and malocclusion.^{13,19,25,30}

In younger patients, the TMJ is still growing and is rich with osteogenic potential, stem cells, blood supply, and a strong inflammatory reaction following the injury. Hence, bone healing is likely to occur

within 2 to 3 weeks (**Figure 2**). In fact, understanding the growth and development of the TMJ is helpful in managing those fractures in young patients.³¹ Specifically, the condylar process (and the mandible) development occurs through remodeling and response to biomechanical strains from the surrounding soft tissues contributing to the structure-function relationships. The healing blastema for the fractured condylar process emanates from the periosteum on the medial aspect of the ramus. Bone deposition occurs via endochondral ossification, primarily in the condylar process, leading to the vertical growth of the mandibular ramus.^{27,32} Hence, TMJ fractures at a young age or surgical interventions at the TMJ in the critical growth phases may result in malocclusion.¹⁹ In addition, given that the mandible is the last facial bone to reach skeletal maturity, it is more susceptible to growth-related injuries.²⁸ With that knowledge in mind, in young patients that

have lost the entire condylar process, spontaneous regeneration with the formation of a condylar process-like structure may occur (**Figure 3**). The latter, in turn, may still result in mandibular deformity and malocclusion.³³⁻³⁵ Owners should be counseled on this potential sequela, and potential future treatment of malocclusions should be discussed.

Treating TMJ fractures, especially with a closed approach, could benefit from rehabilitation. Specifically, the aim is to restore an effortless normal ROM and normal occlusion for the breed without the sense of tension on the muscles of mastication or pain on opening the mouth.²⁵ There are obvious differences in behavior and compliance between people and dogs and cats. Hence, the ability to perform jaw exercises following TMJ fracture treatment may be limited, depending on the patient's demeanor. Documenting the mouth opening before therapy is essential to assessing progress and

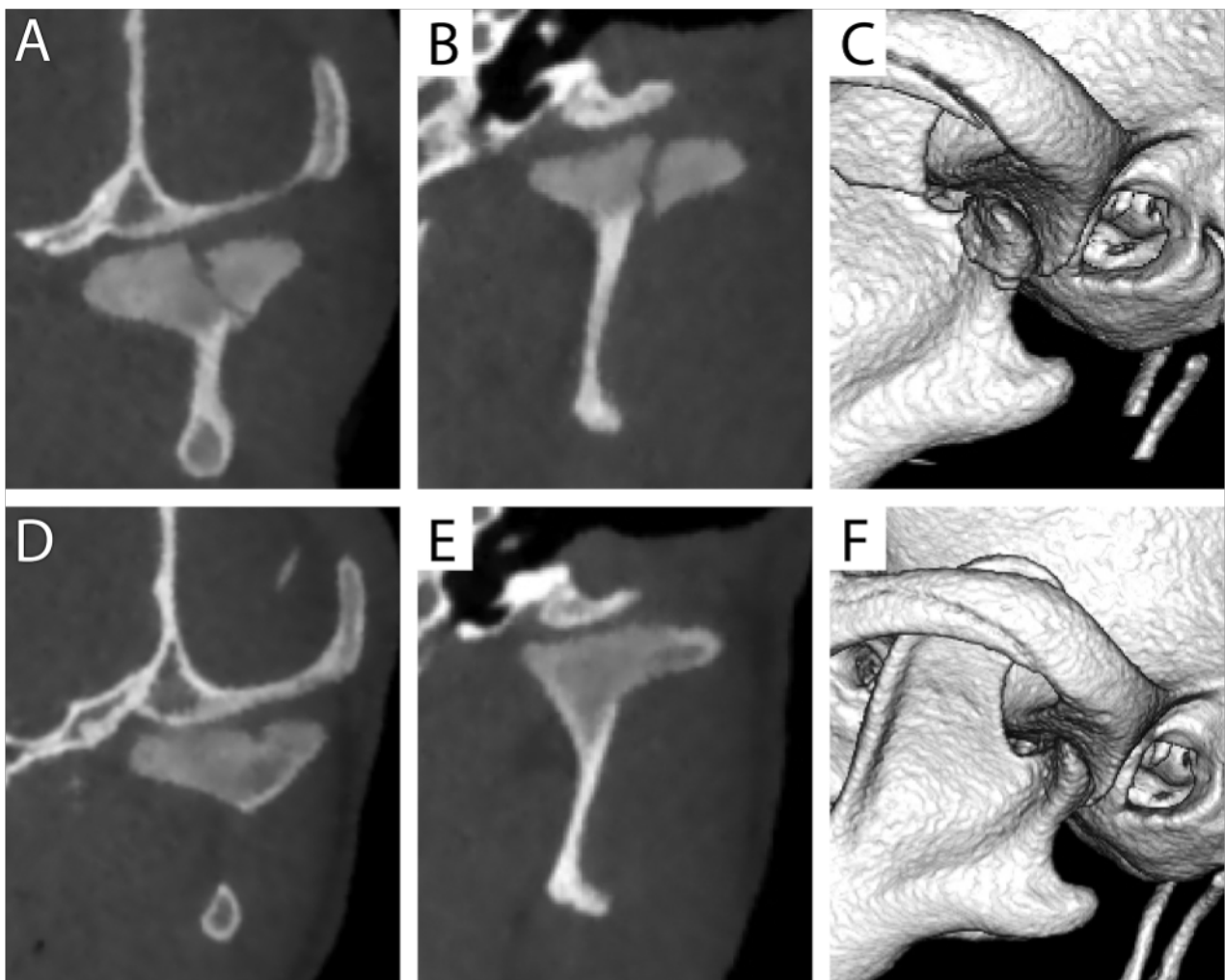


Figure 2—A unilateral, moderately displaced with minor fragmentation fracture of the left mandibular head on the condylar process with an intra-articular component in a sagittal (A), dorsal/coronal (B), and 3-D view (C) in a 3-months-old dog. The dog was managed with a closed treatment approach using a commercially available muzzle. Recheck CBCT at 3 weeks post trauma in a sagittal (D), dorsal/coronal (E), and 3-D view (F) demonstrating complete healing and remodeling of the mandibular head with a small subchondral defect at the center of the articular surface. This exemplifies that in younger patients, the TMJ fractures can heal and remodel 2 to 3 weeks.

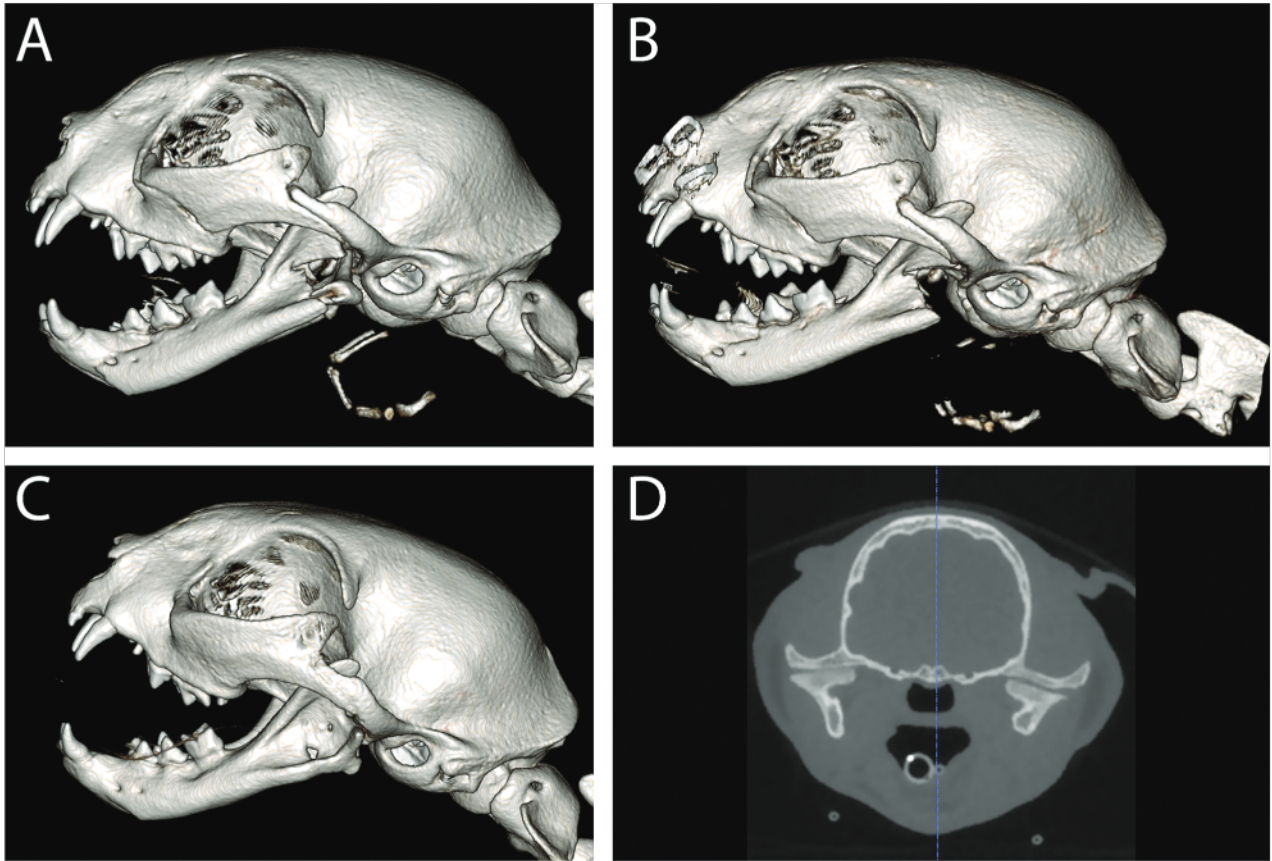


Figure 3—3-Dimensional CBCT images demonstrating a unilateral, severely displaced, condylar process fracture that includes the caudal mandible in an 11-month-old female spayed domestic shorthair cat (A). Due to the severe displacement, the condylar fracture prevented adequate opening and closing of the mouth, and an open treatment approach was deployed via condylectomy (ie, removal of the entire fractured fragment; B). A 3-months recheck CBCT demonstrated nearly complete regeneration and remodeling of the left mandibular head on the condylar process as demonstrated in 3D (C) and sagittal image (D).

clinical improvement. Furthermore, measuring the ROM, using the same technique and tools, at each recheck appointment is prudent for assessing progress or deterioration such as TMJ ankylosis or fibrosis (**Figure 4**). Pragmatically, it is difficult to assert the degree of preinjury opening. However, there are jaw opening “norms” reported by Gracis and Zini³⁶ based on the vertical mandibular range of motion (vmROM) corresponding to the maximum interincisal opening. The vmROM in that report was divided based on the dog’s weight, with the mean vmROM of all dogs of 107 ± 30 mm. The mean vmROM of the cats was 62 ± 8 mm. Specific reference numbers are described in that report³⁶ based on patient size.

When evaluating progress in mouth opening following TMJ trauma, identifying mouth opening of lesser than expected should prompt an investigation into the cause. It may be that the limitation is directly associated with the TMJ injury and its surrounding muscles and ligaments, or there may be secondary fibrotic changes due to a lack of appropriate movement.²⁵ This, in turn, may relate to persistent pain or neurologic damage. Asymmetry of jaw opening and closing may also hinder rehabilitation efforts.²⁵ Finally, it is recommended that the patient

will be reimaged to assess the healing and the potential for TMJ ankylosis, albeit rare, as described earlier. To conclude, TMJ fracture is typically accompanied by substantial injuries to the muscles and joint capsule and ligaments. Hence, rehabilitation following TMJ injury should be started as soon as possible (ie, approximately 1 to 2 weeks following injury) with the aim of early return to normal function.³⁷ This in turn is likely to reduce the chances of fibrosis or ankylosis of the TMJ and its supporting structures.

Open Treatment

Given the challenging anatomy and size of the TMJ bones, especially in smaller patients, open reduction and internal fixation (ORIF) are not common in veterinary medicine at this juncture. An absolute indication for open treatment includes severe and displaced fractures of the mandibular fossa (ie, the squamous part of the temporal bone) and/or the condylar process preventing closure or opening of the mouth, as well as displacement of the condylar process into the auditory system or other critical locations.^{19,26} Relative indications for open treatment are severely fragmented and displaced fractures,

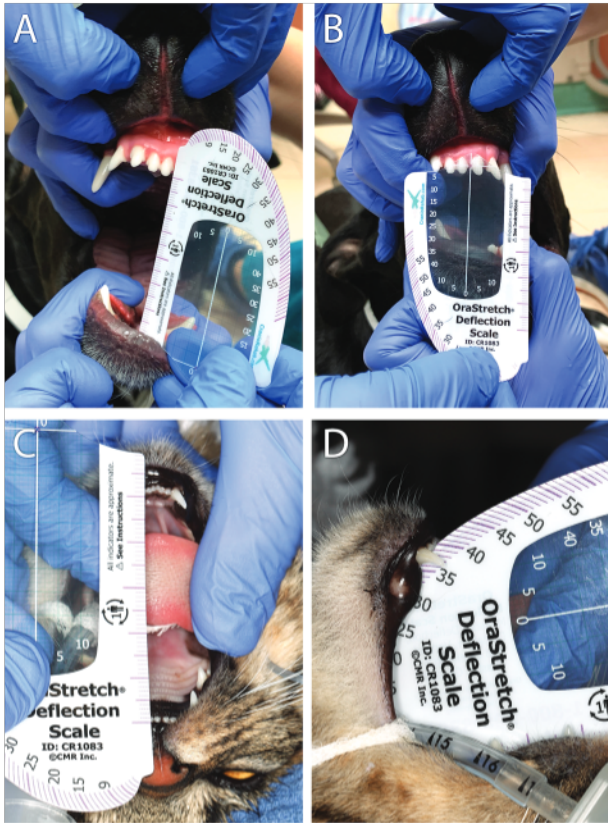

Figure 4—Clinical images of a dog demonstrating measuring mouth opening between the incisor teeth (A) as well as the degree of laterotrusion (B; ie, side-to-side movement) as part of an awake examination of the range of motion. Using the same technique and tools, the range of motion is assessed under general anesthesia in the cat depicted in Figure 3, demonstrating the extent of mouth opening (C and D). Examining the range of motion at each recheck appointment is prudent to assess progress or deterioration, such as TMJ ankylosis or fibrosis.

especially if there is a high index of suspicion of the potential for ankylosis (ie, fracture that limits ROM or interferes with opening or closing the mouth) and doubtful follow-up opportunities.¹⁹

The use of ORIF, although found to provide a better functional reconstruction of condylar process fractures than closed treatment in human patients,^{14,19,26} is challenging and, at times, not possible in veterinary patients due to size and anatomy limitations. Another report³⁸ found that both ORIF and closed treatment yield acceptable results but with significant clinical differences in terms of occlusion, mouth opening, functionality, and pain in favor of open reduction. Hence, in certain types of fractures, especially in the mandibular fossa, using ORIF, although challenging, is possible with good outcomes (**Figure 5**). Importantly, when selecting implants to repair TMJ fractures using ORIF, titanium miniplates and screws are recommended as they offer superior biocompatibility and osteointegration over stainless-steel implants. The latter are manufactured in low-profile systems that are ideal for the oral and maxillofacial (OMF) region.^{39–43} Taken together, evidence from the human medical field demonstrates that the ORIF for the management of TMJ fractures has specific indications and may offer benefits such as faster return to function, better occlusion, and less pain as compared to closed reduction. However, pragmatically it is not easy and occasionally impossible to apply in dogs and cats. In certain situations, ORIF, although technically challenging, is possible and with anecdotally good results. Notably, condylectomy should be reserved for exceptional situations where the condylar process is severely displaced or fragmented, preventing the closing or opening of the mouth.

Long-term Consideration

Outcome studies, in veterinary medicine, evaluating the success rate of closed or open approaches to TMJ fracture management in dogs and cats are scarce. A recent study⁷ demonstrated a significant positive correlation between the severity of fragmentation or displacement of the fracture fragments and negative fracture healing outcomes. All of the TMJ fracture cases in that study were treated conservatively. Importantly, in the same study, not a

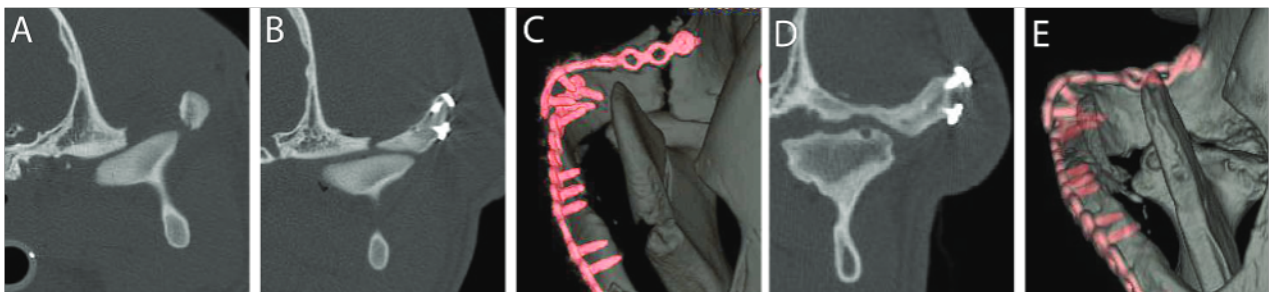


Figure 5—A—Computed tomographic images of a young dog that sustained multiple maxillofacial fractures and severe, displaced fracture of the mandibular fossa of the squamous temporal bone (ie, the dorsal bone component of the TMJ) preventing opening or closing the mouth as the condylar process became dislodged between the fractured bones. B and C—An ORIF approach with a 2.0 nonlocking titanium miniplate resulted in adequate opposition with a small gap. D and E—3-month CT recheck demonstrated bone healing and remodeling with moderate-to-severe osteoarthrotic changes such as uneven articular surfaces, osteophytes, and a subchondral bone cyst. C and E—Reprinted from *Oral and Maxillofacial Surgery in Dogs and Cats*. 2nd ed. Arzi B, Lantz GC (Authors). Fractures and luxation involving the TMJ: p. 368–376. Copyright 2020, with permission from Elsevier.

single dog developed TMJ ankylosis despite 36% of cases exhibiting articular surface fractures. These findings agree with the relatively low (0.4%) occurrence of TMJ ankylosis reported in people following TMJ fractures.⁴⁴ However, TMJ ankylosis was reported to be higher (11%) in cats, with no significant relationship between age and the development of ankylosis.²³ In that study,²³ TMJ ankylosis was mainly observed in fractures affecting the condylar process and mandibular fossa combined. Those numbers should be taken cautiously as that study²³ only used skull radiography and clinical examination, not CT imaging. In the author's clinical experience and using conventional CT and CBCT, the occurrence of TMJ ankylosis is lower than reported.

Fractures of the condylar process may occur in concert with soft tissue injuries of the TMJ.¹² Specifically, intracapsular and dislocated condylar process fractures typically result in more severe soft tissue injuries such as disc displacement or disruption, hemarthrosis, and capsular injury. These, in turn, may cause long-term complications such as chronic pain or discomfort, decreased ROM, ankylosis, and osteoarthritis.^{12,45,46}

Conclusion and Expert Perspective

Management of TMJ fractures in dogs and cats should be planned in the context of the overall maxillofacial trauma that the patient sustained. Clinical studies clearly demonstrate that TMJ fractures may occur in concert with other OMF fractures. Utilizing advanced diagnostic imaging once the patient is clinically stable is fundamental to treatment planning. With the variable level of expertise in managing OMF trauma and TMJ fractures, it is important to remember the "first do no harm" phrase coined by Hippocrates. Selecting an approach that the surgeon is trained and comfortable with is fair and important. If the method is inappropriate or not ideal for the clinical situation, a referral to a specialist is prudent. As noted in this review, substantial evidence-based information was derived from the human literature on the TMJ. While the author has been investigating the TMJ for over a decade in both clinical and laboratory settings, a substantial portion of the author's current approaches was derived from the human medical literature and personal interactions with leading TMJ surgeons and researchers. In this regard, the author is suggesting deploying the Delphi technique to TMJ fracture management. The Delphi technique is a consensus-based method that incorporates experts' anonymous opinions using an iterative process with controlled feedback and statistics that could improve the veterinary perspectives and approaches to this challenging clinical problem.⁴⁷ Until such an evidence-based consensus is reached, the author recommends a closed treatment approach for minimally or moderately displaced TMJ fractures, provided those do not cause difficulties or inability to open or close the mouth. This approach becomes more challenging if the

malocclusion is present. If TMJ fracture is severe enough to cause an inability to open/close the mouth or result in substantial malocclusion, an open approach with ORIF or condylotomy is warranted if possible. This may require referral to a specialized clinic with experience in managing TMJ fractures (as well as other maxillofacial injuries). Finally, although TMJ ankylosis is a possible sequela following TMJ fracture, the occurrence seems to be low.

Acknowledgments

The author declares that there were no conflicts of interest or external funding in the preparation of this manuscript.

The author would like to thank Dr. Chrisoula Toupadakis with the artwork.

References

1. Lin AW, Vapniarsky N, Cissell DD, et al. The temporomandibular joint of the domestic dog (*Canis lupus familiaris*) in health and disease. *J Comp Pathol*. 2018;161:55-67. doi:10.1016/j.jcpa.2018.05.001
2. Murphy MK, MacBarb RF, Wong ME, Athanasiou KA. Temporomandibular disorders: a review of etiology, clinical management, and tissue engineering strategies. *Int J Oral Maxillofac Implants*. 2013;28(6):e393-e414. doi:10.11607/jomi.te20
3. Tamimi D HD. *Specialty Imaging: Temporomandibular Joint*. Elsevier; 2016.
4. Arzi B, Cissell DD, Verstraete FJ, Kass PH, DuRaine GD, Athanasiou KA. Computed tomographic findings in dogs and cats with temporomandibular joint disorders: 58 cases (2006-2011). *J Am Vet Med Assoc*. 2013;242(1):69-75. doi:10.2460/javma.242.1.69
5. De Paolo MH, Arzi B, Pollard RE, Kass PH, Verstraete FJM. Craniomaxillofacial trauma in dogs-part I: fracture location, morphology and etiology. *Front Vet Sci*. 2020;7:241. doi:10.3389/fvets.2020.00241
6. Mestrinho LA, Sebastiao SS, Zwierucho MA, et al. CT characterisation and classification of feline temporomandibular joint trauma: a case series of 79 cats. *J Feline Med Surg*. 2022;24(12):1181-1186. doi:10.1177/1098612X211066654
7. Wolfs E, Arzi B, Guerrero Cota J, Kass PH, Verstraete FJM. Craniomaxillofacial trauma in immature dogs-etiology, treatments, and outcomes. *Front Vet Sci*. 2022;9:932587. doi:10.3389/fvets.2022.932587
8. Tundo I, Southerden P, Perry A, Haydock RM. Location and distribution of craniomaxillofacial fractures in 45 cats presented for the treatment of head trauma. *J Feline Med Surg*. 2019;21(4):322-328. doi:10.1177/1098612X18776149
9. Glazer M, Joshua BZ, Woldenberg Y, Bodner L. Mandibular fractures in children: analysis of 61 cases and review of the literature. *Int J Pediatr Otorhinolaryngol*. 2011;75(1):62-64. doi:10.1016/j.ijporl.2010.10.008
10. Khattak YR, Sardar T, Iqbal A, et al. Treatment of pediatric bilateral condylar fractures: a comprehensive analysis. *J Stomatol Oral Maxillofac Surg*. 2022;124(1S):101339.
11. Lesko RP, De Ruyter BJ, Kamel GN, Davidson EH. The management of a pediatric condylar fracture with dynamic elastic therapy. *Eplasty*. 2019;19:ic16.
12. Weinberg FM, Speksnijder CM, Forouzanfar T, Rosenberg A. Articular soft tissue injuries associated with mandibular condyle fractures and the effects on oral function. *Int J Oral Maxillofac Surg*. 2019;48(6):746-758. doi:10.1016/j.ijom.2019.01.025
13. Arzi B, Lantz GC. Fractures and luxations involving the temporomandibular joint. In: Verstraete FJM, Lommer MJ,

- Arzi B, eds. *Oral and Maxillofacial Surgery in Dogs and Cats*. 2nd ed. Elsevier; 2020:368–376.
14. Lopez J, Lake IV, Khavanin N, et al. Noninvasive management of pediatric isolated, condylar fractures: less is more? *Plast Reconstr Surg*. 2021;147(2):443–452. doi:10.1097/PRS.0000000000007527
 15. Zhou HH, Han J, Li ZB. Conservative treatment of bilateral condylar fractures in children: case report and review of the literature. *Int J Pediatr Otorhinolaryngol*. 2014;78(9):1557–1562. doi:10.1016/j.ijporl.2014.06.031
 16. Cissell DD, Hatcher D, Arzi B, Verstraete FJM. Diagnostic imaging in oral and maxillofacial surgery. In: Verstraete FJM, Lommer MJ, Arzi B, eds. *Oral and Maxillofacial Surgery in Dogs and Cats*. 2nd ed. Elsevier; 2020:56–64.
 17. Bar-Am Y, Pollard RE, Kass PH, Verstraete FJ. The diagnostic yield of conventional radiographs and computed tomography in dogs and cats with maxillofacial trauma. *Vet Surg*. 2008;37(3):294–299. doi:10.1111/j.1532-950X.2008.00380.x
 18. De Paolo MH, Arzi B, Pollard RE, Kass PH, Verstraete FJM. Craniomaxillofacial trauma in dogs—part II: association between fracture location, morphology and etiology. *Front Vet Sci*. 2020;7:242. doi:10.3389/fvets.2020.00242
 19. Bae SS, Aronovich S. Trauma to the pediatric temporomandibular joint. *Oral Maxillofac Surg Clin North Am*. 2018;30(1):47–60. doi:10.1016/j.coms.2017.08.004
 20. Vali Y, Gielen I, Soroori S, Ludewig E. The diagnostic value of intravenous contrast computed tomography in addition to plain computed tomography in dogs with head trauma. *BMC Vet Res*. 2021;17(1):46. doi:10.1186/s12917-021-02764-6
 21. Goguet Q, Lee SH, Longis J, Corre P, Bertin H. Intraoperative imaging and navigation with mobile cone-beam CT in maxillofacial surgery. *Oral Maxillofac Surg*. 2019;23(4):487–491. doi:10.1007/s10006-019-00765-2
 22. Winer JN, Verstraete FJM, Cissell DD, Lucero S, Athanasiou KA, Arzi B. The application of 3-dimensional printing for preoperative planning in oral and maxillofacial surgery in dogs and cats. *Vet Surg*. 2017;46(7):942–951. doi:10.1111/vsu.12683
 23. Cetinkaya MA. Temporomandibular joint injuries and ankylosis in the cat. *Vet Comp Orthop Traumatol*. 2012;25(5):366–374. doi:10.3415/VCOT-11-10-0146
 24. Neff A, Cornelius CP, Rasse M, Torre DD, Audige L. The comprehensive AOCMF classification system: condylar process fractures—level 3 tutorial. *Craniomaxillofac Trauma Reconstr*. 2014;7(Suppl 1):S044–S058. doi:10.1055/s-0034-1389559
 25. Rzewuska A, Kijak E, Halczy-Kowalik L. Rehabilitation in the treatment of mandibular condyle fractures. *Dent Med Probl*. 2021;58(1):89–96. doi:10.17219/dmp/128092
 26. Abdel-Galil K, Loukota R. Fractures of the mandibular condyle: evidence base and current concepts of management. *Br J Oral Maxillofac Surg*. 2010;48(7):520–526. doi:10.1016/j.bjoms.2009.10.010
 27. Roberts WE, Stocum DL. Part II: temporomandibular joint (TMJ)-regeneration, degeneration, and adaptation. *Curr Osteoporos Rep*. 2018;16(4):369–379. doi:10.1007/s11914-018-0462-8
 28. Smartt JM Jr, Low DW, Bartlett SP. The pediatric mandible: II. Management of traumatic injury or fracture. *Plast Reconstr Surg*. 2005;116(2):28e–41e. doi:10.1097/01.prs.0000173445.10908.f8
 29. Tabrizi R, Langner NJ, Zamiri B, Aliabadi E, Daneste H, Naghizade S. Comparison of nonsurgical treatment options in pediatric condylar fractures: rigid intermaxillary fixation versus using guiding elastic therapy. *J Craniofac Surg*. 2013;24(3):e203–e206. doi:10.1097/SCS.0b013e318293d605
 30. Sidebottom AJ. Post-traumatic management of condylar fracture complications. *J Oral Biol Craniofac Res*. 2022;12(2):284–292. doi:10.1016/j.jobcr.2022.02.001
 31. Ochareon P, Herring SW. Growing the mandible: role of the periosteum and its cells. *Anat Rec (Hoboken)*. 2007;290(11):1366–1376. doi:10.1002/ar.20588
 32. Tang Y, Wang X, Zhu Y, Sun H, Zhu M. A Comparative evaluation of CBCT outcomes of two closed treatment methods in intracapsular condylar fractures. *Oral Surg Oral Med Oral Pathol Oral Radiol*. 2017;123(5):e141–e147. doi:10.1016/j.oooo.2016.11.019
 33. Guven O. Formation of condyle-like structure after treatment of temporomandibular joint ankylosis: literature review and long-term follow-up of two patients. *Case Rep Med*. 2017;2017:9060174. doi:10.1155/2017/9060174
 34. de Oliveira Filho MA, Almeida LE, Doetzer AD, Giovanini AF, Malafaia O. Spontaneous condyle-like development after total resection of mandible giant osteochondroma: case report and a follow-up for five years. *Case Rep Surg*. 2020;2020:3720909.
 35. Nagase M, Ueda K, Suzuki I, Nakajima T. Spontaneous regeneration of the condyle following hemimandibulectomy by disarticulation. *J Oral Maxillofac Surg*. 1985;43(3):218–220. doi:10.1016/0278-2391(85)90164-8
 36. Gracis M, Zini E. Vertical mandibular range of motion in anesthetized dogs and cats. *Front Vet Sci*. 2016;3:51. doi:10.3389/fvets.2016.00051
 37. Lindfors E, Arima T, Baad-Hansen L, et al. Jaw exercises in the treatment of temporomandibular disorders—an international modified Delphi study. *J Oral Facial Pain Headache*. 2019;33(4):389–398. doi:10.11607/ofph.2359
 38. Prakash R Sr, Ramesh K, Alwala AM, Porika R, Manjusha, Katkuri S. Open reduction and internal fixation versus closed reduction and maxillomandibular fixation of condylar fractures of the mandible: a prospective study. *Cureus*. 2022;14(1):e21186. doi:10.7759/cureus.21186
 39. Arzi B, Verstraete FJ. Internal fixation of severe maxillofacial fractures in dogs. *Vet Surg*. 2015;44(4):437–442. doi:10.1111/j.1532-950X.2014.12161.x
 40. Evenhuis JV, Verstraete FJM, Arzi B. Management of failed stainless steel implants in the oromaxillofacial region of dogs. *Front Vet Sci*. 2022;9:992730. doi:10.3389/fvets.2022.992730
 41. Langford RJ, Frame JW. Surface analysis of titanium maxillofacial plates and screws retrieved from patients. *Int J Oral Maxillofac Surg*. 2002;31(5):511–518. doi:10.1054/ijom.2002.0283
 42. Boudrieau RJ, Kudisch M. Miniplate fixation for repair of mandibular and maxillary fractures in 15 dogs and 3 cats. *Vet Surg*. 1996;25(4):277–291. doi:10.1111/j.1532-950X.1996.tb01414.x
 43. Hayes JS, Richards RG. The use of titanium and stainless steel in fracture fixation. *Expert Rev Med Devices*. 2010;7(6):843–853. doi:10.1586/erd.10.53
 44. Laskin DM. Role of the meniscus in the etiology of posttraumatic temporomandibular joint ankylosis. *Int J Oral Surg*. 1978;7(4):340–345. doi:10.1016/S0300-9785(78)80106-9
 45. Krishnan DG. Soft tissue trauma in the temporomandibular joint region associated with condylar fractures. *Atlas Oral Maxillofac Surg Clin North Am*. 2017;25(1):63–67. doi:10.1016/j.cxom.2016.11.002
 46. Yang X, Yao Z, He D, Cai Y, Dong M, Yang C. Does soft tissue injury affect intracapsular condylar fracture healing? *J Oral Maxillofac Surg*. 2015;73(11):2169–2180. doi:10.1016/j.joms.2015.05.030
 47. John MT. Improving TMD classification using the Delphi technique. *J Oral Rehabil*. 2010;37(10):766–770. doi:10.1111/j.1365-2842.2010.02109.x