

Outcomes of Single Stage Phalloplasty by Pedicled Anterolateral Thigh Flap versus Radial Forearm Free Flap in Gender Confirming Surgery



Mona Ascha,* Jonathan P. Massie,* Shane D. Morrison,* Curtis N. Crane and Mang L. Chent†

From the Divisions of Plastic Surgery, Departments of Surgery, Case Western Reserve University School of Medicine (MA), Cleveland, Ohio, Feinberg School of Medicine, Northwestern University (JPM), Chicago, Illinois, University of Washington School of Medicine (SDM), Seattle, Washington, and Brownstein and Crane Surgical Services (CNC, MLC), San Francisco, California

Abbreviations and Acronyms

BMI = body mass index
pALT = pedicled anterolateral thigh flap
RFFF = radial forearm free flap

Accepted for publication July 25, 2017.

No direct or indirect commercial incentive associated with publishing this article.

The corresponding author certifies that, when applicable, a statement(s) has been included in the manuscript documenting institutional review board, ethics committee or ethical review board study approval; principles of Helsinki Declaration were followed in lieu of formal ethics committee approval; institutional animal care and use committee approval; all human subjects provided written informed consent with guarantees of confidentiality; IRB approved protocol number; animal approved project number.

* Equal study contribution.

† Correspondence: Brownstein and Crane Surgical Services, 575 Sir Francis Drake Blvd., Greenbrae, California 94904 (telephone: 415-625-3230; e-mail: mangchenmd@gmail.com).

Purpose: Phalloplasty is a critical step in female-to-male (transmale) gender confirming genital surgery. We examined outcomes between transmales who underwent phalloplasty with vaginectomy and full-length urethroplasty using the anterolateral thigh pedicled flap or the radial forearm free flap.

Materials and Methods: We performed a single center, retrospective study of patients who underwent phalloplasty with vaginectomy and full-length urethroplasty using an anterolateral thigh pedicled flap or a radial forearm free flap from April 2013 to July 2016. All patients had at least 6 months of followup. Urethral and nonurethral complications were recorded. Complication rates were assessed using the OR of the anterolateral thigh pedicled flap and the radial forearm free flap groups.

Results: Of the 213 patients 149 and 64 underwent radial forearm free flap and anterolateral thigh pedicled flap phalloplasty, respectively. Patients with a radial forearm free flap had a significantly higher body mass index than those with an anterolateral thigh pedicled flap. The overall urethral complication rate for radial forearm free flap and anterolateral thigh pedicled flap phalloplasty was 31.5% and 32.8%, and the rate of partial or total neophallus loss was 3.4% and 7.8%, respectively. Patients in the pedicled flap cohort experienced significantly greater odds of urethral fistula (OR 2.50, $p = 0.024$), nonurethral complications (OR 2.38, $p = 0.027$) and phallus wound dehiscence (OR 5.03, $p = 0.026$).

Conclusions: Anterolateral thigh pedicled flap phalloplasty was associated with overall greater odds of urethral and other complications at 6 months of followup. Our findings can help guide surgical decision making when selecting a flap for phalloplasty.

Key Words: penis, gender dysphoria, health services for transgender persons, surgical flaps, postoperative complications

RECENT studies conservatively estimate the global population of transgender people to be 25 million.¹⁻⁴ With greater societal acceptance and awareness of the transgender population, an increasing number of people may seek gender confirming surgery

for gender dysphoria. Evidence-based practices are needed to help reconstructive surgeons provide high quality transgender patient care.

Currently various operative techniques are available to construct a neophallus for the female-to-male

(transmale) patient. The ideal neophallus should be aesthetic, maintain tactile and erogenous sensation, permit sexual function and standing urination, and result in minimal donor site and operative morbidity.^{5–9}

Flap based techniques for phalloplasty are numerous.^{5,7,9,10} RFFF and pALT are the most frequently used flaps with the potential for tactile and erogenous sensation. RFFF with tube in tube phalloplasty has emerged as the most common technique in transmale patients.¹¹ However, donor site morbidity is significant, including a visible arm scar with temporary and sometimes permanent dysfunction and swelling of the donor site hand.⁷ pALT allows for the option of a local flap to avoid potential microsurgical vascular anastomoses. It also provides a more easily concealed donor site but carries a high risk of urethral complications such as fistulas and strictures.^{7,8} Patients frequently have more subdermal fat in the thigh than in the arm, making tube in tube formation difficult with pALT. Concomitant thinning of pALT can decrease flap thickness and facilitate neophallus and neourethral construction but it places the pedicle and overall vascularity of the flap at risk.¹² Therefore, it is typically not performed at phalloplasty.

Current literature regarding transmale phalloplasty outcomes is nonstandardized and mostly considered low quality evidence.¹³ Furthermore, there are no comparisons or analyses of outcomes according to surgical technique from a given group of surgical providers.^{5,13–15}

We examined outcomes and potential differences in complications between transmale patients who underwent 1-stage RFFF or pALT phalloplasty with vaginectomy and full-length urethroplasty. We hypothesized that phalloplasty with RFFF would have an overall lower complication rate than phalloplasty with pALT.

METHODS

Study Population and Data Collection

We performed a single center, retrospective study of transmale patients who underwent 1-stage phalloplasty with vaginectomy and full-length urethral lengthening using pALT or RFFF from April 2013 to July 2016. Patients who did not undergo vaginectomy or full-length urethroplasty were excluded from analysis. Overall 35 patients did not have sufficient followup after index phalloplasty and were not included in study.

Patients were grouped in 2 mutually exclusive cohorts of those treated with pALT vs RFFF phalloplasty. Patient choice, goals and desire to avoid donor site morbidity were the main drivers of the types of phalloplasty offered. Patients with BMI greater than 30 kg/m² were urged to proceed with RFFF phalloplasty due to the extent of subdermal fat on the thigh.

In all patients postoperative followup was at least 6 months to assess for complications. Outcome variables of interest included urethral and nonurethral complications. Specific urethra related complications that were recorded included meatal stenosis, urethral stricture and urethral fistula. Nonurethral complications that were recorded included rectal injury, partial or total flap loss, hematoma, dehiscence, abscess, loss of sensation and scrotal complications.

Statistical Analysis

Descriptive statistics were calculated for demographic variables. Statistically significant differences between the pALT and RFFF groups were determined by the Mann-Whitney U test for continuous variables and the Fisher exact test for categorical variables. Outcome variables of interest included urethral complications and nonurethral complications. Complication rates were assessed in the pALT and RFFF groups using the OR. Subset analysis of complication rates was also performed for patients who were at least 1 year after surgery. Differences were considered statistically significant at calculated $p < 0.05$. All analyses were performed with R, version 3.3.0 (<https://www.r-project.org/>).

Urethral Lengthening

All patients underwent primary full-length urethroplasty. Urethral lengthening from the native female urethral meatus to the tip of the neophallus required 2 distinct urethroplasties. Proximal/pars fixa urethroplasty was created from labia minora flaps followed by additional suture line coverage with vascularized bulbospongiosus muscle.¹⁶ The distal aspect of the pars fixa urethra was then anastomosed to the skin flap urethra created from the designated portion of the pALT or the RFFF. Scrotoplasty was performed using labia majora flaps.

Phalloplasty

Pedicled Anterolateral Thigh Flap. Our techniques of pALT phalloplasty were described previously.⁸ Briefly, preoperative markings were made on the chosen thigh donor site (fig. 1, *a*). The flap was harvested with lateral femoral cutaneous nerve preservation and the urethral meatus was matured to the phallus. Glansplasty was not performed at the index operation due to the risk of distal necrosis (fig. 1, *b* and *c*). Next the tubularized pALT flap was transposed to the male anatomical position with urethroplasty and nerve coaptation to the dorsal clitoral nerve. The donor site was closed with a split-thickness skin graft (fig. 1, *d*).

Radial Forearm Free Flap. Our techniques of RFFF phalloplasty were described previously.⁸ Briefly, standard markings were made over the forearm (fig. 2, *a*). We harvested a dermolipomatous flap, isolating the cephalic vein, antibrachial cutaneous nerves and the radial artery with its associated venae comitantes. The deep cubital vein was preserved. The urethral meatus was then matured to the distal portion of the phallus. In most patients concomitant Norfolk glansplasty was safe, given the robust blood supply to the distal portion of the flap (fig. 2, *b*).

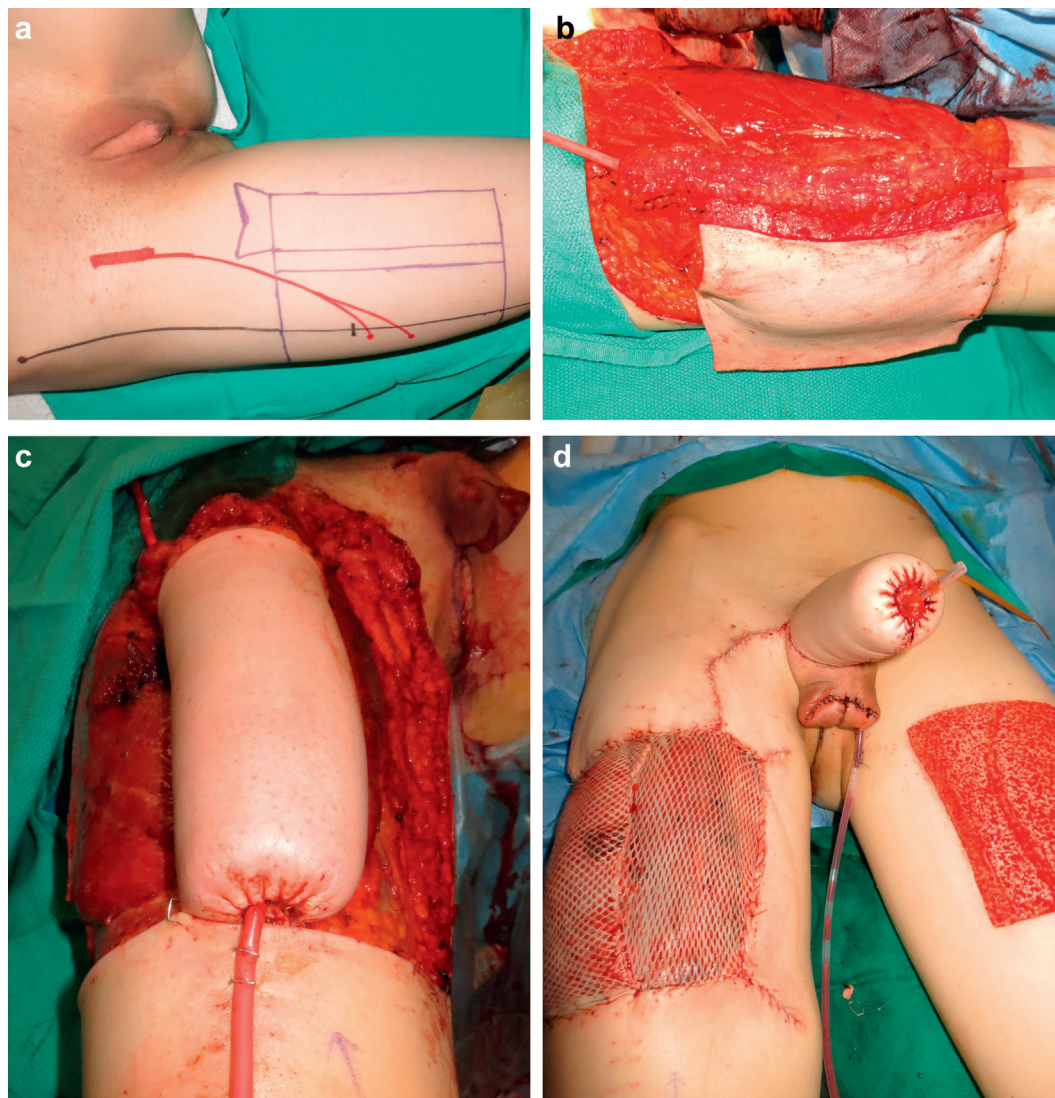


Figure 1. Pedicled anterolateral thigh phalloplasty design and outcomes. *a*, preoperative flap markings. *b*, intraoperative formation of tube in tube showing phallic neourethra rolled over urethral catheter with skin for proximal neophallic shaft seen laterally. *c*, tubularized anterolateral thigh ready to be tunneled into midline male anatomical position. *d*, immediately postoperatively with scrotoplasty and prior to suprapubic catheter placement.

Groin dissection was then performed in the contralateral groin to allow for tension-free anastomosis with arterial and venous branches of the femoral vessels and/or saphenous vein. Anastomotic urethroplasty was completed followed by coaptation of the dorsal clitoral nerve branches to the antebrachial cutaneous nerves and flap inset (fig. 2, *c* and *d*). A split-thickness skin graft from the thigh was used to cover the donor site.

Urethral Revision Procedures

In the event of urethral stricture formation urethroplasty was almost always required. Generally distal urethral strictures were addressed with first stage Johanson urethroplasty. Proximal strictures were generally short and only required scar incision or excision and primary reanastomosis. Most urethra fistulas healed spontaneously

within a 3-month period. As fistulas tended to present early, in most patients the postoperative suprapubic catheter was in place (fig. 3). We discussed with patients their tolerance of the suprapubic catheter and offered continued urinary diversion for up to 3 weeks or removal and wound care. Each option can lead to fistula closure without surgical intervention. When fistulas persisted, we performed epidermal primary closure followed by local flap coverage.

RESULTS

Patient Selection and Demographics

Included in the study were 213 patients, of whom 149 (70.0%) and 64 (30.0%) underwent RFFF and pALT

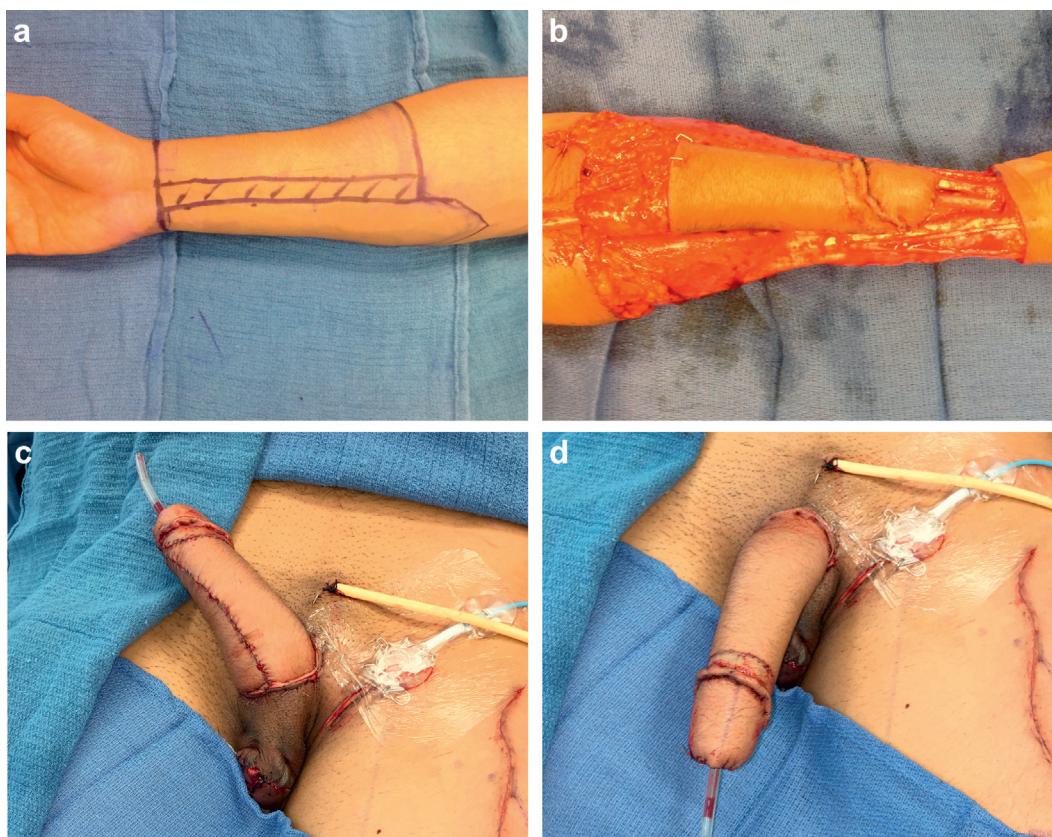


Figure 2. Radial forearm free flap phalloplasty design and outcomes. *a*, preoperative flap markings. *b*, neophallus formed by tube in tube design with glansplasty. *c* and *d*, neophallus is inset in groin after anastomosis to donor vessels and nerves. Suprapubic catheter and Foley are in place.

phalloplasty, respectively. Supplementary table 1 (<http://jurology.com/>) lists baseline demographics. Patients in the 2 groups were similar in age but those in the RFFF cohort had statistically significantly higher BMI (27.3 vs 24.0 kg/m²). Demographic data were available on a subset of patients, including smoking status in 98 (46%), medical comorbidities in 94 (44.1%) and duration of testosterone treatment in 49 (23%). Similarly among patients who were at least 1 year after surgery those in the RFFF cohort had significantly higher BMI (28.0 vs 24.0 kg/m², $p = 0.002$).

Complications

Urethral. The table compares complication rates in patients treated with pALT vs RFFF phalloplasty. In the pALT cohort urethral complications developed in 21 cases (32.8%), including 1 urethral complication in 12 and 2 or more in 9. In the RFFF phalloplasty cohort urethral complications developed in 36 cases (24.2%), including 1 urethral complication in 26 and more than 1 in 10. Figure 4 shows an OR plot of complications in the pALT vs RFFF cohorts. Patients with pALT phalloplasty had 2.50 greater odds of urethral fistula formation

(14 of 64 or 21.9% with pALT vs 15 of 149 or 10.1% with RFFF, $p = 0.024$).

Supplementary table 2 (<http://jurology.com/>) compares complication rates in patients treated with pALT vs RFFF phalloplasty who were at least 1 year after surgery. In this subset no urethral complications were significant. The supplementary figure (<http://jurology.com/>) shows an OR plot of complications in patients in the pALT and the RFFF cohorts who were at least 1 year after surgery.

Nonurethral Related. The table also lists nonurethral complication rates. Patients with pALT phalloplasty had 2.38 greater odds of nonurethral complication (15 of 64 or 23.4% vs 17 of 149 or 11.4%, $p = 0.027$). Specifically patients with pALT phalloplasty had significantly greater odds of phallus wound dehiscence (6 of 64 or 9.4% vs 3 of 149 or 2.0%, OR = 5.03, $p = 0.026$).

Supplementary table 2 (<http://jurology.com/>) shows nonurethral complication rates in patients who were at least 1 year after surgery. Patients with pALT phalloplasty had 7.07 greater odds of wound dehiscence (6 of 59 or 10.2% vs 2 of 127 or 1.6%, $p = 0.018$).

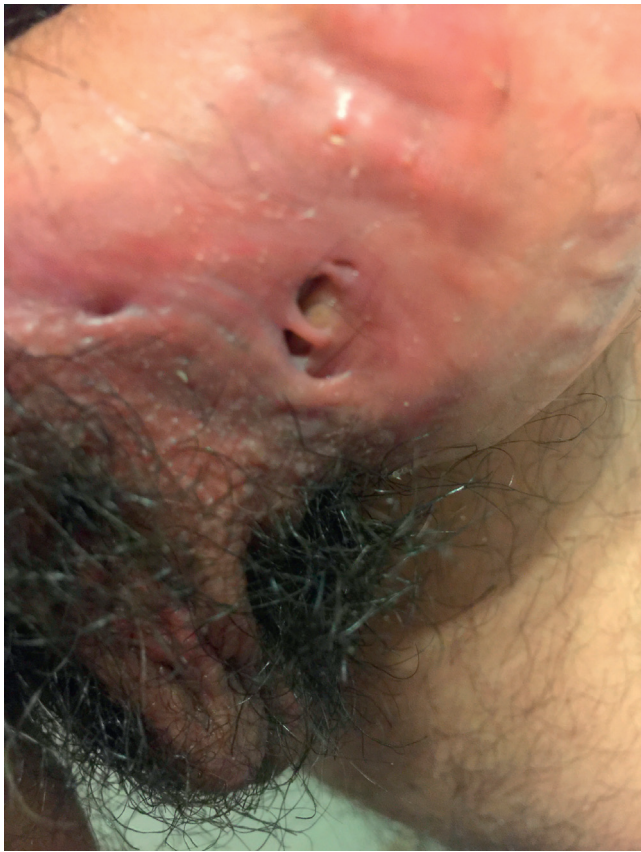

Figure 3. Urethral fistula formation 6 weeks postoperatively as complication of pedicled anterolateral thigh phalloplasty.

DISCUSSION

Phalloplasty is a viable treatment for transmale gender dysphoria. While various flaps may be used to construct a neophallus,⁷ RFFF is most commonly used.^{9,11} However, patient preference coupled with other preoperative considerations may result in the use of other flaps such as pALT. The Appendix

shows common advantages and disadvantages of pALT and RFFF for phalloplasty.

Body Mass Index

Our RFFF cohort had significantly higher BMI than the pALT cohort. As higher BMI is associated with thicker thighs, pALT phalloplasty is often precluded.¹⁷ In addition, a thick subcutaneous layer of pALT complicates tubularization,¹⁷ thereby further precluding this option for any patient desiring 1-stage phalloplasty with complete urethral lengthening.

Complications

Urethral. Urethral complications are common after phalloplasty and may prevent the patient from standing micturition.¹⁸ Techniques to reduce the incidence of urological complications after phalloplasty have been described.^{17–23} In our study the overall urethral complication rate was 32.8% in the pALT cohort and 24.2% in the RFFF cohort, consistent with prior reports.²³ We found that overall urethral complications were more common in the pALT cohort with significantly greater odds of a urethral fistula ($p = 0.024$).

Our post hoc analysis of data from a previous systematic review by Morrison et al¹⁰ showed that patients with RFFF had 1.25 greater odds of a urethral fistula than those with a pedicled or a free ALT flap ($p = 0.63$, 95% CI 0.63–2.72). However, this result may not be a reliable comparison as it was not clear how many patients with pALT in that study underwent full-length urethroplasty and they were not grouped by pedicled or free flap use. While this does not agree with our results since patients with a pALT flap had 2.50 greater odds of urethral fistula ($p = 0.024$), it is important to note that our pALT cohort of 64 patients is currently the largest

Complication rates in transmale patients treated with pedicled anterolateral thigh flap vs radial forearm free flap for phalloplasty

	Flap		OR (95% CI)	p Value
	Pedicled Anterolat Thigh	Radial Forearm Free		
No. pts	64	149	—	—
Mean \pm SD age at phalloplasty	36.2 \pm 9.7	36.7 \pm 11.5	—	0.76
No. total complications (%)	28 (43.8)	47 (31.5)	1.69 (0.92–3.1)	0.089
No. urethral complications (%):	21 (32.8)	36 (24.2)	1.53 (0.81–2.91)	0.193
Meatal stenosis	3 (4.7)	14 (9.4)	0.47 (0.13–1.7)	0.25
Urethral stricture	14 (21.9)	21 (14.1)	1.71 (0.81–3.62)	0.16
Urethral fistula	14 (21.9)	15 (10.1)	2.50 (1.13–5.55)	0.024
No. other complications (%):*	15 (23.4)	17 (11.4)	2.38 (1.1–5.12)	0.027
Rectal injury	0 (0)	1 (0.7)	Not applicable	
Partial loss	5 (7.8)	5 (3.4)	2.44 (0.68–8.74)	0.17
Hematoma	2 (3.1)	4 (2.7)	1.17 (0.21–6.55)	0.86
Dehiscence	6 (9.4)	3 (2.0)	5.03 (1.22–20.8)	0.026
Abscess	3 (4.7)	5 (3.4)	1.42 (0.33–6.11)	0.64
No sensation	1 (1.6)	2 (1.3)	1.17 (0.10–13.1)	0.90

* No scrotal complications.

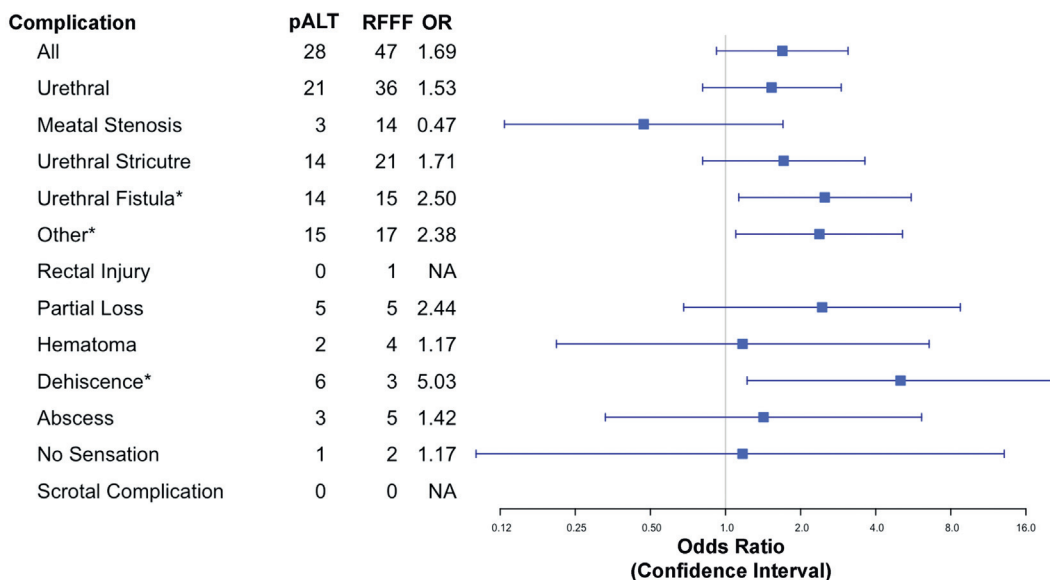


Figure 4. Outcomes of total pALT and RFFF phalloplasty. Forest plots show OR (squares) and 95% CIs (horizontal lines) of complications of pALT vs RFFF phalloplasty. Asterisks indicate statistically significant ($p < 0.05$).

on which comprehensive complications data are available.

In addition, we found that urethral fistulas were significantly more likely to develop in the pALT cohort than in the RFFF cohort. However, when we examined the subset of patients who were at least 1 year after surgery, this complication was no longer significant. This may be due to the fact that urethral fistulas tend to present earlier in the postoperative period. Therefore, excluding those patients who did not reach 1-year postoperative followup resulted in not capturing early urethral fistulas in the data analysis.

Nonurethral. Nonurethral complications can vary widely. However, we collected data on common sequelae such as rectal injury from concomitant vaginectomy, partial flap loss, hematoma, dehiscence, abscess, loss of sensation and scrotal complications. The pALT cohort had significantly greater odds of any single nonurethral complication or combination of nonurethral complications ($p = 0.027$). This is likely attributable to flap thickness and areas of possible vascular compromise with tube in tube formation as discussed.

In addition, on the 2 analyses the pALT cohort had significantly greater odds of dehiscence (see table and supplementary table 2, <http://jurology.com/>). This may be attributable to the weight of pALT, which tends to have a thicker subcutaneous layer than RFFF. For this reason the use of pALT in patients with high BMI is avoided. Consequently the tube in tube pALT phalloplasty is offered to thinner patients but this carries a greater risk of

complications than other techniques.⁷ It is also possible that pALT bulk can be reduced by raising the flap suprafascially or by partial lipectomy, of which each can place the pedicle at risk.²⁴

Notably 2 patients in the pALT cohort experienced a scrotal complication and only 1 patient who underwent RFFF phalloplasty with vaginectomy had a rectal injury. When scrotal complications are present, they involve ischemic necrosis of the distal labia majora flap ipsilateral to the groin dissection. Scrotal vascularity depends on the internal and external pudendal artery branches, of which some may be damaged significantly during groin dissection. Subsequently vascular compromise and neoscrotal skin necrosis can ensue.

Limitations

Our study is not without limitations. Followup in some patients in each group was as short as 6 months, which may be too early to detect complications. However, some complications such as urethral fistulas tend to present early. Patients may also have presented elsewhere with complications but these data were not obtainable. In addition, patient reported outcomes were not explored in this study, which limited a full discussion of the outcomes of these procedures since the patient perceived improvement in gender dysphoria is one of the primary outcomes of interest of phalloplasty.^{25,26} Complication data alone as reported only offer partial understanding of surgical procedures, especially related to gender confirming surgery.

Nevertheless since to our knowledge these findings are novel and unreported, even without patient

reported outcome data this study adds value to the currently available literature. Surgeons and providers should counsel patients accordingly that pALT phalloplasty may be considered in a select group with ideal anatomy, which includes good vasculature and minimal subdermal fat. Patients without ideal anatomy who adamantly want pALT must be prepared for potential complications and discuss staged urethroplasty with the surgeon as a potential way to avoid these complications.

Patient reported outcome metrics for RFFF vs pALT phalloplasty would be a topic of great interest for future investigation as to our knowledge there are no reliable and standardized outcome measures for the transgender population.

CONCLUSIONS

There are various surgical techniques for transmale gender confirming genital surgery. To our knowledge our study is the first to compare complication data on 2 commonly used flaps for phalloplasty in transgender patients, including the pedicled anterolateral thigh flap and the radial forearm free flap. Patients with a radial forearm free flap had fewer complications and a higher BMI than their counterparts with a pedicled anterolateral thigh flap. The latter patients were thinner but experienced more complications, especially urethra related complications. Outcomes data are needed to optimize flap selection criteria, patient satisfaction and quality of life.

APPENDIX

Advantages and disadvantages of radial forearm free flap vs pedicled anterolateral thigh flap for phalloplasty

	Pedicled Anterolateral Thigh Flap	Radial Forearm Free Flap
Advantages	Donor site scar can be well concealed Pedicled flaps do not require vascular microsurgery Color match of the anterolateral thigh to the groin Neural coaptation possible for erogenous and tactile sensation	Flap is thin and pliable, permitting tube within a tube design Long, reliable vascular pedicle Functional and aesthetic satisfaction well established Neural coaptation possible for erogenous and tactile sensation
Disadvantages	Bulkiness of large subcutaneous layer may preclude tube within a tube design Urethral complications more common Large donor defect	Large forearm scar associated with social stigma Microsurgical technique required Atrophy of phallus can occur several months postoperatively Discoloration between phallus and surrounding tissue Difficulty obtaining adequate bulk of neophallus

REFERENCES

1. Arcelus J, Bouman WP, Van Den Nofortgate W et al: Systematic review and meta-analysis of prevalence studies in transsexualism. *Eur Psychiatry* 2015; **30**: 807.
2. Conron KJ, Scott G, Stowell GS et al: Transgender health in Massachusetts: results from a household probability sample of adults. *Am J Public Health* 2012; **102**: 118.
3. Flores AR, Herman JL, Gates GJ et al: How Many Adults Identify as Transgender in the United States? Los Angeles: The Williams Institute 2016.
4. Winter S, Diamond M, Green J et al: Transgender people: health at the margins of society. *Lancet* 2016; **388**: 390.
5. Frey JD, Poudrier G, Chiodo MV et al: An update on genital reconstruction options for the female-to-male transgender patient: a review of the literature. *Plast Reconstr Surg* 2017; **139**: 728.
6. Hage JJ and De Graaf FH: Addressing the ideal requirements by free flap phalloplasty: some reflections on refinements of technique. *Microsurgery* 1993; **14**: 592.
7. Morrison SD, Shakir A, Vyas KS et al: Phalloplasty: a review of techniques and outcomes. *Plast Reconstr Surg* 2016; **138**: 594.
8. Morrison SD, Perez MG, Carter CK et al: Pre- and post-operative care with associated intra-operative techniques for phalloplasty in female-to-male patients. *Urol Nurs* 2015; **35**: 134.
9. Morrison SD, Chen ML and Crane CN: An overview of female-to-male gender-confirming surgery. *Nat Rev Urol* 2017; doi: 10.1038/nrurol.2017.64.
10. Morrison SD, Perez MG, Nedelman M et al: Current state of female-to-male gender confirming surgery. *Curr Sex Health Rep* 2015; **7**: 38.
11. Monstrey S, Hoebcke P, Selvaggi G et al: Penile reconstruction: is the radial forearm flap really the standard technique? *Plast Reconstr Surg* 2009; **124**: 510.
12. Morrison SD, Son J, Song J et al: Modification of the tube-in-tube pedicled anterolateral thigh flap for total phalloplasty: the mushroom flap. *Ann Plast Surg*, suppl., 2014; **72**: S22.
13. Sutcliffe PA, Dixon S, Akehurst RL et al: Evaluation of surgical procedures for sex reassignment: a systematic review. *J Plast Reconstr Aesthet Surg* 2009; **62**: 294.
14. Garcia MM, Christopher NA, De Luca F et al: Overall satisfaction, sexual function, and the durability of neophallus dimensions following staged female to male genital gender confirming surgery: The Institute of Urology, London U.K. experience. *Transl Androl Urol* 2014; **3**: 156.
15. Wierckx K, Van Caenegem E, Elaut E et al: Quality of life and sexual health after sex reassignment surgery in transsexual men. *J Sex Med* 2011; **8**: 3379.
16. Massie JP, Morrison SD, Wilson SC et al: Phalloplasty with urethral lengthening: addition of a vascularized bulbospongiosus flap from vaginectomy reduces post-operative urethral complications. *Plast Reconstr Surg* 2017; doi: 10.1097/PRS.0000000000003697.
17. Lee GK, Lim AF and Bird ET: A novel single-flap technique for total penile reconstruction: the pedicled anterolateral thigh flap. *Plast Reconstr Surg* 2009; **124**: 163.
18. Salgado CJ, Fein LA, Chim J et al: Prelamination of neourethra with uterine mucosa in radial forearm osteocutaneous free flap phalloplasty in the female-to-male transgender patient. *Case Rep Urol* 2016; **2016**: 8742531.
19. Zhang YF, Liu CY, Qu CY et al: Is vaginal mucosal graft the excellent substitute material for urethral reconstruction in female-to-male transsexuals? *World J Urol* 2015; **33**: 2115.

20. Schaff J and Papadopoulos NA: A new protocol for complete phalloplasty with free sensate and prelaminated osteofasciocutaneous flaps: experience in 37 patients. *Microsurgery* 2009; **29**: 413.
21. Salgado CJ, Nugent AG, Moody AM et al: Immediate pedicled gracilis flap in radial forearm flap phalloplasty for transgender male patients to reduce urinary fistula. *J Plast Reconstr Aesthet Surg* 2016; **69**: 1551.
22. Wilson SC, Stranix JT, Khurana K et al: Fasciocutaneous flap reinforcement of ventral onlay buccal mucosa grafts enables neophallus revision urethroplasty. *Ther Adv Urol* 2016; **8**: 331.
23. Doornaert M, Hoebeke P, Ceulemans P et al: Penile reconstruction with the radial forearm flap: an update. *Handchir Mikrochir Plast Chir* 2011; **43**: 208.
24. Spyriounis PK and Karmiris NI: Partial penile reconstruction following fat augmentation with anterolateral thigh perforator flap. *J Plast Reconstr Aesthet Surg* 2012; **65**: e15.
25. Frey JD, Poudrier G, Chiodo MV et al: Research disparities in female-to-male transgender genital reconstruction: the charge for high-quality data on patient reported outcome measures. *Ann Plast Surg* 2017; **78**: 241.
26. Massie JP, Morrison SD, Smith JR et al: Patient-reported outcomes in gender confirming surgery. *Plast Reconstr Surg* 2017; **140**: 236e.

EDITORIAL COMMENT

Ascha et al present a highly informative, retrospective comparison of outcomes of 1-stage phalloplasty by pALT or RFFF in gender confirming neophallus creation. Drawbacks of RFFF include donor site scarring and potential hand/forearm dysfunction. pALT avoids vascular anastomosis and has lower donor site morbidity but carries a risk of higher urethral complications. The authors determine which approach to perform with the patient based on BMI and the desire to avoid donor site morbidity. Future studies should use patient reported outcome measures¹ and seek novel ways to improve long-term followup to most accurately estimate procedure complication profiles.

These surgeries are complex with a high complication rate even in the most experienced hands.

More and more urologists will be called on to help provide care for transgender patients. General urologists must have a basic understanding of gender confirming genital surgery as they will increasingly treat transgender patients. Academic reconstructive urologists will be called on to manage short-term and long-term complications of gender confirming surgery. Fortunately many reconstructive urologists possess the skills needed to be of service to transgender patients. We must invest the time and energy to understand the complications and treatment.

Benjamin N. Breyer

*Departments of Urology, and Epidemiology and Biostatistics
University of California San Francisco
San Francisco, California*

REFERENCE

1. Breyer BN, Edwards TC, Patrick DL et al: Comprehensive qualitative assessment of urethral stricture disease: toward the development of a patient centered outcome measure. *J Urol* 2017; **198**: 1113.

REPLY BY AUTHORS

We appreciate this appraisal and agree that urologists will increasingly be called upon in the care of transgender patients. It is therefore imperative to establish best practice techniques in this advancing field. We concur that future studies investigating patient reported outcomes in gender affirming surgery are paramount. We have previously argued that patient reported outcomes should be the gold standard by which these procedures are judged (reference 26 in article).¹ A successful postoperative result has often been judged by a low complication profile. However, as reported in our study gender affirming procedures are not performed without

risk. Anecdotally despite a relatively high complication rate we experience high patient satisfaction and resolution of gender dysphoria. We echo that these are the metrics by which a successful result should be assessed.

Transgender patients have attempted suicide at a rate as high as 40%.² Therefore, gender affirming surgery has the potential to be a therapeutic and life-saving intervention, a medical necessity. We would argue that the future standard by which these procedures should be judged is resolution of gender dysphoria and patient satisfaction. Notably these metrics were lacking in our study.

However, we aim to include such metrics in all aspects of our transgender care in the future. We hope that similar efforts will be instituted

throughout the field so that we may offer the highest quality of research and care to our transgender communities.

REFERENCES

1. Morrison SD, Crowe CS, Rashidi V et al: Beyond phonosurgery: considerations for patient-reported outcomes and speech therapy in transgender vocal feminization. *Otolaryngol Head Neck Surg* 2017; **157**: 349.
2. Haas A, Rodgers PL and Herman JL: *Suicide Attempts Among Transgender and Gender Non-Conforming Adults: Findings of the National Transgender Discrimination Survey*. New York: American Foundation for Suicide Prevention and Los Angeles: The Williams Institute 2014.