Dig Dis Sci (2010) 55:548–559
DOI 10.1007/s10620-009-1108-6

REVIEW

Evaluation and Treatment of Iron Deficiency Anemia: A Gastroenterological Perspective

Amy Zhu · Marc Kaneshiro · Jonathan D. Kaunitz

Received: 10 September 2009 / Accepted: 15 December 2009 / Published online: 27 January 2010
© The Author(s) 2010. This article is published with open access at Springerlink.com

Abstract A substantial volume of the consultations requested of gastroenterologists are directed towards the evaluation of anemia. Since iron deficiency anemia often arises from bleeding gastrointestinal lesions, many of which are malignant, establishment of a firm diagnosis usually obligates an endoscopic evaluation. Although the laboratory tests used to make the diagnosis have not changed in many decades, their interpretation has, and this is possibly due to the availability of extensive testing in key populations. We provide data supporting the use of the serum ferritin as the sole useful measure of iron stores, setting the lower limit at 100 μg/l for some populations in order to increase the sensitivity of the test. Trends of the commonly obtained red cell indices, mean corpuscular volume, and the red cell distribution width can provide valuable diagnostic information. Once the diagnosis is established, upper and lower gastrointestinal endoscopy is usually indicated. Nevertheless, in many cases a gastrointestinal source is not found after routine evaluation. Additional studies, including repeat upper and lower endoscopy and often investigation of the small intestine may thus be required. Although oral iron is inexpensive and usually effective, there are many gastrointestinal conditions that warrant treatment of iron deficiency with intravenous iron.

Keywords Clinical diagnosis · Micronutrient deficiencies · Red cell indices · Ferritin

A. Zhu · M. Kaneshiro · J. D. Kaunitz
Greater Los Angeles Veterans Affairs Healthcare System, Los Angeles, CA, USA

A. Zhu · M. Kaneshiro
Cedars-Sinai—VA Residency Program, Los Angeles, CA, USA

J. D. Kaunitz
Department of Medicine, School of Medicine, University of California Los Angeles, Los Angeles, CA, USA

J. D. Kaunitz
Brentwood Biomedical Research Institute, Los Angeles, CA 90073, USA

J. D. Kaunitz (✉)
West Los Angeles VA Medical Center, Bldg. 114, Suite 217, 11301 Wilshire Blvd., Los Angeles, CA 90073, USA
e-mail: jake@ucla.edu

Introduction

Evaluation of anemia has traditionally been performed by primary care physicians, internists, and hematological specialists. Yet many practitioners now regard colonoscopy as an essential component of the anemia evaluation, to the extent that many anemia consultations are directed to gastroenterologists, often offering no more information than a complete blood count, and requesting that the specialist "rule out cancer," "diagnose anemia," or more typically, "perform colonoscopy." The recent shift of the burden of diagnosing and treating anemia to gastroenterologists, coupled with recent changes in the interpretation of traditional diagnostic testing, prompted us to review this topic with the purpose of providing gastroenterologists with an approach that should prove helpful in clinical practice. In this review, we will provide basic information about the pathogenesis, diagnosis, and treatment of iron deficiency anemia (IDA), a type of anemia of interest to gastroenterologists due to its prevalent gastrointestinal etiology and its need for endoscopic evaluation. Although this review is necessarily focused on the pathogenesis, etiology, diagnosis, and treatment of IDA, and not other

causes of anemia, recognition that anemia is not due to IDA can provide valuable information for the referring practitioner. We will provide data supporting a uniform and organized approach to the diagnosis and treatment of IDA in a likely referral population that can easily be undertaken by gastrointestinal specialists. Please note that the intent of this review is not a thorough or exhaustive coverage of IDA; in particular, specific populations, such as those receiving hemodialysis will not be discussed. The reader is also referred to a recent review addressing iron deficiency in digestive diseases [1].

Iron Deficiency Anemia

Iron deficiency anemia (IDA) affects approximately 30% of the world's population [2]. Although more prevalent in children and neonates, IDA remains extremely common in the adult population. In the United States, 5–12% of non-pregnant women and 1–5% of men have IDA [3]. The prevalence varies greatly according to age, gender, race, and ethnicity (Table 1). In premenopausal women, menstrual blood loss and pregnancy-related iron losses account for most IDA diagnoses. Nevertheless, occult bleeding from the gastrointestinal (GI) tract is the leading cause for IDA in men and postmenopausal women. A loss of 10 ml of blood per day is usually required for a positive guaiac-based fecal occult blood test (FOBT), although FOBT positivity is highly dependent on the locus of the bleeding source [4]. Bleeding lesions in the GI tract are identified in about 50% of patients with IDA [5]. GI malignancy is also significantly more common in men and postmenopausal women with IDA, with a prevalence of 10–17% [6, 7]. Factors such as older age, male sex, elevated serum lactate dehydrogenase (LDH), and lower ferritin are considered markers for GI malignancy in IDA patients [7, 8]. Predictive factors for IDA in patients with colorectal cancer include female gender, right-sided tumors, and a tumor diameter > 3 cm [9].

About one-third of the patients with inflammatory bowel disease (IBD) are anemic [2]. Although anemia in IBD often involves a combination of IDA and the anemia of chronic disease (ACD), IDA remains an important contributor via: (1) decreased iron intake due to avoidance of foods that may exacerbate symptoms of IBD; (2) chronic intestinal bleeding; (3) impaired iron absorption in Crohn's disease of the duodenum or upper jejunum; and (4) increased erythropoietin response that cannot be matched to the available iron, resulting in ineffective erythropoiesis [2].

Therefore, an evaluation of the GI tract should be part of a thorough diagnostic assessment in adults with IDA. Although particular attention should be given to adult men and postmenopausal women [4], premenopausal women and young patients with IDA may also provide unique diagnostic challenges.

Table 1 Prevalence of IDA in the United States (adapted from the Centers for Disease Control and Prevention)

Group/age	1988–1994 (%)	1999–2000 (%)
Children		
1–2	9	7
3–5	3	5
6–11	2	4
Women (non-pregnant)		
12–49	11	12
50–69	5	9
70	7	6
Men		
12–15	1	5
16–69	1	2
70	4	3
Women by racial/ethnic group		
Non-Hispanic white	8	10
Black	15	19
Mexican living in U.S.	19	22

Iron deficiency—United States, 1999–2000. *MMWR Morb Mortal Wkly Rep*. 2002;51:897–899

Iron Absorption and Metabolism

Gastrointestinal Iron Absorption

Dietary iron consists of about 5–15 mg of elemental iron and 1–5 mg of heme iron, of which about 1–2 mg is intestinally absorbed. Children, adult males, and postmenopausal women require 10 mg of elemental iron daily. In premenopausal and pregnant women, the requirement increases by two to three fold [10]. The mechanism of heme iron absorption is unknown. Inorganic iron may be absorbed via the divalent metal transporter-1 (DMT-1), a protein that transports a number of divalent metals, including ferrous iron (Fe^{2+}). Nevertheless, dietary iron in the duodenum, particularly from plant sources is likely ferric iron (Fe^{3+}); therefore a membrane cytochrome containing ferrireductase is necessary to reduce (Fe[III]) to (Fe[II]). DMT-1 is principally expressed in the enterocyte cytoplasm and lamina propria, but is also expressed in goblet cells and in the overlying mucous layer [11]. DMT-1 is inserted into the brush border membrane with overall increased expression in IDA; inorganic iron is also taken up by the integrin-mobilferrin-paraferritin (IMP) pathway. Once transported across the duodenal luminal membrane, iron is carried across the cytoplasm by a carrier protein and is bound by transferrin at the basolateral membrane. Iron is

released from the intestinal mucosa via hephaestin, a ceruloplasmin-like ferro-oxidase, and ferroportin, another transport protein [12]. Both DMT-1 and ferroportin are regulated by the hepatically secreted defensin hepcidin, which impairs transduodenal iron transport (see below).

Sources of Iron Loss

GI Blood Loss

Under usual circumstances, in the absence of occult bleeding, the predominant source of iron loss is in the iron-containing cytochromes of sloughed epithelial cells, which account for a loss of ~1 mg/day. GI tract microerosions and other forms of occult blood loss can account for 1–2 mg of iron loss daily. In the plasma, iron is usually bound by transferrin and is taken up by tissues expressing cell-surface transferrin receptors. Circulating iron is mostly taken up by the bone marrow in order to generate hemoglobin for red blood cells, whereas 10–15% is taken up by muscle fibers to generate myoglobin. After a half-life of 120 days, senescent RBCs are engulfed by reticuloendothelial macrophages; iron is recycled into the plasma for redistribution to other tissues via transferrin. Intracellularly, iron is stored as ferritin, particularly in the hepatic reticuloendothelial macrophages and in hepatocytes. Ferritin is measurable in plasma, where it correlates closely with bone marrow stores in the steady state [13, 14]. Ferritin is elevated in inflammatory disease states since it is an acute-phase reactant [15–17]. There are also a number of iron responsive element binding proteins that regulate the balance of iron. Hepcidin inhibits the release of iron into the plasma from enterocytes, hepatocytes, and macrophages when the plasma level of iron is increased [18].

Iron Malabsorption or Deficient Diet

In rare situations, IDA can occur in the absence of chronic GI blood loss. Celiac disease, although mostly associated with diarrhea and malabsorption, can also manifest extra-intestinal symptoms such as dermatitis, arthritis, and immunologic problems. In one study, IDA was the clinical presentation of 28% of subjects with "silent" (only extra-intestinal symptoms) celiac disease [19], presumably due to duodenal involvement with iron malabsorption. Hypochlorhydric states, such as atrophic gastritis due to chronic infection with *Helicobacter pylori* or autoimmune gastritis, or in rare cases, chronic, high-dose therapy with proton pump inhibitors have been implicated in the pathogenesis of IDA [20–24]. Since the duodenum is the major locus of iron absorption, surgical duodenal bypass, formerly for peptic ulcer disease, and more recently as part of gastric bypass for obesity, have also been associated with the development of IDA [25, 26]. An acute loss of 4 units or more (2 l) of blood can deplete iron stores. Lastly, the consumption of an iron-deficient diet, such as occurs in strict vegans, can deplete iron stores if the diet is adhered to for three or more years in the absence of excessive losses [10].

Non-GI Sources of Chronic Occult Blood Loss

Although it is possible to lose blood from the airway and urinary system, the loss is seldom occult, and thus comes to medical attention prior to the development of IDA. An exception can be tumors or lesions of the urothelium, which can bleed occultly prior to producing symptoms, or more rarely, chronic intravascular hemolysis, in which hemoglobin is released from damaged red cells into the plasma, where it is excreted in the urine, detectable as hemosiderin in the urine sediment.

Signs and Symptoms

Patients with mild IDA are most likely asymptomatic. When the anemia becomes more severe, patients may present with nonspecific symptoms such as fatigue, pallor, and dyspnea on exertion. Physical examination may reveal tachycardia, generalized and conjunctival pallor, koilonychia, glossitis, stomatitis, and findings consistent with heart failure. Behavioral changes such as pica (the craving and consumption of nonfood items) and restless leg syndrome may also be present [27, 28]. Patients with GI causes of IDA may occasionally complain of "alarm" symptoms such as a change in stool caliber, epigastric pain, and change in bowel habits, weight loss, early satiety, and poor appetite. Esophageal webs associated with IDA comprise the Plummer–Vinson syndrome.

Laboratory Diagnosis

Red Cell Indices, Serum Iron, and Iron Binding Capacity

Iron deficiency is usually diagnosed with laboratory tests. Low serum hemoglobin in the setting of a reduced mean corpuscular volume (MCV) is usually the initial finding on a routine complete blood count. Red cell distribution width (RDW) has been proposed as a sensitive indicator for IDA. Increased RDW represents heterogeneity in the red blood cell volume distribution, equivalent to anisocytosis observed in a peripheral blood smear. A significant increase in mean RDW can be used to diagnose IDA (sensitivity 81.0%, specificity 53.4%) [29]. An inverse relationship is also observed between the serum hemoglobin and the RDW in IDA [29]. Although the absolute values of red cell indices

may vary and be confounded by coincident diseases such as heterozygous thalassemia syndromes, the trend of RDW and MCV over time can be quite instructive [3]. Iron deficiency usually initially manifests as a falling MCV accompanied by a rising RDW, due to the increasing preponderance of microcytes in the circulation [30–32]. With iron treatment, the marked reticulocytosis occurring in the first 4 weeks following therapy is manifest as a sudden increase of RDW, sometimes to over 30% [33]. Thus a pattern of falling MCV accompanied by a rising RDW should alert the clinician to the presence of possible IDA. The marked RDW increase occurring after the initiation of therapy helps confirm the diagnosis (Fig. 1).

Additional laboratory findings in IDA include elevated total iron-binding capacity (TIBC), low transferrin saturation, and low serum iron level. Due to the large overlap of transferrin saturation among subjects with IDA, ACD, and those with a mixed diagnosis, the use of transferrin saturation in the diagnosis of IDA has been discouraged [15, 34].

Serum Ferritin

Serum ferritin is the single best laboratory test for the diagnosis of iron deficiency. In patients with bleeding colorectal adenomas ≥1 cm, serum ferritin may decrease before a decrease in the serum iron level is detected [35]. Every 1 μg/l of serum ferritin corresponds to 8–10 mg storage of iron [13]. Based on a review of multiple clinical trials where the diagnosis of IDA was confirmed by bone marrow aspiration or a positive response to exogenous iron administration, Guyatt et al. [15] calculated that the predictive value or area under the receiver operating characteristic (ROC) curve for serum ferritin is 0.95 ($p < 0.001$), compared to 0.77 for MCV, 0.74 for transferrin saturation, and 0.62 for absolute RDW. The likelihood ratio (LR), which incorporates sensitivity and specificity into calculating how much the odds of the disease increase when a test is positive, provides a convenient means of ascribing probability of disease according to a laboratory value (Table 2) [15]. Kis et al. [34] in a retrospective study of 101 veterans who had undergone bone marrow aspirations, also found that the ROC for ferritin was superior to TIBC or to transferrin saturation, calculating that a ferritin of ≤100 μg/l had a 64.9% sensitivity and a 96.1% specificity for IDA. In another study, Sawhney et al. [36] reported that a threshold of 100 μg/l effectively stratified anemic veterans into a high-risk group for advanced neoplasia from a low-risk non-anemic group. Based on these data, a simple clinical cutoff can guide management of anemic subjects: serum ferritin <15 μg/l rules in iron deficiency, serum ferritin >100 μg/l mostly excludes iron deficiency; intermediate values warrant further investigation [15]. Although ferritin level increases with age, and is an acute-phase reactant that may be falsely elevated in the setting of chronic inflammation, infection, malignancy and chronic renal failure, the sensitivity and specificity of the serum ferritin is little changed if the 100 μg/l threshold is used [15, 34]. Thus, a lower limit of normal of 100 μg/l for ferritin might serve as a simple diagnostic test to effectively stratify patients for endoscopic evaluation, including subjects that might have been uninvestigated according to more stringent thresholds. Although this higher range will lead to the investigation of more false-positives, most subjects will be over 50 years old in any case and thus eligible for screening colonoscopy, perhaps justifying the excess risk.

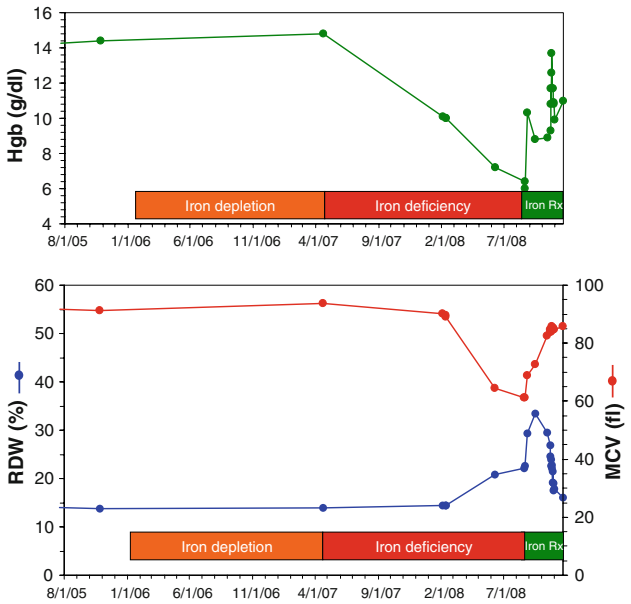

Fig. 1 Red cell indices and Hgb over time in a patient with severe iron deficiency anemia prior to and after successful treatment. Note the fall of MCV accompanied by a rise of RDW as the deficiency progressed, with marked increase of RDW immediately following the institution of therapy

Table 2 Likelihood ratios (LR) and confidence interval (CI) for the presence of IDA stratified by serum ferritin (adapted from [15])

Serum ferritin	LR	95% CI
≥100 μg/l	0.08	0.07–0.09
45 < 100 μg/l	0.54	0.48–0.60
35 < 45 μg/l	1.83	1.47–2.19
25 < 35 μg/l	2.54	2.11–2.97
15 < 25 μg/l	8.83	7.22–10.44
≤15 μg/l	51.85	41.53–62.27

Investigational Tests

Several other indices of iron deficiency have been under investigation. The following are a few highlights from recent studies.

Serum Transferrin Receptors

Similar to serum ferritin, serum transferrin receptors (sTFR) may be used to estimate body iron stores [3]. sTFR is a transmembrane glycoprotein that transfers circulating iron into RBCs. In IDA, sTFR is expressed on erythrocyte membranes, enabling the detection of the receptor soluble extracellular domain in the circulation. sTFR is dependent on erythroid precursors in the bone marrow and on the number of sTFRs per cell. Although the sTFR is sensitive and is not affected by inflammation, it is not widely available. Furthermore, the assay is not standardized, which impedes its clinical application [17, 37].

Erythrocyte Zinc Protoporphyrin

The erythrocyte zinc protoporphyrin assay (ZnPP) is another laboratory screening method used to assess iron status. In IDA, DMT-1 is upregulated, which increases zinc transport across the intestinal membrane to replace the missing iron in the formation of the protoporphyrin ring [38]. ZnPP assay is a sensitive test, but specificity may be limited because ZnPP increases in the settings of inflammation, lead poisoning, ACD, and hemoglobinopathies [37].

Reticulocyte Hemoglobin Content

The reticulocyte hemoglobin content (CHr) reflects the amount of iron available to the bone marrow for incorporation into new RBCs since reticulocytes are only 1–2 days old. The sensitivity and specificity of this test are comparable to those of serum ferritin [17]. Based on the same concept, another marker of iron status is the percentage of hypochromic RBC's (PHRC). PHRC tests the concentration of hemoglobin in RBCs rather than the hemoglobin content, as in CHr. Nevertheless, the test's utility is in question since PHRC is dependent on the size of the RBCs, which may vary with the length of storage time, and therefore cannot be shipped to off-site laboratories [17]. These tests are particularly useful in the diagnosis of iron deficiency in the presence of inflammation and ACD [39].

When the diagnosis remains ambiguous after laboratory results are analyzed, a bone marrow biopsy should be considered in order to make a definitive diagnosis. The absence of stainable iron is the 'gold standard' for diagnosis of IDA.

Further Testing for Anemia Other Than IDA

In addition to IDA, other causes of microcytic, hypochromic anemia to consider are thalassemias, ACD, and sideroblastic anemia. Evaluation for thalassemia or other hemaglobinopathies should be considered in those with a family history or are from high-risk populations, particularly with origins from the Mediterranean basin or Southeast Asia [40]. In comparison, red blood cell production is usually low in IDA, but normal to high in thalassemias. Sideroblastic anemia is diagnosed by visualizing ringed sideroblasts in Prussian blue-stained bone marrow.

Gastrointestinal Evaluation

FOBT

An FOBT is routinely used in detecting blood loss from the GI tract. As mentioned earlier, a loss of 10 ml/day is usually required for the majority of FOBT to become positive; 30 ml/day was associated with 93% positivity [41]. The routine use of FOBT for diagnosing IDA, however, can be questioned due to the markedly poor ROC of the test [42, 43]. Nevertheless, FOBT may be useful for risk-stratifying premenopausal subjects with IDA (see below). In general, IDA should be diagnosed by serum ferritin studies combined with the trend of the red cell indices. Using tests of stool hemoglobin in the diagnosis of IDA is discouraged in subjects aged >50 years as the tests, whether negative or positive, are unlikely to change the need for endoscopic or other evaluation of the GI tract.

GI Tract Evaluation

Lower and upper GI tract evaluation is recommended to diagnose the cause of IDA, particularly in men ≥50 and in post-menopausal women, in whom IDA is suspected to occur from a bleeding lesion.

Premenopausal Women

Since premenopausal women comprise the largest category of IDA subjects, the gastroenterologist frequently encounters constituents from this group with suspected gastrointestinal blood loss. Since physiological blood loss is greater in this group than any other, and since there are relatively few controlled studies investigating the etiology of IDA in this population, the indications for gastrointestinal

evaluation can be problematic. Although IDA in most premenopausal women can be attributed to menstrual blood loss and insufficient dietary intake [3], a substantial portion harbor significant underlying gastrointestinal tract lesions, particularly of the upper tract [44–46]. The average age of menopause is 51 years, and since premenopausal patients with IDA near or even surpass this age, their risk for colorectal malignancy increases accordingly. If menstrual blood loss is significant and appears to be the primary source of IDA, then gynecologic evaluation and management should be priority. Gastrointestinal tract evaluation should be pursued in those who have anemia that is severe or remains refractory to iron treatment, have significant gastrointestinal symptoms, weight loss, positive fecal occult blood testing, are >40 years of age, or those whose menstrual blood loss does not correlate with the severity of their IDA [45, 46]. Green and Rockey reported that in 111 women referred to GI specialists for IDA, use of aspirin (ASA) or nonsteroidal anti-inflammatory drugs (NSAIDs) and upper GI symptoms were associated with upper lesions whereas weight loss $\geq$ 10 lb., FOBT positivity and lower GI symptoms were more associated with lower lesions. In a study of 186 premenopausal women referred for gastroenterological evaluation, Hgb $<$ 10, FOBT positivity, abdominal symptoms, and weight loss $\geq$5 kg were predictive of the presence of gastrointestinal lesions. The authors reported finding five gastric and six colon cancers in this referral group but no intestinal lesions were identified with conventional small intestinal radiography performed on the 166 subjects in which no upper or lower lesion was identified [46]. In a study of 166 pre-menopausal women referred for gastrointestinal evaluation, the symptoms of heartburn and regurgitation, Hgb $<$ 10, and MCV $<$ 72 were significant positive predictors for significant GI lesions, whereas a history of meno-metrorrhagia was a significant negative predictor. Of the 35 women with GI lesions, 47% were diagnosed with *H. pylori* (Hp) gastritis and 17% with celiac disease, with the authors recommending routine use of the urea breath test and celiac serologies in their population, with endoscopic evaluation reserved only for those who test negative for Hp or celiac disease or whose IDA fails to resolve after Hp eradication [47]. Nevertheless, an upper endoscopy should be considered in those with predictive symptoms, or with suspected Hp gastritis or celiac disease so that confirmatory histology can be obtained and other lesions excluded.

Due to the relatively few studies published about the gastrointestinal etiology of IDA in the pre-menopausal population, combined with a study design that for most is heavily biased towards a referral population, guidelines based on grade A evidence regarding the gastrointestinal evaluation of this population are lacking. Nevertheless, agreement among the published studies is sufficient to guide clinical decision-making, with the main principle that GI lesions are frequent and malignancies are present in this population; the threshold for endoscopic investigation should thus be low.

Types of Tests Available

GI evaluation can be endoscopic and radiographic. Endoscopic tests include esophagogastroduodenoscopy (EGD), colonoscopy, enteroscopy, and wireless capsule endoscopy (WCE), whereas radiographic tests include barium enema, upper GI series with or without small-bowel follow-through, enteroclysis, abdominal computer tomography (CT), and CT colonography. The choice of study is largely dependent on the clinician's experience, test availability, the patient's comorbidities, and the type and location of the suspected lesion.

GI Tract Lesions

Although IDA has historically been associated with lesions in the colon, upper GI tract lesions are also commonly found in patients with IDA [4, 48]. Cancer is the most common lesion found in the colon, whereas peptic ulcer is the most common lesion identified in the upper GI tract [48]. A list of the upper and lower GI bleeding conditions associated with IDA is included in Table 3. As previously discussed, the existence of non-bleeding sources of IDA, including celiac disease, prior gastric surgery, and chronic atrophic gastritis from *Hp* infection or autoimmune gastritis can compromise iron absorption. Therefore, upper endoscopic evaluation should include random gastric antral and fundic biopsies in addition to duodenal biopsies in order to assess the histological changes of atrophic gastritis and celiac disease [49]. Celiac disease must be considered as a cause for IDA particularly in the younger population, in particular populations with Northern European ancestry, and as previously noted can present with or without overt GI symptoms [50]. Some authors advocate serologic and biochemical screening when clinical suspicion for celiac disease and atrophic gastritis is high or in otherwise unexplained IDA, especially in light of a reported prevalence of celiac disease in IDA of 3–15% and atrophic gastritis of 20–27% [20, 21, 50, 51]. GI investigation in elderly patients with iron deficiency or depletion, irrespective of hemoglobin level, is recommended since a similar prevalence of GI lesions was observed in iron-depleted or deficient patients without anemia as in those with anemia [52]. Conversely, the likelihood of bleeding GI lesions is low in anemic patients without iron deficiency. These patients should probably not undergo diagnostic investigation of the GI tract for this indication [5],

Table 3 Pathological conditions of the GI tract associated with iron deficiency (adapted and modified from [3, 4, 22])

Upper GI tract only	Lower GI tract only	Either or both
Gastric ulcer	Colonic adenoma	Crohn's disease
Duodenal ulcer	Colonic carcinoma	Vascular ectasia
Gastric carcinoma	Ulcerative colitis	Portal hypertensive gastropathy or colopathy
Watermelon stomach	Idiopathic cecal ulcer	Parasitic infections (hookworm, whipworm, amebiasis, etc.)
Dieulafoy's ulcer		
Hiatal hernia		Nonsteroidal anti- inflammatory drug gastropathy or enteropathy
Erosive esophagitis		
Erosive gastritis		
Celiac disease		
Atrophic gastritis		
Helicobacter pylori chronic gastritis		
Gastric surgery		

although as discussed above, the risk of cancer or of advanced neoplasia may be higher in anemic subjects with ferritin >30 and <100 μg/l [36].

Obscure Lesions

About 5–10% of patients with anemia from suspected gastrointestinal origin have no source found after EGD and colonoscopy are performed [53]. A possible explanation to consider is a missed lesion, since up to 25% of patients with initially negative studies have upper tract lesions when EGD is repeated. Some unusual and difficult-to-recognize lesions in the upper tract include Cameron lesions in hiatal hernias, watermelon stomach, portal hypertensive gastropathy, and vascular ectasias. Important lesions can also be missed with colonoscopy, particularly when bowel preparation is poor for the initial exam [4].

Moreover, a small-bowel lesion is detected in approximately 75% of patients with a negative EGD and colonoscopy after further investigation [54]. As recommended by the American Gastroenterological Association (AGA), patients who have persistent or recurrent IDA after negative EGD and colonoscopy should undergo small-bowel evaluation.

In the setting of IDA that exists with obscure GI bleeding, there are numerous options to consider for further evaluation. Radiographic techniques include barium studies, such as small-bowel follow-through and enteroclysis; nuclear studies, such as tagged red blood cell scans and Meckel's scan; computed tomography (CT) and magnetic resonance imaging with enteroclysis; and angiography. Endoscopic techniques include repeating EGD and colonoscopy, push enteroscopy, double-balloon enteroscopy (DBE), and WCE. Surgical procedures include exploratory laparotomy with and without intraoperative enteroscopy [53].

The most recent AGA technical review addressing obscure GI bleeding in 2007 suggests that WCE is the preferred method of small-bowel evaluation due to the length of the small bowel examined, the quality of the examination, and its non-invasiveness. The relative utility of small-bowel follow-through and enteroclysis has significantly declined due to their lower diagnostic yield; at present they are not indicated in the absence of signs of small-bowel obstruction [55]. Similarly, tagged red blood cell scans and angiography are of low yield unless the patient is rapidly bleeding. In the setting of IDA, WCE is diagnostically superior to small-bowel X-ray series and push enteroscopy; WCE identifies sources of bleeding in the small bowel twice as frequently as does push enteroscopy [55]. WCE has a higher diagnostic yield than does DBE, although DBE remains useful in that it is often complementary especially when performed after WCE identifies areas that require treatment or biopsy [1]. When comparing WCE to the 'gold standard' of intraoperative endoscopy, the calculated sensitivity was 95%, specificity 75%, and positive and negative predictive values were 95 and 86% respectively [53].

Major disadvantages of WCE include the inability to perform biopsy or therapy and the risk of a retained capsule, which may necessitate surgical exploration. Other limitations include the inability to wash or repeatedly examine lesions, the confounding effect of intraluminal bile which can be mistaken for blood, and the current lack of backing by insurance companies. WCE is generally contraindicated in the presence of small intestinal strictures/obstruction and pregnancy. Although thought to interfere with implanted cardiac pacemakers, no reports to date support this contention.

In patients with IDA, WCE identified small-bowel erosions, ulcerations, and angiodysplasia most frequently. Active bleeding in the small intestine without any

identifiable lesion was observed in 11% of patients, classifying this finding as a major causative factor for IDA with or without signs of obscure GI bleeding [56]. The diagnostic yield for WCE increases with advancing age, likely secondary to the increased use of NSAIDs, ASA, and warfarin.

The etiologies of obscure GI bleeding that may cause IDA vary with age. Likely sources in patients younger than 40 include small-intestinal tumors (i.e., lymphomas, carcinoid tumors, adenocarcinomas, and polyps from hereditary polyposis syndromes), Meckel's diverticulum, Dieulafoy's lesion, and Crohn's disease. Patients older than 40 are more likely to have vascular lesions, which account for 40% of all causes, and NSAID-induced small-intestinal disease. Less common causes include hemobilia in patients who have undergone liver biopsy, have been exposed to trauma, or have hepatocellular cancer, hemosuccus pancreaticus in patients with necrotizing pancreatitis or have undergone pancreatic transplantation, and aortoenteric fistula in patients with prior abdominal aortic aneurysm repair [53].

Anemia in IBD patients is often secondary to a combination of IDA and ACD. The utility of performing upper endoscopy in adult patients with IBD presumed to be distally confined has not been studied, however pediatric data suggests that it is useful in differentiating Crohn's disease from ulcerative colitis [57] and therefore may be helpful in the investigation of IDA in adults with IBD as well.

In many patients, after appropriate GI evaluation is performed, the cause of IDA is still not identified. As previously mentioned, other explanations to consider include non-GI blood loss, misdiagnosis of anemia type, missed lesions and nutritional deficiency [4]. If patients do not have significant anemia or clinical symptoms, a reasonable approach would be to follow patients clinically, start iron treatment, and stop the use of any potentially offending medications such as NSAIDs or ASA if possible. Patients who do not respond to iron supplementation, have severe anemia, or suspected serious illness, will likely require continued GI evaluation including repeat endoscopic and serologic tests [1].

When to Get Help

There are no known guidelines for when to seek hematologic referral for further evaluation of IDA. Nevertheless, in the setting of continued IDA of unknown source that is severe or refractory to treatment, or in anemia that appears to be multifactorial, it is reasonable to seek assistance from a hematologist. As previously mentioned, in addition to IDA, other etiologies to consider in the differential diagnosis of microcytic, hypochromic anemias include ACD, thalassemia, and sideroblastic anemia.

Treatment

Treatment of iron deficiency should begin with dietary replacement (i.e., fortified cereals and breads, red meat, beans, green leafy vegetables), but when diet alone is inadequate to restore iron stores and Hgb to normal levels, or when anemia is severe, treatment with exogenous iron supplements should be implemented. Treatment is dependent on the urgency of the situation and the patient's presenting symptoms. If serum hemoglobin is < 8 g/dl and the patient is symptomatic with shortness of breath, extreme fatigue, or signs of myocardial ischemia, then an immediate blood transfusion is warranted. When the patient is asymptomatic and the hemoglobin level is within an acceptable range, treatment should begin with oral iron.

Oral Iron

As the first-line treatment for IDA, oral iron is safe, cost-effective, and convenient. Ferrous sulfate and ferrous gluconate are the two preferred oral preparations of iron, given the low cost and good bioavailability of elemental iron. To optimize iron absorption, ferrous salts should be taken with orange juice, since iron is better absorbed in an acidic environment. Furthermore, ascorbic acid reduces the oxidation of ferrous to ferric iron. Foods that reduce iron absorption include tea, coffee, phosphate-containing carbonated beverages, and medications that block gastric acid secretion (i.e., antacids, H_2 blockers, proton pump inhibitors). Ferrous sulfate is typically taken in 300-mg tablets (60 mg elemental iron); ferrous gluconate is taken in 320-mg tablets (36 mg elemental iron) three to four times daily. Common adverse effects of oral iron supplements include nausea, epigastric discomfort, and constipation, all of which are dose-related. Adverse effects can occur in up to 20% of patients, impairing compliance [10]. Since the duodenum can maximally absorb 10–20 mg of iron daily, >90% of ingested iron is not absorbed, where it can produce erosions and enteric siderosis [58, 59]. Successful iron repletion is possible with lower doses such as 15 mg elemental iron/day [60–62]. Enteric-coated iron tablets are better tolerated but are less effective because the iron may not be released in the duodenum, where it is primarily absorbed [10, 11]. The therapeutic goal of oral iron therapy is to induce reticulocytosis within days and raise serum hemoglobin by 1–2 g/dl every 2 weeks, ultimately restoring iron stores in approximately 3–4 months [3, 12]. In light of the foregoing considerations, decreasing the dose of oral iron preparations if adverse effects develop should be tried; if reticulocytes or RDW increase within 4 weeks, the dose is probably adequate.

Intravenous Iron

Indications

When the patient fails oral iron therapy, parenteral iron therapy is indicated [63]. Indications for parenteral iron therapy in GI disease include: (1) high iron requirements due to chronic uncorrectable bleeding or chronic hemodialysis; (2) iron malabsorption secondary to a GI condition (i.e., celiac disease, atrophic gastritis, gastric bypass); (3) IBD with ineffective erythropoiesis, poor absorption, and intolerance (also see below); (4) severe anemia with unwillingness to receive transfusions; (5) intolerance of or noncompliance with oral therapy; (6) need for rapid restitution of iron stores (e.g., pre-operative) [2, 3, 64, 65], although some suggest that in the case of celiac disease, institution of a gluten-free diet is curative over 6–12 months [66], and (7) possibly in restless legs and related syndromes [27]. Note that parenteral iron sucrose therapy is currently restricted by the US FDA to renal failure patients either undergoing dialysis or pre-dialysis who are receiving concurrent epoeitin therapy.

Preparations

Intravenous iron preparations are available as ferric gluconate, iron sucrose, iron dextran, and ferric carboxymaltose. Ferric gluconate (Ferrlecit) is effective in treating IDA patients on hemodialysis and IDA patients without renal disease [3]. For those who develop hypersensitivity reactions to ferric gluconate, iron sucrose (Venofer) may be given [3, 67]. Doses of iron sucrose for patients on hemodialysis are adjusted lower [67]. Also, iron sucrose appears to be a safe and effective alternative form of treatment that is able to rapidly restore iron stores in pregnant and postpartum women with IDA [68–70]. Iron dextran (INFeD, DexFerrum), unlike ferric gluconate and iron sucrose, is higher in molecular weight and releases iron more slowly to be bound by transferrin and to supply the bone marrow. Because of these properties, it has historically had the advantage of being able to be administered in large doses (200–500 mg), satisfying the patient's total iron requirement with just one administration (total-dose infusion), thereby saving cost and improving patient compliance. Nevertheless, a smaller test dose is currently recommended due to reports of severe anaphylactic reactions in addition to adverse effects such as hypotension, myalgia, arthralgia, nausea, vomiting, and fever. Therefore, iron dextran is rarely used as it is contraindicated in the pediatric population and discouraged in adults [71]. A newly suggested alternative to total-dose iron dextran administration may be giving total-dose or high-dose iron sucrose infusions that are equally effective and associated with fewer toxicities [72–74].

Ferric carboxymaltose (Ferinject R) is a novel intravenous iron preparation that can be administered in high single doses (of up to 1,000 mg iron per week) on a weekly basis at infusions rates much higher than for iron sucrose. To date, phase III studies support its safety and efficacy in diverse patient populations, including IBD patients with iron deficiency anemia [75].

Considerations for IBD Patients

Anemia in IBD has received particular attention due to the importance of the disease combined with its high prevalence of anemia [76]; routine monitoring with complete blood counts is an integral part of management that is often overlooked. Correcting anemia improves the quality of life in anemic patients, with normalization of hemoglobin and ferritin being the treatment goals.

The efficacy of oral iron therapy in IBD patients may be hindered by gastrointestinal side-effects, reduced absorption in the setting of inflammation, and altered distribution. Also, due to the presence of pre-existing mucosal injury, unabsorbed luminal iron, perhaps due to its strong oxidizing properties, may exacerbate the inflammatory lesions of IBD, whereas intravenous iron therapy may suppress inflammation in Crohn's disease [58, 59, 77–80]. In a controlled trial, the dose of oral iron was either reduced or discontinued in 52% of subjects due to gastrointestinal effects [81], although oral ferrous sulfate was well tolerated and as effective as intravenous iron after 12 weeks in another trial [75]. Given the efficacy and toleration of intravenous iron in IBD, and the impaired quality of life and cognitive function in anemic patients with IBD [82], the use of intravenous iron in anemic patients with IBD with either severe anemia (Hgb < 10), or intolerance or non-response to oral iron [77] has been advocated; an IBD working group recommended IV iron therapy for *all* IBD patients with IDA [83]. Please also refer to a separate recent review of this area [84].

Recombinant Human Erythropoietin

Recombinant human erythropoietin (EPO) is most commonly used for and FDA indicated for the treatment of ACD in patients with chronic renal failure. These patients are supplemented with IV iron in order to compensate for the functional iron deficiency that is caused by increased erythropoiesis [85]. In the setting of GI-related IDA, however, EPO may be indicated in several situations. In patients with GI cancer where IDA is common, inappropriate low levels of endogenous

Table 4 Pharmacological properties of parenteral iron products (adapted from [89])

	Iron dextran	Iron sucrose	Ferric gluconate
Bioavailability	+	++	++
$t_{1/2}$ (h)	6	5–6	1
Clearance (1,000-mg dose)	10–20 mg/h[a]	Unknown	Unknown
Volume of distribution (l)	Not reported	7.9	6
Dialyzed	Negligible	Negligible	Negligible
Safety profile	+	++	++
Pregnancy category (FDA)	C	B	B

[a] Cleared by the reticuloendothelial system

erythropoietin may also be present [86]. Therefore, giving cancer patients EPO together with IV iron supplementation for at least 14 days before an operation reduces the need for perioperative autologous blood transfusions [86, 87]. The synergistic effect of the combination therapy, however, appears to be limited to IV rather than oral iron preparations [86, 87].

Patients with IBD also have faster and larger hemoglobin increases when they are concomitantly started on EPO once restoration of their iron stores is achieved [2]. Erythropoiesis is decreased from IBD-associated inflammation as well as from some of the anti-inflammatory treatments of IBD. Erythropoietin therapy should be used for IBD patients who are unresponsive to intravenous iron and always used in combination with intravenous iron replacement [77, 83]. Since many gastroenterologists are unfamiliar with the use of EPO, we recommend that the drug be given, at least initially, under the supervision of a hematologist or nephrologist experienced in its use. This subject has also been reviewed separately [88].

In addition to iron replacement with or without EPO, patients should be managed according to the specific underlying cause of IDA. Mass lesions in the GI tract may require surgical intervention, whereas disorders such as gastritis, peptic ulcers, or IBD may be managed medically [4]. Vascular ectasias may be endoscopically managed via thermal-based treatment or medically managed via hormonal compounds or octreotide (Table 4) [4].

Summary and Conclusions

Occult GI bleeding remains the most common cause of IDA in the adult male and postmenopausal female populations. Trends of laboratory indices and the serum ferritin, especially when a higher upper limit of normal is used, are extremely helpful in the diagnosis of IDA. When the diagnosis of IDA has been established, the clinician should proceed to upper and lower GI endoscopy in most cases. When a source is not found after routine endoscopy, further diagnostic workup includes repeat testing and evaluation of the small bowel often using WCE. Treatment of IDA should be aimed specifically at the underlying cause. If the patient requires iron replacement, oral therapy should be initiated as the first-line therapy; dose reduction is suggested in iron-intolerant subjects. When the patient fails oral therapy, or if oral therapy is contraindicated or discouraged, parenteral therapy should be instituted. Currently, the preferred choice for intravenous iron therapy is iron sucrose due to favorable pharmacologic properties combined with low rates of adverse drug events.

Acknowledgments This work was supported by the Department of Medicine, West Los Angeles VA Medical Center and the Cedars-VA Residency Program. We would like to thank Jenifer Kugler for her expert editorial assistance.

Open Access This article is distributed under the terms of the Creative Commons Attribution Noncommercial License which permits any noncommercial use, distribution, and reproduction in any medium, provided the original author(s) and source are credited.

References

1. Bermejo F, Garcia-López S. A guide to diagnosis of iron deficiency and iron deficiency anemia in digestive diseases. *World J Gastroenterol*. 2009;15:4638–4643.
2. Gasche C, Lomer MC, Cavill I, Weiss G. Iron, anaemia, and inflammatory bowel diseases. *Gut*. 2004;53:1190–1197.
3. Clark SF. Iron deficiency anemia. *Nutr Clin Pract.*. 2008;23:128–141.
4. Rockey DC. Occult gastrointestinal bleeding. *Gastroenterol Clin North Am*. 2005;34:699–718.
5. Powell N, McNair A. Gastrointestinal evaluation of anaemic patients without evidence of iron deficiency. *Eur J Gastroenterol Hepatol*. 2008;20:1094–1100.
6. Ioannou GN, Rockey DC, Bryson CL, Weiss NS. Iron deficiency and gastrointestinal malignancy: a population-based cohort study. *Am J Med*. 2002;113:276–280.
7. Ho CH, Chau WK, Hsu HC, Gau JP, You JY, Chen CC. Predictive risk factors and prevalence of malignancy in patients with iron deficiency anemia in Taiwan. *Am J Hematol*. 2005;78:108–112.
8. James MW, Chen CM, Goddard WP, Scott BB, Goddard AF. Risk factors for gastrointestinal malignancy in patients with iron-deficiency anaemia. *Eur J Gastroenterol Hepatol*. 2005;17:1197–1203.
9. Ho CH, Yu YB, Wu PH. The prevalence of iron deficiency anemia and its clinical implications in patients with colorectal carcinoma. *J Chin Med Assoc*. 2008;71:119–122.
10. Alleyne M, Horne MK, Miller JL. Individualized treatment for iron-deficiency anemia in adults. *Am J Med*. 2008;121:943–948.
11. Simovich M, Hainsworth LN, Fields PA, Umbreit JN, Conrad ME. Localization of the iron transport proteins Mobilferrin and DMT-1 in the duodenum: the surprising role of mucin. *Am J Hematol*. 2003;74:32–45.
12. Umbreit J. Iron deficiency: a concise review. *Am J Hematol*. 2005;78:225–231.

13. Walters GO, Miller FM, Worwood M. Serum ferritin concentration and iron stores in normal subjects. *J Clin Pathol*. 1973; 26:770–772.
14. Cook JD, Lipschitz DA, Miles LE, Finch CA. Serum ferritin as a measure of iron stores in normal subjects. *Am J Clin Nutr*. 1974; 27:681–687.
15. Guyatt GH, Oxman AD, Ali M, Willan A, McIlroy W, Patterson C. Laboratory diagnosis of iron-deficiency anemia: an overview. *J Gen Intern Med*. 1992;7:145–153.
16. Prieto J, Barry M, Sherlock S. Serum ferritin in patients with iron overload and with acute and chronic liver diseases. *Gastroenterology*. 1975;68:525–533.
17. Wish JB. Assessing iron status: beyond serum ferritin and transferrin saturation. *Clin J Am Soc Nephrol*. 2006;1(1):S4–S8.
18. Lee PL, Beutler E. Regulation of hepcidin and iron-overload disease. *Annu Rev Pathol*. 2009;4:489–515.
19. Tursi A, Giorgetti G, Brandimarte G, Rubino E, Lombardi D, Gasbarrini G. Prevalence and clinical presentation of subclinical/silent celiac disease in adults: an analysis on a 12-year observation. *Hepatogastroenterology*. 2001;48:462–464.
20. Hershko C, Hoffbrand AV, Keret D, et al. Role of autoimmune gastritis, *Helicobacter pylori* and celiac disease in refractory or unexplained iron deficiency anemia. *Haematologica*. 2005;90: 585–595.
21. Hershko C, Patz J, Ronson A. The anemia of achylia gastrica revisited. *Blood Cells Mol Dis*. 2007;39:178–183.
22. Annibale B, Capurso G, Chistolini A, et al. Gastrointestinal causes of refractory iron deficiency anemia in patients without gastrointestinal symptoms. *Am J Med*. 2001;111:439–445.
23. Stewart CA, Termanini B, Sutliff VE, et al. Iron absorption in patients with Zollinger-Ellison syndrome treated with long-term gastric acid antisecretory therapy. *Aliment Pharmacol Ther*. 1998;12:83–98.
24. Sharma VR, Brannon MA, Carloss EA. Effect of omeprazole on oral iron replacement in patients with iron deficiency anemia. *South Med J*. 2004;97:887–889.
25. Geokas MC, McKenna RD. Iron-deficiency anemia after partial gastrectomy. *Can Med Assoc J*. 1967;96:411–417.
26. Mizon C, Ruz M, Csendes A, et al. Persistent anemia after Roux-en-Y gastric bypass. *Nutrition*. 2007;23:277–280.
27. Grote L, Leissner L, Hedner J, Ulfberg J. A randomized, double-blind, placebo controlled, multi-center study of intravenous iron sucrose and placebo in the treatment of restless legs syndrome. *Mov Disord*. 2009;24:1445–1452.
28. Ekbom K, Ulfberg J. Restless legs syndrome. *J Intern Med*. 2009;266:419–431.
29. Aulakh R, Sohi I, Singh T, Kakkar N. Red cell distribution width (RDW) in the diagnosis of iron deficiency with microcytic hypochromic anemia. *Indian J Pediatr*. 2009;76:265–268.
30. Bessman JD, Feinstein DI. Quantitative anisocytosis as a discriminant between iron deficiency and thalassemia minor. *Blood*. 1979;53:288–293.
31. Aslan D, Gumruk F, Gurgey A, Altay C. Importance of RDW value in differential diagnosis of hypochrome anemias. *Am J Hematol*. 2002;69:31–33.
32. Bessman JD, Johnson RK. Erythrocyte volume distribution in normal and abnormal subjects. *Blood*. 1975;46:369–379.
33. Bessman D. Erythropoiesis during recovery from iron deficiency: normocytes and macrocytes. *Blood*. 1977;50:987–993.
34. Kis AM, Carnes M. Detecting iron deficiency in anemic patients with concomitant medical problems. *J Gen Intern Med*. 1998; 13:455–461.
35. Kishida T, Shinozawa I, Tanaka S, et al. Significance of serum iron and ferritin in patients with colorectal adenomas. *Scand J Gastroenterol*. 1997;32:233–237.
36. Sawhney MS, Lipato T, Nelson DB, Lederle FA, Rector TS, Bond JH. Should patients with anemia and low normal or normal serum ferritin undergo colonoscopy? *Am J Gastroenterol*. 2007; 102:82–88.
37. Zimmermann MB. Methods to assess iron and iodine status. *Br J Nutr*. 2008;99(3):S2–S9.
38. Metzgeroth G, Adelberger V, Dorn-Beineke A, et al. Soluble transferrin receptor and zinc protoporphyrin—competitors or efficient partners? *Eur J Haematol*. 2005;75:309–317.
39. Brugnara C. Iron deficiency and erythropoiesis: new diagnostic approaches. *Clin Chem*. 2003;49:1573–1578.
40. Muncie HL Jr, Campbell J. Alpha and beta thalassemia. *Am Fam Physician*. 2009;80:339–344.
41. Stroehlein JR, Fairbanks VF, McGill DB, Go VL. Hemoccult detection of fecal occult blood quantitated by radioassay. *Am J Dig Dis*. 1976;21:841–844.
42. Macrae FA, St John DJ. Relationship between patterns of bleeding and hemoccult sensitivity in patients with colorectal cancers or adenomas. *Gastroenterology*. 1982;82:891–898.
43. Guittet L, Bouvier V, Mariotte N, et al. Performance of immunochemical faecal occult blood test in colorectal cancer screening in average-risk population according to positivity threshold and number of samples. *Int J Cancer*. 2009;125:1127–1133.
44. Kepczyk T, Cremins JE, Long BD, Bachinski MB, Smith LR, McNally PR. A prospective, multidisciplinary evaluation of premenopausal women with iron-deficiency anemia. *Am J Gastroenterol*. 1999;94:109–115.
45. Green BT, Rockey DC. Gastrointestinal endoscopic evaluation of premenopausal women with iron deficiency anemia. *J Clin Gastroenterol*. 2004;38:104–109.
46. Bini EJ, Micale PL, Weinshel EH. Evaluation of the gastrointestinal tract in premenopausal women with iron deficiency anemia. *Am J Med*. 1998;105:281–286.
47. Carter D, Maor Y, Bar-Meir S, Avidan B. Prevalence and predictive signs for gastrointestinal lesions in premenopausal women with iron deficiency anemia. *Dig Dis Sci*. 2008;53:3138–3144.
48. Rockey DC, Cello JP. Evaluation of the gastrointestinal tract in patients with iron-deficiency anemia. *N Engl J Med*. 1993;329: 1691–1695.
49. Dickey W, McMillan SA, McCrum EE, Evans AE. Association between serum levels of total IgA and IgA class endomysial and antigliadin antibodies: implications for coeliac disease screening. *Eur J Gastroenterol Hepatol*. 1997;9:559–562.
50. Zamani F, Mohamadnejad M, Shakeri R, et al. Gluten sensitive enteropathy in patients with iron deficiency anemia of unknown origin. *World J Gastroenterol*. 2008;14:7381–7385.
51. Karnam US, Felder LR, Raskin JB. Prevalence of occult celiac disease in patients with iron-deficiency anemia: a prospective study. *South Med J*. 2004;97:30–34.
52. Joosten E, Ghesquiere B, Linthoudt H, et al. Upper and lower gastrointestinal evaluation of elderly inpatients who are iron deficient. *Am J Med*. 1999;107:24–29.
53. Raju GS, Gerson L, Das A, Lewis B. American Gastroenterological Association (AGA) Institute technical review on obscure gastrointestinal bleeding. *Gastroenterology*. 2007;133:1697–1717.
54. Fireman Z, Kopelman Y. The role of video capsule endoscopy in the evaluation of iron deficiency anaemia. *Dig Liver Dis*. 2004; 36:97–102.
55. Triester SL, Leighton JA, Leontiadis GI, et al. A meta-analysis of the yield of capsule endoscopy compared to other diagnostic modalities in patients with obscure gastrointestinal bleeding. *Am J Gastroenterol*. 2005;100:2407–2418.
56. Muhammad A, Pitchumoni CS. Evaluation of iron deficiency anemia in older adults: the role of wireless capsule endoscopy. *J Clin Gastroenterol*. 2009;43:627–631.

57. Turner D, Griffiths AM. Esophageal, gastric, and duodenal manifestations of IBD and the role of upper endoscopy in IBD diagnosis. *Curr Gastroenterol Rep.*. 2007;9:475–478.
58. Haig A, Driman DK. Iron-induced mucosal injury to the upper gastrointestinal tract. *Histopathology*. 2006;48:808–812.
59. Kaye P, Abdulla K, Wood J, et al. Iron-induced mucosal pathology of the upper gastrointestinal tract: a common finding in patients on oral iron therapy. *Histopathology*. 2008;53:311–317.
60. Rimon E, Kagansky N, Kagansky M, et al. Are we giving too much iron? low-dose iron therapy is effective in octogenarians. *Am J Med*. 2005;118:1142–1147.
61. Makrides M, Crowther CA, Gibson RA, Gibson RS, Skeaff CM. Efficacy and tolerability of low-dose iron supplements during pregnancy: a randomized controlled trial. *Am J Clin Nutr*. 2003; 78:145–153.
62. Zhou SJ, Gibson RA, Crowther CA, Makrides M. Should we lower the dose of iron when treating anaemia in pregnancy? a randomized dose-response trial. *Eur J Clin Nutr*. 2009;63:183–190.
63. Maslovsky I. Intravenous iron in a primary-care clinic. *Am J Hematol*. 2005;78:261–264.
64. Auerbach M, Goodnough LT, Picard D, Maniatis A. The role of intravenous iron in anemia management and transfusion avoidance. *Transfusion*. 2008;48:988–1000.
65. Edwards TJ, Noble EJ, Durran A, Mellor N, Hosie KB. Randomized clinical trial of preoperative intravenous iron sucrose to reduce blood transfusion in anaemic patients after colorectal cancer surgery. *Br J Surg*. 2009;96:1122–1128.
66. Annibale B, Severi C, Chistolini A, et al. Efficacy of gluten-free diet alone on recovery from iron deficiency anemia in adult celiac patients. *Am J Gastroenterol*. 2001;96:132–137.
67. Charytan C, Schwenk MH, Al-Saloum MM, Spinowitz BS. Safety of iron sucrose in hemodialysis patients intolerant to other parenteral iron products. *Nephron Clin Pract*. 2004;96:c63–c66.
68. Bayoumeu F, Subiran-Buisset C, Baka NE, Legagneur H, Monnier-Barbarino P, Laxenaire MC. Iron therapy in iron deficiency anemia in pregnancy: intravenous route versus oral route. *Am J Obstet Gynecol*. 2002;186:518–522.
69. Al RA, Unlubilgin E, Kandemir O, Yalvac S, Cakir L, Haberal A. Intravenous versus oral iron for treatment of anemia in pregnancy: a randomized trial. *Obstet Gynecol*. 2005;106:1335–1340.
70. Bhandal N, Russell R. Intravenous versus oral iron therapy for postpartum anaemia. *BJOG*. 2006;113:1248–1252.
71. Akarsu S, Taskin E, Yilmaz E, Yilmaz H, Kilic M, Aygun AD. Treatment of iron deficiency anemia with intravenous iron preparations. *Acta Haematol*. 2006;116:51–57.
72. Wall GC, Pauly RA. Evaluation of total-dose iron sucrose infusions in patients with iron deficiency anemia. *Am J Health Syst Pharm*. 2008;65:150–153.
73. Blaustein DA, Schwenk MH, Chattopadhyay J, Singh H, Daoui R, Gadh R, Avram MM (2003) The safety and efficacy of an accelerated iron sucrose dosing regimen in patients with chronic kidney disease. Kidney Int Suppl. S72–S77.
74. Schroder O, Schrott M, Blumenstein I, Jahnel J, Dignass AU, Stein J. A study for the evaluation of safety and tolerability of intravenous high-dose iron sucrose in patients with iron deficiency anemia due to gastrointestinal bleeding. *Z Gastroenterol*. 2004;42:663–667.
75. Kulnigg S, Stoinov S, Simanenkov V, et al. A novel intravenous iron formulation for treatment of anemia in inflammatory bowel disease: the ferric carboxymaltose (FERINJECT) randomized controlled trial. *Am J Gastroenterol*. 2008;103:1182–1192.
76. Wilson A, Reyes E, Ofman J. Prevalence and outcomes of anemia in inflammatory bowel disease: a systematic review of the literature. *Am J Med*. 2004;116(Suppl 7A):44S–49S.
77. Gisbert JP, Gomollón F. Common misconceptions in the diagnosis and management of anemia in inflammatory bowel disease. *Am J Gastroenterol*. 2008;103:1299–1307.
78. Reifen R, Matas Z, Zeidel L, Berkovitch Z, Bujanover Y. Iron supplementation may aggravate inflammatory status of colitis in a rat model. *Dig Dis Sci*. 2000;45:394–397.
79. Seril DN, Liao J, West AB, Yang GY. High-iron diet: foe or feat in ulcerative colitis and ulcerative colitis-associated carcinogenesis. *J Clin Gastroenterol*. 2006;40:391–397.
80. Lund EK, Wharf SG, Fairweather-Tait SJ, Johnson IT. Oral ferrous sulfate supplements increase the free radical-generating capacity of feces from healthy volunteers. *Am J Clin Nutr*. 1999; 69:250–255.
81. Lindgren S, Wikman O, Befrits R, et al. Intravenous iron sucrose is superior to oral iron sulphate for correcting anaemia and restoring iron stores in IBD patients: a randomized, controlled, evaluator-blind, multicentre study. *Scand J Gastroenterol*. 2009; 44:838–845.
82. Wells CW, Lewis S, Barton JR, Corbett S. Effects of changes in hemoglobin level on quality of life and cognitive function in inflammatory bowel disease patients. *Inflamm Bowel Dis*. 2006; 12:123–130.
83. Gasche C, Berstad A, Befrits R, et al. Guidelines on the diagnosis and management of iron deficiency and anemia in inflammatory bowel diseases. *Inflamm Bowel Dis*. 2007;13:1545–1553.
84. Gomollón F, Gisbert JP. Anemia and inflammatory bowel diseases. *World J Gastroenterol*. 2009;15:4659–4665.
85. Macdougall IC. Strategies for iron supplementation: oral versus intravenous. *Kidney Int Suppl*. 1999;69:S61–S66.
86. Kosmadakis N, Messaris E, Maris A, et al. Perioperative erythropoietin administration in patients with gastrointestinal tract cancer: prospective randomized double-blind study. *Ann Surg*. 2003; 237:417–421.
87. Braga M, Gianotti L, Gentilini O, Vignali A, Corizia L, Di Carlo V. Erythropoiesis after therapy with recombinant human erythropoietin: a dose-response study in anemic cancer surgery patients. *Vox Sang*. 1999;76:38–42.
88. López RM, Aladrén BS, Garcia FG. Use of agents stimulating erythropoiesis in digestive diseases. *World J Gastroenterol*. 2009; 15:4675–4685.
89. Silverstein SB, Rodgers GM. Parenteral iron therapy options. *Am J Hematol*. 2004;76:74–78.