

# UC Davis

## UC Davis Previously Published Works

### Title

Papilledema Outcomes from the Optical Coherence Tomography Substudy of the Idiopathic Intracranial Hypertension Treatment Trial

### Permalink

<https://escholarship.org/uc/item/09p1h6sm>

### Journal

Ophthalmology, 122(9)

### ISSN

0161-6420

### Authors

Group, The Optical Coherence Tomography Substudy Committee and the NORDIC Idiopathic Intracranial Hypertension Study

Auinger, Peggy

Durbin, Mary

et al.

### Publication Date

2015-09-01

### DOI

10.1016/j.ophtha.2015.06.003

Peer reviewed

# Papilledema Outcomes from the Optical Coherence Tomography Substudy of the Idiopathic Intracranial Hypertension Treatment Trial

The Optical Coherence Tomography Substudy Committee and the NORDIC Idiopathic Intracranial Hypertension Study Group\*

**Purpose:** To assess treatment efficacy using spectral-domain (SD) optical coherence tomography (OCT) measurements of papilledema in the Idiopathic Intracranial Hypertension Treatment Trial (IIHTT), which evaluated the effects of acetazolamide and weight management and of placebo and weight management in eyes with mild visual loss.

**Design:** Randomized double-masked control clinical trial of acetazolamide plus weight management compared with placebo plus weight management in subjects with mild visual field loss and previously untreated idiopathic intracranial hypertension (IIH).

**Participants:** Eighty-nine (43 acetazolamide treated, 46 placebo treated) of 165 subjects meeting IIHTT entry criteria.

**Methods:** Subjects underwent perimetry, papilledema grading (Frisén method), high- and low-contrast visual acuity, and SD OCT imaging at study entry and 3 and 6 months. Study eye results (worse perimetric mean deviation [PMD]) were used for most analyses.

**Main Outcome Measures:** Retinal nerve fiber layer (RNFL) thickness, total retinal thickness (TRT), optic nerve (ONH) volume, and retinal ganglion cell layer (RGCL) measurements derived using 3-dimensional segmentation.

**Results:** Study entry OCT values were similar in both treatment groups. At 6 months, the acetazolamide group had greater reduction than the placebo group for RNFL thickness (175  $\mu\text{m}$  vs. 89  $\mu\text{m}$ ;  $P = 0.001$ ), TRT (220  $\mu\text{m}$  vs. 113  $\mu\text{m}$ ;  $P = 0.001$ ), and ONH volume (4.9  $\text{mm}^3$  vs. 2.1  $\text{mm}^3$ ;  $P = 0.001$ ). The RNFL thickness ( $P = 0.01$ ), TRT ( $P = 0.003$ ), and ONH volume ( $P = 0.002$ ) measurements also showed smaller increases in subjects who lost 6% or more of study entry weight. The acetazolamide (3.6  $\mu\text{m}$ ) and placebo (2.1  $\mu\text{m}$ ) groups showed minor RGCL thinning ( $P = 0.06$ ). The RNFL thickness, TRT, and ONH volume measurements showed moderate correlations ( $r = 0.48\text{--}0.59$ ;  $P < 0.0001$ ) with Frisén grade. The 14 eyes with RGCL thickness less than the fifth percentile of controls had worse PMD ( $P = 0.001$ ) than study eyes with RGCL in the fifth percentile or more.

**Conclusions:** In IIH, acetazolamide and weight loss effectively improve RNFL thickness, TRT, and ONH volume swelling measurements resulting from papilledema. In contrast to the strong correlation at baseline, OCT measures at 6 months show only moderate correlations with papilledema grade. *Ophthalmology* 2015;122:1939-1945 © 2015 by the American Academy of Ophthalmology.



\*Supplemental material is available at [www.aajournal.org](http://www.aajournal.org).

Spectral-domain (SD) optical coherence tomography (OCT) has provided high-quality data collected from multiple clinical sites from patients naïve to treatment for papilledema resulting from idiopathic intracranial hypertension (IIH) who have mild vision loss at entry into the Idiopathic Intracranial Hypertension Treatment Trial (IIHTT).<sup>1,2</sup> Optical coherence tomography reliably and reproducibly demonstrates alterations in the optic nerve head (ONH) and retinal layers (RNFLs) in patients with IIH. At baseline, we measured the average peripapillary RNFL thickness, average peripapillary total retina thickness (TRT), ONH

volume, and the retinal ganglion cell layer (RGCL) plus inner plexiform layer (IPL) thickness in the macular region. The RNFL thickness, TRT, and ONH volume also correlated strongly with Frisén papilledema grade.<sup>3</sup> Prior studies of eyes with significant ONH swelling showed that 2-dimensional (2-D) segmentation analysis failures are common when using the proprietary OCT algorithms for measuring the effects of swelling in the peripapillary retina via RNFL thickness with SD OCT (Mandel G, et al. IOVS 2010;51:ARVO E-Abstract 555) and TRT with time-domain OCT.<sup>4</sup> For eyes studied in the IIHTT, the

proprietary 2-D segmentation algorithm (Zeiss Meditec [ZM] method) used in the commercial OCT device displayed noteworthy failure rates in the measurement of average RNFL thickness (10%), TRT (16%), and RGCL plus IPL thickness (20%). The 3-dimensional (3-D) segmentation algorithm from the University of Iowa engineering group<sup>5</sup> was less prone to failure, with rates of 2.4%, 2.4%, and 0.8%, respectively for the same OCT parameters.

The IIHTT showed that acetazolamide significantly improved perimetric mean deviation (PMD), cerebrospinal fluid (CSF) pressure, quality-of-life measures, and papilledema grade in subjects with mild visual field loss in patients newly diagnosed with IIH.<sup>2</sup> The accepted objective method for evaluating papilledema and monitoring the alterations in the ONH, the Frisén scale, is an ordinal grading based on descriptive features.<sup>6</sup> Spectral-domain OCT provides continuous variable measurements that demonstrate the structural changes in the optic nerve and retina because of papilledema and measures the effects of intracranial hypertension and its treatment.

We report the results of OCT measures for the 6-month investigational phase of the IIHTT by treatment group. We investigated: (1) whether the 3 OCT measures reflecting swelling—RNFL thickness, TRT, and ONH volume—are improved significantly with acetazolamide compared with placebo or with weight loss (see “Methods” for definition) compared with no weight loss; (2) whether these 3 OCT measures change to the same degree from baseline in study eyes at the study outcome time point of 6 months; (3) whether strong interocular correlations for these 3 OCT measures are maintained at 6 months; (4) whether the amount of swelling found with these 3 OCT measures are correlated strongly with the Frisén grade at 6 months; and (5) whether the RGCL plus IPL thins significantly over 6 months and whether RGCL plus IPL thinning correlates with vision performance at 6 months.

## Methods

Details of the IIHTT study design and entry criteria are published.<sup>7</sup> Patients with IIH who were naïve to treatment with a PMD of  $-2.00$  to  $-7.00$  dB using the Swedish interactive threshold algorithm standard 24-2 test pattern on the Humphrey Field Analyzer II perimeter (Carl Zeiss Meditec, Inc, Dublin, CA) in the eye with the worse PMD (designated the study eye) were enrolled. All subjects signed consent and the study was performed under institutional review board approval and in accordance with the Declaration of Helsinki. The trial is registered at [ClinicalTrials.gov](http://ClinicalTrials.gov) (identifier, NCT01003639).

Standardized fundus photographs, Frisén grading of photographs at the photographic reading center<sup>8</sup> and by clinical examination by site investigators, high- and low-contrast (2.5%) visual acuity, threshold 24-2 perimetry, and SD OCT imaging using the Cirrus 4000 SD OCT device (with version 6.01 software; Carl Zeiss Meditec, Inc) were performed in each eye at each visit. Study sites followed a study-specific protocol for image collection by certified technicians, digitally transferred the collected data, and had quality control and analyses by the OCT reading center. The availability of the specific study OCT limited the substudy to subjects at 24 sites.

The image acquisition protocol required 2 optic disc regions centered on the optic disc and 2 macular region volume scans

centered on the fovea. The OCT data were uploaded to the NORDIC imaging center site via a secure upload web client. In addition to certifying site equipment and technicians, the OCT reading center maintained quality control on all OCT data collected.<sup>1</sup>

We used optic disc region volume image data to calculate the peripapillary circumference average RNFL thickness and TRT with the ZM (2-D) method and 3-D segmentation method. The ONH volume was calculated using 3-D analysis of segmented optic disc volume scans.<sup>5</sup> Three-dimensional layer segmentation was performed on the ONH-centered scans, and from each ONH-centered volume, the total retinal volume (i.e., the volume between the internal limiting membrane and the retinal pigment epithelium reference surface) was computed. The RNFL thickness and TRT were computed using a radius of 1.73 mm around the center of the ONH.

Using the Macula Cube volumetric images, TRT of sectors and the average thickness of the RGCL plus IPL complex were measured using the ZM and 3-D segmentation methods. The ZM method finds the distance between the outer boundary of the RNFL and the outer boundary of the IPL to report the combined thickness of the RGCL plus IPL, while excluding the RNFL.<sup>9</sup>

For 3-D segmentation analysis, 11 intraretinal surfaces of each macula-centered volumetric scan were segmented first using the graph-theoretic approach developed at the University of Iowa.<sup>5</sup> The (1) internal limiting membrane, (2) interface between the RNFL and the RGCL, (3) interface between the IPL and the inner nuclear layer, and (4) posterior surface of the retinal pigment epithelial layer surfaces were retained to enable computation of the fovea center and RGCL plus IPL thickness. For each A-scan location, the RGCL plus IPL thickness was defined as the distance between the second surface and the third surface.

## Statistical Analyses

For 3-D segmentation RGCL plus IPL thickness, age-matched controls (derived by 3-D segmentation of the set of normative scans provided by Carl Zeiss Meditec, Inc) were used to determine the average RGCL as a percentile of the controls. Descriptive statistics were used to summarize each SD OCT measure based on the first measurement of the study eye (the eye with worse PMD). The first SD OCT measures from both eyes were compared using Pearson correlation coefficients to describe the interocular relationship of these measures (each comparison was for the same measure and method of analysis performed in both eyes).

The RGCL plus IPL value calculated by 3-D segmentation was defined as thinned if the study eye RGCL plus IPL value was less than the fifth percentile of the 3-D segmentation RGCL value derived from age-matched Zeiss normative scans. We used *t* tests to compare this group with study subjects with RGCL plus IPL thickness values in the fifth percentile or more of controls.

The IIH clinical characteristics, collected at 6 months under the IIHTT protocol, were compared with the 6-month OCT findings. Frisén grade of papilledema was determined from digital photographs evaluated by the photographic reading center and also by clinical examination (not by photographic review at the site) performed by the principle investigator at each site. Specific IIH clinical features that were correlated with the OCT findings included amount of weight change, body mass index (BMI), and CSF opening pressure in millimeters of oxygen at 6 months. The best-corrected visual acuity (reported as number of letters correctly identified) for high-contrast (100%) and low-contrast (2.5%) charts and PMD (reported in decibels) on automated threshold visual field testing were correlated with the OCT findings. All OCT data were evaluated and compared for treatment group assignment (acetazolamide plus weight management [acetazolamide-treated group] and placebo plus weight management [placebo-treated group]) and

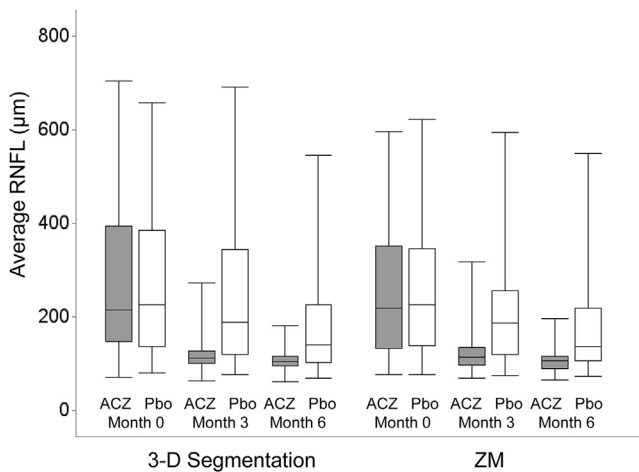
whether the planned weight loss target (defined as 6% of the weight at study entry) was reached at 6 months (weight loss or no weight loss).

We also analyzed the OCT data for IIHTT treatment failures. Treatment failure was defined when a participant with baseline PMD up to  $-3.5$  dB had visual function worsen by more than 2 dB PMD from baseline in either eye, or when a participant with baseline PMD between  $-3.5$  dB and  $-7$  dB had visual function worsen by more than 3 dB PMD from baseline in either eye. An adjudication committee, using all available clinical information, confirmed that the worsening was the result of progression of IIH.<sup>7</sup> We explored whether these eyes had baseline OCT features predictive of failure or subsequent OCT features that correlated with visual field worsening.

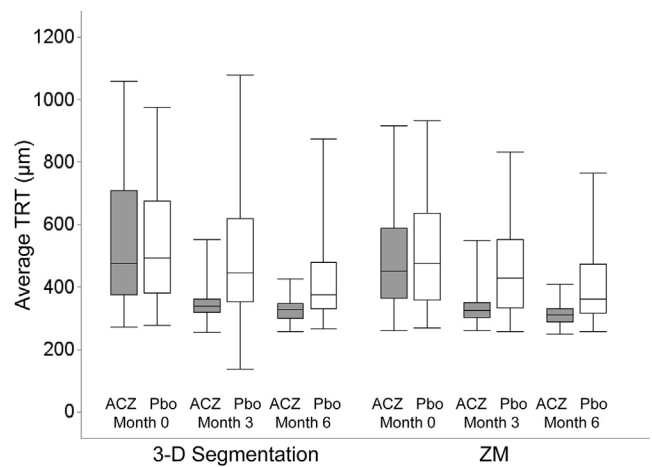
Mean responses for each OCT variable and interocular correlations were computed using repeated-measures analysis of covariance models that included treatment group as the factor of interest with adjustment for site and the baseline value of the outcome. Months 3 and 6 were treated as categorical variables. The interactions between treatment group (acetazolamide or placebo) and month and between baseline value of the outcome and month also were included in the models. Treatment effects were the group differences (acetazolamide vs. placebo) in adjusted mean response. Weight change effects were reported as the group differences (loss vs. no change) in adjusted mean response. The covariance structure of the R matrix was specified as direct product compound symmetry.

## Results

Eighty-nine (43 acetazolamide treated, 46 placebo treated) of 165 enrolled IIHTT subjects were included in the OCT substudy. At study entry, all the OCT measures reflecting swelling associated with papilledema, RNFL thickness, TRT, and ONH volume were similar in study eyes of both treatment groups (Figs 1, 2, and 3; all baseline data reported previously<sup>1</sup>). Over 6 months, all 3 OCT measures were reduced in study eyes in both treatment groups, with significant changes seen by 3 months (Figs 1–3). The changes from baseline at 6 months for ONH volume and the RNFL



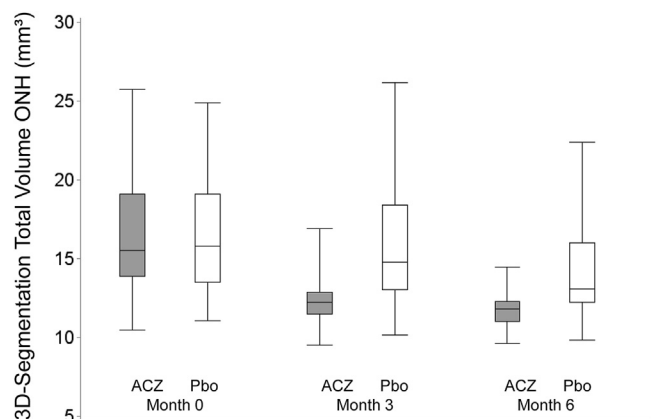
**Figure 1.** Boxplots showing average retinal nerve fiber layer (RNFL) thickness at study enrollment (month 0), month 3, and month 6, divided by treatment group. Acetazolamide (ACZ; solid) and placebo (Pbo; hashed) boxes for each time point for 3-dimensional segmentation and Zeiss Meditec (ZM) algorithm show derived data. The difference from baseline to month 6 values is significant for both groups using both methods ( $P < 0.001$  for ACZ and  $P = 0.001$  for Pbo).



**Figure 2.** Boxplots showing average total retinal thickness (TRT) at study enrollment (month 0), month 3, and month 6, divided by treatment group. Acetazolamide (ACZ; solid) and placebo (Pbo; hashed) boxes for each time point for 3-D segmentation and Zeiss Meditec (ZM) algorithm show derived data. The difference from baseline to month 6 values is significant for both groups using both methods ( $P < 0.001$ ).

thickness and TRT measured by both methods for study eyes showed strong correlation with the fellow nonstudy eye and for nonstudy eyes that met criteria for study entry (Table 1). The RGCL plus IPL thickness was reduced minimally at 6 months. The correlations were strong for 3-D segmentation-derived RGCL thickness, but not for values derived from the ZM method (Table 1; see “Discussion”).

At 6 months, the acetazolamide-treated study eyes demonstrated 3-D segmentation-derived mean RNFL thickness ( $174 \mu\text{m}$ ;  $P = 0.001$ ), TRT ( $218 \mu\text{m}$ ;  $P = 0.001$ ), and ONH volume ( $4.9 \text{ mm}^3$ ;  $P = 0.001$ ) that were less than eyes in the placebo group eyes ( $93 \mu\text{m}$ ,  $121 \mu\text{m}$ ,  $2.4 \text{ mm}^3$ , respectively; Figs 1–3). Similar results were seen in nonstudy eyes (data not shown). The mean reduction in the RNFL thickness, TRT, and ONH volume compared with study entry was significantly greater in the acetazolamide-treated



**Figure 3.** Boxplots showing average optic nerve head (ONH) volume at study enrollment (month 0), month 3, and month 6, divided by treatment group. Acetazolamide (ACZ; solid) and placebo (Pbo; hashed) boxes for each time point for 3-D segmentation algorithm show derived data. The difference from baseline to month 6 values is significant for both groups ( $P < 0.001$ ).

Table 1. Optical Coherence Tomography Change at 6 Months from Baseline Intercorrelations between Study Eyes and Nonstudy Eyes

Label	Correlation between Study Eyes and All Nonstudy Eyes	Correlation between Study Eyes and Eligible Nonstudy Eyes
3-Dimensional segmentation method		
Total volume ONH (mm <sup>3</sup> )	0.92	0.92
Average RNFL thickness (μm)	0.86	0.86
Average TRT (μm)	0.86	0.86
Average RGCL + IPL (μm)	0.72	0.78
ZM methods		
Average RNFL thickness (μm)	0.80	0.81
Average TRT (circle) (μm)	0.81	0.79
Average RGCL + IPL (μm)	0.32	0.10

IPL = inner plexiform layer; ONH = optic nerve head; RGCL = retinal ganglion cell layer; RNFL = retinal nerve fiber layer; TRT = total retinal thickness; ZM = Zeiss Meditec.  
Eligible nonstudy eyes defined as fellow eye with baseline perimetric mean deviation worse than -2.0 dB.

study eyes (Table 2). The RNFL thickness ( $P = 0.01$ ), TRT ( $P = 0.003$ ), and ONH volume ( $P = 0.002$ ) showed greater reduction in subjects who lost weight compared with those who had minor or no weight loss (Table 3). The reduction of OCT measurements associated with weight loss was seen in either treatment group. The differences for RNFL thickness, TRT, ONH volume, and RGCL plus IPL thickness between weight groups for acetazolamide and placebo treatment groups were similar (Table 3).

At 6 months, the RNFL thickness, TRT, and ONH volume showed significant moderate correlations ( $r = 0.41-0.53$ ;  $P \leq 0.0001$ ) with Frisén grade determined by both clinical

examination and photographic reading center evaluations (Table 4). Comparing the change in RNFL thickness, TRT, and ONH volume with a change in Frisén grade, determined by clinical examination and reading center photographs, showed slightly stronger correlations (Table 4). There were no correlations (data not shown) for any of the OCT measures compared with high- or low-contrast visual acuity, PMD, CSF opening pressure, or BMI (data not shown).

At 6 months, RGCL thickness values derived by 3-D segmentation and ZM methods were reduced minimally for both treatment groups (Fig 4; Tables 1 and 2). The RGCL thickness (by 3-D segmentation) was less than the normal fifth percentile in 9 study eyes (7%) at study entry, in 14 study eyes (36%) at 3 months, and in 14 study eyes (50%) at 6 months. The PMD ( $P = 0.001$ ) was significantly worse in eyes with less than fifth-percentile RGCL thickness at 6 months; however, high-contrast visual acuity ( $P = 0.56$ ) and low-contrast visual acuity ( $P = 0.12$ ) were not significantly different at 6 months (Table 5). The PMD and high- and low-contrast visual acuity were not significantly different between eyes grouped by RGCL thickness at 3 months (Table 5). The 10 study eyes with RNFL thickness less than the fifth percentile (83 μm) at 6 months did not have worse PMD or high- or low-contrast visual acuity (data not shown).

At 6 months, 19 eyes had RNFL thickness less than the normal ZM fifth-percentile thickness (83 μm), 8 of which also had 3-D segmentation RGCL thickness values less than the normal ZM fifth-percentile values. These 19 eyes did not have significantly worse PMD, high-contrast visual acuity, or low-contrast visual acuity than eyes without RNFL thinning (data not shown).

Six of the 7 eyes that met criteria for treatment failure had OCT data collected. Only 1 of 6 eyes that had visual field loss leading to treatment failure had RGCL plus IPL thickness (65.4 μm) that was less than the fifth percentile at study entry, and treatment failed in this patient at 1 month. No other eyes had major RGCL reduction before or at the time of treatment failure. None of the treatment failure eyes demonstrated RNFL thinning less than the control fifth percentile at the time of failure. Optical coherence tomography data collection was not consistent after treatment failure.

Table 2. Treatment Effects on Optical Coherence Tomography Outcomes in Study Eyes at Month 6

Label	Treatment Group	Adjusted Mean Change from Baseline (Standard Error)	Treatment Effect	95% Confidence Interval	P Value
3-Dimensional segmentation method-derived measures					
Total volume ONH (mm <sup>3</sup> )	Acetazolamide	-4.9 (0.3)	-2.8	-3.7 to -1.8	<0.001
	Placebo	-2.1 (0.3)			
Average RNFL thickness (μm)	Acetazolamide	-174.7 (11.8)	-86.1	-119.8 to -52.4	<0.001
	Placebo	-88.6 (12.5)			
Average TRT (μm)	Acetazolamide	-220.1 (14.8)	-106.7	-149.0 to -64.5	<0.001
	Placebo	-113.4 (15.6)			
Average RGCL + IPL (μm)	Acetazolamide	-3.6 (0.6)	-1.5	-3.1 to 0.08	0.06
	Placebo	-2.1 (0.6)			
ZM method-derived measures					
Average RNFL thickness (μm)	Acetazolamide	-144.6 (10.8)	-69.4	-100.7 to -38.2	<0.001
	Placebo	-75.2 (11.7)			
Average TRT (μm)	Acetazolamide	-182.4 (13.0)	-87.2	-124.6 to -49.8	<0.001
	Placebo	-95.2 (14.0)			
Average RGCL + IPL (μm)	Acetazolamide	6.3 (1.3)	1.1	-2.7 to 4.9	0.57
	Placebo	5.2 (1.4)			

IPL = inner plexiform layer; ONH = optic nerve head; RGCL = retinal ganglion cell layer; RNFL = retinal nerve fiber layer; TRT = total retinal thickness; ZM = Zeiss Meditec.

Treatment effects are the group differences (acetazolamide vs. placebo) in adjusted mean response.

Table 3. Weight Change Effects on Optical Coherence Tomography Outcomes in Study Eyes at Month 6

Label	Weight Change Group	Adjusted Mean Change from Baseline (Standard Error)	Weight Change Effect	95% Confidence Interval	P Value
3-Dimensional segmentation method—derived measures					
Total volume ONH (mm <sup>3</sup> )	Loss	-4.2 (0.4)	-1.8	-2.8 to -0.7	0.002
	No change	-2.4 (0.4)			
Average RNFL thickness (µm)	Loss	-153.3 (14.2)	-56.9	-96.4 to -17.4	0.01
	No change	-96.4 (13.5)			
Average TRT (µm)	Loss	-197.8 (17.5)	-78.3	-127.0 to -29.7	0.002
	No change	-119.5 (16.6)			
Average RGCL + IPL (µm)	Loss	-3.4 (0.5)	-1.4	-2.8 to -0.001	0.05
	No change	-2.0 (0.5)			
ZM algorithm—derived measures					
Average RNFL thickness (µm)	Loss	-125.2 (13.1)	-51.7	-88.5 to -15.0	0.01
	No change	-73.5 (12.6)			
Average TRT (µm)	Loss	-165.3 (15.8)	-67.8	-112.2 to -23.4	0.003
	No change	-97.5 (15.0)			
Average RGCL + IPL (µm)	Loss	6.2 (1.5)	0.5	-3.8 to 4.8	0.83
	No change	5.7 (1.4)			

IPL = inner plexiform layer; ONH = optic nerve head; RGCL = retinal ganglion cell layer; RNFL = retinal nerve fiber layer; TRT = total retinal thickness; ZM = Zeiss Meditec.

Weight change effects are the group differences (loss vs. no change) in adjusted mean response.

## Discussion

Our results, collected in this longitudinal prospective study and treatment trial of IIH patients using SD OCT to monitor the effects of papilledema, showed that acetazolamide plus weight management was effective in reducing swelling of RNFL, total retina, and ONH volume in study and nonstudy eyes at 6 months in the IIHTT. These OCT measures also were reduced in the placebo plus weight management group. Eyes of subjects with at least 6% of baseline body weight reduction (IIHTT planned target) showed significantly less swelling of OCT measures as well, regardless of the treatment group. Thinning or atrophy of the macula region RGCL was negligible in most study and nonstudy eyes. The RNFL and TRT thicknesses and ONH volume measurements had similar sensitivity for following the effects of papilledema and the change with treatment. This differs from prior reports of Scott

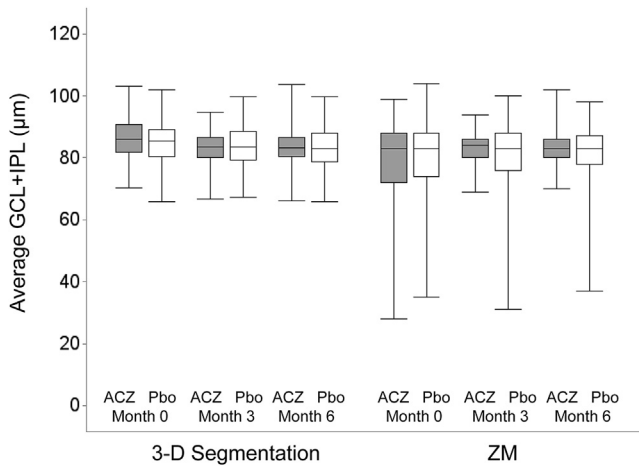
et al<sup>10</sup> and Vartin et al<sup>11</sup> suggesting the TRT was superior to RNFL thickness for monitoring papilledema. Our use of 3-D segmentation probably increased the reliability as well as the ability to actually measure the swelling when severe.

There was no overall correlation with the average RNFL or RGCL thickness and visual performance at 6 months. However, even when excluding the treatment failure eyes (6 eyes in the OCT cohort), loss or thinning of the RGCL to less than the control fifth percentile at 6 months was correlated significantly with mild, but definitely worse, PMD. Also, eyes with RNFL thinning did not demonstrate significantly worse visual performance than eyes with continued RNFL swelling or normal thickness. In IIH, where continued papilledema can obscure OCT demonstration of RNFL thinning or atrophy, RGCL thickness measurement with 3-D segmentation, in contrast to 2-D methods,<sup>1</sup> is a reliable structural biomarker of neuronal loss. We cannot explain why the RGCL thickness was

Table 4. Spearman Correlations between Month 6 Measures and Changes for Optical Coherence Tomography Values and Frisén Grades for Study Eyes

Optical Coherence Tomography Values	Frisén Grade Clinical Examination Results	Frisén Grade Photographs	Change in Optical Coherence Tomography Values	Change in Frisén Grade Clinical Examination Results	Change in Frisén Grade Photographs
3-Dimensional segmentation method					
ONH volume	0.50 (P < 0.0001)	0.53 (P < 0.0001)	Change in ONH volume	0.63 (P < 0.0001)	0.67 (P < 0.0001)
RNFL thickness	0.41 (P < 0.0004)	0.47 (P < 0.0001)	Change in RNFL thickness	0.57 (P < 0.0001)	0.54 (P < 0.0001)
TRT	0.41 (P = 0.0003)	0.44 (P = 0.0001)	Change in TRT	0.58 (P < 0.0001)	0.60 (P < 0.0001)
ZM method					
RNFL thickness	0.50 (P < 0.0001)	0.55 (P < 0.0001)	Change in RNFL thickness	0.64 (P < 0.0001)	0.69 (P < 0.0001)
TRT	0.52 (P < 0.0001)	0.53 (P < 0.0001)	Change in TRT	0.62 (P < 0.0001)	0.67 (P < 0.0001)

ONH = optic nerve head; RNFL = retinal nerve fiber layer; TRT = total retinal thickness; ZM = Zeiss Meditec.



**Figure 4.** Boxplots showing average retinal ganglion cell layer (RGCL) plus inner plexiform layer (IPL) thickness at study enrollment (month 0), month 3, and month 6, divided by treatment group. Acetazolamide (ACZ; solid) and placebo (Pbo; hashed) boxes for each time point for 3-dimensional segmentation and Zeiss Meditec (ZM) algorithm show derived data. The difference from baseline to month 6 values is significant for both groups using 3-dimensional segmentation ( $P < 0.001$  for ACZ and  $P = 0.01$  for Pbo) and significant for ACZ ( $P = 0.03$ ), but not for Pbo ( $P = 0.09$ ) for the ZM method. Note that the differences were miniscule.

minimally reduced at 6 months in the acetazolamide treatment group. This is difficult to reconcile given the better visual field PMD at 6 months in both treatment groups that was significantly better in the entire IIHTT cohort acetazolamide-treated eyes as reported in the primary outcome article.<sup>2</sup> It may be that the baseline RGCL plus IPL slight increase in thickness in the acetazolamide group (see Fig 4) was the result of retinal edema or some other cause of retinal swelling that resolved. Nevertheless, the amount of RGCL thinning at 6 months was nominal compared with RGCL thinning because of other optic neuropathies (Wang J-K, et al. IOVS 2014;515:ARVO E-Abstract 5780-B0116). Additionally, we believe the lack of interocular correlation for change in RGCL thickness for the ZM method (2-D segmentation) was the result of the algorithm failure causing artificially low values at baseline.<sup>1</sup>

We were not surprised to see a weaker correlation than was seen at baseline<sup>3</sup> between the OCT measures of peripapillary retina and ONH swelling and Frisén grade at 6 months. Given that 52% of placebo-treated eyes and 75% of acetazolamide-treated eyes were either grade 0 or 1, we anticipated a floor effect as the continuous variable RNFL thickness, TRT, and ONH volume values became less swollen. Additionally, OCT and Frisén grading assess different pathophysiological aspects of papilledema. The Frisén grade is based on descriptive inspection of numerous features that are grouped into set stages. Determining progression or regression of edema can be obscured by gliosis, ischemia, and dilated venules. In contrast, the OCT evaluated with 3-D segmentation provides continuous reliable measures that seem to reflect the effects of intracellular and extracellular edema and axonal loss and thinning across all degrees of swelling. Frisén grade changes over time or in response to therapy can show large

Table 5. Vision Performance in Study Eyes at 3 and 6 Months Divided by Reduction in Retinal Ganglion Cell Layer Thickness

Retinal Ganglion Cell Layer Thickness	Perimetric Mean Deviation (db)	High-Contrast	Low-Contrast Visual Acuity (No. Identified)
		Visual Acuity (No. Identified)	
<Fifth percentile at 3 mos	-2.55±1.82	57.4±4.8	24.6±9.5
≥Fifth percentile at 3 mos	-2.48±1.26	58.4±5.1	28.9±9.9
<Fifth percentile at 6 mos	-3.53±1.94	57.7±6.0	24.5±8.2
≥Fifth percentile at 6 mos	-2.04±1.37	58.6±5.3	28.7±9.2

Data are mean ± standard deviation.

changes,<sup>12</sup> but judging grade changes when modest amounts of swelling are present is difficult.

The absolute values or change from baseline for RNFL thickness, TRT, ONH volume, or RGCL plus IPL thickness at 6 months did not change with the clinical features relevant to IIH, which included high- or low-contrast visual acuity, PMD, CSF opening pressure, or the BMI at 6 months. This is similar to the findings of Skau et al,<sup>13</sup> who showed that the CSF pressure did not correlate with the OCT in 20 patients followed up for less than 1 month and approximately 5 years. Our results differed with those of Skau et al<sup>13</sup> and Rebolleda and Munoz-Negrete,<sup>14</sup> who showed that OCT swelling frequently resolves over months. In contrast, IIHTT eyes showed persistent, albeit reduced, OCT-measured peripapillary and ONH swelling in many eyes during the uniform 6-month follow-up.

The benefits of acetazolamide and weight loss on OCT swelling reduction could not be separated easily given that acetazolamide had an effect on weight outcome. Although IIHTT subjects who achieved the weight loss goal of at least 6% of the presentation weight at 6 months had reduced swelling by OCT, there was no direct correlation with BMI decrease and a reduction in swelling of the RNFL or total retina. This is similar to a prior report that followed up patients for 3 months,<sup>15</sup> suggesting that small amounts of weight loss has limited benefit in IIH. However, at least 1 report using retrospective data suggested that small amounts of weight loss could reduce IIH-associated findings.<sup>16</sup>

Optical coherence tomography assessments of swelling resulting from papilledema in IIH are improved with acetazolamide plus weight management and placebo plus weight management. In contrast to the strong correlation at baseline, 6-month RNFL thickness, TRT, and ONH volume showed only moderate correlations with papilledema grade. Treated IIH with mild vision loss is associated with minimal RGCL plus IPL thinning in most eyes. Optical coherence tomography is a useful procedure to monitor the consequences of papilledema resulting from intracranial hypertension and to measure the effects of therapy.

## References

- OCT Sub-Study Committee for the NORDIC Idiopathic Intracranial Hypertension Study Group. Baseline OCT Measurements in the Idiopathic Intracranial Hypertension

- Treatment Trial: Part I. Quality control, comparisons and variability. *Inv Ophthalmol Vis Sci* 2014;55:8173–9.
2. NORDIC Idiopathic Intracranial Hypertension Study Group. The Idiopathic Intracranial Hypertension Treatment Trial: a randomized trial of acetazolamide. *JAMA* 2014;311:1641–51.
  3. OCT Sub-Study Committee for the NORDIC Idiopathic Intracranial Hypertension Study Group. Baseline OCT Measurements in the Idiopathic Intracranial Hypertension Treatment Trial: Part II. Correlations and relationship to clinical features. *Inv Ophthalmol Vis Sci* 2014;55:8180–8.
  4. Wang JK, Kardon RH, Kupersmith MJ, Garvin MK. Automated quantification of volumetric optic disc swelling in papilledema using spectral-domain optical coherence tomography. *Invest Ophthalmol Vis Sci* 2012;53:4069–75.
  5. Garvin M, Abramoff M, Kardon R, et al. Intraretinal layer segmentation of macular optical coherence tomography images using optimal 3-D graph search. *IEEE Trans Med Imaging* 2008;27:1495–505.
  6. Frisén L. Swelling of the optic nerve head: a staging scheme. *J Neurol Neurosurg Psychiatr* 1982;45:13–8.
  7. Friedman D, McDermott M, Kieburtz K, et al; for the NORDIC IIHTT Study Group. The Idiopathic Intracranial Hypertension Treatment Trial (IIHTT): design considerations and methods. *J Neuro-Ophthalmol* 2014;34:107–17.
  8. Fischer W, Kieburtz K, Wall M, et al; for the NORDIC Idiopathic Intracranial Hypertension Study Group. Methods and baseline results for the photographic reading center of the Idiopathic Intracranial Hypertension Treatment Trial (IIHTT). *Invest Ophthalmol Vis Sci* 2015;56:3292–303.
  9. Mwanza J, Oakley J, Budenz D, Anderson D. Cirrus optical coherence tomography normative database study group. Ability of Cirrus HD-OCT optic nerve head parameters to discriminate normal from glaucomatous eyes. *Ophthalmology* 2011;118:241–8.
  10. Scott C, Kardon R, Lee A, et al. Diagnosis and grading of papilledema in patients with raised intracranial pressure using optical coherence tomography vs clinical expert assessment using a clinical staging scale. *Arch Ophthalmol* 2010;128:705–11.
  11. Vartin V, Nguyen A, Balmitgere T, et al. Detection of mild papilledema using spectral domain optical coherence tomography. *Br J Ophthalmol* 2012;96:375–9.
  12. Sinclair A, Burdon M, Nightingale P, et al. Rating papilloedema: an evaluation of the Frisén classification in idiopathic intracranial hypertension. *J Neurol* 2012;259:1406–12.
  13. Skau M, Yri H, Sander B, et al. Diagnostic value of optical coherence tomography for intracranial pressure in idiopathic intracranial hypertension. *Graefes Arch Clin Exp Ophthalmol* 2013;251:567–74.
  14. Rebolledo G, Munoz-Negrete F. Follow-up of mild papilledema in idiopathic intracranial hypertension with optical coherence tomography. *Inv Ophthalmol Vis Sci* 2009;50:5197–200.
  15. Skau M, Sander B, Milea D, Jensen R. Disease activity in idiopathic intracranial hypertension: a 3-month follow-up study. *J Neurol* 2011;258:277–83.
  16. Kupersmith MJ, Gamell L, Turbin R, et al. Effects of weight loss on the course of idiopathic intracranial hypertension in women. *Neurology* 1998;50:1094–8.

## Footnotes and Financial Disclosures

Originally received: December 31, 2014.

Final revision: May 22, 2015.

Accepted: June 2, 2015.

Available online: July 23, 2015.

Manuscript no. 2014-2124.

\*Members of the Optical Coherence Tomography Substudy Committee and the NORDIC Idiopathic Intracranial Hypertension Study Group are listed in the [Appendix](#) (available at [www.aaajournal.org](http://www.aaajournal.org)).

Financial Disclosure(s):

The author(s) have no proprietary or commercial interest in any materials discussed in this article.

Supported by the National Institutes of Health, Bethesda, Maryland (grant nos.: U10EY017281-01A1, U10EY017387-01A1, and 3U10EY017281-01A1S1).

Author Contributions:

Conception and design: Kupersmith, Sibony, Kardon, Durbin

Analysis and interpretation: Garvon, Wang, Kardon, Kupersmith

Data collection: Keltner, Werner, Plumb

Obtained funding: none

Overall responsibility: Feldon, Kupersmith, Durbin

Abbreviations and Acronyms:

**BMI** = body mass index; **CSF** = cerebrospinal fluid; **IIH** = idiopathic intracranial hypertension; **IIHTT** = Idiopathic Intracranial Hypertension Treatment Trial; **IPL** = inner plexiform layer; **OCT** = optical coherence tomography; **ONH** = optic nerve head; **PMD** = perimetric mean deviation; **RGCL** = retinal ganglion cell layer; **RNFL** = retinal nerve fiber layer; **SD** = spectral domain; **TRT** = total retinal thickness; **ZM** = Zeiss Meditec; **2-D** = 2-dimensional; **3-D** = 3-dimensional.

Correspondence: Mark J. Kupersmith, MD, Departments of Neurology and Ophthalmology, Icahn School of Medicine at Mount Sinai, NORDIC Headquarters, Mount Sinai Roosevelt Hospital, 1000 Tenth Avenue, New York, NY 10019. E-mail: [mkuper@chpnet.org](mailto:mkuper@chpnet.org).



## Appendix

### OCT Substudy Committee (all authors, alphabetically arranged) IIHTT

#### OCT Substudy Committee

Peggy Auinger, MS (University of Rochester School of Medicine & Dentistry, Rochester, NY), Mary Durbin, PhD (Zeiss-Meditec, Inc, Dublin, CA), Steven Feldon, MD, MBA (University of Rochester School of Medicine & Dentistry, Rochester, NY), Mona Garvin, PhD (University of Iowa, Iowa City, IA), Randy Kardon, MD, PhD (University of Iowa, Iowa City, IA), John Keltner, MD (University of California, Davis, CA), Mark Kupersmith, MD (OCT Principal Investigator, Mount Sinai Roosevelt Hospital and New York Eye and Ear Infirmary, NY, NY), Patrick Sibony, MD (Stony Brook University, Stony Brook, NY), Kim Plumb (University of California, Davis, CA), Jui-Kai Wang, MS (University of Iowa, Iowa City, IA), John S. Werner, PhD (University of California, Davis, CA)

### Acknowledgement List

**Steering Committee:** Michael Wall, MD (Principal Investigator) (University of Iowa), James Corbett, MD, FAAN (University of Mississippi Medical Center), Steven Feldon, MD, MBA (University of Rochester Eye Institute), Deborah Friedman, MD (UT Southwestern Medical Center), John Keltner, MD (UC Davis Medical Center), Karl Kiebertz, MD, MPH (University of Rochester School of Medicine & Dentistry), Mark Kupersmith, MD (Network Chair) (Roosevelt Hospital), Michael P. McDermott, PhD (University of Rochester School of Medicine & Dentistry), Eleanor B. Schron, PhD, RN, FAAN (Project Officer, National Eye Institute), David Katz, MD (Bethesda Neurology LLC), Tippi Hales (Raleigh Neurology Associates PA); Cindy Casaceli, MBA (University of Rochester School of Medicine & Dentistry)

**Substudy Sites:** New York Eye and Ear Infirmary: Rudrani Banik, MD (Principal Investigator), Sanjay Kedhar, MD (Sub-Investigator), Flora Levin, MD (Investigator), Jonathan Feistmann, MD (Investigator), Katy Tai, MA (Coordinator), Alex Yang, BA (Co-Coordinator), Karen Tobias, BA (Coordinator), Melissa Rivas, BA (Co-Coordinator), Lorena Dominguez, BA (Coordinator), Violette Perez, BA (Coordinator); University of Iowa and Department of Veterans Affairs: Reid Longmuir, MD (Principal Investigator), Matthew Thurtell, MBBS, MSc (Sub-Investigator), Trina Eden (Coordinator), Randy Kardon, MD, PhD (Sub-Investigator); The Eye Care Group: Robert Lesser, MD (Principal Investigator), Yanina O'Neil, MD (Sub-Investigator), Sue Heaton, BS, CCRC (Coordinator), Nathalie Gintowt (Co-Coordinator); Bascom Palmer Eye Institute, University of Miami: Byron L. Lam MD (Principal Investigator), Joshua Pasol MD (Sub-Investigator), Potyra R. Rosa MD (Coordinator), Alexis Morante MS (Co-Coordinator), Jennifer Verriotto MS (Coordinator); Bethesda Neurology, LLC: David Katz, MD (Principal Investigator), Tracy Asbury (Coordinator), Robert Gerwin,

MD (Sub-Investigator), Mary Barnett (Data Entry); Swedish Medical Center: Steven Hamilton, MD (Principal Investigator), Caryl Tongco (Coordinator), Beena Gangadharan (Co-Coordinator), Eugene May, MD (Sub-Investigator); Dean A. McGee Eye Institute: Anil Patel, MD (Principal Investigator), Bradley Farris, MD (Sub-Investigator), R. Michael Siatkowsk, MD (Sub-Investigator), Heather Miller, LPN (Coordinator), Vanessa Bergman (Co-Coordinator), Kammerin White (Coordinator), Steven O'Dell (Lumbar Puncture), Joseph Andrezik (Lumbar Puncture), Timothy Tyle (Lumbar Puncture); University of Pennsylvania: Kenneth Shindler MD, PhD (Principal Investigator), Joan Dupont (Coordinator), Rebecca Salvo (Coordinator), Sheri Drossner (Co-Coordinator), Susan Ward (Coordinator), Jonathan Lo (Coordinator), Stephanie Engelhard (Coordinator), Elizabeth Windsor (Coordinator), Sami Khella (Lumbar Puncture), Madhura Tamhankar, MD (Sub-Investigator); Washington University in St. Louis School of Medicine: Gregory Van Stavern, MD (Principal Investigator), Jamie Kambarian (Coordinator), Renee Van Stavern, MD (Sub-Investigator), Karen Civitelli (Regulatory), J. Banks Shepherd, MD (Sub-Investigator); University of Alabama Birmingham: Michael Vaphiades, DO (Principal Investigator), Jason Swanner, MD (Investigator), A. Blane Jett (Coordinator), Karen Searcey (Coordinator), Frankie Webb (Coordinator), Ashley Knight, BA (Coordinator), Shereka Lewis, BS (Coordinator), Lanning Kline, MD (Sub-Investigator), Ronald Braswell, MD (Sub-Investigator); Raleigh Neurology Associates, PA: Syndee J. Givre, MD, PhD (Principal Investigator), Tippi Hales (Coordinator), Penni Bye (Coordinator), Keisha Fuller (Coordinator), Kenneth M. Carnes, MD, (Sub-Investigator), Kimberly James (Regulatory), Marisol Ragland (Data Entry); Saint Louis University: Sophia M. Chung, MD (Principal Investigator), Dawn M. Govreau, COT (Coordinator), John T. Lind, MD, MS (Sub-Investigator); University of Rochester Eye Institute: Zoe Williams, MD (Principal Investigator), George O'Gara (Coordinator), Kari Steinmetz (Coordinator), Mare Perevich (Coordinator), Karen Skrine (Coordinator), Elisabeth Carter (Coordinator), Rajeev Ramchandran, MD (Sub-Investigator); Ohio State University: Steven Katz, MD (Principal Investigator), Marc Criden, MD (Investigator), Gina Coman, RMA, CPC, OCS (Co-Coordinator), John McGregor, FACS, MD, (Sub-Investigator), Andrea Inman (Regulatory); Johns Hopkins University: Prem S. Subramanian, MD, PhD (Principal Investigator), Paul N. Hoffman, MD, PhD (Investigator), Marianne Medura (Coordinator), M. Michaele Hartnett (Coordinator), Madiha Siddiqui (Coordinator), Diane Brown (Coordinator), Ellen Arnold (Coordinator), Jeff Boring, MD (Sub-Investigator), Neil R. Miller, MD (Sub-Investigator); University of Southern California: Peter Quiros, MD (Principal Investigator), Sylvia Ramos (Coordinator), Margaret Padilla (Coordinator), Lupe Cisneros (Coordinator), Anne Kao, MD (Sub-Investigator), Carlos Filipe Chicani, MD (Sub-Investigator), Kevin Na (Regulatory); University of Houston: Rosa Tang, MD, MPH, MBA (Principal Investigator), Laura Frishman, PhD (Coordinator), Priscilla Cajavilca, MD (Coordinator), Sheree Newland, LVN (Coordinator), Liat Gantz, OD, PhD

(Coordinator), Maria Guillermo Prieto, MD (Coordinator), Anastas Pass, OD, JD (Coordinator), Nicky R. Holdeman, OD, MD (Sub-Investigator); University of Calgary: William Fletcher, MD, FRCPC (Principal Investigator), Suresh Subramaniam, MSc, MD, FRCPC (Investigator), Jeannie Reimer (Coordinator), Jeri Nickerson (Coordinator), Fiona Costello, MD, FRCPC (Sub-Investigator); The Greater Baltimore Medical Center: Vivian Rismondo-Stankovich, MD (Principal Investigator), Maureen Flanagan, CO, COA (Coordinator), Allison Jensen, MD (Sub-Investigator); Stony Brook University: Patrick Sibony, MD (Principal Investigator), Ann Marie Lavorna, RN (Coordinator), Mary Mladek, COT (Coordinator), Ruth Tenzler, RN (Coordinator), Robert Honkanen, MD (Sub-Investigator), Jill Miller-Horn, MD, MS (Lumbar Puncture), Lauren Krupp, MD (Lumbar Puncture); Massachusetts Eye and Ear Infirmary: Joseph Rizzo, MD (Principal Investigator), Dean Cestari, MD (Sub-Investigator), Neal Snebold, MD (Investigator), Brian Vatcher (Coordinator), Christine Matera (Coordinator), Edward Miretsky, BA (Coordinator), Judith Oakley, BA (Coordinator), Josyane Dumser (Coordinator), Tim Alperen, BA (Coordinator), Sandra Baptista-Pires (Coordinator), Ursula Bator, OD (Coordinator), Barbara Barrett, RN (Coordinator), Charlene Callahan (Coordinator), Sarah Brett (Coordinator), Kamella Zimmerman (Coordinator), Marcia Grillo (Coordinator), Karen Capaccioli (Coordinator); Duke Eye Center and Duke University Medical Center: M. Tariq Bhatti MD (Principal Investigator), LaToya Greene COA,CRC (Coordinator), Maria Cecilia Santiago-Turla (Coordinator), Noreen McClain (Coordinator), Mays El-Dairi MD (Sub-Investigator); Florida State University College of Medicine: Charles Maitland, MD (Principal Investigator), H. Logan Brooks, Jr., MD (Investigator), Ronda Gorsica (Coordinator), Brian Sherman, MD (Sub-Investigator), Joel Kramer, MD (Sub-Investigator); William Beaumont Hospital: Robert Granadier, MD (Principal Investigator), Tammy Osentoski, RN (Coordinator), Kristi Cumming, RN (Coordinator), Bobbie Lewis, RN (Coordinator), Lori Stec, MD (Sub-Investigator)

**Dietary Weight Loss Program:** Betty Kovacs, Richard Weil, MD, CDE, Xavier Pi-Sunyer, MD (New York Obesity Nutrition Research Center)

**Fundus Reading Center:** Steven Feldon, MD, MBA, William Fisher, Dorothea Castillo, Valerie Davis, Lourdes Fagan, Rachel Hollar, Tammy Keenan, Peter MacDowell (University of Rochester Eye Institute)

**Visual Reading Field Center:** John Keltner, MD, Kim Plumb, Laura Leming, (UC Davis Department of Ophthalmology & Vision Science), Chris Johnson, PhD (University of Iowa)

**Optical Coherence Tomography Reading Center:** John Keltner, MD, John S. Werner, PhD, Kim Plumb, Laura Leming (UC Davis Department of Ophthalmology & Vision Science), Danielle Harvey, PhD (UC Davis Department of Public Health Sciences, Division of Biostatistics)

**Data Coordination & Biostatistics Center:** Jan Bausch, BS, Shan Gao, MS, Xin Tu, PhD (Biostatistics); Debbie Baker, Deborah Friedman, MD, MPH (Medical Monitor), Karen Helles, Nichole McMullen, Bev Olsen, Larry Preston, Victoria Snively, Ann Stoutenburg (CHET/CTCC) (University of Rochester School of Medicine & Dentistry)

**NORDIC Headquarters:** O. Iyore Ayanru, Elizabeth-Ann Moss, Pravin Patel (Roosevelt Hospital)

**Consultant:** Richard Mills, MD (Glaucoma Consultants Northwest)

**Data Safety Monitoring Board Members:** Maureen Maguire, PhD (Chair) (University of Pennsylvania), William Hart, Jr., MD, PhD, Joanne Katz, ScD, MS (Johns Hopkins), David Kaufman, DO (Michigan State University), Cynthia McCarthy, DHCE MA, John Selhorst, MD (Saint Louis University School of Medicine)

**Adjudication Committee:** Kathleen Digre, MD (University of Utah); James Corbett, MD, FAAN (University of Mississippi Medical Center); Neil R. Miller, MD (Johns Hopkins University); Richard Mills, MD (Glaucoma Consultants Northwest)