

*SA Boyadjiev
for the International
Craniosynostosis Consortium*

Genetic analysis of non-syndromic craniosynostosis

Author's affiliation:

Simeon A. Boyadjiev, Section of Genetics,
Department of Pediatrics, University of
California, Davis, Sacramento, CA, USA

Correspondence to:

S. A. Boyadjiev
M.I.N.D. Institute
University of California
2825 50th Street
Sacramento
CA 95817, USA
E-mail: simeon.boyd@ucdmc.ucdavis.edu

Structured Abstract

Author – Simeon A. Boyadjiev

Craniosynostosis is a common malformation occurring in 3–5 per 10 000 live births. Most often craniosynostosis occurs as an isolated (i.e. non-syndromic) anomaly. Non-syndromic craniosynostosis (NSC) is a clinically and genetically heterogeneous condition that has the characteristics of a multifactorial trait. It is believed that each sutural synostosis (e.g. sagittal, coronal) represents a different disease. Significant progress has been made in understanding the clinical and molecular aspects of monogenic syndromic craniosynostosis. However, the phenotypic characterization of NSC is incomplete and its causes remain unknown. This review summarizes the available knowledge on NSC and presents a systematic approach aimed at the identification of genetic and non-genetic factors contributing to the risk of this common craniofacial defect.

Key words: FGFR; TWIST; craniosynostosis; craniofacial; birth defects

Introduction

Craniosynostosis occurs in all racial groups and more than 85% of all cases are non-syndromic (1). Non-syndromic craniosynostosis (NSC) is believed to have a strong genetic component with possible gene–gene or gene–environment interactions that remain to be identified (1,2). When associated anomalies or delay are present the possibility of a monogenic syndrome should be considered. Recent studies have found an unexpectedly high incidence of medical problems among children with NSC, such as increased intracranial pressure (ICP) (3–5), learning disabilities in sagittal craniosynostosis (6, 7), strabismus and amblyopia in coronal craniosynostosis (8), and Chiari I malformation in metopic craniosynostosis (9). However, these associations remain to be confirmed. The true incidence of associated anomalies in NSC is unknown as most of these studies are retrospective, use small samples, and are based on incomplete clinical evaluations. Thus, there is much to be learned about the frequency and severity of the involvement of different organ systems, the extent and the causes of the clinical variability, and the natural progression of NSC.

Dates:

Accepted 11 March 2007

To cite this article:

Boyadjiev SA:
Genetic analysis of non-syndromic
craniosynostosis
Orthod Craniofacial Res 10, 2007; 129–137

Copyright © 2007 The Author.
Journal compilation © 2007 Blackwell Munksgaard

The existing gap in our knowledge can be explained by several factors: 1) it is difficult to recruit a sufficiently large craniosynostosis population. The number of NSC cases that are available for comprehensive evaluation at any one center is limited; 2) many of these patients do not undergo systematic clinical evaluation and are not enrolled in well-designed clinical studies; and 3) there is clinical overlap between NSC and mild or atypical patients with Crouzon, Saethre-Chotzen and Muenke syndromes (10, 11).

We have initiated collaboration among leading medical institutions to accrue families with at least one individual with NSC. The clinical characterization of probands and other affected family members is conducted in a highly organized and detailed fashion using standardized evaluation protocols, three-dimensional head computed tomography (3D-CT), magnetic resonance images (MRI), and 3dMD photogrammetry of the face (indirect anthropometry). Collaborators and practicing physicians are contributing to this large scale effort by referring their patients to a study website hosted on the secure server of the General Clinical Research Center (GCRC) of the Johns Hopkins University (<https://gcrc-s1.win.ad.jhu.edu/cranio/index.cfm>). It provides a user friendly interface for collection of clinical and epidemiological information through study forms and questionnaires that can be completed by research personnel or by study participants. As a result of this collaborative effort > 380 families with at least one individual with craniosynostosis have been

already recruited and characterized. The existing clinical databases and sample repositories are being used for better understanding of the etiology, pathogenesis, and prognosis of craniosynostosis.

Epidemiology and clinical characteristics of NSC

The most common causes of cranial asymmetry are positional plagiocephaly and true craniosynostosis. The clinical, morphological, radiologic, and molecular evaluation of a child with an asymmetric skull should allow the differentiation between these groups. True craniosynostosis may involve different calvarial sutures producing distinct skull deformities (Fig. 1). As a whole, about 8% of the NSC cases are familial (multiplex) (1). The familial cases are usually consistent with autosomal dominant transmission and exhibit significant intrafamilial variability. The differences in phenotypic manifestation, population incidence, proportion of familial cases, and male-female ratios indicate that each type of sutural synostosis (e.g. sagittal, coronal, etc.) represents a separate noseologic entity. This implies that a distinct set of etiologic factors, both genetic and environmental, determines the type of sutural synostosis.

There are indications that intrauterine head constraint causes NSC (1, 12, 13). However, constraint does not always result in craniosynostosis, suggesting that additional, likely genetic factors are also required. A recent report that a pharmaceutical agent prevents craniosynostosis by uncoupling the mutant FGFR2 receptor

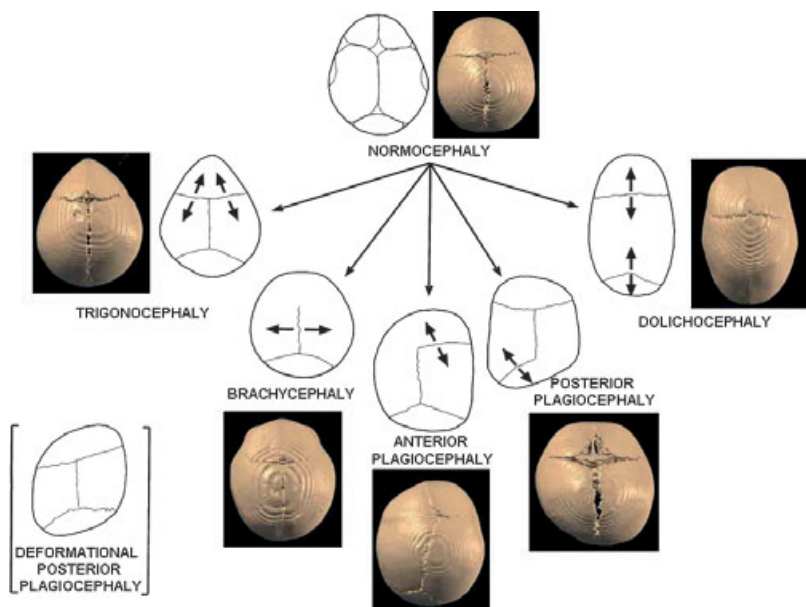


Fig. 1. Schematic presentation of the calvarial sutures and the skull deformities resulting from synostosis of a particular suture. The arrows indicate the direction of skull growth. 3D-CT images of patients illustrate types of craniosynostosis (modified from (1); 3D-CT images courtesy of J. Marsh and J. Panchal).

from its downstream target *FRS2* brings therapeutic intervention for craniosynostosis closer to reality (14).

Sagittal craniosynostosis

This is the most common type of craniosynostosis and shows strong male prevalence (M:F ratio of 3.5:1). It accounts for 40–58% of all craniosynostosis cases and has an estimated birth prevalence of 1.9–2.3 per 10 000 live births (15, 16). About 2% of sagittal synostosis cases are familial (16). The fusion of the sagittal suture results in dolichocephaly, which is objectively documented by a cephalic index below 75 (maximal head breadth \times 100/maximal head length). Twinning, increased parity, maternal smoking, and intrauterine head constraint have been suggested as risk factors (12, 17). Retrospective clinical characterization of 214 patients with sagittal synostosis found major malformations in 22% of the cases (15).

Coronal craniosynostosis

Unilateral (anterior plagiocephaly) or bilateral (brachycephaly) fusion of the coronal suture is the second most common form of craniosynostosis. It accounts for 20–30% of all NSC cases and has an estimated incidence of 0.8–1 in 10 000 live births with 60–75% of those affected being females (18, 19). About 8–10% of coronal synostosis patients have a positive family history. Unilateral coronal craniosynostosis should be differentiated clinically from positional plagiocephaly. Progressive frontal plagiocephaly can also result from fusion of the frontosphenoidal or frontozygomatic sutures and this mandates detailed 3D-CT imaging with 1-mm cuts of the basilar coronal ring sutures in plagiocephalic patients with open coronal sutures (20, 21). The higher proportions of familial cases and the suggested increase in average paternal age may indicate a stronger genetic component to coronal than to sagittal NSC. Special clinical attention and/or targeted *FGFR3* P250R and *TWIST* analyses are needed to differentiate true coronal NSC from mild cases of Muenke and Saethre–Chotzen syndromes.

Metopic craniosynostosis

This has a reported incidence of 1 per 10 000–15 000 births (1, 22) and results in trigonocephaly. It accounts for approximately 14% of all craniosynostosis cases and has a male:female ratio of 3.3:1 (22). Trigonocephaly presents as an isolated anomaly in approximately 70%

of the cases and the recurrence risk is 3.2% (23). The hypothesis of multifactorial inheritance is reinforced by Lajeunie's data on twins with non-syndromic trigonocephaly, as the heritability (h^2) for this trait was 0.4 (22). In contrast, an autosomal dominant transmission has been suggested for the familial metopic NSC that comprises up to 10% of the cases (23). Trigonocephaly can also be a feature of more than 20 dysmorphic syndromes, such as Opitz C and Jacobsen syndromes. There is convincing evidence that fetal exposure to sodium valproate is associated with trigonocephaly (24). An important, perhaps life-threatening consequence of metopic craniosynostosis is the Chiari I malformation that has been documented in 30% of patients with metopic ridges (9). These authors suggested that 3D-CT imaging of all children with metopic ridges would decrease the risk of hindbrain hernia.

Lambdoid craniosynostosis

This is the least common type of craniosynostosis accounting for only 3.1% of all NSC cases (25). In bilateral lambdoid synostosis the entire occipital region is flattened and widened. Most cases of lambdoid craniosynostosis are unilateral and result in asymmetric posterior plagiocephaly that needs to be differentiated from positional plagiocephaly. These two conditions pose a significant diagnostic dilemma that requires careful clinical and radiologic differentiation and different therapeutic approaches. 3D-CT proved to be the most useful modality for documenting lambdoid fusion because lambdoid sutures are not readily visualized on skull radiographs and routine CT study may not detect partial sutural fusion (26). In cases of severe and progressive plagiocephaly with open lambdoid sutures, synostoses of the asterion region (27) or the mendosal suture (28) have to be excluded by detailed 3D-CT. Associations of lambdoid synostosis with intrauterine constraint, pre-term labor, and male gender have been suggested (29).

Multiple suture craniosynostosis

This accounts for approximately 5% of NSC. It is clinically separated into two groups: two-suture disease and complex craniosynostosis with fusion of more than two sutures. No significant differences were found between patients with single suture fusion and those with two-suture fusion except for the higher rate of reoperation –25% vs. 5%. Complex craniosynostosis

frequently causes increased ICP and developmental delay and the rate of reoperation is 37% (2). Increased ICP was present in two-thirds of the patients with coronal and sagittal suture fusion and 12 of 16 patients had Chiari I anomaly on MRI (30). Normal fundoscopy was documented in 64% of the patients with increased ICP suggesting the need for 3D-CT.

Genetics of non-syndromic craniosynostosis

Sagittal craniosynostosis

The genetic basis of non-syndromic sagittal craniosynostosis remains unclear. No mutations in *FGFR1-3*, or *TWIST* were found in >100 patients, suggesting that mutations in the hotspots of the genes causing syndromic craniosynostosis are unlikely to cause sagittal NSC (31, 32). A *FGFR2* mutation A315T was found in one of 29 patients with isolated sagittal craniosynostosis (33).

Coronal craniosynostosis

A P250R mutation in *FGFR3* was identified in patients with presumably non-syndromic coronal craniosynostosis (34) that were later categorized as having Muenke syndrome (35). Analysis of 26 patients with coronal craniosynostosis found this mutation in 31% of the cases (36). On the basis of statistical analysis, these investigators suggest that up to 52% of all cases with coronal synostosis may have this mutation. It may be difficult to differentiate the patients with Muenke syndrome from true coronal NSC on the basis of clinical evaluation alone, thus targeted *FGFR3* P250R mutation analysis is justified in patients with coronal craniosynostosis. A novel *FGFR2* A315S mutation was reported in a patient with right unicoronal craniosynostosis born from a pregnancy complicated by breech presentation and skull compression (37). Both the patient's mother and maternal grandfather carried the mutation and had mild facial asymmetry but no craniosynostosis, suggesting that the mutation pre-disposes individuals to synostosis in the presence of intrauterine constraint. Recently, mutations in *EFNA4* were reported in rare patients with non-syndromic coronal craniosynostosis (38).

Metopic craniosynostosis

An unusual *FGFR1* I300W mutation in a girl with non-syndromic metopic fusion who had two facial

skin tags, but no other anomalies has been reported (39). The mutation was not present in the mother's DNA and in 300 control chromosomes. While specific gene mutations for metopic synostosis have yet to be identified, a number of cytogenetic abnormalities have been associated with syndromic trigonocephaly. These include deletion of chromosome 11q24 (40), trisomy or deletion of 9p (41), deletion of 7p (42), and other less common anomalies. Since these rearrangements can be subtle, a telomeric FISH screening is indicated for complex cases with trigonocephaly.

Lambdoid craniosynostosis

The genetic basis of this condition is unknown. Only two familial cases have been described (43) and rare patients with chromosomal rearrangements have been reported (44, 45).

Multiple suture craniosynostosis

Fusion of multiple sutures is more difficult to explain by uterine constraint and is more likely to result from genetic mutation. In complex craniosynostosis, the skull is more severely distorted. The chances of a syndromic diagnosis are higher among this group of patients (1).

Syndromic craniosynostosis

Proper analysis of NSC can not be accomplished without consideration of the less common but much better characterized craniosynostosis syndromes. Approximately 15% of all craniosynostosis cases present with associated anomalies involving mainly the face and the limbs and are considered to be syndromic (2). More than 180 syndromes manifest craniosynostosis and at least half of them follow Mendelian patterns of inheritance (London Dysmorphology Database, http://www.lmdatabases.com/about_lmd.html). Significant progress in understanding the genetic basis of some craniosynostosis syndromes has occurred during the past decade. Mutations in *FGFR1*, *FGFR2*, and *FGFR3* were found in patients with Crouzon, Jackson-Weiss, Pfeiffer, Apert, and Beare-Stevenson syndromes (46, 47). Identical *FGFR2* mutations (e.g. C278F, G298P, and C342T) have been found in patients carrying the diagnosis of Crouzon, Pfeiffer, and Jackson-Weiss craniosynostosis syndromes, suggesting

that these entities represent a clinical spectrum of the same genetic disorder with possible effect of genetic modifiers (46, 48, 49). An identical FGFR2 mutation has even been found in unrelated patients with Pfeiffer and Apert syndromes (50). It has also been shown that the same phenotype can be caused by mutations in different genes as in the cases of Pfeiffer syndrome that are due to FGFR1 and FGFR2 mutations (19, 48). Despite these reports, an astute observer should keep in mind the possibility of clinical misclassification, due to atypical patients with overlapping features or, less likely, errors in clinical judgment. The majority of Saethre–Chotzen syndrome cases are due to mutations in TWIST (19, 48, 51, 52). Boston type craniosynostosis due to MSX2 P148H mutation has been described in a single family with variable phenotype ranging from metopic ridging to cloverleaf skull and digital abnormalities (53). Baller–Gerold syndrome, a rare autosomal recessive condition with radial aplasia/hypoplasia and craniosynostosis has been associated with mutations in RECQL4 (54).

Careful clinical characterization of presumed NSC patients could identify a subset of patients with associated anomalies and/or developmental delay that do not fit into a recognizable syndrome and possibly represent novel syndromes. It is important to emphasize that mild and/or atypical syndromic cases, especially of Muenke and Saethre–Chotzen syndromes, may mimic coronal NSC. This necessitates targeted mutation analysis of FGFR3 and TWIST genes. Many DNA diagnostic laboratories offer these genetic tests (<http://www.geneclinics.org/>). Such syndromic cases should be excluded from further

clinical, morphometric, and molecular studies of NSC.

Clinical analysis of the already recruited NSC probands

As a result of our ongoing research protocol we have already performed clinical assessment of 189 NSC families with 605 individuals total and part of the information is summarized in Table 1. While the groups with synostosis of a particular suture are still small for meaningful clinical conclusions, the emerging picture indicates that the different types of craniosynostosis have different characteristics and are likely to represent etiologically different defects.

Morphometric analysis of NSC

In addition to collecting and analyzing clinical and epidemiologic data, we have created a library of soft-tissue surface scans obtained through photogrametric 3dMD technology, as well as digital files of patients’ head CT scans for 3D reconstruction and morphometric analysis (Fig. 2). As a first step in our analysis, we have validated the 3dMD technology and shown a very high degree of correlation between direct and indirect anthropometry (55). 3D-CT files were used for assessment of brain morphology in non-syndromic unicoronal craniosynostosis and brain changes not localized to structures immediately adjacent to the fused suture were identified. Although the morphologic phenotypes of the craniosynostosis skulls have been relatively well characterized, these observations of subtle brain abnormalities indicate that the

Table 1. Clinical characteristics of 189 cases of non-syndromic craniosynostosis patients

Suture fusion	Total number (%)	Developmental delay (%)	Associated anomalies (%)	Sex (M:F) ratio	Familial cases (%)	Involvement in multiple CS (%)	
						Two sutures	Complex
Sagittal	81 (43)	10	9	3.1:1	4	40	80
Unicoronal	21 (11)	33	14	2.5:1	–	54	82
Metopic	26 (10)	28	12	3.2:1	20	26	67
Unilambdoid	13 (7)	23	23	3.3:1	23	31	82
Multiple CS	48 (25)						
Two sutures	34	19	20	1.1:1	14		
Complex	14	53	20	1.1:1	13		

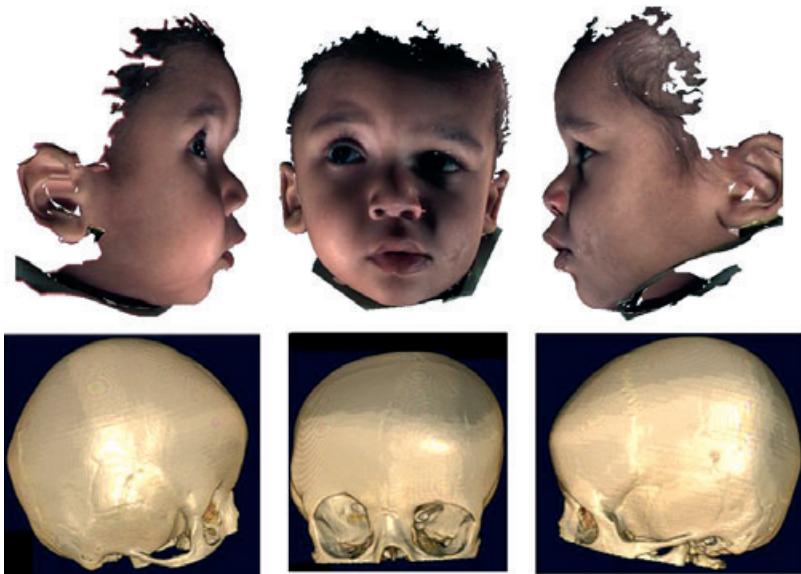


Fig. 2. Pre-operative 3dMD (top row) and corresponding 3D-CT (bottom row) images of a patient with anterior plagiocephaly due to right coronal craniosynostosis provide opportunity for precise morphometric evaluation of soft tissue and underlying skull landmarks.

craniosynostosis is not only a disease of the suture, but of the whole complex system of brain, dura, and skull (56, 57). The relationship between these brain phenotypes and the cognitive and behavioral profile of craniosynostosis is yet to be established. It is highly likely that the cognitive profile of NSC is a direct reflection of the unrecognized increased ICP and/or changes in the brain. Indeed, increased ICP was present in two-thirds of the patients with coronal and sagittal suture fusion followed by Renier *et al.* (30). The prevalence, nature, and severity of complications and the developmental outcome of craniosynostosis, even in cases of currently accepted optimal treatment, remain unclear. Much of the existing reports on cognitive skills of children with craniosynostosis are contradictory and difficult to interpret due to methodological limitations (6). Prospective longitudinal studies of a large group of NSC will help to address these important issues and we have already established the necessary infrastructure to create these resources.

Molecular studies of non-syndromic craniosynostosis

The molecular analysis of the NSC DNA samples collected by our group follows several steps. First, syndromic craniosynostosis cases are excluded by hot-spot mutation analysis for syndromic craniosynostosis (FGFR1 exon IIIa, FGFR2 exons IIIa and IIIc, FGFR3 exon IIIa, and the entire coding sequence of TWIST). Table 2 summarizes our findings. Our results suggest that 1) targeted FGFR3 P250R and complete TWIST

Table 2. Hot-spot molecular analysis of 161 craniosynostosis patients

Craniosynostosis	Number of tested	Mutations (number of cases)
Sagittal	81	None
Coronal	21 (4)*	FGFR3 P250R (2 cases), TWIST P139L (1), TWIST 433_455del23 (1)
Lambdoid	14	None
Metopic	13	TWIST G67A, normal variant
Multiple sutures	32 (2)*	FGFR3 P250R (2)

Hot-spot analysis of the remaining probands is in progress. *Numbers in parentheses indicate individuals with syndromic mutations.

sequencing analysis is indicated for all patients with coronal CS; 2) no clinical molecular testing is indicated for patients with isolated sagittal craniosynostosis.

Candidate genes direct sequencing analysis

In the second tier of analysis patients with non-syndromic sagittal CS were screened for mutations in the entire coding regions of 11 candidate genes – FGFR1, FGFR2, FGFR3, TWIST1, TWIST2, MSX2, FGFR1, SNAIL, SLUG, NELL1, and RUNX2. No non-synonymous single nucleotide polymorphisms (nsSNP) were found in FGFR1, FGFR2, FGFR3, TWIST, TWIST2, and SLUG. Several nsSNP were identified in MSX2, FGFR1, and SNAIL, but were also present in unaffected controls and their significance remains unclear. Several rare familial nsSNPs were identified in RUNX2 and NELL1 and are

being evaluated as disease pre-disposing variants. In addition, TWIST2 was sequenced and no mutations were identified among patients with coronal, metopic, and lambdoid NSC. This study represents the first large scale systematic sequencing effort to identify mutations among patients with sagittal NSC. The results of the analysis of these high-priority candidate genes clearly demonstrate that a strategy more efficient and less expensive than direct sequencing needs to be adopted for the identification of genes contributing to the risk of NSC.

Association analysis of NSC

The availability of the entire human genome sequence provided a wealth of genetic markers and our next goal is to perform large scale association analysis of NSC to identify genes for detailed genetic and functional analysis. We have completed the SNP genotyping and association analysis of 89 case-parent trios with non-syndromic sagittal craniosynostosis. This required genotyping of 384 SNPs in or around 60 genes selected as primary NSC candidates on the basis of their expression pattern, biological function, involvement in craniosynostosis phenotypes in humans and in animal models, or putative associations established in a previous exploratory round of genotyping. Associations were established with ALX 4 (rs1828656, $p = 0.0091$; rs1869480, $p = 0.0091$), NELL1 (rs951199, $p = 0.002$; rs752088, $p = 0.008$), and FGFR2 (rs3135758, $p = 0.018$). We also observed putative associations with FGF2 (rs308402, $p < 0.04$), FGF8 (rs1008013, $p < 0.045$) and RUNX2 (rs2396441, $p < 0.03$). We are corroborating these associations with additional families and markers and will perform detailed analysis of the genes that show reproducible associations with sagittal NSC.

Our current data indicate that upregulation of the FGFR-mediated intracellular signaling pathway is likely to play a role in the etiology of NSC. This upregulation is likely to be caused by DNA variants of different interacting members of the FGFR developmental cascade. Most likely DNA variants with major effects cause single-gene (Mendelian) craniosynostosis (35), whereas NSC results from the combinatorial effect of several variants with modest individual effects and may also require environmental influences.

With the development of the HapMap (58) project and the accumulation of millions of informative markers, the opportunity for whole genome association

mapping has become feasible and we plan to adjust our study protocol accordingly. We are aware that it is more challenging to demonstrate the functional significance of the associated polymorphism than to prove its association. We have a clear conceptual plan on how to approach this task through computational and genomic analysis and functional cell-based assays.

Summary

The number of NSC cases that are available for comprehensive evaluation at any one center is limited. Therefore, we have established a collaborative effort among leading medical institutions to enroll sufficiently large study population. An invitation for collaboration is being extended to both physicians and researchers with similar interests. Systematic evaluation of a large group of carefully categorized patients will allow the unbiased ascertainment of the clinical and anthropometric features of specific sutural synostosis and their phenotypic variability. The accumulation of varied data sets from well-characterized, clinically homogeneous populations, and a specimen repository from NSC families will create the research resources needed to find the genes associated with NSC by candidate gene or whole-genome association studies. Identification of these genes will be the first step toward understanding the biological mechanisms of premature sutural synostosis and will suggest targets for better treatment and/or prevention of this birth defect.

Authorship: The research approaches and the data presented in this review are results of extensive collaborations with the following investigators of the International Craniosynostosis Consortium: James Boggan, Craig Senders, Travis Tollefson, Granger Wong and Christopher Nauta (University of California, Davis); Alan Scott, George Jallo, Benjamin Carson, Craig Vander Kolk, Doris Lin, Davis Cutler, Ethylin Wang Jabs, Sara Lewis, and Terri Beatty (Johns Hopkins University, Baltimore); John Meara, John Mulliken, and Caroline Robson (Children's Hospital, Boston); Virginia Kimonis (University of California, Irvine); Kristina Aldridge (University of Missouri); Joan Richtsmeier (Pennsylvania State University); Jeffrey Marsh and Alex Kane (Washington University in St Louis); Jayesh Panchal (University of Oklahoma); Michael Cunningham (University of Washington, Seattle); Andrew Wilkie (Oxford University, UK); Fernanda Jehee and Maria Passos-Bueno (Sao Paulo University, Brazil); and Bernd Wallnik (University of Cologne, Germany).

Acknowledgements: The research website was developed and is maintained by David Holmack and Richard Zhu (GCRC, the Johns Hopkins University). Special thanks to all referring physicians and participating families for donating their time, effort, and samples. SAB is partially funded through a Children's Miracle Network Endowed Chair and through grants K23 DE00462, R03 DE016342, and R01 DE016886 from NIDCD/NIH and M01-RR00052 from NCRN/NIH.

References

- Cohen MJ. *Craniosynostosis: Diagnosis, Evaluation, and Management*. New York: Oxford University Press; 2000.
- Chumas P, Cinalli G, Arnaud E, Marchac D, Renier D. Classification of previously unclassified cases of craniosynostosis. *J Neurosurg* 1997;86:177–81.
- Thompson DN, Harkness W, Jones B, Gonzalez S, Andar U, Hayward R. Subdural intracranial pressure monitoring in craniosynostosis: its role in surgical management. *Childs Nerv Syst* 1995;11:269–75.
- Thompson DN, Malcolm GP, Jones BM, Harkness WJ, Hayward RD. Intracranial pressure in single-suture craniosynostosis. *Pediatr Neurosurg* 1995;22:235–40.
- Shimoji T, Tomiyama N. Mild trigonocephaly and intracranial pressure: report of 56 patients. *Childs Nerv Syst* 2004;749–56.
- Shipster C, Hearst D, Somerville A, Stackhouse J, Hayward R, Wade A. Speech, language, and cognitive development in children with isolated sagittal synostosis. *Dev Med Child Neurol* 2003;45:34–43.
- Magge S, Westerveld M, Pruzinsky T, Persing J. Long-term neuropsychological effects of sagittal craniosynostosis on child development. *J Craniofac Surg* 2002;13:99–104.
- Gupta P, Foster J, Crowe S, Papay F, Luciano M, Traboulsi E. Ophthalmologic findings in patients with nonsyndromic plagiocephaly. *J Craniofac Surg* 2003;14:529–32.
- Tubbs R, Elton S, Blount J, Oakes W. Preliminary observations on the association between simple metopic ridging in children without trigonocephaly and the Chiari I malformation. *Pediatr Neurosurg* 2001;35:136–9.
- Paznekas W, Cunningham M, Howard T, Korf B, Lipson M et al. Genetic heterogeneity of Saethre-Chotzen syndrome, due to TWIST and FGFR mutations. *Am J Hum Genet* 1998;62:1370–80.
- Chun K, Teebi A, Jung J, Kennedy S, Laframboise R et al. Genetic analysis of patients with the Saethre-Chotzen phenotype. *Am J Med Genet* 2002;110:136–43.
- Graham JJ. Craniofacial deformation. *Balliere's Clin Paediatr* 1998;6:293–315.
- Koskinen-Moffett LK, Moffett BC, Jr., Graham JM, Jr. Cranial Synostosis and intra-uterine compression: a developmental study of human sutures. *Prog Clin Biol Res* 1982;101:365–78.
- Eswarakumar VP, Ozcan F, Lew ED, Bae JH, Tome F et al. Attenuation of signaling pathways stimulated by pathologically activated FGF-receptor 2 mutants prevents craniosynostosis. *Proc Natl Acad Sci U S A* 2006;103:18 603–8.
- Hunter A, Rudd N. Craniosynostosis. I. Sagittal synostosis: its genetics and associated clinical findings in 214 patients who lacked involvement of the coronal suture(s). *Teratology* 1976;14:185–93.
- Lajeunie E, Merrer ML, Bonaiti-Pellie C, Marchac D, Renier D. Genetic study of scaphocephaly. *Am J Med Genet* 1996;62:282–5.
- Kallen K. Maternal smoking and craniosynostosis. *Teratology* 1999;60:146–50.
- Hunter A, Rudd N. Craniosynostosis II. Coronal synostosis: Its familial characteristics and associated clinical findings in 109 patients lacking bilateral polysyndactyly or syndactyly. *Tetraology* 1977;15:301–10.
- Lajeunie E, Merrer ML, Bonaiti-Pellie C, Marchac D, Renier D. Genetic study of nonsyndromic coronal craniosynostosis. *Am J Med Genet* 1995;55:500–4.
- Rogers G, Proctor M, Mulliken J. Unilateral fusion of the fronto-sphenoidal suture: a rare cause of synostotic frontal plagiocephaly. *Plast Reconstr Surg* 2002;110:1011–21.
- Currarino G. Premature closure of the frontozygomatic suture: unusual frontoorbital dysplasia mimicking unilateral coronal synostosis. *AJNR Am J Neuroradiol* 1985;6:643–6.
- Lajeunie E, Merrer ML, Marchac D, Renier D. Syndromal and nonsyndromal primary trigonocephaly: analysis of a series of 237 patients. *Am J Med Genet* 1998;75:211–5.
- Jehee FS, Johnson D, Alonso LG, Cavalcanti DP, de Sa Moreira E, Alberto FL, et al. Molecular screening for microdeletions at 9p22-p24 and 11q23-q24 in a large cohort of patients with trigonocephaly. *Clin Genet* 2005;67:503–10.
- Lajeunie E, Barcik U, Thorne J, Ghouzzi VE, Bourgeois M, Renier D. Craniosynostosis and fetal exposure to sodium valproate. *J Neurosurg* 2001;95:778–82.
- Huang M, Gruss J, Clarren S, Mouradian W, Cunningham M et al. The differential diagnosis of posterior plagiocephaly: true lambdoid synostosis versus positional molding. *Plast Reconstr Surg* 1996;98:765–74.
- Goodrich J, Argamaso R. Lambdoid stenosis (posterior plagiocephaly) and craniofacial asymmetry: long-term outcomes. *Childs Nerv Syst* 1996;12:720–6.
- Jimenez D, Barone C, Argamaso R, Goodrich J, Shprintzen R. Asterion region synostosis. *Cleft Palate Craniofac J* 1994;31:136–41.
- Tubbs R, Wellons JJ, Oakes W. Unilateral lambdoidal synostosis with mendosal suture involvement. *Pediatr Neurosurg* 2003;39:55.
- Shahinian H, Jaekle R, Suh R, Jarraya R, Aguilar V, Soojian M. Obstetrical factors governing the etiopathogenesis of lambdoid synostosis. *Am J Perinatol* 1998;15:281–6.
- Renier D, Cinalli G, Lajeunie E, Arnaud E, Marchac D. Oxycephaly, a severe craniosynostosis. Apropos of a series of 129 cases. *Arch Pediatr* 1997;4:722–9.
- Boyadjiev S, Zhang G, Ingersoll R, Isaac N, Kasch L et al. Analysis of candidate genes for non-syndromic craniosynostosis. *Am J Hum Genet* 2002;71:A1795.
- Zeiger J, Beaty T, Hetmanski J, Wang H, Scott A et al. Genetic and environmental risk factors for sagittal craniosynostosis. *J Craniofac Surg* 2002;13:602–6.
- Weber I, Ninkovic M, Janicke A, Utermann B, Witsch-Baumgartner M et al. Molecular analysis of 74 patients with craniosynostosis. *Eur J Hum Genet* 2001;9:179 P0409.
- Bellus G, Gaudenz K, Zackai E, Clarke L, Szabo J et al. Identical mutations in three different fibroblast growth factor receptor genes in autosomal dominant craniosynostosis syndromes. *Nat Genet* 1996;2:174–6.
- Muenke M, Gripp K, McDonald-McGinn D, Gaudenz K, Whitaker L. A unique point mutation in the fibroblast growth factor

- receptor 3 gene (FGFR3) defines a new craniosynostosis syndrome. *Am J Hum Genet* 1997;60:555–64.
36. Moloney D, Wall S, Ashworth G, Oldridge M, Glass I et al. Prevalence of Pro250Arg mutation of fibroblast growth factor receptor 3 in coronal craniosynostosis. *Lancet* 1997;349:1059–62.
 37. Johnson D, Wall S, Mann S, Wilkie A. A novel mutation, Ala315Ser, in FGFR2: a gene environment interaction leading to craniosynostosis?. *Eur J Hum Genet* 2000;8:571–7.
 38. Merrill AE, Bochukova EG, Brugger SM, Ishii M, Pilz DT et al. Cell mixing at a neural crest-mesoderm boundary and deficient ephrin-Eph signaling in the pathogenesis of craniosynostosis. *Hum Mol Genet* 2006;15:1319–28.
 39. Kress W, Petersen B, Collmann H, Grimm T. An unusual FGFR1 mutation (fibroblast growth factor receptor 1 mutation) in a girl with non-syndromic trigonocephaly. *Cytogenet Cell Genet* 2000;91:138–40.
 40. Lewanda A, Morse S, Reid C, Jabs E. Two craniosynostotic patients with 11q deletions, and review of 48 cases. *Am J Med Genet* 1995;59:193–8.
 41. Christ L, Crowe C, Micale M, Conroy J, Schwartz S. Chromosome breakage hotspots and delineation of the critical region for the 9p-deletion syndrome. *Am J Hum Genet* 1999;65:1387–95.
 42. Chotai K, Brueton L, Herwerden Lv, Garrett C, Hinkel G et al. Six cases of 7p deletion: clinical, cytogenetic, and molecular studies. *Am J Med Genet* 1994;51:270–6.
 43. Fryburg J, Hwang V, Lin K. Recurrent lambdoid synostosis within two families. *Am J Med Genet* 1995;58:262–6.
 44. Odell J, Siebert J, Bradley C, Salk D. Duplication 7p in a family with t(7;11): association with anomalies of the anterior cranial base. *Am J Med Genet* 1987;27:687–92.
 45. Park J, Graham JJ, Berg S, Wurster-Hill D. A de novo interstitial deletion of chromosome 6 (q22.2q23.1). *Clin Genet* 1988;33:65–8.
 46. Jabs E. Toward understanding the pathogenesis of craniosynostosis through clinical and molecular correlates. *Clin Genet* 1998;53:79–86.
 47. Wilkie A. Craniosynostosis: genes and mechanisms. *Hum Mol Genet* 1997;6:1647–56.
 48. Rutland P, Pulleyn L, Reardon W, Baraitser M, Hayward R et al. Identical mutations in the FGFR2 gene cause both Pfeiffer and Crouzon syndrome phenotypes. *Nat Genet* 1995;9:173–6.
 49. Meyers G, Day D, Goldberg R, Daentl D, Przylepa K et al. FGFR2 exon IIIa and IIIc mutations in Crouzon, Jackson-Weiss, and Pfeiffer syndromes: evidence for missense changes, insertions, and a deletion due to alternative RNA splicing. *Am J Hum Genet* 1996;58:491–8.
 50. Passos-Bueno M, Sertie A, Zatz M, Richieri-Costa A. Pfeiffer mutation in an Apert patient: how wide is the spectrum of variability due to mutations in the FGFR2 gene? *Am J Med Genet* 1997;71:243–5.
 51. Ghouzzi Ve, Merrer ML, Perrin-Schmitt F, Lajeunie E, Benit P et al. Mutations of the TWIST gene in the Saethre-Chotzen Syndrome. *Nat Genet* 1997;15:42–6.
 52. Howard T, Paznekas W, Green E, Chiang L, Ma N et al. Mutations in TWIST, a basic helix-loop-helix transcription factor, in Saethre-Chotzen Syndrome. *Nat Genet* 1997;15:36–41.
 53. Jabs E, Muller U, Li X, Ma L, Luo W et al. A mutation in the homeodomain of the human MSX2 gene in a family affected with autosomal dominant craniosynostosis. *Cell* 1993;75:443–50.
 54. Van Maldergem L, Siitonen HA, Jalkh N, Chouery E, De Roy M et al. Revisiting the craniosynostosis-radial ray hypoplasia association: Baller-Gerold syndrome caused by mutations in the RECQL4 gene. *J Med Genet* 2006;43:148–52.
 55. Aldridge K, Boyadjiev SA, Capone GT, DeLeon VB, Richtsmeier JT. Precision and error of three-dimensional phenotypic measures acquired from 3dMD photogrammetric images. *Am J Med Genet A* 2005;138:247–53.
 56. Aldridge K, Kane AA, Marsh JL, Panchal J, Boyadjiev SA et al. Brain morphology in nonsyndromic unicoronal craniosynostosis. *Anat Rec A Discov Mol Cell Evol Biol* 2005;285:690–8.
 57. Aldridge K, Marsh JL, Govier D, Richtsmeier JT. Central nervous system phenotypes in craniosynostosis. *J Anat* 2002;201:31–9.
 58. Gibbs R, Belmont J, Hardenbol P, Willis T, Yu F. The International HapMap Project. *Nature* 2003;426:789–96.