

UC Davis

UC Davis Previously Published Works

Title

Inflammation and changes in cytokine levels in neurological feline infectious peritonitis

Permalink

<https://escholarship.org/uc/item/0b182524>

Journal

Journal of Feline Medicine and Surgery, 5(6)

ISSN

1098-612X

Authors

Foley, JE

Rand, C

Leutenegger, C

Publication Date

2003-12-01

DOI

10.1016/s1098-612x(03)00048-2

Peer reviewed



Since January 2020 Elsevier has created a COVID-19 resource centre with free information in English and Mandarin on the novel coronavirus COVID-19. The COVID-19 resource centre is hosted on Elsevier Connect, the company's public news and information website.

Elsevier hereby grants permission to make all its COVID-19-related research that is available on the COVID-19 resource centre - including this research content - immediately available in PubMed Central and other publicly funded repositories, such as the WHO COVID database with rights for unrestricted research re-use and analyses in any form or by any means with acknowledgement of the original source. These permissions are granted for free by Elsevier for as long as the COVID-19 resource centre remains active.

Inflammation and changes in cytokine levels in neurological feline infectious peritonitis

JE Foley^{1,2*}, C Rand², C Leutenegger¹

¹Department of Medicine and Epidemiology, Davis School of Veterinary Medicine, University of California, Davis, CA 95616, USA
²Center for Companion Animal Health, Davis School of Veterinary Medicine, University of California, Davis, CA 95616, USA

Feline infectious peritonitis (FIP) is a progressive, fatal, predominantly Arthus-type immune-mediated disease that is triggered when cats are infected with a mutant enteric coronavirus. The disease presents variably with multiple organ failure, seizures, generalized effusion, or shock. Neurological FIP is clinically and pathologically more homogeneous than systemic 'wet' or 'dry' FIP; thus, comparison of cytokine profiles from cats with neurological FIP, wet FIP, and non-FIP neurological disease may provide insight into some baseline characteristics relating to the immunopathogenesis of neurological FIP. This study characterizes inflammation and changes in cytokines in the brain tissue of FIP-affected cats. Cellular infiltrates in cats with FIP included lymphocytes, plasma cells, neutrophils, macrophages, and eosinophils. IL-1 β , IL-6, IL-12, IL-18, TNF- α , macrophage inhibitory protein (MIP)-1 α , and RANTES showed no upregulation in the brains of control cats, moderate upregulation in neurological FIP cats, and very high upregulation in generalized FIP cats. Transcription of IFN- γ appeared upregulated in cats with systemic FIP and slightly downregulated in neurological FIP. In most cytokines tested, variance was extremely high in generalized FIP and much less in neurological FIP. Principal components analysis was performed in order to find the least number of 'components' that would summarize the cytokine profiles in cats with neurological FIP. A large component of the variance (91.7%) was accounted for by levels of IL-6, MIP-1 α , and RANTES. These findings provide new insight into the immunopathogenesis of FIP and suggest targets for immune therapy of this disease.

Date accepted: 13 May 2003

© 2003 ESFM and AAFP. Published by Elsevier Ltd. All rights reserved.

Introduction

Feline infectious peritonitis (FIP) is a progressive Arthus-type immune-mediated disease, predominantly of cats from multiple-cat households (Pedersen 1995b, Foley et al 1997). The disease develops after a mutant enteric coronavirus gains entry into the feline macrophage and the cat's innate immune system fails to contain and eliminate the intracellular infection. Infected macrophages disseminate systemically and trigger immunological processes resulting in microgranuloma formation, vasculitis, organ failure, and death (Pedersen and Boyle 1980, Poland et al 1996, Vennema et al 1998). Many details of this process are poorly understood, including the immunopathogenesis of the

disease. The tremendous clinical variability in FIP has made investigating the immunopathology difficult.

Neurological FIP, which is clinically and pathologically more homogeneous than systemic FIP, is a good system for establishing baseline characteristics of immunopathogenesis (Foley and Leutenegger 2001). Neurological FIP occurs in about 1/3 of the cats with FIP (Fenner 1991, Kline et al 1994, Foley et al 1998), and presents with weight loss, fever, ataxia, dementia, and other abnormal neurological signs (Kornegay 1978, August 1984, Kline et al 1994, Foley et al 1998). Neurological FIP consists of meningitis, ependymitis, periventriculitis, and choroiditis, sometimes leading to obstructive hydrocephalus (Slauson and Finn 1972, Krum et al 1975, Legendre and Whitenack 1975, Kornegay 1978, Tamke et al 1988, Summers et al 1995, Foley et al

*Corresponding author. Tel: 1-530-752-3692; Fax: 1-530-752-7701. E-mail: jefoley@ucdavis.edu

Table 1. Clinical score for cats with neurological FIP

0=well cat, no evidence of FIP
1=early mild signs only, including anterior uveitis, keratic precipitates, palpable or ultrasound-visible hepatic or renal granulomas, mesenteric lymphadenopathy
2=moderate progressive signs, including weight loss, fever, meningitis, abnormal CSF (elevated protein, cells, and/or RT-PCR-positive), mild renal or hepatic insufficiency, mild neurological dysfunction
3=severe progressive signs, including severe neurological dysfunction±seizures or paralysis, characteristic ascitic or pleural fluid, moderate to severe organ insufficiency, ±dyspnea
4=end-stage FIP, including recumbency, non-responsiveness, obtundation, seizures, hydrocephalus, hypothermia or evidence of shock, renal or hepatic failure

1998). Often there is little coronavirus present in FIP-affected brain tissue (Foley et al 1998), yet inflammatory cells are recruited to the brain and contribute to disease, in part, through secretion of cytokines. Little is known about cytokine secretion in FIP, although preliminary studies have described increases in IL-10 (Dean et al 1997), IL-6 and IL-1 (Goitsuka et al 1990), and IL-1 α (Hasegawa and Hasegawa 1991), and reductions in IL-2, IL-4, IL-10, and IL-12 (Gunn-Moore et al 1998) in generalized FIP. No information is available regarding cytokine production in neurological FIP and how cytokines compare, in this tissue, with abdominal tissues of cats with generalized or effusive FIP. The purpose of this study was to compare cytokines in the brains of FIP-affected cats with that in the brains of control cats (well cats and cats with neuropathies not attributable to coronavirus).

Materials and methods

Identification of cases

Formalin-fixed brain tissue was collected from four groups of cats, all of which had been patients at the UC Davis Veterinary Medical Teaching Hospital (VMTH) and had been euthanized at the request of owners (including the healthy controls). Ten cats had histopathologically confirmed neurological FIP and no extra-CNS disease (referred to as neurological FIP). Seven cats had neurological and concurrent extra-CNS FIP (generalized FIP). The cats with FIP represented all confirmed cases of FIP seen at the VMTH over the previous 5 years from which sufficient tissue could be obtained. Eleven cats had non-FIP neurological disease, and seven cats were healthy controls with pathologically normal brains. As for the cats with FIP, these cases were chosen on the basis of availability and the fact that they met the

criteria for controls. Clinical abnormalities were described according to a scale (Table 1).

Pathological evaluation

Full necropsies were performed on all cats by pathologists in the VMTH Pathology Service within 12 h of the death of each cat. Brain samples were thinly sliced, placed overnight in 10% buffered formalin, embedded in paraffin, and then sectioned onto glass slides for staining with hematoxylin and eosin. All histological slides were reviewed by VMTH pathologists and one of the investigators (JEF) before further processing. The pathological summaries include all inflammatory cells visualized in all brain sections. All the reviewed slides included sections of cerebrum, cerebellum, and brainstem; in some cats, additional sections were available and these were included whenever available.

Diagnostic testing: serology and reverse transcription-polymerase chain reaction

Serology was performed by indirect immunofluorescence assay (IFA), using *Felis catus* whole fetal-4 cells infected with FIPV-UCD1 as substrate, as previously described (Pedersen 1995a). Samples were tested starting at dilutions of 1:25 to endpoint, and positive and negative control sera included in each run. The titer was considered the highest dilution at which characteristic bright green fluorescence could be detected.

For reverse transcription-polymerase chain reaction (RT-PCR), RNA was extracted from 50 μ m sections of formalin-fixed, paraffin-embedded cerebrum, cerebellum, medulla, and midbrain following pretreatment with xylene in 70% ethanol. All the available sections from each cat were pooled for extraction, a minimum of two in one cat and a maximum of four per cat, after preliminary statistical analysis to ensure that within-cat

variance was low enough to justify this. The sample was resuspended in lysis buffer (DNeasy Tissue kit, Qiagen, Valencia, CA) and incubated with proteinase K at 56°C for 14 h. Samples were aliquotted into two (for extraction of RNA separately from DNA) and nucleic acids were extracted using the kit. In one aliquot, genomic DNA was digested with DNase I (Promega, Madison, WI) at 37°C for 40 min and the reaction was terminated at 95°C for 5 min followed by chilling on ice. In the other aliquot, genomic DNA was dissolved in DEPC-treated water, quantitated by spectrophotometry, and diluted to 20 ng/ μ l.

RT reactions were performed with 10 μ l of tRNA preincubated with 600 ng random hexadeoxyribonucleotide (pd(N)₆) primers (random hexamer; Promega). RT was performed in a 20 μ l volume containing 50 mM Tris-HCl (pH 8.3), 40 mM KCl, 6 mM MgCl₂, 0.5 mM dNTPs, 40 U RNase inhibitor (Gibco BRL, Life Technologies, Grand Island, NY), 5 mM dithiothreitol (DTT), and 200 U SuperScript II (Gibco BRL) at 42°C for 50 min. After 5 min at 95°C, 80 μ l of DEPC water was added.

Real-time TaqMan PCR systems for feline GAPDH, FIPV, IL-4, IL-10, IL-12 p40, and interferon (IFN)- γ were as previously described (Gut et al 1999, Leutenegger et al 1999). Systems for IL-1 β , IL-6, IL-18, IFN- α , tumor necrosis factor (TNF)- α , macrophage inflammatory protein (MIP)-1 α , and RANTES were designed using Primer Express software (Applied Biosystems, Foster City, CA). The internal probe was labeled at the 5' end with the reporter dye FAM (6-carboxy-fluorescein), at the 3' end with the quencher dye TAMRA (6-carboxytetramethylrhodamine), and was phosphate-blocked at the 3' end to prevent extension. The sense and the antisense primers were placed in two consecutive exons of the gene; the probe spanned the junction over the two exons between the sequences covered by the two primers. For the intronless genes, IFN- α and RANTES, the systems did not discriminate between cDNA and gDNA. The primer and probe sequences for newly described feline real-time TaqMan RT-PCR systems are described in Table 2.

PCR reactions contained 400 nM of each primer, 80 nM of the TaqMan probe and mastermix (TaqMan Universal PCR Mastermix, Applied Biosystems), and 5 μ l of the diluted cDNA sample in a final volume of 25 μ l; samples were amplified in a combined thermocycler/fluorometer (ABI Prism 7700 Sequence Detection System, Applied Biosystems) for 2 min at 50°C, 10 min at 95°C, and

then 40 cycles of 15 s at 95°C and 60 s at 60°C. Final quantitation was done using the comparative C_T method (Leutenegger et al 1999) and is reported as relative transcription or the *n*-fold difference relative to a calibrator cDNA (ie the lowest level of cytokine transcription in brain tissue from a well-cat control).

Statistical analysis

Statistical analysis was performed using 'R' (R-Development Core Team). A Wilcoxon signed rank test was used to compare clinical scores and Mann-Whitney U-test to compare FECV titers. The t-tests were used to compare the means of transcription of coronavirus RNA, serum protein, and serum globulins in cats with neurological vs generalized FIP. Cytokine levels among groups were compared by single-factor ANOVA. Prior to this analysis, within-cat variance was assessed to ensure that it was appropriate to pool tissue for cytokine analysis. Three to four duplicate sections of the CNS of six cats, three with systemic FIP and three with neurological FIP, were separately extracted and evaluated for cytokine mRNA by PCR. Within-cat variance was compared with between-cat variance to determine whether it was valid to lump samples from within a cat. Results of the ANOVA indicated statistical significance for all cytokines except IL-4, IL-10, IL-12, IL-18, and IFN- α , indicating that levels of the other cytokines from multiple sections from a single cat were much more similar to each other than to sections from other cats. The *P*-values were 0.02 for IL-1 β , 0.03 for IL-6, 0.01 for IFN- γ , 0.007 for TNF- α , 0.05 for MIP-1 α , and 0.002 for RANTES. Further analysis consisted of principal components analysis (PCA), in order to identify major contributory cytokines in the profiles. This method recharacterizes variables into several principal components (PC) that maximally account for variance in the variables. The loadings give the relative strengths and orientations of the variables to the first several important PCs. In other words, the first PC is an axis that goes through the centroid (of the data cloud) in such a way so as to minimize the average square distance of the points from the axis. The second PC also goes through the centroid, through the maximum variation in the data, but must be completely uncorrelated with PC1. Results of statistical tests were considered significant if the probability of obtaining the observed results by chance alone was ≤ 0.05 .

Table 2. Sequences of PCR primers and TaqMan probes for specific feline cytokines

Cytokine	Primer	Sequence (5'–3')	Length	Probe	Probe sequence (5'–3')	Accession
IL-1 β	fIL1b.55f	AATGACCTGTTCTTTGAGGCTGAT	76	fIL1b.84p	CGAAAAGATGAAGGGCAGCCTCCAA	M92060
	fIL1b.130r	CCAGAAAACCTGTGGCTCAGGTT				
IL-6	fIL6.132f	CCCTGCAGACAAAATGGAAGA	110	fIL6.181p	TGTTATAGTTGTCACACATCTCCTTTTTC AGTGCAGA	X87408
	fIL6.241r	GTGCCTCCTTGCTGTCCTCA				
IL-18	fIL18.178f	GGAGATCAACCTGTGTTGAGGAT	105	fIL18.208p	ATTCTGACTGTACAGATAATGCACCCC GGAC	*
	fIL18.297r	GATGGTACTGCCAGACCTCTAGTG				
IFN- α	fIFNa.112f	CTTGACGCTCCTGGGACAAA	101	fIFNa.141p	TCCCTGCCATCTCCTGTCAGAAGG	E04599
	fIFNa.212r	ACTGGTCTCCACCAGAACACG				
TNF- α	fTNFa.239f	CTTCTCGAACTCCGAGTGACAAG	74	fTNFa.266p	TAGCCCATGTAGTAGCAAACCCCGAAGC	M92061
	fTNFa.312r	CCACTGGAGTTGCCCTTCA				
MIP-1 α	fMIP1a.17f	CTGCCCTCGCCATCCTC	99	fMIP1a.62p	TCTTCTCTGCACCA TTT GGTGCTGACAC	Z14137
	fMIP1a.115r	ATAGGAGAAGCAGCAGGCAGTT				
RANTES	fRANTES.157f	CTACACCAGCAGCAGTGTCC	67	fRANTES.180p	TGCCAGCAGTCGTCTTTGTCACCC	U22385
	fRANTES.223r	ACACACCTGGCGCTTCCTC				

Intron–exon junctions are underlined.

*GenBank submission pending.

Results

Clinical and pathological summaries

The ranges in ages of cats in the different treatment groups were 0.5–11 years for the neurological FIP group, 0.5–11 years for systemic FIP, 0.5–17 years for neurological non-FIP, and 1–10 years for well-cat controls. Because client-owned cats were used on the basis of availability, it was not possible to match controls one to one to cases on age of other factors; however, there were no significant differences in mean age among the four groups ($P=0.2$). The presenting complaints in the neurological FIP cats included anterior uveitis (two cats), inappetence (two), lethargy (three), nystagmus (three), tremors, ataxia and other cerebellar signs (three), obtundation or coma (three), paresis or paralysis (four), bizarre behavior (one), and seizures (one). In cats with generalized FIP, presenting signs included anterior uveitis (two cats), keratic precipitates (two), weight loss (two), ataxia (one), circling (two), coma (one), paresis or paralysis (two), and blindness (one). In non-FIP neurological control cats, presentation included lethargy (one cat), ptyalism (one), ataxia (one), inappetence (two), blindness (three), seizures (one), stupor (one), and opisthotonos (one). Clinical scores were not statistically significantly different among the groups ($P=0.31$).

In the cats for which serum proteins were evaluated, total proteins ranged from 7.1 to 9.7 mg/dl (mean 8.62 ± 0.87 standard deviation (s.d.)) in cats with neurological FIP, and from 5.3 to 8.6 mg/dl (mean 7.45 ± 1.46 s.d.) in cats with generalized FIP. This difference was statistically significant ($P=0.06$). Globulins ranged from 4–7.3 mg/dl (mean 5.6 ± 1.13 s.d.) in cats with neurological FIP to 5.3–8.6 (mean 6.9 ± 1.21 s.d.) in cats with generalized FIP. This difference was not significant ($P=0.24$).

All cats with FIP and the neurological controls had abnormal cellular infiltrates in the CNS. One cat with neurological FIP had only macrophages, while a cat with generalized FIP had only neutrophils in the brain tissue. However, other cats with neurological FIP had mixtures of lymphocytes and plasma cells (one cat), lymphocytes, macrophages, and plasma cells (two), lymphocytes, plasma cells, and neutrophils (one), macrophages, plasma cells, and neutrophils (one), eosinophils, macrophages, lymphocytes, and neutrophils (one), and lymphocytes, macrophages, plasma cells, and neutrophils (two). CNS

infiltrates showed less complexity in generalized FIP with three cases of macrophages with neutrophils, two with lymphocytes and plasma cells, and one with macrophages and neutrophils. The cats with non-FIP neurological disease had macrophages (one cat), neutrophils (two), or lymphocytes, macrophages, and plasma cells (four).

Pathological lesions in cats with neurological FIP included choroiditis (five cats), iritis (one), retinitis (one), uveitis (one), encephalitis (eight), ependymitis (two), meningitis (nine), and vasculitis (seven). In cats with generalized FIP, neurological lesions included choroiditis (four), retinitis (one), uveitis (one), ependymitis (two), encephalitis (four), meningitis (seven), and vasculitis (five). The extra-CNS disease included effusive peritonitis affecting all abdominal organs (one cat), thoracic effusive FIP (four), pericarditis (one), nephritis (four), hepatitis (three), and gastrointestinal serositis (one). All cats with non-FIP neuropathies had meningitis, five had encephalitis, and four had neoplastic cell infiltration. Diagnoses included neoplasia and cerebral cryptococcosis.

Coronavirus characterization: serology and reverse transcription-polymerase chain reaction

Anti-coronavirus IgG titers in neurological FIP ranged from 3200 to 6400, with a geometric mean of 5381.7. In generalized FIP, the range was 300–6000, with geometric mean of 876.9. This difference was statistically significant ($P=0.04$). Unfortunately, because these samples were evaluated retrospectively, sera for antibody assessment of non-FIP neurological and well-cat controls were not consistently evaluated. Coronavirus RT-PCR of brain tissue was negative in control cats. In cats with FIP, coronavirus RT-PCR was positive in 13 of the 17 cats. The four RT-PCR-negative cats had neurological FIP, confirmed by histopathological evaluation and positive anti-FIPV N-protein antibody staining (5.2D5, N. Pedersen, UC, Davis, CA). Relative levels of transcription of coronaviral cDNA ranged from 0 to 2494 times baseline in cats with neurological FIP (mean 730.41 ± 1004 s.d.). In cats with generalized FIP, values ranged from 29.94 to 7302 (mean 3551.47 ± 2757 s.d.). These differences were statistically significant ($P=0.005$). Of the cats tested, the two cats with no detectable coronaviral cDNA had the highest antibody titers (6400).

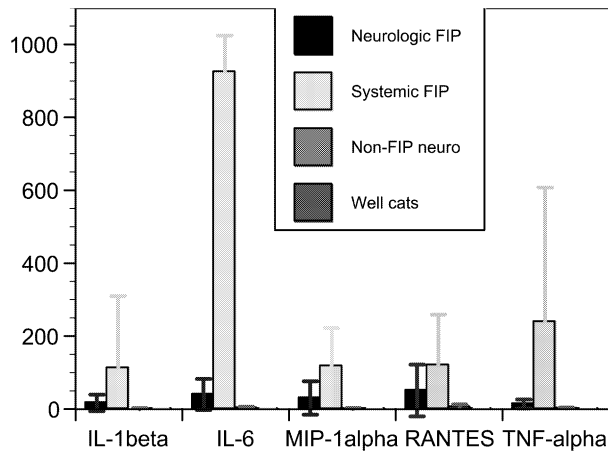


Fig 1. Comparison of mean (\pm s.d.) values of IL-1 β , IL-6, MIP-1 α , RANTES, and TNF- α in the brain tissue of cats with primarily neurological FIP, generalized FIP, non-FIP neuropathy, or no disease. Cytokine transcription is expressed as the n -fold differences to the calibrator.

Cytokine profiles

Cats with generalized FIP had multiple upregulated cytokines with mixed Th₁ and Th₂ patterns (Figs 1 and 2). Cats with generalized FIP had particularly increased transcription of TNF- α , IL-6, and IL-18. In fact, cats with generalized FIP had the highest cytokine levels of all groups for all cytokines except IL-10 and IL-12. The cytokines IL-1 β ($P=0.02$), IL-6 ($P=0.01$), IL-18 ($P=0.05$), TNF- α ($P=0.004$), MIP-1 α ($P=0.04$), and RANTES ($P=0.04$) were significantly highest in generalized FIP than in all other groups, although values for

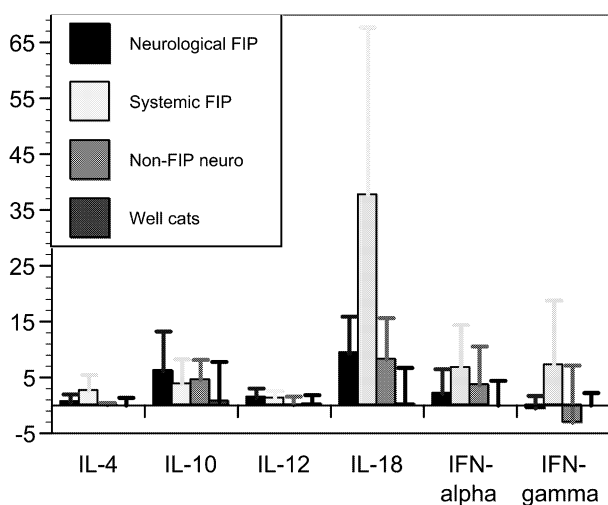


Fig 2. Comparison of mean (\pm s.d.) values of IL-4, IL-10, IL-12, IL-18, IFN- α , and IFN- γ in the brain tissue of cats with primarily neurological FIP, generalized FIP, non-FIP neuropathy, or no disease. Cytokine transcription is expressed as the n -fold differences to the calibrator.

IL-18 should be interpreted with caution, given the high within-cat variance for this cytokine. In addition to generally high mean levels of cytokines in these cats, there was also high variance in cytokine levels particularly in IL-1 β , IL-6, TNF- α , IL-18, and IFN- γ . Cats with neurological FIP had increased cytokine levels, compared with well-cat controls, in all cytokines evaluated except IFN- γ ; IFN- γ levels in cats with neurological FIP tended to be lower than even that for well cats, but this difference was not statistically significant ($P=0.3$). Levels of IL-6, RANTES, IL-1, IL-18, and IFN- α were particularly high. Variance in cytokine levels was much lower than in generalized FIP. In non-FIP neurological controls, most cytokines showed no change in mean values compared with well-cat controls, with the exceptions of IL-4, IL-10, IL-18, and IFN- α . Mean IFN- γ levels were lower than that for well-cat controls. Variance was high, particularly with IL-18, IFN- α , and IFN- γ . When PCA was performed with cats with neurological FIP, 91.7% of the variance was accounted for in the first two components, with 61.4% in the first component. The loadings for PC1 were 0.372 for IL-6, 0.329 for MIP-1 α , and -0.861 for RANTES, and for PC2 were 0.383 for IL-1 β , 0.468 for IL-6, 0.113 for TNF- α , 0.652 for MIP-1 α , and 0.443 for RANTES.

Discussion

Cats with FIP have dramatic cytokine upregulation in the CNS. In neurological FIP, there are consistent increases in several cytokines, but importantly, far less variability in levels than in generalized FIP, making neurological FIP a valuable clinical model for studying the immunopathogenesis of FIP. The technique of using archived brain tissue for RT-PCR with TaqMan PCR proved sensitive and practical for a variety of cytokines. Because each assay was calibrated to an internal RNA GAPDH control for that sample, loss of signal strength due to formalin fixation, paraffin-embedding, or archiving duration could be controlled for. In fact, our laboratory has successfully amplified cytokines from cat tissues as old as 25 years in storage (C. Leutenegger, unpublished data). Nevertheless, it is important to include the internal calibrator.

In this study, neurological lesions were histopathologically pleomorphic. The reported predominant cell types are macrophages and lymphocytes, and less commonly plasma cells or neutrophils (Slauson and Finn 1972, Krum et al 1975, Legendre and Whitenack 1975, Kornegay

1978, Tamke et al 1988, Summers et al 1995, Foley et al 1998). In this study, all but one cat with primary neurological FIP had a lymphocytic component to the infiltrate, while lymphocytes were less typical in the brain lesions of cats with generalized FIP. An earlier report indicated that inflammatory cells in FIP lesions include CD4⁺ T-cells and IgM- or IgG-producing B-lymphocytes (Paltrinieri et al 1998). It was interesting to note that four cats with FIP in the present study had infiltrates with no detectable macrophages. Typically, in FIP, the cells expressing antigen are macrophages, but small lymphocytic cells may also be positive.

Coronavirus load in the brains of cats with FIP in this study was comparable with that reported previously (Foley et al 1998). Previously, 5/16 cats with neurological FIP were RT-PCR-positive in cerebrospinal fluid (CSF) and 10/15 were RT-PCR-positive in brain tissue. In this study, 4/17 cats with FIP had RT-PCR-negative brain tissue. However, compared with previously used techniques for evaluating coronavirus directly (virus culture, traditional RT-PCR, and immunohistochemical staining), the TaqMan RT-PCR assay is extremely sensitive. Nevertheless, even using TaqMan, there were four histopathologically confirmed cases of FIP in which coronavirus RNA could not be detected, most likely due to localization of virus in areas not sampled for PCR.

Cats with neurological FIP had higher antibody titers, but lower coronavirus loads than cats with generalized FIP. Interestingly, of the cats tested, cats with no detectable coronaviral cDNA had the highest titers (6400). This could reflect localization of coronavirus RNA or a primarily immune-mediated disease initiated by the presence of coronavirus but operating autonomously with undetectably low levels of virus. It is unlikely to have been due to antigen-antibody binding because the virus would still be available for PCR. Mouse models of FIP help clarify the significance of ongoing immune-mediated processes in these diseases. In MHV-JHM in mice, CD4⁺ and CD8⁺ T-cells contribute to viral clearance, but B-cell products contribute to demyelination; thus SCID mice (which cannot eliminate virus or make antibodies) have very high viral load but no lesions in the face of low or undetectable antibodies (Houtman and Fleming 1996). Antibodies have been reported to exacerbate clinical FIP (Weiss and Scott 1981, Vennema et al 1990, Hohdatsu et al 1991, Corapi et al 1992, Olsen et al 1992). Thus, for the cats in this study, antibodies may have been responsible for much of the lesion

development, yet cell-mediated immunity may have largely contained virus levels in some cats.

Cytokine profiles were analyzed with PCA because this technique reduced variance to minimum PC and could cope with lack of independence among individual cytokines. Only two components were necessary to capture almost entire observed variance. Unfortunately, because of the way cases were made available by client request for euthanasia, it was not possible to match controls one to one to cases on such possible sources of variance as age, home quality, concurrent disease, and other factors. A few studies have evaluated changes in cytokine levels directly attributable to age. Using a murine scald injury model, splenocyte production of both IL-4 and IL-10 increased with age, while there were no changes in IFN- γ or IL-12, and IL-2 production decreased (Plackett et al 2003); however, after injury, there was a decrease in all of the cytokines examined, regardless of age. In neonatal foals, there were no changes during the first 4 weeks of life in peripheral blood mononuclear cell cytokine expression of IL-1 β , IL-2, IL-4, IL-6, IL-8, IL-10, IL-12p35, IL-12p40, or TNF- α (Boyd et al 2003). The cytokines IFN- γ , TGF- β 1, and IL-1 α increased significantly with age. These studies documented unpredictable changes in cytokine levels across species and disease models with age. In the present study, there were no significant differences among the groups with respect to age. In fact, the tendency (although not statistically significant) was for cats with neurological FIP to be a little older than cats with systemic FIP, and one major difference between these groups was that neurological FIP had lower IFN- γ levels, a cytokine reported not to decrease with age in Plackett et al (2003) and to increase with age in Boyd et al (2003). More importantly, in this study, cytokine variability in the systemic FIP group was very high, even though the variance in age was lower for this group than any other group except the well-cat control.

In the present study, the PCA loadings implicated IL-6, IL-1 β , MIP-1 α , and RANTES as key factors in the immunopathogenesis. These cytokines share common features in recruiting or regulating inflammatory cells, and for IL-6, TNF- α , and IL-1 β , increasing vascular permeability. IL-1 β , which is secreted by many immune-active cells, also leads to local tissue destruction, promotes leukocyte adhesion to the endothelium, and is pyrogenic. IL-6 recruits and activates T-cells and macrophages, expands cytotoxic T-lymphocytes, modulates plasma cell

differentiation, increases vascular permeability, downregulates acute phase proteins, and contributes to immune-mediated destruction in the CNS (Akira et al 1993, Lotz 1995, Tilg et al 1997, Samoiloova et al 1998). Elevations in IL-6 and IL-1 have been reported previously in FIP (Goitsuka et al 1990, Hasegawa and Hasegawa 1991).

Compared with control cats, brains of cats with FIP had higher levels of the chemokines, MIP-1 α and RANTES, which are chemoattractants for inflammatory cells in the brains of cats with FIP. MIP-1 α , or macrophage inflammatory protein, is a chemokine in the conserved C-C family of chemokines (Davatelis et al 1988). It is secreted by macrophages, neutrophils, inflammatory fibroblasts, astrocytes, and lymphocytes, and chemoattractant primarily not only for macrophages and monocytes but also for T-cells and eosinophils. It is pyrogenic and a potentiator of IFN- γ production. However, increases in IFN- γ were not detected in the present study. RANTES is a T-cell secreted chemokine that attracts memory T-cells, dendritic cells, NK cells, eosinophils, basophils, and macrophages. It promotes tissue infiltration of these cells, activates adhesion molecules, and represents one of the more common chemokines to be upregulated in immune-mediated diseases.

The cytokines IL-1 β , IL-6, and IL-10 contribute, to some extent, to B-cell production of antibodies, which promote the formation of FIP lesions. Previously reported increases in IL-10 (Dean et al 1997) were not observed in the present study. The contribution of cell-mediated immunity to FIP is probably mixed: it may be important for early containment of FECV and FIPV but is not effective in late FIP. Cytotoxic T-lymphocytes probably exacerbate lesion formation. In MHV, CD4⁺ cells protect mice from encephalomyelitis and are important in viral clearance but CD4-knockout mice had less inflammation and demyelination than intact genotypes (Lane et al 2000). CD4⁺ cells have been described as components of FIP granulomas (Paltrinieri et al 1998). The chronic inflammation and apparent failure to downregulate inflammation could be due to the absent (IL-12) or weak (IL-18) responses in cats with FIP. The low-grade IL-12 and IL-18 responses also help account for the lack of IFN- γ upregulation. In experimental FIP, apoptosis and T-cell depletion have been noted in the spleen and mesenteric nodes, apparently mediated by cytokines (Haagmans et al 1996). The apoptosis is mediated by cytotoxic T-lymphocytes and not only serves to reduce virus load (Shibata et al 1994) but also reduces inflammation (Schmied et al 1993). CD8⁺ cells

against coronaviral antigens contributed to chronic demyelination and exacerbated the lesions via direct damage in MHV (Perlman et al 1987, Castro et al 1994).

There was no appreciable upregulation of IFN- α or IFN- γ in any of the treatment groups. This very important finding may be a key to understanding why some cats succumb to FIP, if they are incapable for producing adequate IFN- γ or fail to do so for whatever reason. IFN- γ has many possible effects, including direct anti-viral properties, inducing MHC class I expression, increasing superoxide dismutase, protecting against oxygen radicals, and increasing cytotoxicity of other cells. IFN- γ is important for clearance of MHV (Parra et al 1999), and IFN- γ -knockout mice are particularly susceptible to granulomatous peritonitis if they are naturally infected with MHV (France et al 1999). Treatment with anti-IFN- γ antibody increased mortality in mice with MHV-JHM, while therapy with IFN- γ reduced mortality and virus load (Smith et al 1991). IFN- γ -knockout mice had higher viral loads (in liver) than mice with intact IFN- γ expression and more severe lesions, consisting largely of neutrophils (Kyuwa et al 1998). Results using IFN- γ in FIP in cats have not been highly successful but there have not been large-scale, well-controlled clinical trials (eg Mochizuki et al 1994). The three most likely reasons for poor success might be that (1) the more widely available product is a human recombinant IFN- γ , with possibly different effects and the one that cats may make antibodies to; (2) the dysregulated cytokine pattern may vary enough among cats with FIP that a more targeted, cat-specific approach may be needed; and (3) it may be difficult (or impossible) to achieve sufficient levels of the cytokine in the appropriate tissue. For example, administration of recombinant IFN- γ to mice with MHV-JHM resulted in reduced virus levels in the liver, but not in the brain (Smith et al 1991).

In summary, this study compares a panel of cytokines in the brain tissue of cats with neurological FIP, cats with generalized FIP, and control cats, and characterizes major changes in immunological signals. Because neurological FIP appears remarkably immunologically homogeneous (in contrast with systemic FIP), it seems possible that immune therapy might ultimately be designed for this syndrome, which could create a balance of cytokines that might allow a cat to eliminate virus without developing extensive immune-mediated lesions. The information presented in this paper contributes to the understanding of major aspects

of the immune dysregulation that occurs in FIP. Future work obviously needs to contrast more generalized cytokine changes in cats with generalized FIP, and evaluate the ability to change cytokine levels in the CNS and also evaluate whether cytokine changes following experimental manipulation result in a better prognosis for cats with FIP.

Acknowledgements

This project was generously supported by the Robert F. Winn Foundation and the Center for Companion Animal Health (CCAH) at the University of California, Davis.

References

- Akira S, Taga T, Kishimoto T (1993) Interleukin-6 in biology and medicine. *Advances in Immunology* **54**, 1–78.
- August J (1984) Feline infectious peritonitis: an immune-mediated coronavirus vasculitis. *Veterinary Clinics of North America Small Animal Practice* **14**, 971–984.
- Boyd NK, Cohen ND, Lim WS, Martens RJ, Chaffin MK, Ball JM (2003) Temporal changes in cytokine expression of foals during the first month of life. *Veterinary Immunology and Immunopathology* **92**, 75–85.
- Castro RF, Evans GD, Jaszewski A, Perlman S (1994) Coronavirus-induced demyelination occurs in the presence of virus-specific cytotoxic T cells. *Virology* **200**, 733–743.
- Corapi WV, Olsen CW, Scott FW (1992) Monoclonal antibody analysis of neutralization and antibody-dependent enhancement of feline infectious peritonitis virus. *Journal of Virology* **66**, 6695–6705.
- Davatelis G, Tekamp-Olson P, Wolpe SD, Hermsen K, Luedke C, Gallegos C, Coit D, Merryweather J, Cerami A (1988) Cloning and characterization of a cDNA for murine macrophage inflammatory protein (MIP), a novel monokine with inflammatory and chemokinetic properties. *Journal of Experimental Medicine* **167**, 1939–1944.
- Dean G, Woo J, Lavoy A, Moore P, Pedersen N (1997) Cytokine expression in feline lymphoid tissue in health and disease. Feline immunology workshop, Davis, CA, 1997.
- Fenner W (1991) Inflammations of the nervous system. In: August J (ed), *Consultations in Feline Internal Medicine*. Vol. I. Philadelphia: WB Saunders, pp. 507–517.
- Foley J, Leutenegger C (2001) A review of coronavirus infection in the central nervous system of cats and mice. *Journal of Veterinary Internal Medicine* **15**, 438–444.
- Foley JE, Poland A, Carlson J, Pedersen NC (1997) Risk factors for feline infectious peritonitis among cats in multiple-cat environments with endemic feline enteric coronavirus. *Journal of the American Veterinary Medical Association* **210**, 1313–1318.
- Foley J, Lapointe J-M, Koblik P, Poland A, Pedersen N (1998) Diagnostic features of neurologic feline infectious peritonitis. *Journal of Veterinary Internal Medicine* **12**, 36–63.
- France MP, Smith AL, Stevenson R, Barthold SW (1999) Granulomatous peritonitis and pleuritis in interferon-gamma gene knockout mice naturally infected with mouse hepatitis virus. *Australian Veterinary Journal* **77**, 600–604.
- Goitsuka R, Ohashi T, Ono K, Yasukawa K, Koishibara Y, Fukui H, Ohsugi Y, Hasegawa A (1990) IL-6 activity in feline infectious peritonitis. *Journal of Immunology* **144**, 2599–2603.
- Gunn-Moore DA, Caney SM, Gruffydd-Jones TJ, Helps CR, Harbour DA (1998) Antibody and cytokine responses in kittens during the development of feline infectious peritonitis (FIP). *Veterinary Immunology and Immunopathology* **65**, 221–242.
- Gut M, Leutenegger CM, Huder JB, Pedersen NC, Lutz H (1999) One-tube fluorogenic reverse transcription-polymerase chain reaction for the quantitation of feline coronaviruses. *Journal of Virological Methods* **77**, 37–46.
- Haagmans BL, Egberink HF, Horzinek MC (1996) Apoptosis and T-cell depletion during feline infectious peritonitis. *Journal of Virology* **70**, 8977–8983.
- Hasegawa T, Hasegawa A (1991) Interleukin 1 alpha mRNA-expressing cells on the local inflammatory response in feline infectious peritonitis. *Journal of Veterinary Medical Science* **53**, 995–999.
- Hohdatsu T, Nakamura M, Ishizuka Y, Yamada H, Koyama H (1991) A study on the mechanism of antibody-dependent enhancement of feline infectious peritonitis virus infection in feline macrophages by monoclonal antibodies. *Archives of Virology* **120**, 207–217.
- Houtman J, Fleming J (1996) Dissociation of demyelination and viral clearance in congenitally immunodeficient mice infected with murine coronavirus JHM. *Neurovirology* **2**, 101–110.
- Kline K, Joseph R, Averill D (1994) Feline infectious peritonitis with neurological involvement: clinical and pathological findings in 24 cats. *Journal of the American Animal Hospital Association* **30**, 111–118.
- Kornegay J (1978) Feline infectious peritonitis: the central nervous system form. *Journal of the American Animal Hospital Association* **14**, 580–584.
- Krum S, Johnson K, Wilson J (1975) Hydrocephalus associated with the noneffusive form of feline infectious peritonitis. *Journal of the American Veterinary Medical Association* **167**, 746–748.
- Kyuwa S, Tagawa Y, Shibata S, Doi K, Machii K, Iwakura Y (1998) Murine coronavirus-induced subacute fatal peritonitis in C57BL/6 mice deficient in gamma interferon. *Journal of Virology* **72**, 9286–9290.
- Lane TE, Liu MT, Chen BP, Asensio VC, Samawi RM, Paoletti AD, Campbell IL, Kunkel SL, Fox HS, Buchmeier MJ (2000) A central role for CD4(+) T cells and RANTES in virus-induced central nervous system inflammation and demyelination. *Journal of Virology* **74**, 1415–1424.
- Legendre A, Whitenack D (1975) Feline infectious peritonitis with spinal cord involvement in two cats. *Journal of the American Veterinary Medical Association* **160**, 729–734.
- Leutenegger CM, Mislin CN, Sigrist B, Ehrenguber MU, Hofmann-Lehmann R, Lutz H (1999) Quantitative real-time PCR for the measurement of feline cytokine mRNA. *Veterinary Immunology and Immunopathology* **71**, 291–305.
- Lotz M (1995) Interleukin-6: a comprehensive review. *Cancer Treatment and Research* **80**, 209–233.
- Mochizuki M, Nakatani H, Yoshida M (1994) Inhibitory effects of recombinant feline interferon on the replication of feline enteropathogenic viruses in vitro. *Veterinary Microbiology* **39**, 145–152.
- Olsen CW, Corapi WV, Ngichabe CK, Baines JD, Scott FW (1992) Monoclonal antibodies to the spike protein of feline infectious peritonitis virus mediate antibody-dependent

- enhancement of infection of feline macrophages. *Journal of Virology* **66**, 956–965.
- Paltrinieri S, Cammarata MP, Cammarata G, Comazzi S (1998) Some aspects of humoral and cellular immunity in naturally occurring feline infectious peritonitis. *Veterinary Immunology and Immunopathology* **65**, 205–220.
- Parra B, Hinton DR, Marten NW, Bergmann CC, Lin MT, Yang CS, Stohlman SA (1999) IFN-gamma is required for viral clearance from central nervous system oligodendroglia. *Journal of Immunology* **162**, 1641–1647.
- Pedersen N (1995a) The history and interpretation of feline coronavirus serology. *Feline Practice* **23**, 46–52.
- Pedersen NC (1995b) An overview of feline enteric coronavirus and infectious peritonitis virus infections. *Feline Practice* **23**, 7–22.
- Pedersen N, Boyle J (1980) Immunologic phenomena in the effusive form of feline infectious peritonitis. *American Journal of Veterinary Research* **41**, 868–876.
- Perlman S, Schelper R, Bolger E, Ries D (1987) Late onset, symptomatic, demyelinating encephalomyelitis in mice infected with MHV-JHM in the presence of maternal antibody. *Microbial Pathogenesis* **2**, 185–194.
- Plackett TP, Schilling EM, Faunce DE, Choudhry MA, Witte PL, Kovacs EJ (2003) Aging enhances lymphocyte cytokine defects after injury. *The FASEB Journal* **17**, 688–689.
- Poland AM, Vennema H, Foley JE, Pedersen NC (1996) Two related strains of feline infectious peritonitis virus isolated from immunocompromised cats infected with a feline enteric coronavirus. *Journal of Clinical Microbiology* **34**, 3180–3184.
- Samoilova EB, Horton JL, Hilliard B, Liu TS, Chen Y (1998) IL-6-deficient mice are resistant to experimental autoimmune encephalomyelitis: roles of IL-6 in the activation and differentiation of autoreactive T cells. *Journal of Immunology* **161**, 6480–6486.
- Schmied M, Breitschopf H, Gold R, Zischler H, Rothe G, Wekerle H, Lassmann H (1993) Apoptosis of T lymphocytes in experimental autoimmune encephalomyelitis. Evidence for programmed cell death as a mechanism to control inflammation in the brain. *American Journal of Pathology* **143**, 446–452.
- Shibata S, Kyuwa S, Lee SK, Toyoda Y, Goto N (1994) Apoptosis induced in mouse hepatitis virus-infected cells by a virus-specific CD8+ cytotoxic T-lymphocyte clone. *Journal of Virology* **68**, 7540–7545.
- Slauson D, Finn J (1972) Meningoencephalitis and panophthalmitis in feline infectious peritonitis. *Journal of the American Veterinary Medical Association* **160**, 729–734.
- Smith AL, Barthold SW, de Souza MS, Bottomly K (1991) The role of gamma interferon in infection of susceptible mice with murine coronavirus, MHV-JHM. *Archives of Virology* **121**, 89–100.
- Summers B, Cummings J, de Lahunta A (1995) Feline infectious peritonitis. In: *Veterinary Neuropathology*. St Louis: Mosby, pp. 119–121.
- Tamke P, Petersen M, Dietze A, DeLahunta A (1988) Acquired hydrocephalus and hydromyelia in a cat with feline infectious peritonitis: a case report and brief review. *Journal of Canadian Veterinary* **29**, 997–1000.
- Tilg H, Dinarello CA, Mier JW (1997) IL-6 and APPs: anti-inflammatory and immunosuppressive mediators. *Immunology Today* **18**, 428–432.
- Vennema H, de Groot RJ, Harbour DA, Dalderup M, Gruffydd-Jones T, Horzinek MC, Spaan WJ (1990) Early death after feline infectious peritonitis virus challenge due to recombinant vaccinia virus immunization. *Journal of Virology* **64**, 1407–1409.
- Vennema H, Poland A, Foley J, Pedersen N (1998) Feline infectious peritonitis viruses arise by mutation from endemic feline enteric coronaviruses. *Virology* **243**, 150–157.
- Weiss R, Scott F (1981) Pathogenesis of feline infectious peritonitis: nature and development of viremia. *American Journal of Veterinary Research* **42**, 382–390.