

UC Irvine

UC Irvine Previously Published Works

Title

Invasive squamous cell bladder cancer of the ureterovesical junction in a renal transplant patient: a case report

Permalink

<https://escholarship.org/uc/item/0b87882k>

Journal

Journal of Surgical Case Reports, 2017(5)

ISSN

2042-8812

Authors

Mowlds, Donald S
Foster, Clarence E
Ichii, Hirohito

Publication Date

2017-05-01

DOI

10.1093/jscr/rjx066

Peer reviewed

CASE REPORT

Invasive squamous cell bladder cancer of the ureterovesical junction in a renal transplant patient: a case report

Donald S. Mowlds¹, Clarence E. Foster², and Hirohito Ichii^{2,*}

¹Department of Plastic Surgery, University of California, Irvine, Orange, CA 92868, USA and ²Division of Transplant Surgery, Department of Surgery, University of California, Irvine, Orange, CA 92868, USA

*Correspondence address. Associate professor, Division of Transplant Surgery, Department of Surgery, University of California, Irvine, 333 City Blvd West, Suite 1205, Orange, CA 92868, USA. Tel: 714-456 8439; Fax: 714-456-8796; E-mail: hichii@uci.edu

Abstract

It is well established in the literature that the incidence of malignancy is higher in transplant patients than in the general population. Risk factors and screening guidelines for transplant patients have been proposed, but are far from standardized. In this case report, we discuss the treatment course of a 73-year-old female with a history of renal tuberculosis, who developed squamous cell carcinoma at the transplant ureterovesical junction 6 years following graft placement. To our knowledge, this is the second reported case in a patient with a history of renal tuberculosis.

INTRODUCTION

The incidence of malignancy in transplant patients is higher than in the general population, ranging from 2% to 31% and approaching 50% in patients more than 20 years post-transplantation [1]. Here we present the case of a 73-year-old woman who developed squamous cell carcinoma of the bladder 6 years following renal transplant.

CASE REPORT

This case report details the treatment course of a 73-year-old female with diabetes mellitus Type II, hypertension and end-stage renal disease who received a deceased donor renal transplant in 2008. The patient's surgical history also includes a right nephrectomy in 1960 secondary to what was presumably unilateral tubulointerstitial nephritis due to *Mycobacterium tuberculosis*. Since transplantation, the patient's immunosuppression regimen has consisted of Tacrolimus 0.5 mg twice daily and

Cellcept 500 mg twice daily. The patient initially presented with nausea and vomiting, pain at the transplant site and decreased urine output. Laboratory studies revealed a serum creatinine of 5.5 mg/dL, a significant increase from her baseline of 0.6 mg/dL. Her urinary analysis was negative for infection and revealed only 1 red blood cell per high-power field. Upon admission, an ultrasound demonstrated hydronephrosis and increased resistive indices. A computed tomography (CT) scan without contrast of the abdomen and pelvis was performed. The radiologist reported no obstructive pathology (Fig. 1). The following day, the patient underwent nephrostomy tube placement by Interventional Radiology through which a nephrostogram was obtained. Marked narrowing at the distal ureter near the ureterovesical junction was observed (Fig. 2). Over the ensuing days, the patient's serum creatinine improved and she was discharged from the hospital with plans for a cystoureterogram. In the interim, the patient had a Double J stent placed across the stenotic ureteral segment.

Received: January 23, 2017. Accepted: April 26, 2017.

Published by Oxford University Press and JSCR Publishing Ltd. All rights reserved. © The Author 2017.

This is an Open Access article distributed under the terms of the Creative Commons Attribution Non-Commercial License (<http://creativecommons.org/licenses/by-nc/4.0/>), which permits non-commercial re-use, distribution, and reproduction in any medium, provided the original work is properly cited. For commercial re-use, please contact journals.permissions@oup.com

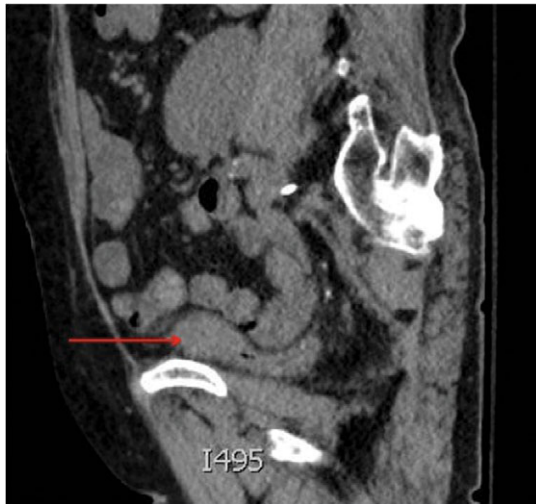


Figure 1: Saggital view of a mass at the dome of the decompressed bladder.

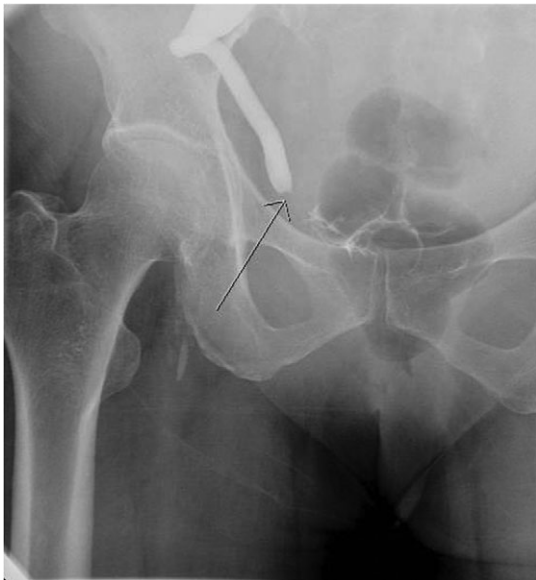

Figure 2: Aterograde nephrostogram demonstrating the obstruction at the ureterovesical junction.

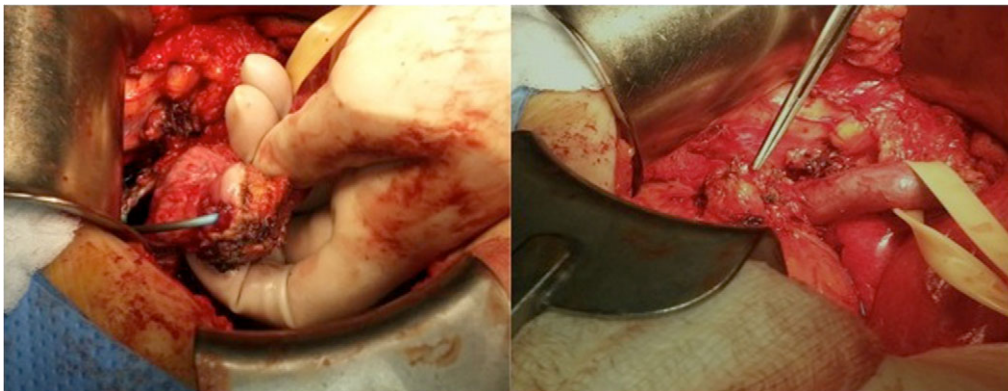


Figure 3: Intraoperative images depicting the tumor at the ureterovesical junction.

The patient underwent an attempted neoureterocystostomy in an effort to alleviate the stricture at the distal transplant ureter-vesical anastomosis. Intraoperatively, exposure of the distal transplant ureter proceeded without difficulty. Once isolated, a 4 × 4 cm mass encircling the distal transplant ureter was visualized (Fig. 3). The mass was excised and sent to pathology for frozen section analysis, which revealed squamous cell cancer arising from the bladder wall. The proximal ureter was spared. The Urology service was immediately available and elected to perform a partial cystectomy with transplant ureteroileal conduit creation. The patient's post-operative course was uncomplicated.

The patient returned to the operating room for a radical cystectomy and regional lymph node dissection with a left nephroureterectomy. The final pathology confirmed a diagnosis of invasive squamous cell carcinoma (4 cm in diameter) with invasion into the transplant ureter, perinephric fat, lamina propria and muscularis propria. Two of nine peri-vesical lymph nodes were positive for metastatic squamous cell carcinoma, making her T3aN2M0 (Stage IV). No further medical or surgical treatment was indicated for the patient. The patient was switched from Cellcept to Everolimus postoperatively to take advantage of its antitumor properties.

DISCUSSION

It is well known that the incidence of malignancy is higher among transplant recipients than the non-grafted population. Specifically, the incidence of urologic cancer is 10 times higher among renal transplant patients than in the general population [2]. Less than 5% of all bladder tumors are of squamous cell origin, with an incidence of 0.2/100 000 in the general population of Western countries [3]. Renal transplant patients have an incidence of 133/100 000, reflecting the increased risk of developing cancer in this patient population.

The association between cyclophosphamide and azathioprine therapy and the development of bladder cancer is well established [4]. This patient's immunosuppressive therapy consisted of Cellcept and Tacrolimus. In their retrospective analysis of 3 741 consecutive renal transplants, Davis *et al.* discovered that 80% of their patients who developed bladder squamous cell cancer received Cellcept and Tacrolimus for immunosuppression. The remaining 20% received cyclophosphamide and azathioprine prior to the year 2000 at which time they were converted to Cellcept and Tacrolimus.

The patient discussed in this report was switched to Everolimus, an mTOR inhibitor, which has been demonstrated to reduce the occurrence of *de novo* cancer in kidney transplant patients [5]. This appears to be related to a suppressive effect on cell proliferation and neovascularization as well as a reduction in overall host immunosuppression [6]. In transplant recipients who have developed cancer, this appears to be an important component in the treatment strategy. In extreme cases, as with high-grade and invasive pathology, graft removal may be required so that immunosuppression may be avoided all together [7].

One study suggests screening patients with risk factors that may predispose them to the development of SCC [8]. In the single institution experience reported by Davis *et al.*, five patients developed SCC of the bladder. Each had notable risk factors such as a history of treatment with intravenous Cyclophosphamide, chronic bladder outlet obstruction, long-term catheter use, chronic irritation to the genitourinary tract or a history of smoking. Interestingly, the patient described in this report did not possess a single one of these risk factors. European guidelines have been developed supporting the screening of renal transplant recipients with known risk factors for developing bladder cancer, most notably persistent visible or microscopic hematuria. They advocate for the use of urine cytology for non-visible hematuria (>5 red blood cells per high-power field) in the absence of urinary tract infection or nephrolithiasis [9]. Based on their experience, Davis *et al.* advocate that patients with even one episode of microscopic hematuria should undergo urine cytology and ultrasound studies. Cystoscopy should be performed if the previous studies are non-revealing [8]. As demonstrated by Kim *et al.*, this strategy may result in earlier detection of bladder cancer in renal transplant patients [9]. Although the patient demonstrated neither visible nor microscopic hematuria, screening to identify potentially at risk-patients may facilitate early investigation and treatment.

There appears to be only one report in the literature describing renal tuberculosis requiring nephrectomy and the subsequent development of squamous cell carcinoma of the bladder following transplantation [10]. Whether either of these patients were at a greater risk of developing squamous cell cancer of the

bladder pre-transplant is unclear, but nevertheless an interesting query for meaningful investigation.

CONFLICT OF INTEREST STATEMENT

None declared.

REFERENCES

1. Buell JF, Gross TG, Woodle ES. Malignancy after transplantation. *Transplantation* 2005;**80**:S254.
2. Buzzeo BD, Heisey DM, Messing EM. Bladder cancer in renal transplant recipients. *Urology* 1997;**50**:525.
3. Shokeir AA. Squamous cell carcinoma of the bladder: pathology, diagnosis and treatment. *BJU Int* 2004;**93**:216.
4. Scharf J, Nahir M, Eidelman S, Jacobs R, Levin D. Carcinoma of the bladder with azathioprine therapy. *JAMA* 1977;**237**:152.
5. Mathew T, Kreis H, Friend P. Two-year incidence of malignancy in sirolimus-treated renal transplant recipients: results from five multicenter studies. *Clin Transplant* 2004;**18**:446–9.
6. Guba M, Graeb C, Jauch KW, Geissler EK. Pro- and anti-cancer effects of immunosuppressive agents used in organ transplantation. *Transplantation* 2004;**77**:1777–82.
7. Nambirajan T, Woolsey S, Mahendra V, O'Rourke D, Walsh IK, Kernohan RM. Squamous cell carcinoma of the bladder and prostatic urethra in a post renal transplant patient. *Ulster Med J* 2003;**72**:121–2.
8. Davis NF, McLoughlin LC, Dowling C, Power R, Mohan P, Hickey D, et al. Incidence and long-term outcomes of squamous cell bladder cancer after deceased donor renal transplantation. *Clin Transplant* 2013;**27**:E665–8.
9. Rogers A, Ng JK, Glendinning J, Rix D. The management of transitional cell carcinoma (TCC) in a European regional renal transplant population. *BJU Int* 2012;**110**:E34.
10. Moon KC, Ahn HS, Min SH, Kim HS. Orthotopic ileal neobladder reconstruction in a woman who developed squamous cell carcinoma of the urinary bladder after kidney transplantation. *Tumori* 2011;**97**:20e–3e.