

UC Davis

Dermatology Online Journal

Title

Livedoid vasculopathy

Permalink

<https://escholarship.org/uc/item/0c0377tx>

Journal

Dermatology Online Journal, 29(5)

Authors

Leeolou, Melissa C
Rieger, Kerri E
Yeh, Jennifer E

Publication Date

2023

DOI

10.5070/D329562414

Copyright Information

Copyright 2023 by the author(s). This work is made available under the terms of a Creative Commons Attribution-NonCommercial-NoDerivatives License, available at <https://creativecommons.org/licenses/by-nc-nd/4.0/>

Peer reviewed

Livedoid vasculopathy

Melissa C Leeolou¹ BS, Kerri E Rieger^{1,2} MD PhD, Jennifer E Yeh¹ MD PhD

Affiliations: ¹Department of Dermatology, Stanford University School of Medicine, California, USA, ²Department of Pathology, Stanford University School of Medicine, California, USA

Corresponding Author: Jennifer Yeh, Stanford University School of Medicine, 450 Broadway Street, Pavilion C, 2nd Floor, Redwood City, CA 94063, Tel: 650-723-6316; Email: jezeh@stanford.edu

Abstract

Livedoid vasculopathy is a painful thrombo-occlusive vascular disorder characterized by spontaneous thrombosis in medium-size arterioles, which causes localized hypoxia and skin ulceration. As livedoid vasculopathy is rare, case reports are the primary means of expanding collective knowledge about its presentation and response to various therapies.

Keywords: livedo, livedoid, reticularis, vasculopathy

Introduction

Livedoid vasculopathy is a challenging diagnosis that requires workup of related conditions and exclusion of clinical mimics. In this case, we review a patient with lacy reticular violaceous patches clinically characteristic of livedoid vasculopathy, though with inconclusive findings on repeat biopsies, who responded to systemic anticoagulation with rivaroxaban. Our case highlights the importance of treating this condition based on high suspicion from clinical evaluation.

Case Synopsis

A 70-year-old woman with a history of hypertension and hyperlipidemia presented with three weeks of painful red rash on the hands, legs, and feet. She had previously completed a 9-day prednisone taper with no improvement. She had no systemic symptoms. On examination, she had lacy reticular violaceous patches with areas of necrosis on the dorsal hands, dorsal feet, and ankles (**Figure 1**). Work-up was notable for positive beta-2 glycoprotein IgM and

indeterminant anti-cardiolipin IgM; anti-nuclear antibodies, rheumatoid factor, cryoglobulins, uric acid, immunofixation (immunoelectrophoresis), and hepatitis B and C were negative. Homocysteine was normal. Other laboratory tests to indicate hypercoagulation including antithrombin III, favor V Leiden, lupus anticoagulant, antiphospholipid antibodies, diluted Russell viper venom time, and anti-neutrophil cytoplasmic antibodies were negative. Protein C and S activity were not decreased. Multiple punch biopsies of the legs revealed no definitive evidence of vasculitis, vasculopathy, or calciphylaxis, but sparse perivascular hemorrhage was appreciated (**Figure 2**). The patient was again trialed on high dose prednisone (60mg daily) with no response, then started on aspirin 81mg daily with progressive ulcer formation on the distal extremities and persistent pain. Given examination clinically consistent with livedoid vasculopathy, she was started on rivaroxaban (initially at 10mg daily and increased to 10mg twice daily). One month later, she noted healing of distal extremity ulcers as well as decreasing pain (**Figure 3**).

Case Discussion

Livedoid vasculopathy is a rare thrombo-occlusive vascular disorder that typically presents on the lower extremities with purpuric macules and papules. It typically presents on the lower extremities with purpuric macules and papules. In some patients, hemorrhagic crust and superficial ulcers form, bordered by violaceous erythema. Disorders that predispose to thrombosis, such as Factor V Leiden thrombophilia and antithrombin III deficiency, may contribute to the pathogenesis [2].

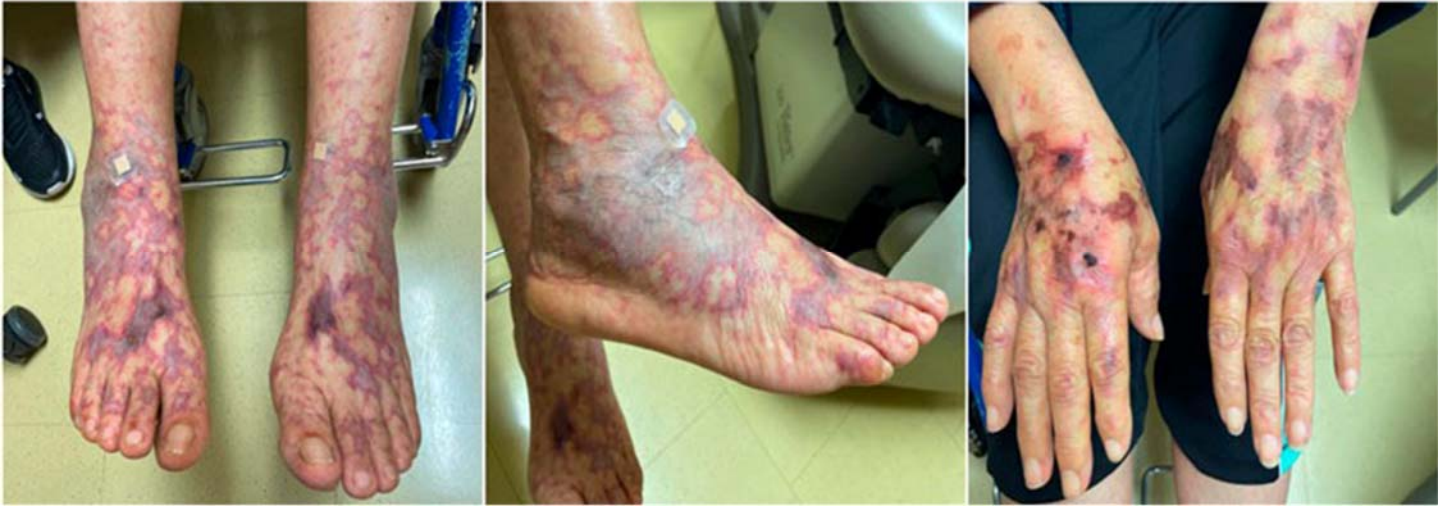

Figure 1. Reticular patches on the dorsal hands and feet at initial presentation.

On histopathology, livedoid vasculopathy is characterized by thickened or hyalinized superficial dermal blood vessels along with fibrin deposits. Perivascular hemorrhage and focal thrombosis are often seen [3]. In our case, the absence of vasculitis and vasculopathy on biopsy may have been due to the older age of sampled lesions. An elliptical biopsy was not performed due to the patient's significant skin fragility, which would have made skin closure challenging. Since the patient's symptoms showed no improvement on high-dose corticosteroids suggesting a non-inflammatory etiology, she was started on systemic anti-coagulation with subsequent skin healing. Though livedoid vasculopathy is a rare disorder for which there are no definitive therapeutic guidelines, anticoagulants,

anti-platelet agents, and fibrinolytic therapies are considered first-line treatments [3].

Other treatments reported in the literature include anabolic steroids, danazol, hyperbaric oxygen therapy, intravenous immunoglobulin, immunosuppressive agents, JAK inhibitors (baricitinib, tofacitinib), TNF inhibitors (etanercept, adalimumab), and ultraviolet light [3-7].

Case reports, proof-of concept trials, and retrospective studies have supported the use of rivaroxaban for livedoid vasculopathy in patients both with and without identifiable coagulation abnormalities [8]. A report of a 57-year-old woman with livedoid vasculopathy and no abnormalities on numerous hypercoagulability and autoimmune tests, demonstrated ulcer resolution and pain reduction on rivaroxaban [8]. The authors postulated that the patient's response to rivaroxaban could indicate that a currently unknown or undetectable coagulation abnormality may exist that predisposes patients to developing livedoid vasculopathy [8]. Likewise, a single-arm phase 2a trial of 25 patients with livedoid vasculopathy, of which 44% had confirmed hypercoagulability abnormalities, demonstrated a clinically significant reduction of pain across 95% of participants with no difference between those with known prothrombotic states versus idiopathic presentations [9]. A review of 73 patients with livedoid vasculopathy found similar results; 49.3% (36/73) of patients had an identified hypercoagulability abnormality and 82.2% (60/73)

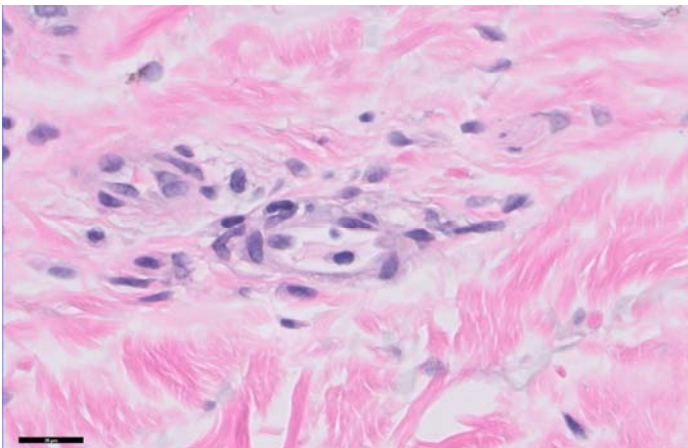


Figure 2. Biopsy sample from the lower extremity revealing sparse perivascular hemorrhage without definitive evidence of vasculitis or vasculopathy. H&E, scale bar 20 μ m, 600 \times .

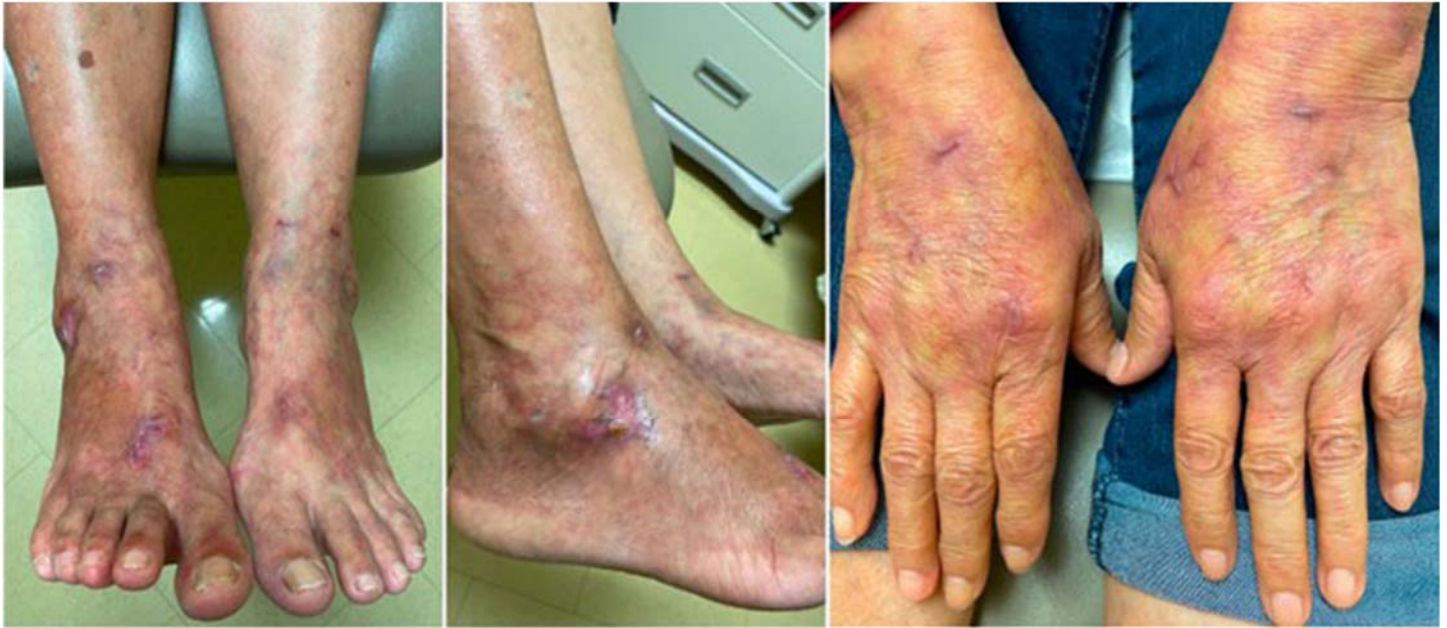

Figure 3. Resolution of reticular patches and ulcer healing after two months on rivaroxaban.

patients demonstrated improvement on rivaroxaban [10]. Further studies to investigate the pathophysiology of livedoid vasculopathy and the efficacy of rivaroxaban should be conducted to confirm these results.

The prognosis for livedoid vasculopathy is unclear; it has been associated with thromboembolic events, including deep vein thrombosis and pulmonary embolism [3]. Treatment should be directed toward the underlying hypercoagulable state.

References

1. Khenifer S, Thomas L, Balme B, Dalle S. Livedoid vasculopathy: Thrombotic or inflammatory disease? *Clin Exp Dermatol.* 2010;35:693-698. [PMID: 19874344].
2. Majmundar VD, Baxi K. Livedoid Vasculopathy. In: StatPearls [Internet]. Treasure Island (FL): StatPearls Publishing. 2022. [PMID: 32644463].
3. Micieli R, Alavi A. Treatment for Livedoid Vasculopathy. *JAMA Dermatol.* 2018;154:193. [PMID: 29141075].
4. Gao Y, Jin H. Efficacy of an anti-TNF α agent in refractory livedoid vasculopathy: a retrospective analysis. *J Dermatolog Treat.* 2022;33:178-183. [PMID: 32116074].
5. Huang XW, Zheng HX, Wang ML, et al. Adalimumab in Treating Refractory Livedoid Vasculopathy. *Vaccines (Basel).* 2022;10:549. [PMID: 35455298].
6. Han Y, Tu P. Baricitinib is potentially effective in the treatment of refractory livedoid vasculopathy. *Front Immunol.* 2022;13:1008392. [PMID: 36389811].
7. Jia E, Yan G, Xiao M, et al. Refractory ulcerations associated with livedoid vasculopathy successfully treated with tofacitinib. *Dermatol Ther.* 2020;33:e14470. [PMID: 33112475].
8. Evans JM, Jensen JD, Sami, N. Successful treatment of livedoid vasculopathy with rivaroxaban. *JAAD Case Rep.* 2015;1:340-341. [PMID: 27051773].
9. Weishaupt C, Strölin A, Kahle B, et al. Anticoagulation with rivaroxaban for livedoid Vasculopathy (RILIVA): A multicentre, single-arm, open-label, phase 2A, proof-of-concept trial. *The Lancet Haematol.* 2016;3:E72-E79. [PMID: 26853646].
10. Gao Y, Jin H. Rivaroxaban for treatment of livedoid Vasculopathy: A systematic review. *Dermatolog Ther.* 2021;34:e15051. [PMID: 34197012].

Conclusion

This case highlights a striking clinical presentation of livedoid vasculopathy that significantly improved on rivaroxaban, thus demonstrating the importance of early diagnosis and treatment in reducing morbidity and mortality.

Potential conflicts of interest

The authors declare no conflicts of interest.