CONTRIBUTIONS
OF THE
UNIVERSITY OF CALIFORNIA
ARCHAEOLOGICAL RESEARCH FACILITY

Number 30 1976

STUDIES IN CALIFORNIA PALEOPATHOLOGY

ARCHAEOLOGICAL RESEARCH FACILITY
Department of Anthropology
University of California
Berkeley

CONTRIBUTIONS

OF THE

UNIVERSITY OF CALIFORNIA

ARCHAEOLOGICAL RESEARCH FACILITY

1976

STUDIES IN CALIFORNIA PALEOPATHOLOGY

by

J. Michael Hoffman

and

Lynda Brunker

UNIVERSITY OF CALIFORNIA

Department of Anthropology

Berkeley

TABLE OF CONTENTS

STUDIES IN CALIFORNIA PALEOPATHOLOGY

PREFACE

These studies in the paleopathology of California are presented with two main a mind: 1) to present a summary of the previously published work in this area and assess the current state of our knowledge of California paleopathology resent some new examples of skeletal abnormalities gleaned from museum

If the latter reports seem unnecessarily detailed, they are presented as cate to some small extent the kinds of background knowledge and sources of that should be utilized before one begins to interpret osseous lesions. The intended to burden the reader but to provide additional insights to the of the material.

We would like to thank the following people who have helped in this series of staffs of the library systems on the Berkeley, Davis and San Francisco of the University of California; Dr. J. Lawrence Angel, Smithsonian Institution, sly supplied data and photographs on two of the crania exhibiting enlarged amina; Drs. Bert Gerow and Theodora Kreps, Anthropology Museum, iversity; Ms. Grace Lee, Department of Anatomy, Stanford University School ; Dr. Harry Genant and technical staff, Department of Radiology, UC-San and the office staff of the Department of Anthropology, UC-Berkeley, Ms. Toni Cord.

Financial support was received from Faculty Research Grants awarded to one by the Committee on Research, UC-Berkeley, and is gratefully acknowledged.

We would especially like to thank Professor Robert F. Heizer, for first in- as to much of the material (both bibliographic and skeletal), for his editorial for his continuing support of these studies.

Any remaining errors, sins of omission, and final interpretations are those ors alone.

STUDIES IN CALIFORNIA PALEOPATHOLOGY:

I. A BIBLIOGRAPHY OF CALIFORNIA PALEOPATHOLOGY

by

J. Michael Hoffman

and

Lynda Brunker

INTRODUCTION

The past decade has been a time of renewed interest in the study of the manifestations of prehistoric disease, i.e., paleopathology. This interest has seen not only the development of new techniques and formulation of theoretical models but also a continuing reappraisal of previously described and/or analyzed material. Because of the role such studies may have in the teaching of prehistoric skeletal biology and the adaptive responses of populations to environmental stresses, the compilation of previously published work in the field seems desirable at this time. Several extensive bibliographies on the general topic of paleopathology have been published in recent years (Armelagos et. al., 1971; Crain 1971) as well as a large collection of papers (Brothwell and Sandison 1967). In addition, The Paleopathology Newsletter of the Paleopathology Association attempts to keep its readers abreast of current work and publications from around the world.

Many of the paleopathologic studies conducted on skeletal material today are done by physical anthropologists. As a comparative discipline, anthropology has as one of its goals the understanding of human variation through time. Thus, through the medium of paleopathology, we can begin to trace the disease histories of native Californians over long periods of time -- from the prehistoric past to modern times. Unfortunately the pathways along which these changes can be viewed are very rough, inconsistent in their quality and, even at times, nonexistent. This is particularly true for the time period immediately following the first Spanish contacts with California natives in the sixteenth century until well into the twentieth century. Despite the vast amount of ethnographic information compiled by A. L. Kroeber and his students there are virtually no data on diseases present or therapeutic practices. However, there are some other, less formal, sources to which we can turn.

The first detailed description of California Indian life comes from a manuscript published in 1628, "The World Encompassed by Sir Francis Drake," reprinted in Heizer (1974). We find therein the following description which is probably the first documentation of the health status of native Californians:

> "After that time had a little qualified their madnes, they then began to shew and make knowne vnto vs their griefes and diseases which they carried about them, some of them having old aches, some shruncke sinewes, some old soares and canckered vlcers, some wounds more lately received, and the like, in most lamentable manner craving helpe and cure thereof from vs: making signes, that if we did but blow vpon their griefes, or but touched the diseased places, they would be whole" (Heizer 1974: 91-92).

An early southern California physician, P. C. Remondino, gives us some further clues in a book in which he attempts to give his readers "some general ideas on

climatology in relation to health and disease" (Remondino 1892: vii). The author gives us first-hand information from two army doctors stationed in the southern California deserts: Dr. William A. Winder, Fort Yuma, 1853, and army surgeon L. Y. Loring, Forts Yuma and Mojave, in the early 1870's. From Winder's report Remondino notes the following:

> "...Indians had one great enemy that took them off rapidly, that being pneumonia. There was some phthisis [a wasting away of the body, usually associated with pulmonary tuberculosis], but evidently as a result of pneumonia; rheumatism was not then [1853] as prevalent as at present [1892]. He particularly observed that those periods characterized by the greatest range of temperature were those in which attacks of pneumonia were most numerous. At the Old Mission of San Diego, then a military post, and at other camps on the west side of the mountains, he observed neither pneumonia nor phthisis" (Remondino 1892: 15).

Loring's observations are summarized in the following:

> "Although the troops never developed any disease that could be ascribed to climate or locality, phthisis was prevalent with the Indians at both posts, especially at Mojave. Rheumatism was also quite common. Both diseases were greatly aggravated by a syphilitic taint, their mode of living, diet, and going about naked. They use but little animal food, but subsist mainly on the mesquite bean, wild potatoes, and what little corn or grain they raise; so that, being poorly nourished, they early become consumptive" (Remondino 1892: 15).

Fortunately, there are here mentioned several diseases which have the potential of being identified in prehistoric osseus remains: phthisis (?TB), rheumatism (various forms of arthritis or degenerative joint disease) and the enigmatic problem of syphilis.

Gifford's monograph, Californian Anthropometry (1926), is one of the few sources to help us somewhat in reconstructing disease histories among native Californians. Here, too, the observations are confined to casual observances about injuries which do not help us a great deal. Gifford notes several instances of broken bones, a "shoulder injury," a "hunchback," some "crippled" hands and fingers, and other miscellaneous trauma. Tantalizing as these observations are, they hardly merit anything more than a mention. What is desired is population information, including age and sex distributions, plus etiologic determinations when known or inferable. And this we do not have.

Reconstructing disease histories is very problematic. Obviously when considering prehistoric material we are limited to those pathologic processes which leave

their impress on bone, except for the rare cases of mummified remains (either natural or intentional mummification) or the indirect knowledge gained from coprolites or artistic portrayals of disease. The reports annotated herein begin to give us a picture of the range of infirmities to which the prehistoric Californian was exposed. For the most part, these fall into three basic categories: trauma, infection, and degenerative joint disease. Numerous kinds of injuries are reported from fractured bones to man-caused occurrences such as imbedded projectile points. Infectious diseases are widespread in some sites, rare in others, except for the nearly omnipresent occurrence of dental abscesses and periodontal disease secondary to severe attrition. The differential distribution of infectious pathologies in time and space would be an important problem to investigate. Degenerative joint disease, especially of the vertebral column, is another widespread phenomenon. Here too, though, we note temporospatial differences which beg for understanding. Besides these three main categories which account for the vast majority of disease in ancient California which we can identify, there are examples of tumorous processes, developmental anomalies, genetic disorders and others. The wealth of material from California plus the uniqueness and diversity of the state, ecologically- and ethnographically-speaking, make it a virtual laboratory for testing many hypotheses about man and his ability to adapt to disease, adaptations which are both biological and cultural in nature.

The following bibliography is offered, then, as a beginning point for those who seek information about ancient disease in California. It is not alleged to be completely exhaustive, and we hope that others will contribute items for possible future inclusion that we have failed to locate. Its focus is on those published writings that deal exclusively, primarily, or peripherally, with examples of paleopathology from California. To list every mention of disease would entail the compilation of scores of archeological reports noting the presence of "vertebral arthritis" and "dental disease." We felt this was unnecessary, partly for the reason that judgments have often been made by those not really capable of assigning such evaluations. We have, however, included some very brief items, a few instances of non-human animal pathology, and some very early historical material. Our reason for doing so was to include some of the more rare, unique, or unusual material.

There is, inevitably, some duplication of material. For example, Brabender's doctoral dissertation (1965a) and the derived publication (1965b) are both cited. The former includes all the specific details of individual specimens while the latter provides a good, detailed summary. We have also included a rather unusual source (Grinnell 1907, from Forest and Stream magazine) which is derived in part from a professional journal (Wilson 1901), to illustrate how such material is extracted, reworked and expanded.

Some guiding comments are provided, but the ultimate judgment on the validity of the published opinions must rest with the interested scholar who will at times want to see the actual specimens. Where we know the repository of the bones this has been indicated.

The bibliographers' tasks are never completed, not only in their own minds but also in those of the scholars who read the utilize their work. This is a beginning effort, and we hope that persons who use this bibliography will send us additional sources known to them and suggestions for improvement in order to increase its usefulness.

The following museum abbreviations are used in the annotations: LACM - Los Angeles County Museum; LMA - Lowie Museum of Anthropology; SDM - San Diego Museum of Man; USNM - United States National Museum.

Literature cited (not in annotated bibliography):

Armelagos, G.J., J.H. Mielke and J. Winter
1971 Bibliography of Human Paleopathology. Research Reports No. 8, Department of Anthropology, University of Massachusetts, Amherst.

Brothwell, D.R. and A.T. Sandison, Eds.
1967 Diseases in Antiquity. Springfield: C.C. Thomas.

Crain, J.B.
1971 Human Paleopathology: A Bibliographic List. Sacramento Anthropological Society Paper 12.

Gifford, E.W.
1926 Californian Anthropometry. Univ. of Calif. Publ. in Amer. Arch. and Ethnol. 22(2): 217-390.

Heizer, R.F.
1974 Appendix II. Extract from The World Encompassed by Sir Francis Drake. 1628. In Elizabethan California. Ramona, Cal.: Ballena Press.

Remondino, P.C.
1892 The Mediterranean Shores of America. Southern California: Its Climatic, Physical, and Meteorological Conditions. Philadelphia: F.A. Davis.

Abbreviations used in bibliography:

UCAS-AR (UCCA) University of California Archaeological Survey - Annual Report (UCCA)

UCAS-R University of California Archaeological Survey - Reports

UCPAAE University of California Publications in American Archaeology and Ethnology

BIBLIOGRAPHY

Abbott, K. H. and C. B. Courville
1939 Historical notes on the meningiomas. I. A study of hyperostoses in prehistoric skulls. Bulletin of the Los Angeles Neurological Society 4: 101-113.

[Well illustrated and described, a "pre-Spanish" skull from San Nicolas Island is presented. Diagnosed as a meningioma, it is a good example of the problem in assessing cranial hyperostoses; presently housed in SDM (no. 17661).]

Allen, H.
1896 Crania from the mounds of the St. John's River, Florida: a study made in connection with crania from other parts of North America. Journal of the Academy of Natural Science 10: 367-448.

[Included are some Santa Barbara Islands crania and a few other specimens, all currently at the Museum of the Academy of Natural Sciences. Although the study is of the classic descriptive nature, large exostoses are reported on crania numbers 1820 and 1821 (in the Academy).]

Angel, J. Lawrence
1966 Early skeletons from Tranquility, California. Smithsonian Contributions to Anthropology 2(1).

[Material from the central San Joaquin Valley is analyzed, C^{14} dated to 2550 $\pm$ 60 years. Angel attempts to place the pathologies in an ecological context (diet, activity); includes "atlatl elbow," early-age onset of vertebral arthritis, and dental disease.]

Bard, Cephas L.
1930 Medicine and surgery among the first Californians. Touring Topics 22: 20-30.

[Includes medical and health practices among California Indians. Editor's Own Page, p. 9, gives background of Dr. Bard. The long article is a reprint of a rare booklet published in 1894, consisting of the paper read by Dr. Bard upon his retirement as president of the So. Calif. Medical Society, entitled "A contribution to the history of medicine in Southern California." Numerous medicinals are mentioned as well as other therapies, including the treatment of rheumatism by placing the patient on an ant hill until well-bitten].

Bennett, K.A.

1972 Lumbo-sacral malformations and spina bifida occulta in a group of proto-historic Modoc Indians. American Journal of Physical Anthropology 36: 435-439.

[Bennett presents material from the Nightfire Island site (CA-SK-4). The high frequency of a complex malformation is tentatively explained by inbreeding. The archaeology of the site is unpublished.]

Brabender, I.

1965a Die Palobiologische Rekonstruktion zweier Prahistorischer bevolkerungen aus Kalifornien. Doctoral Dissertation, University of Mainz, Germany.

[A comparative study of the paleodemography and paleopathology of two sites is presented: SJo-68 (Early Horizon) and Ala-328 (Middle and Late Horizons). Changing cultural conditions (diet, warfare) are felt to be reflected in the higher prevalence of pathologies in SJo-68 and the lower life expectancy in Ala-328. This is a very detailed work listing specific pathologies for individual burials as well as the summary statistics. (See Ryan (1972) below). Material is housed in LMA; dissertation on file in Archaeological Research Facility, Berkeley.]

1965b Beitrag zur palaobiologischen Rekonstruktion prahistorischer kalifornischer Populationen. Homo 16, Band 4: 200-230.

[This is a general summary of Brabender's (1965a) doctoral dissertation.]

Brennan, Edward

1971 Appendix B. The skeletal material from the new Don Pedro Reservoir. In: A Study of Prehistory in the Tuolumne River Valley, California, Michael Moratto, ed. San Francisco State College Anthropology Museum Papers No. 9: 161-166.

[Presented is material from CA-Tuo-279 and CA-Tuo-300, housed in the Treganza Museum at San Francisco State, C^{14} dated to post-915 A.D. Burial 9 (CA-Tuo-300) has a spinal kyphosis and an imbedded chert projectile point in one of the vertebrae immediately superior to the kyphotic section.]

Brooks, Sheilagh T.
1968 Appendix V: Skeletal material from LAn-227. UCAS-AR (UCLA) 10: 144-153.

[A small sample (n=30-32) of skeletons from the Santa Monica Mountains is analyzed. C^{14} dating of cemetery is 420 ± 100 years B. P. Pathologies were limited to the teeth and vertebral column in adults; no bone pathologies seen in children.]

Brooks, Sheilagh T. and William D. Hohenthal
1963 Archaeological defective palate crania from California. American Journal of Physical Anthropology 21: 25-32.

[Three examples of cleft palate associated with palatal exostoses are described and illustrated: two from CA-Ala-328 (2339 ± 150 years B. P.) now in LMA, and one from CA-Sac-29 (Early to Middle Horizon) housed at Sacramento State University.]

Bryan, Bruce
1970 Archaeological Exploration on San Nicolas Island. Southwest Museum Papers No. 22, 160 pp.

[Material from San Nicolas Island is reviewed (? dates); included are numerous wounds inflicted by stone implements, a "hunchback" and other pathologies. Material is presumably in the Southwest Museum.]

Cook, Sherburne F.
1947 Survivorship in aboriginal populations. Human Biology 19: 83-89.

[Cook contrasts the survivorship patterns in aboriginal American Indians with early historic (1800-1928) native Americans. Included in the former is a large sample from California, the latter, some mission groups. Concluding with a discussion of factors leading to differential survivorship, the paper is important in illustrating how demographic information can be integrated with paleopathology.]

1955 The epidemic of 1830-1833 in California and Oregon. UC-PAAE 43 (3): 303-326.

[Although this paper does not deal with prehistoric disease, it is an excellent example of the use of an epidemiologic framework to establish the determinants and distribution of disease. This approach can be used to great advantage in studies of paleopathology. The paper also dramatically portrays the effects of an infectious disease (malaria) on a nonimmune population.]

Courville, Cyril B.

1948 Cranial injuries among the Indians of North America. A preliminary report. Bulletin of the Los Angeles Neurological Society 13 (4): 181-219.

[This well-illustrated article describes numerous kinds of human-inflicted cranial injuries from a diversity of weapons in prehistoric California. Examples are primarily drawn from southern and central California; material is from several museums.]

1952 Cranial injuries among the early Indians of California. Bulletin of the Los Angeles Neurological Society 17(4): 137-162.

[This article expands the California material presented in Courville (1948). It also includes a discussion of legends and folk tales involving cranial injuries as well as "striking weapons" and methods of defense.]

1953 Cranial injuries in prehistoric animals. With special notes on a healed wound of the skull in the dire wolf (Canis Aenocyon dirus Leidy) and a mortal wound in the California black bear (Ursus americanus). Bulletin of the Los Angeles Neurological Society 18(3): 117-126.

[Since paleopathology is not confined to humans, this item is included for general interest. Expecially interesting is a case of a bear meeting its death from an obsidian spear point penetrating its cranium; found in the Santa Rosa Mountains.]

1962 Cranial injuries in the Gold Rush period of California. Report of a skull showing fatal gunshot wound. Bulletin of the Los Angeles Neurological Society 27(2): 91-94.

[This specimen is from the Gold Rush Museum, Amador City (Museum No. 285) and is probably a (?white) miner. Trepanation must be considered here or in any case of a circumscribed cranial defect. Burial in the basement of a saloon helps determine the etiology.]

Dahlberg, A.A.

1963 Analysis of the American Indian dentition. In: Dental Anthropology, D.R. Brothwell, ed., pp. 149-178. New York: Praeger.

[This general survey includes several good photos of early California Indians (provenience unstated) illustrating dental pathologies of various kinds.]

D'Amico, A.

1958 The edge-to-edge bite: resolution of its development. In: The canine teeth; normal function and relations of the natural teeth of man. The California Indian. Journal of the Southern California State Dental Association 26: 132-142.

[Through an analysis of pre-white specimens of children and youth, the author demonstrates that the antero-posterior progression of dental attrition is what results in an edge-to-edge bite at maturity. Nevada and California (Maidu) skulls from the LMA collection were used and the number of each specimen is given. Comparisons are made with some Australopithecine, Homo erectus, and Mount Carmel skulls and similarities in the progression of attrition are noted. The author then discusses that the change in Western Europe from edge-to-edge overbite was not an evolutionary one but due to elimination of abrasive elements in the diet.]

Drake, Robert J.

1948 Archeological investigation of the San Bruno shellmound, San Mateo County, California. El Palacio 55(10): 317-323.

[Presented is material currently at LMA from San Bruno Site 1 (late Transitional or early Late Horizon). In addition to several evidences of healed injuries are what the author presents as two examples of "head-taking" (see also Rackerby (1967) below).]

Gifford, E.W. and W. Egbert Schenck

1926 Archaeology of the southern San Joaquin Valley, California. UCPAAE 23(1): 1-122.

[Included, from the Buena Vista Lake Region (Site 14, Item 1), is the first of several discussions of the Buena Vista Lake skull, LMA No. 12-1731. (See also Kroeber (1951) and Pope (1961) below). The authors also hypothesize that possibly the confused burial of bodies at Site 6 may have been due to the epidemic of 1833 (see Cook (1955) above).]

Grady, Mark Allen

1969 An osteological analysis of selected burials from the Rooney extension of 4-Sac-127, Sacramento, California. Unpublished M.A. thesis, Department of Anthropology, Sacramento State College.

not here

[The Rooney extension of the Augustine site (CA-Sac-127) is tentatively dated to the Middle Horizon and provided a skeletal sample of 152+

individuals. The thesis includes a general pathological survey including inflammation, arthritis, trauma and neoplasms. No comparative data are given.]

Grinnell, George Bird
1907 Primitive bows and arrows. Forest and Stream LXIX (21): 808-810, 848-851.

[Grinnell discusses California weaponry and illustrates cranial injuries in early California Indians (provenience unknown); specimens from the Army Medical Museum. This is essentially a rehash of Wilson's (1901) article cited below, although Grinnell includes more material on the nature of weapons -- a prime agent of pathologies often overlooked (see also Pope (1962) below).]

Haney, Patricia J.
1974 Atlatl elbow in Central California prehistoric cultures. In: Readings in Archaeological Method and Techniques, Robert Kautz, ed., pp. 31-34. Center for Archaeological Research at Davis, Publication No. 4, University of California, Davis.

[This study attempts to correlate changes in the arthritic patterns of the elbow with changing subsistence and technology. Material is drawn from three sites: CA-SJo-112 (Early Horizon), CA-Sol-257 (Middle Horizon) and CA-Sac-145 (Late Horizon). The very small sample size detracts from the conclusions, nor are other possibilities entertained for the changes seen since there is no conclusive archaeological evidence of the atlatl.]

Hawkes, Phillip Newill
1967 An Application of Methods for the Determination of Age, Sex, Stature and Pathologies Applied to the Skeletal Material from 4-Sac-29 and 4-Yub-1. Unpublished M.A. Thesis, Department of Anthropology, Sacramento State College.

[This thesis provides a good, general survey of skeletal pathologies and is very well illustrated. Material dated from the Middle and Late Horizons and includes numerous and varied pathologies. Of special interest is the presentation of two possible cases of syphilis from CA-Sac-29 from the post-contact period.]

Hester, T.R. and R.F. Heizer
1973 Arrow points or knives? Comments on the proposed function of 'Stockton Points'. American Antiquity 38(2): 220-221.

[This paper concerns the interpretation of functional use (cutting implements vs. projectile points) and used paleopathologic specimens to settle the case. Several examples of points imbedded in the bones of prehistoric California Indians are presented; LMA specimens from Central California.]

Hohenthal, W.D. and S.T. Brooks
1960 An archaeological scaphocephal from California. American Journal of Physical Anthropology 18(1): 59-65.

[This pathologic cranium is from CA-Ala-328 (Late Middle Horizon), presumably housed in LMA.]

Johnson, Jerald Jay
1967 Excavations at the Old Bridge site (Site 5-237). In: The Archaeology of the Camanche Reservoir Locality, California. Sacramento Anthropological Society Paper 6: 185-282.

[Included are sixty-three burial descriptions, from Calaveras County, from all three Horizons. Evidences of pathologies are noted in several cases but the author includes no diagnostic interpretations: e.g., Burial No. 38, "left tibia diseased."]

1970 Archeological investigations at the Applegate Site (CA-Ama-56). In: Papers on California and Great Basin Prehistory. Center for Archeological Research at Davis, Publication No. 2. University of California, Davis, pp. 65-144.

[The author assigns an early Middle Horizon age to most of the material. Pathological conditions are listed for sixteen of the twenty-nine burials; although primarily of the dental and arthritic lipping variety, he notes the spongy nature and enlargement of long bones in Nos. 6 and 7 and lesions on long bones in Burial Nos. 7, 16, 18, and 21.]

Kennedy, K.A.R.
1959 The aboriginal population of the Great Basin. University of California Archaeological Survey Report 45: 1-84.

[Kennedy proposed to determine the nature of the morphological differences between the several regions of the Great Basin. He demonstrates a difference between the western and eastern geographical segments. Included in the western region are four crania from Rose Springs in Inyo County, California (Site CA-Iny-372) housed in LMA. He lists frequencies by sex of some dental and cranial pathologies for the population as a whole.]

1960 The dentition of Indian crania of the Early and Late Archeological Horizons in Central California. University of California Archaeological Survey Report 50: 41-50.

[Cranial material from Early and Late Horizon sites, pooled from several localities in the lower Sacramento Valley, are compared to assess if morphological differences can be attributed to dietary customs change (see also Leigh (1928) below). Only slight changes were noted.]

King, Thomas R.

1968 Part 2: The archeology of the Schwabacher site, 4-Mad-117. In: A Survey of the Archeological Resources of the Buchanan Reservoir Region, Madera County, California, San Francisco State College Anthropology Museum Occasional Papers No. 4, pp. 1-135.

[The result of salvage archeology, this material is currently at the Treganza Museum. One cemetery was discovered under a structure C^{14} dated to 1705 A.D. Individual burials are listed for which the author includes a "Pathology" category if appropriate; for example, "calcified lump on femur" plus a few instances of imbedded projectile points.]

Klatsky, M. and J.S. Klatell

1943 Anthropological studies in dental caries. Journal of Dental Research 22(4): 267-274.

[The purpose of the inquiry was to determine whether primitive man did suffer from caries or was he, in fact, immune or partly immune. Study was of 4000 skulls from the American Museum of Natural History from 46 geographical groups including thirty skulls from California (provenience unlisted). The California specimens had a low percentage (1.6%) of carious teeth (see Prero (1970) below).

Results of the study showed that all primitive peoples are not immune to caries, that resistance displayed is not due to immunity by an antigen-antibody reaction, but is a result of proper alignment and the need for more forceful and thorough mastication of more abrasive diets (see D'Amico (1958) above).]

Kroeber, A.L.

1951 At the bedrock of history: recent remarkable discovery of human remains over three hundred years old in the San Joaquin Valley of California. University of California Archaeological Survey Report 11: 5-10. Reprinted from Sunset Magazine, September, 1910 25(3): 255-260.

[Kroeber discusses the Buena Vista Lake skull (see Gifford and Schenck (1926) and Pope (1962) as the most interesting of the remains from the San Joaquin Valley. A photograph is given of the skull in which an arrow-head has pierced the right orbit, downward. He speculates that the fatal wound was not received in battle but was on an unsuspecting victim -- perhaps as an example of the custom of dispatching unsuccessful medicine men.]

Leigh, R. W.

1928 Dental pathology of aboriginal California. UCPAAE 23(10): 399-440.

[Leigh based this study on 300 crania -- pre-Spanish and early post-Spanish -- from LMA. A dozen of the fifty tribes of California are represented. The author demonstrates a correlation between dental pathologies and general food habits and mode of life (see Kennedy (1960) above).]

1929 Dental pathology of aboriginal California. Dental Cosmos 71: 756-767, 878-889.

[A reprint of the above article.]

Lillard, J. B. and William K. Purves

1936 The archaeology of the Deer Creek-Cosumnes area, Sacramento County, California. Bulletin No. 1, Sacramento Junior College, Department of Anthropology.

[Although generally of the skull measurement and physical type genre, the authors discuss injuries and imbedded projectile points, i.e. a burial in Site 1 had a skull in which a chert arrowhead had penetrated the nose and protruded through the upper palate. Also, a test pit in Site 1 uncovered a burial of a female with three recently born infants.]

Littlewood, R.A.

1960 Appendix: Measurements and techniques. In: Analysis of skeletal material from the Zuma Creek site (LAn-174). UCAS-AR (UCLA) 1959/1960, pp. 135-154.

[This is a comparative study of the Zuma Creek crania with other published western cranial series. The author describes an extreme degree of dental pathologies including attrition abscesses.]

Loud, Llewelyn L.

1924 The Stege Mounds at Richmond, California. UCPAAE 17(6): 355-372.

[The Stege Mound is one of the group of Berkeley-Richmond mounds which include the Ellis Landing (see Nelson (1910) below), West Berkeley and Emeryville (see Rackerby (1967) and Uhle (1907) below) shell mounds. From mound no. 300 is a skeleton (LMA cat. no. 12-3445) exhibiting a diseased left femur resulting from a wound near the left acetabulum where an obsidian point has broken off in the bone.]

McHenry, Henry

1969 Transverse lines in long bones of prehistoric California Indians. American Journal of Physical Anthropology 29(1): 1-18.

[Material is from Early, Middle and Late Horizon sites from Central California (sites unspecified); housed in LMA.]

n.d. Harris lines, enamel hypoplasia, and subsistence change in prehistoric California. Ballena Press Anthropological Papers, in press.

[This paper confirms and extends McHenry's (1968) earlier studies and adds enamel hypoplasia as another potential indicator of biologic stress associated with subsistence change. Central California skeletons were studied, housed in LMA and Museum of Anthropology, University of California, Davis (sites unspecified).]

Moodie, Roy L.

1929a Deafness among ancient California Indians. Bulletin of the Southern California Academy of Science 28: 46-49.

[Auditory exostoses are examined as a cause of deafness; specimens from San Nicolas Island, now housed in LACM.]

1929b Studies in paleodontology, XIII. Diseases of the teeth of an Indian from a post-Spanish interment in the desert of southern California. Pacific Dental Gazette 37: 81-86.

[This is a detailed exposition, well-illustrated, of an Indian skeleton from Mason Valley, Laguna Mountains, now housed in SDM (no. 8766). The severe oral disease contains everything but caries.]

1929c Studies in paleodontology, XIV. A curious example of dental abrasion in an ancient California Indian. Pacific Dental Gazette 37: 87-94.

[In another well-illustrated article, a Moodie hallmark; a "pre-Spanish" specimen from La Jolla Shores is shown with a severe oral disease consequent to attrition; housed in SDM (no. 8873).]

1929d Studies in paleodontology, XV. Dental attrition and its results among certain ancient Indians from southern California. Pacific Dental Gazette 37: 217-227.

[This article discusses further oral disease in specimens from La Jolla Shores.]

1929e Studies in paleodontology, XVI. The California sabre-tooth; the mandibular teeth and associated structures. Pacific Dental Gazette 37: 317-321.

[This brief article surveys the pathologies in specimens from LaBrea. Sixty of the twelve hundred sabre-tooth tigers manifested pathologies, including: gigantism (hyperpituitarism), pyorrhea, osteomyelitis, apical abscesses, osteomata, trauma and impactions. Specimens housed in LACM.]

1929f Studies in paleodontology, XXI. A further note concerning the association of arthritis with diseased teeth. Pacific Dental Gazette 37: 681-682.

[Illustrates and briefly discusses the association of infected teeth with rheumatoid arthritis in a California Indian (provenience unknown).]

1929g Studies in paleodontology, XXV. The California sabre-tooth: facial asymmetry following loss of sabre. Pacific Dental Gazette 37: 764-766.

[Specimen in LACM illustrating facial changes following loss of sabre teeth and subsequent socket resorbtion.]

1929h Studies in paleodontology, XVII. The California sabre-tooth: two impactions and an abscess. Pacific Dental Gazette 37: 767-770.

[Specimens in LACM.]

Moratto, Michael J.

1969 The archeology of the Jones site, 4-Mad-159. In: The Archeology of the Buchanan Reservoir Region, Madera County, California, T. F. King, ed. San Francisco State College Anthropology Museum Occasional Papers No. 5: 82-218.

[Appendix 1 lists complete burial records including "Discontinuous Traits" (mainly Wormian bones) and "Pathology" (mainly dental and arthritic) for each of 55 burials. Material housed in the Treganza Museum. In the discussion, an instance is mentioned (for which no number is given) of a skeleton having "semi-ankylosis in the spine."]

Nelson, Nels C.
1910 The Ellis Landing Shellmound. UCPAAE 7: 357-426.

[Material is housed in LMA and assigned an age of ca. 3500 years B. P. Some pathologies listed are a tooth grown well up into the nasal cavity, fused cervical vertebrae and a fracture at the elbow which has mended in a flexed position (another specimen is described by Pope (1923) below).]

Newman, Russell
1949 Appendix II. Preliminary report of the skeletal remains (of the Early Central California Culture). In: The Archeology of Central California. I: The Early Horizon, R. F. Heizer, ed. UCAS-R 12: 49-50.

[This is a brief, preliminary description of crania from four Early Horizon sites: C-56 (CA-SJo-56), C-68 (CA-SJo-68), C-107 (CA-Sac-107), C-142 (CA-SJo-142). The author lists per cent distribution of auditory exostoses in each site (there is a high occurrence), observes that there is pronounced vertebral lipping only in C-68, and that alveolar abscesses and ante-mortem tooth loss are very common throughout.]

1957 A comparative analysis of prehistoric skeletal remains from Lower Sacramento Valley. UCAS-R 39: 1-66.

[Compared are three skeletal series, grouped on the basis of the chronological Horizons, from several sites in the Interior Valley Zone (the sites are listed). Pathologies include: arthritic changes, auditory exostoses, cranial injuries and imbedded projectile points. Material housed in LMA.]

Oetteking, B.
1930 An extreme case of arthritis deformans from San Nicolas Island. Museum of the American Indian, Heye Foundation, Indian Notes 7: 52-56.

[Well-illustrated, describes specimen now housed in the museum. Site is not stated.]

Olson, W. H. and F. A. Riddell
1962 Salvage of the Rio Oso site. Ms. on File, State of California Resources Agency, Department of Parks and Recreation, Division of Beaches and Parks.

[Material currently at the State Indian Museum in Sacramento has been assigned to Late Horizon, Phase I; site number is CA-Yub-14. No pathologies are listed but under a discussion of "evidences of conflict", the authors list imbedded projectile points and wounds.]

Orr, Phil. C.
1943 Archeology of Mescalitan Island. Santa Barbara Museum of Natural History, Occasional Papers, No. 5.

[Mescalitan Island is the Museum's locality number 46, sites I, II and III; material is in the Museum and has been assigned to the Canalino Culture. Site I is of particular interest for the number of imbedded projectile points described. Burial AA has 17 points imbedded in various parts of the body -- one of which has pierced an orbit.]

Peck, Stuart L.
1955 An archeological report on the excavation of a prehistoric site at Zuma Creek, Los Angeles County, California. Archeological Survey Association of Southern California, Paper No. 2.

[Site CA-LAn-174, a very small amount of material, of interest only in that Burial 13-12 has a mandible so small that M_2 and M_3 were "well within the condyle."]

Pepper, O. H. P. and E. P. Pendergrass
1936 Hereditary occurrence of enlarged parietal foramina. American Journal of Roentgenology 35: 1-8.

[Article includes two photos of a skull from the Ponce Mound (CA-SCl-1) now housed in USNM (no. 276981).]

Pope, S. T.
1962 Bows and Arrows. Berkeley: University of California Press. Originally published in 1923 as "A Study in Bows and Arrows," University of California Publications in American Archaeology and Ethnology, 13(9): 329-414.

[This small volume is the result of experiments using museum specimens of bows and arrows to compare mechanical efficiencies and penetration ability. Plates 16 and 20 illustrate examples of deep penetration into human bones. The former is a representation of the Buena Vista Lake skull (see Gifford and Schenck (1926) and Kroeber (1951) above) with a good discussion of the path of the arrow and the anatomy affected as well as descriptions of other anomalies

and injuries of the skull. Plate 20 (LMA no. 12-2340), from the Ellis Landing mound (see Nelson (1910) above), is of a left femur with an obsidian point imbedded in the greater trochanter.]

Prero, Michael Dwayne
1970 An osteological analysis of a prehistoric California Indian site: Sac. 43. Unpublished M.A. Thesis, Department of Anthropology, University of California, Davis.

[The material from site CA-Sac-43, the Brazil Mound, dating from the Middle Horizon and housed in LMA, was used in a comparative study of Middle Horizon material from Sacramento Valley. General poor health was seen in Sac-43, with females showing more pathologies than males. The high prevalence of dental caries found in Sac-43 (58%) is very unusual in California (see Klatsky and Klatell (1943). Sac-43 manifested higher prevalence of pathologies, generally, than the Cook or Augustine site material to which it was compared.]

Rackerby, Frank
1967 The archeological salvage of two San Francisco Bay shellmounds. San Francisco State College Anthropology Museum Occasional Papers No. 3: 1-83.

[The material, form sites CA-Ala-12 and CA-Ala-13, is in LMA. The burials are individually described with pathologies and injuries noted where appropriate. Skull wounds and imbedded projectile points are numerous and there is an instance which is interpreted as "head-taking" (see Drake (1948) regarding the San Bruno shellmound): i.e. Burial 19 (Ala-13) has had the skull removed and placed between the knees.]

Ragir, Sonia
1972 The Early Horizon in Central California. Contributions of the University of California Archaeological Research Facility (Berkeley), No. 15.

[Pages 40-43 of this monograph summarize the paleopathological findings of Brabender on SJo-68 (Early Horizon) written in a manuscript in 1963. (See Brabender (1965a, 1965b.)]

Rogers, D. B.
1929 Prehistoric Man of the Santa Barbara Coast. Special Publication of the Santa Barbara Museum of Natural History, No. 1.

[In the appendix of this book are references to several specimens that had been "bludgeoned in life" and to imbedded arrowheads. In anecdotal

fashion, the author describes one skull in which the atlas had fused to the cranium, "due to a broken neck in infancy, leaving a permanently stiff neck." "Thus handicapped, she fell once too often at age 25 and suffered a fatal basal fracture."

He tells of another skull with a congenital deformity: there was a "small amount of brain quantity on the left side. Thus incapable of normal mental functions: the personal belongings which were buried with this "man give a fair reflection of his aberrant tastes." (Proveniences are not stated.)]

Roney, James G.

1959 Paleopathology of a California archeological site. Bulletin of the History of Medicine 33: 97-109.

[This paper explicitly used an epidemiological approach, which includes skeletal material, cultural data and environmental factors to reconstruct the determinants and distribution of disease. Emphasis is on a population approach. Site CA-Son-299 is a Middle Horizon site (ca. 500-200 B. C.); material housed in LMA.]

1966 Paleoepidemiology; an example from California. In: Human Paleopathology, Saul Jarcho, ed., pp. 99-120. New Haven: Yale U. Press.

[This is a brief, updated version of Roney's 1959 paper.]

Rootenberg, Sheldon

1960 Cranial and post-cranial measurements and observations for San Nicolas Island skeletal remains. University of California Archaeological Survey, Annual Report (University of California, Los Angeles) 1959/1960, pp. 115-129.

[Material is in the UCLA Museum, from several San Nicolas Island sites (the sites are listed) and is dated to Early Canalino period. The author discusses the extreme amount of dental attrition and resultant dental pathologies. There is a burial from SNI-18 with two cranial osteomata and another from SNI-56 having a cylindrical growth of the cranial base.]

Ryan, Dennis John

1972 The Paleopathology of Ala-328: the Relationships among Disease, Culture, and Environment in a California Indian Population. M.A. Thesis, Department of Anthropology, San Francisco State University.

[Thorough, well-illustrated thesis of material from Middle and Late Horizons, now housed in LMA and Treganza Museum. Does not mention Brabender's (1965b) work on the same site.]

Schenck, W. Egbert
1926 The Emeryville Shellmound: Final Report. University of California Publications in American Archaeology and Ethnology, 23(3): 147-282.

[Site Ala-309, housed in LMA; no. 12-3801 has a left tibia and fibula fused at the ankle, no. 12-3604 has an unusually large mandible due to the teeth not having erupted properly, no. 12-3640 has a healed depressed skull fracture, and "a body in the NW perimeter had a pathological elbow."]

Schenck, W.E. and E.J. Dawson
1929 Archeology of the northern San Joaquin Valley. University of California Publications in American Archaeology and Ethnology 25(4): 289-413.

[Provenience is not stated for the skeletal material, but the authors describe several badly healed bone injuries, fused vertebrae, imbedded projectile points, and an example of presumably porotic hyperostosis.]

Schulz, Peter D.
1970 Oral morphology and disease in a prehistoric Central California population -- 4-Mer-14. Ms. on file, Archeological Resources Section, Department of Parks and Recreation, Sacramento.

Schulz, P.E. and H.M. McHenry
1975 Age distribution of enamel hypoplasia in prehistoric California Indians. Journal of Dental Research, in press.

[Material from unspecified sites in the lower Sacramento-San Joaquin Valley, representing Early, Middle and Late Horizons, is presented; housed in LMA and Museum of Anthropology, University of California, Davis. (See McHenry (1968) and McHenry and Schultz (1975).]

Snure, Henry
1924 A roentgen-ray study of the LaBrea fossils (California). American Journal of Roetgenology 11: 351-354.

[This is the first X-ray study of the LaBrea fossils (all nonhuman material). The focus is on infections (?TB); material housed in LACM.]

Stewart, T. Dale

1941 Appendix A: Skeletal remains from the Buena Vista site, California. In: Archeological Investigations at Buena Vista Lake, Kern County, California, W.R. Wedel, ed. Bureau of American Ethnology, Bulletin 130: 172-188.

[Stewart examined 75 specimens, in the USNM, from four Buena Vista sites. No. 372297 has pathological changes he attributes to syphilis, but the dating is uncertain and could be post-1542 (a photograph is given). He diagnoses osteomyelitis in the femur of another specimen --also illustrated -- and describes a third having separate neural arch in the fifth lumbar vertebra.]

1974 Nonunion of fractures in antiquity, with descriptions of five cases from the New World involving the forearm. Bulletin of the New York Academy of Medicine 50(8): 875-891.

[Article includes a specimen from near Palo Alto, a "Digger" Indian now housed in the USNM (no. 225001).]

Uhle, Max

1907 The Emeryville Shellmound. University of California Publications in American Archaeology and Ethnology 7(1): 1-107.

[Presumably in LMA, one burial contains a cranium which shows a "lupus-like mutilation of the nose" for which a drawing is given.]

Warren, G. L.

1971 Skeletal analysis of 4-SLo-406. San Luis Obispo County Archeological Society, Occasional Papers, No. 4.

[The result of salvage archaeology, there are good descriptions of each burial. Osteitis of undescribed types, a skeleton with twelve large projectile points imbedded in it, and fused vertebrae are representative of the pathologies outlined. Material dated to ca. 500 B.C. - A.D. 500.]

Wilson, Thomas

1901 Arrow wounds. American Anthropologist 3(3): 513-531.

[This general review of arrow wounds, prehistoric and historic, includes an early California Indian with a penetrating wound of the left orbit (p. 517). (See Grinnell (1907) and also Pope (1962).]

STUDIES IN CALIFORNIA PALEOPATHOLOGY:

II. COMMINUTED FRACTURE OF A HUMERUS WITH PSEUDOARTHROSIS FORMATION

J. Michael Hoffman

T. Dale Stewart (1974) has recently called attention to several prehistoric New World cases of one of the orthopaedic surgeon's worst fears - nonunion of fractured bone. In his review of five new cases of nonunited fractures of the forearm, Stewart presents several instances of pseudoarthrosis, i.e., 'false joint,' accompanying the nonunited fractures. While Stewart's discussion centers on the questions of recognition and differential diagnosis of forearm fracture nonunion, the present paper presents a case of pseudoarthrosis of the humerus following a comminuted fracture and discusses the etiology of false-joint formation.

Description of Case (LMA # 12-6430)*

The specimen is from Marin County, CA, site CA-Mrn-242, also known as the Cauley Mound. Field notes from Mrn-242, in the possession of the Archaeological Research Facility, Berkeley, contain only information about burials rather than the site in general. Unfortunately the notes associated with this burial are missing and we cannot, therefore, discuss associated artifacts and attendant dates for the material.

Pelvic morphology, general skeletal robusticity and size of articular surfaces indicate a male specimen of adult age. Definitive aging is not possible because there is no pubic symphysis or cranium; however, all extant epiphyses are closed.

The left humerus has sustained a comminuted fracture (i.e., bone broken into three or more fragments) with subsequent formation of a pseudoarthrosis (or pseudarthrosis). The bone was originally fractured into three segments, the two fracture planes located 1) approximately 12 cm from the proximal extremity and 2) just proximal to the deltoid tuberosity.

The proximal end of the middle fragment has been drawn superomedially and is now fused to the medial surface of the proximal fragment just below the surgical neck. There is strong callus formation with extensive remodelling to give the union a smooth surface appearance. The fused middle fragment projects 35° inferomedially from the proximal segment.

A pseudoarthrosis has formed between the distal end of the middle fragment and the proximal end of the distal humeral segment to the extent that a well-formed ball-and-socket joint has developed. The proximal aspect of the false-joint presents a concavity directed inferolaterally, approximately 4 cm X 6 cm in diameter, with the greatest curvature of the concavity in the superior aspect of the articular surface. The concavity itself has been formed from remodelled callus and appears as a rounded expansion of the fused middle fragment when viewed from its medial aspect. The distal articular surface, directed superomedially and slightly posteriorly, is convex and slightly larger around than the more distal shaft diameter (in part the result of the deltoid tuberosity).

*LMA = Lowie Museum of Anthropology

Both false articular surfaces evidence deep pitting. But the outline of the articular surfaces is rather smooth without any noticeable bony projections from the surfaces, thus allowing a rather freely moving joint restricted only by the fibrous capsule which probably surrounded the pseudo-arthrosis.

The pitting noted in the articular surfaces is also seen to extend distally a few centimeters from the proximal end of the distal fragment. The pits are of a smaller size here and they are accompanied by a few small foci of newly-formed bone (probably of periosteal origin). Some of the pits have the appearance of sinus tracts which extend into the medullary cavity.

Examination of the radiographs of the fracture fragments reveal a picture consistent with the gross appearance of the bones. The fused fragments show extensive remodelling and solid fusion throughout their area of attachment. The distal fragment is notable for the appearance of several focal radiolucent areas representing bone lysis as is typically seen in osteomyelitis. The reactive new bone formation and the pitting/sinus tract formation are consistent with this possibility of bone infection.

Discussion

Aegerter and Kirkpatrick in their discussion of fracture healing state that

> if bone production is deficient and the healing process delayed substantially beyond a year, especially in the areas in which there is repeated motion, a pseudarthrosis is likely to be formed. The organism is slow in bridging with rigid bone an area in which motion is constant. Instead the callus remains fibrous and pliable. Evenutally a bursa-like sac develops in the region and its walls may undergo cartilaginous metaplasia. This is a marvelous imitation of a joint with articular plates covering the bone ends, an illustration of the adaptability of tissues to new environmental conditions. (1975:235)

The initial problem, then, in pseudoarthrosis formation is the delayed union of fractured bone, continuing to a state of nonunion with subsequent false-joint formation. The distinction between delayed union and nonunion of fractures is important. In the former the processes of bone repair are retarded but still going on and, with sufficient time (and ideal healing conditions), should produce bony union; in the latter the reparative processes have stopped. There are many causes of delayed and nonunited fractures and the two processes can be seen as a continuum which is affected by various etiologic agents acting in concert with individual variability to repair damaged tissue. These causes include (after Verbeek and Dubbelman 1962, Lichtenstein 1970, and Rosse and Clawson 1970):

nature of the fracture (is it simple or compound, greenstick or comminuted?)
size of the fracture surfaces (can they be adequately apposed?)

distance between fracture surfaces (is the distance too great to be bridged?)
loss of bone substance (again, can the distance be bridged or will the extremity be shortened?)
condition of adjacent soft parts (is circulation impaired? do soft tissues intervene between fracture fragments?)
infection (is the fracture compound?)
constitutional factors (age, nutritional status, systemic diseases, etc.)
quality and nature of treatment (is infection controlled? is there adequate immobilization and is it applied long enough? is bony apposition sufficient? is there adequate alignment of fragments?).

If the individual's healing abilities, in concert with one or more of the above factors, are inadequate to the task, then delayed union or nonunion will result. The boundary between these is rather arbitrary as Verbeek and Dubbelman (1962) note; the important elements appear to be time and the adequacy of callus formation.

Although we have noted the many causes of delayed and nonunion of fractures, the single most important element leading to pseudoarthrosis formation apparently is inadequate immobility of the fracture site. Continued movement at a fracture site inhibits the vascular growth and metaplasia necessary for callus formation. Even intermittent movement may disrupt the integrity of an already formed but weakly developed callus. In short, pseudoarthrosis may be seen as the result of repair with motion. As long as motion is present cartilage will develop from the fibrous tissues of the fracture site and will remain and function as cartilage until completely immobilized.

Even in nonunited fractures, the fragments may be connected by fibrous or fibrocartilaginous connective tissue; but in a pseudoarthrosis the bone ends are covered with hyaline cartilage and the joint space is surrounded by a thick bursal sac containing synovial fluid (Shands and Rainey 1967). Strictly speaking, then, even a 'nonunited' fracture may be united.

Regarding the importance of adequate, sustained immobilization, Cameron (1966) presents the results of a series of experimental studies of shaft fractures in the femoral diaphyses of dogs. The importance of immobilization apparently lies in its ability to prevent or reduce torsion in the fracture fragments, thereby allowing adequate vascularization, metaplasia and callus formation.

At this point we should entertain the possibility of whether this fractured humerus had been immobilized, at least for some period of time. Obviously, without direct evidence of splints or other devices we cannot be sure; but the ethnographic record would argue for its possible presence. In his treatise on American Indian therapeutics and medical practices, Vogel makes the following general observation regarding the empirical treatment of obvious injuries:

> Indian treatment of externally caused injuries, in which the origin of the ailment was perfectly obvious, was usually rational and often effective. In such a category were fractures, dislocations, wounds of all kinds, including snake and insect bites, skin irritations, bruises, and the like. (Vogel 1970:13-14)

Specifically in regard to handling fractured bone, he notes the following:

> An interesting native achievement in fracture treatment was the use of form-fitting splints. Padding of wet clay or rawhide was often used, as well as poultices. The Ojibwas washed a fractured arm with warm water and greased it, applied a warm poultice of wild ginger and spikenard, covered with a cloth and bound the arm with thin cedar splints. The Pimas used splints from the flat, elastic ribs of the giant cactus. The Mescalero Apaches rubbed dislocated parts until warm and then with a quick jerk forced the bone into place, rubbing medicine on afterward to allay the pain, and finally tied with a bandage. In fractures, rubbing and straightening as well as pain-allaying medicine was employed, and finally sticks were applied all around as splints, being bound tightly with rags. (Vogel 1970:215)

What, though, about the situation for California? Culley (1936:337) has noted that California Indians used a species of Datura as an anesthetic for patients who were having fractures set. Bard, an early California physician, makes mention of the use of splints by native Californians during the 1800's:

> Quite a number of the thousands of skeletons which have been exhumed in Southern California show evidences of fractures which have been so nicely adjusted that no deformity resulted. To accomplish this purpose they used splints made of wood or of tules, twined together and smeared with asphaltum. (Bard 1930:22)

Fractures were a not uncommon injury in prehistoric California as attested to by the numerous examples in the literature. Roney (1959) found fourteen fractured bones in six individuals; Brabender (1965) noted up to 4.5% of the population of Ala-328 sustained fractures; and Ryan (1972), working with additional material from Ala-328 found an even higher percentage. Ryan does note that of seventeen long bone fractures, fully fifteen show malunion or pseudoarthrosis. He concludes by saying "the evidence also points strongly to the fact that these people did not set broken bones or in any way use great care to immobilize them." (Ryan 1972:28)

The ethnographic record, then, would have us believe that fracture setting and immobilization were not unknown to native Californians, while the archaeological record would severely weaken the notion of its presence, or at least its efficiency. One possible interpretation, which includes the merits of both arguments, is that some knowledge of fracture management

(setting and immobilization) was probably present but was, at the same time, inefficient. The argument for some sort of immobilization practice could be made solely on the grounds of its use to reduce pain without having to argue for its utilization as a device to immobilize realigned fracture segments. In the initial stages of fracture healing, before callous formation begins, immobilization (with or without rigid splinting) helps immeasurably to reduce the pain associated with the traumatic incident. Once callus formation began and the fracture site became somewhat stabilized intrinsically, the pain would be lessened and, if splints were used, they might be discarded regardless of the adequacy of alignment the fracture segments displayed. So splinting for immobilization to reduce pain may indeed have been practiced, even immobilization for realigned bone fractures but without modern radiographic techniques or internal fixative devices at their disposal, we should not expect much better results than the archaeological record tells us. We should also keep in mind that well-set and -immobilized fractures after a period of time will escape our detection unless a radiographic survey is performed to seek them out.

A combination of imperfect immobilization (thus allowing movement about the fracture site) and infection create a milieu for pseudoarthrosis formation that is vastly superior to either one alone. The gross and radiographic appearances of the fracture fragments would argue that an osteomyelitis was present at the fracture site, though probably of low-grade virulence and partially healed. The fragmented, comminuted nature of the fracture might allow us to propose that the fracture was also compound, i.e., fracture fragment/s protruding through the skin. With the proximal fragment being abducted to the degree it is here it is quite probable that its sharpened distal end penetrated the fibers of the overlying deltoid muscle, subcutaneous tissues and skin. A port of entry was thus readily available for microorganisms to penetrate to the traumatic region and allow infection to begin. That the infection was not terribly virulent, or host resistant very low, can be seen in the degree of healing and remodelling. The healing and remodelling, however, we can assume took place at a much slower rate than normal.

The literature distinguishes three kinds of pseudoarthrosis: congenital, defect, and pseudoarthrosis in the strict sense. Aegerter and Kirkpatrick (1975:184) have defined the congenital, hereditary variety as "a pathologic entity characterized by deossification of a weight-bearing long bone, bending, pathologic fracture, and inability to form normal callus in healing." Defect pseudoarthroses occur following injuries which cause large osseous defects and are often associated with soft tissue damage and infection (Verbeek and Dubbelman 1962:5). Pseudoarthrosis in the strict sense refers to false-joint formation following delayed or nonunion in the manner we have been discussing so far.

The specimen presented here reveals the typical appearance of a pseudoarthrosis with a ball on the longer and a socket on the shorter fracture segments. Because of the loss of normal functional movements in many instances, the bones distal to the pseudoarthrosis become decalcified;

but since the forearm, wrist and hand bones are missing we cannot examine this phenomenon here. The highly developed nature of this false ball-and-socket joint, though, suggests a fairly loose, unstable joint with at least a moderate loss of normal distal functions.

The fracture fragment ends in a pseudoarthrosis are nearly always broadened and this should be considered a degree of adaptation. For as Verbeek and Dubbelman (1962:10) note, "with failure of union, nature resorts to the makeshift of a broadening of support surfaces (bone ends) and the formation of a fibrin capsule of connective tissue to connect these surfaces. This leads to an unusual structure [the pseudoarthrosis]."

Shands and Rainey (1967) note that ununited fractures (with or without pseudoarthrosis) of the middle third of the humerus are relatively common (no figures given) and usually result from inadequate initial approximation of the fragment ends and poor immobilization. In all probability this was the case for our prehistoric resident of Marin County. That adequate apposition and realignment was not obtained is obvious. However, we are confronted with interpreting a comminuted fracture in which one end (the proximal) of the middle fragment fused while the other end failed to do so. Adequate interpretation here relies on a knowledge of muscle attachments, i.e., their origins and insertions, and their pull on bone fragments when there is a complete fracture. Muscle pulls on fracture fragments usually present a characteristic appearance.

In this instance the proximal fracture site shows overriding of the proximal fragment and shortening. This consequence is produced by the action of the supraspinatus m., which inserts on the greater tubercle of the humerus and abducts the proximal fragment while the long muscles which bridge the fracture site (i.e., deltoid, coracobrachialis, biceps and triceps mm.) draw the distal fragment superiorly. The result of this overriding and shortening is a fairly well immobilized, but poorly apposed, proximal fracture site. Even without proper, sustained immobilization this fracture site has a fair chance of uniting. The distal fracture site which has been drawn superiorly by the action of the long muscles mentioned above, does not have the stability of the proximal site resulting from the impaction caused by overriding and shortening. Consequently the distal fracture site is liable to much more instability and motion - the perfect prerequisites for pseudoarthrosis formation. Mobility of the proximal fragment is also greatly lessened by the counterbalanced pull of the muscles which make up the so-called rotator cuff.

An omnipresent problem in paleopathological analysis and interpretation is the differential diagnosis of the specimen. Stewart (1974) concludes his discussion of nonunited forearm fractures with a plea to keep in mind the simpler explanations rather than exploiting the more bizarre opportunities which, although certainly more exciting, have no better basis in terms of etiology. Stewart cites two cases of supposed amputation (Brothwell and Moller-Christensen 1963; Saul 1972) and reasonably argues that nonunited fractures are just as viable alternative interpretations.

More recently in this regard, Rogers (1973) has presented a case of putative amputation at the midshaft of the humerus from aboriginal Peru. The specimen is the proximal half of a humerus with a smoothly rounded end and without the distal fragments. Rogers' interpretation of this specimen apparently relies heavily on the indirect association that since the precolumbian Peruvians practiced surgery, i.e., trephination, and since a pottery figurine depicts a man with an amputated foot and stump cap, they must have practiced surgical amputation; therefore this specimen represents such an instance. This argument appears reasonable, and it is; but other possibilities (i.e., a differential diagnosis) must be entertained and this Rogers has failed to do. Even granting this is a case of amputation, to emphatically state it is surgical in origin precludes the possibility of autoamputation through some disease process (e.g., leishmaniasis, blastomycosis, leprosy, gangrene and others) or the remains of a nonunited fracture or pseudoarthrosis.

The point is, whenever one is faced with a diagnostic problem in paleopathology one should, just as the practicing physician, propose a differential diagnosis and not exclude, without good reason, any diagnostic alternative which could manifest itself in the form at hand. A single disease process may have numerous and highly variable manifestations, but many distinct diseases and other processes often appear identical. This is especially true in the interpretation of dry osseous lesions in which a more definitive diagnosis based cellular detail cannot be accomplished.

Literature Cited

Aegerter, E. and J.A. Kirkpatrick, Jr.
1975 Orthopedic Diseases, 4th ed. Philadelphia: W.B. Saunders.

Bard, Cephas L.
1930 Medicine and surgery among the first Californians. Touring Tropics 22:20-30.

Brabender, Ingrid
1965 Beitrag zur palaobiologischen Rekonstruktion prahistorischer kalifornischer Populationen. Homo 16, Band 4:200-230.

Brothwell, D.R. and V. Moller-Christensen
1963 A possible case of amputation, dated to c. 2000 B.C. Man 63:192-194.

Cameron, Bruce M.
1966 Shaft Fractures and Pseudarthroses. Springfield: C.C. Thomas.

Culley, John
1936 The California Indians: their medical practices and their drugs. Journal of the American Pharmaceutical Association 25(4):337.

Lichtenstein, Louis
1970 Diseases of Bone and Joints. St. Louis: C.V. Mosby.

Rogers, Spencer L.
1973 A case of surgical amputation from aboriginal Peru. San Diego Museum of Man, Ethnic Technology Notes No. 11.

Roney, James G., Jr.
1959 Paleopathology of a California archaeology site. Bulletin of the History of Medicine 33:97-109.

Ross, Cornelius and D. Kay Clawson
1970 Introduction to the Musculoskeletal System. New York: Harper and Row.

Ryan, Dennis John
1972 The paleopathology of Ala-328: the relationships among disease, culture, and environment in a California Indian population. Unpublished M.A. Thesis, Department of Anthropology, San Francisco State University.

Saul, Frank P.
1972 The human skeletal remains of Altar de Sacrificios: An osteobiographic analysis. Papers of the Peabody Museum of Archaeology and Ethnology, Harvard University, No. 63.

Shands, A.R., Jr. and R.B. Raney, Sr.
1967 Handbook of Orthopaedic Surgery, 7th ed. St. Louis: C.V. Mosby.

Stewart, T.D.
1974 Nonunion of fractures in antiquity, with descriptions of five cases from the New World involving the forearm. Bulletin of the New York Academy of Medicine 50:875-891.

Verbeek, O. and C.P. Dubbelman
1962 Pseudoarthrosis of the Long Bones. Chicago: Year Book Medical Publishers.

Vogel, Virgil J.
1970 American Indian Medicine. Norman: University of Oklahoma Press.

Plate 1: Fractured humerus with pseudoarthrosis formation, site Mrn-242

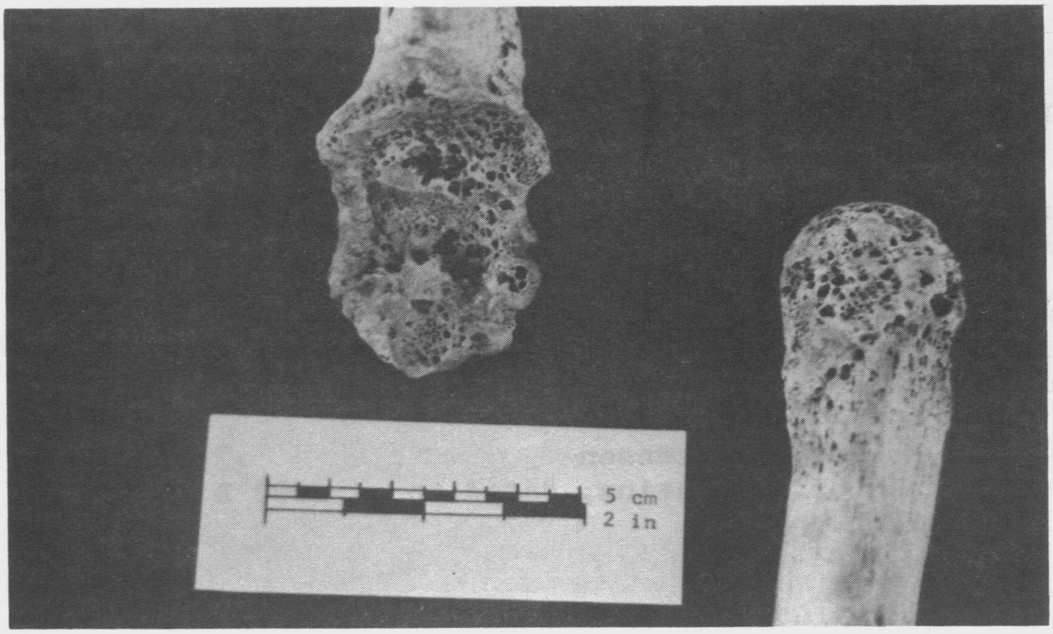

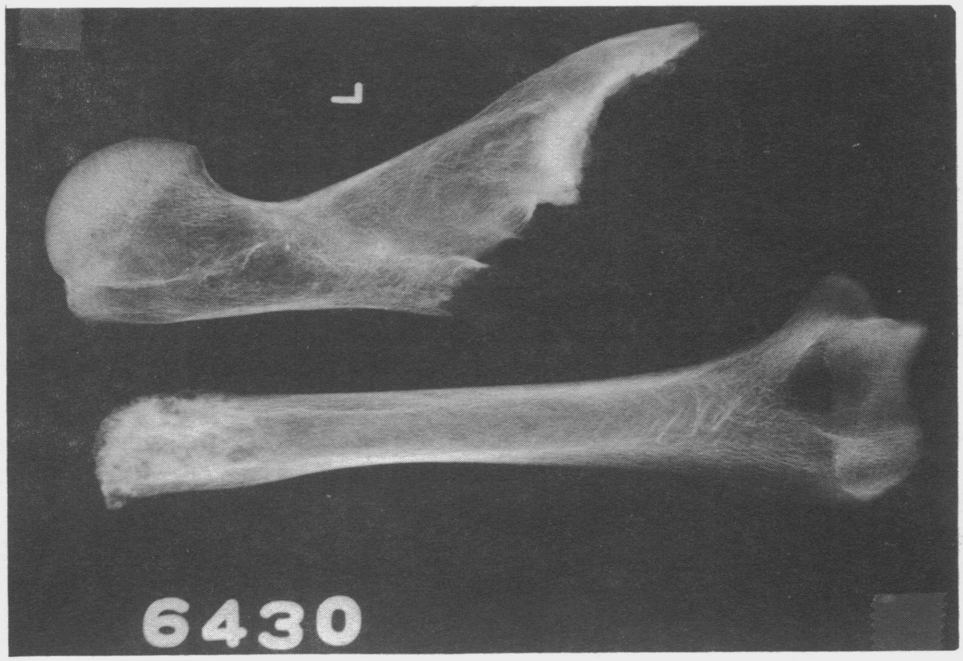

Plate 2: Detailed view of articular surfaces of pseudoarthrosis
X-ray of pseudoarthrosis.

Literature Cited

Aegerter, E. and J.A. Kirkpatrick, Jr.
1975 Orthopedic Diseases, 4th ed. Philadelphia: W.B. Saunders.

Bard, Cephas L.
1930 Medicine and surgery among the first Californians. Touring Topics 22:20-30.

Brabender, Ingrid
1965 Beitrag zur palaobiologischen Rekonstruktion prahistorischer kalifornischer Populationen. Homo 16, Band 4:200-230.

Brothwell, D.R. and V. Moller-Christensen
1963 A possible case of amputation, dated to c. 2000 B.C. Man 63:192-194.

Cameron, Bruce M.
1966 Shaft Fractures and Pseudarthroses. Springfield: C.C. Thomas.

Culley, John
1936 The California Indians: their medical practices and their drugs. Journal of the American Pharmaceutical Association 25(4):337.

Lichtenstein, Louis
1970 Diseases of Bone and Joints. St. Louis: C.V. Mosby.

Rogers, Spencer L.
1973. A case of surgical amputation from aboriginal Peru. San Diego Museum of Man, Ethnic Technology Notes No. 11.

Roney, James G., Jr.
1959 Paleopathology of a California archaeology site. Bulletin of the History of Medicine 33:97-109.

Ryan, Dennis John
1972 The paleopathology of Ala-328: the relationships among disease, culture, and environment in a California Indian population. Unpublished M.A. Thesis, Department of Anthropology, San Francisco State University.

Saul, Frank P.
1972 The human skeletal remains of Altar de Sacrificios: An osteobiographic analysis. Papers of the Peabody Museum of Archaeology and Ethnology, Harvard University, No. 63.

Shands, A.R., Jr. and R.B. Raney, Sr.
1967 Handbook of Orthopaedic Surgery, 7th. ed. St. Louis: C.V. Mosby.

Stewart, T.D.
1974 Nonunion of fractures in antiquity, with descriptions of five cases from the New World involving the forearm. Bulletin of the New York Academy of Medicine 50:875-891.

Verbeek, O. and C.P. Dubbelman
1962 Pseudoarthrosis of the Long Bones. Chicago: Year Book Medical Publishers.

Vogel, Virgil J.
1970 American Indian Medicine. Norman: University of Oklahoma Press.

STUDIES IN CALIFORNIA PALEOPATHOLOGY

III. ENLARGED PARIETAL FORAMINA - THEIR MORPHOLOGICAL VARIATION AND USE IN ASSESSING PREHISTORIC BIOLOGICAL RELATIONSHIPS

J. Michael Hoffman

Among the many goals of the prehistorian is the reconstruction of human relationships in time and space. The data utilized in reconstructing these relationships fall into two broad categories: cultural and biological. Cultural data include the many and diverse artifacts associated with archaeological sites, their structures, settlement patterns and all the inferences derived therefrom: subsistence and economic systems, demography, and social, religious and ideologic systems among others. Human biological relationships in prehistory, however, are limited to the skeletal remains of the members of these prehistoric populations. Here three kinds of data may be utilized: morphological, craniometric, and discrete variations or anomalies (Anderson 1968:135).

Morphological assessment entails the nonmetric description of continuous characteristics, often to the point of making population comparisons solely on typological grounds (e.g., Gifford 1926). For the most part this technique has been abandoned by the majority of contemporary physical anthropologists. Craniometric evaluations are grounded in the quantitative expression of absolute size and relative proportions. Population assessments based on this technique, usually employing a multivariate measure, assume that at least part of the variance observed among and between populations for these measures is genetic in origin. Because of the uncertainty of the genetic origin (or at least component) of these measures, caution should be used in their interpretation (cf. Howells 1973 and Kowalski 1972). More recently, and again primarily using a multivariate measure, discrete or nonmetric analyses have been employed in assessing biological relationships. This methodology employs a distance measure based on the presence or absence (and therefore the relative frequency) of discrete skeletal variations or 'anomalies.' Evidence indicates there is a strong genetic component to the expression of at least some of these traits and, therefore, they should be a better measure of genetic relationships than metric data. However, except for a few of these traits, our knowledge of their genetic basis in man is rather uncertain.

This paper, then, presents a series of prehistoric skulls from the San Francisco Bay region which demonstrate such a known, genetically-speaking, skeletal anomaly - enlarged parietal foramina. The possible implications of the distribution of these skulls follows their description.

The Specimens

The following abbreviations are used in the catalog numbers of the crania:

S.I. = Smithsonian Institution

S.A. = Stanford Anatomy

LSJM = Leland Stanford Junior Museum

LMA = Lowie Museum of Anthropology

Smithsonian Institution (descriptions and measurements courtesy of Dr. J. Lawrence Angel): two specimens from the Ponce Mound (also called Castro Site, et al., 4-SC1-1) near Palo Alto, CA., collected and donated by Harold Heath in 1913.

S.I. #276981 - an adult male ca. 24 years old, with closure of the sagittal and lambdoid sutures; there is premature synostosis but little or no deformation; Angel notes there are "two beautiful, symmetrical enlarged foramina looking like the eyeholes in a Shang dynasty bronze mask;" (Plate 1).

S.I. #276982 - a child ca. four years old with "gross cranial deformation skewing the vault from lower right toward upper left and complete premature fusion of coronal, right upper lambdoid, and sagittal sutures;" the enlarged foramina appear as two slits "looking like scars actually, but obviously not traumatic." (Plate 1).

Stanford University: nine skulls from the Ponce Mound site, eight collected in the 1930's by Prof. Meyer of the Department of Anatomy, Stanford University School of Medicine (hence the S.A. designation), and one donation (LSJM #75.1055) by Mr. Victor Buenzle in 1975; all skulls are presently in the Department of Anatomy, Stanford University, except crania S.A. 83 and LSJM #75.1055 which are in the anthropology collections of the Leland Stanford Junior Museum.

S.A. 22 - adult, female (?), with all major cranial vault sutures intact; there is moderate flattening bilaterally at the junctions of the occipital, temporal, and parietal bones; the foramina are large, open, oval structures; (Plate 2).

S.A. 23 - adult, male (?), displaying single, small, trilobed foramen just lateral to the sagittal suture on the left; the left infratemporal region is missing and there is slight crushing with distortion; the right lower 1/3 of the coronal and the middle 1/3 of the sagittal sutures are closed; there is slight lambdoid flattening and mild vault keeling; (Plate 2).

S.A. 24 - adult, female, with metopic suture nearly intact except for short superior segment; posterior 1/3 of the sagittal suture is fused; several small osteomata appear on the vault; there is slight lambdoid flattening and bilateral flattening as in S.A. 22; the foramina are large oval defects: (Plate 2).

S.A. 25 - adult, male(?), with fused coronal, sagittal and lambdoid sutures and mild vault keeling; there is slight lambdoid flattening and the bilateral flattening noted in S.A. 22 and 24; on

the left, two, small (< 2mm) foramina are present in a single dimpled depression separated by a thin bridge of bone; a partially closed slit extends laterally from the depression; the right parietal foramen has a slit extending 2.5 mm laterally and a remnant of a slit medially - all in a slight dimpled depression; another fragment of the original enlarged foramen on the right appears as a dimple slightly inferior and medial to the main extant foramen; (Plate 2).

S.A. 26 - adult, male(?), with fusion of middle 1/2 of the lambdoid and the anterior 1/2 of the sagittal sutures; there are open, oval foramina of unequal sizes; (Plate 3).

S.A. 49 - adult, female, with fusion of the right half and part of left portion of the coronal, the anterior sagittal, and the medial aspect of the left half of the lambdoid sutures; there is slight lambdoid flattening and mild vault keeling; the left foramen is a small dimpled depression with a thin plate of bone nearly closing the orifice; the right foramen is generally oval in shape but the superolateral aspect has narrowed due to an ingrowth of bone from the inferolateral border of the foramen, giving the foramen an outline appearance of a curve-necked gourd; (Plate 3).

S.A. 54 - adult, male; the left foramen is small with a slit extending laterally from the superior border; remnants of the right foramen appear as two small dimples, both open in a slight depression; all sutures are intact except for the extreme posterior end of the sagittal which is fused; (Plate 3).

S.A. 83 - child of approximate dental age of 12 years (all four permanent second molars just reaching occlusal plane); the skull, showing evidence of partial cremation, is warped such that there has occurred a continuous separation along suture lines beginning with the left half of the coronal and continuing along the sagittal and the right half of the lambdoid, resulting in the occipital, left parietal and left temporal forming a separate unit of the cranial vault; all vault sutures are intact; there are large accessory ossicles at the parietomastoid sutures bilaterally; the enlarged left parietal foramen is roughly rectangular in shape while the oval right foramen shows slits at its medial and lateral extremities due to the progress of closure of the foramen; the associated post-cranial material is unremarkable; (Plate 4).

LSJM #75.1055 - adult, female, ca. 20 years old (basilar suture partially closed, third molars erupted with mild occlusal wear); a metopic suture is wholly intact; there are large accessory ossicles at the parietomastoid sutures bilaterally and a single accessory ossicle ca. 1.5 cm in diameter in the midportion of the sagittal suture; the foramina are large, oval defects; there is bilateral tympanic plate dehiscence; (Plate 4).

Lowie Museum of Anthropology: two skulls from 4-CCo-138, a Late Horizon site from Contra Costa Co., CA., collected by E.N. Johnson in 1937.

LMA #12-5575 - adult, female(?); although the sagittal suture is nearly obliterated, approximately 4 cm posterior to bregma a remnant of it deviates to the right and continues 3.5 cm to end in the right

parietal about 2 cm above the medial 1/3 of the right parietal foramen; the lateral aspects of the lambdoid suture are partly fused, and the medial part of the lambdoid nearly or completely fused and appear to terminate in the middle of the inferior borders of each foramina on their respective sides rather than in the midline at the posterior terminus of the sagittal suture; portions of the coronal suture are beginning to fuse; the foramina are extremely large, oval structures; (Plate 4).

LMA #6246 - adult, female, 52-59 years old (after Gilbert and McKern 1973) the sagittal suture is completely obliterated giving the skull a moderately keeled appearance; the lambdoid suture is completely and the coronal nearly obliterated; a shallow groove connects the large, oval parietal foramina across the midline, immediately below which is a prominent, smoothly rounded bump 2 cm in diameter; the occipital squama has a slight oval depression (4 x 2.5 cm) with a central area of fine osteoporotic bone; (Plate 4).

Dimensional aspects of the foramina are found in Table 1.

TABLE 1

Measurements of enlarged parietal foramina
(All measurements in mm except axis angle)

Specimen #	Greatest diameter		Maximum diameter perpendicular to greatest diameter		Axis angle with horizontal		Medial corner distance to midline		Lower border distance above lambda	
	L	R	L	R	L	R	L	R	L	R
S.I. 276981	18.2	21.1	10.8	13.2	+40°	+47°	9.5	8.0	20.0	17.0
S.I. 276982	18.8	15.9	3.0	1.5	+15°	-16°	13.0	17.0	7.0	0
S.A. 22	12.5	13.9	7.6	7.2	+35°	+40°	14.5	13.7	19.0	16.0
S.A. 23	4.2	--	2.8	--	+80°	--	on mid-line	--	33.6	0
S.A. 24	16.6	13.6	8.8	8.3	+30°	+35°	8.1	9.0	8.1	9.8
S.A. 25	--	2.4	--	2.2	--	+10°	12.5*	21.0	15.0	19.0
S.A. 26	8.0	17.9	4.6	10.2	+30°	+15°	11.5	10.5	13.6	9.3
S.A. 49	2.4	13.4	1.2	4.2	+35°	+40°	11.4	13.8	9.5	7.8
S.A. 54	2.4	--	2.0	--	+35°	--	10.7	--	39.2	
S.A. 83	20.4	12.8	7.5	5.3	+35°	+30°	12.0	16.6	6.0	8.0
LSJM 75.1055	17.1	25.3	11.5	16.6	+10°	+18°	15.5	8.5	16.0	10.0
LMA 12-5575	35.5	37.4	26.9	28.0	+10°	+10°	10.0	5.0	n.d.	n.d.
LMA 12-6246	14.7	15.9	10.0	8.5	+5°	0°	7.3	7.3	n.d.	n.d.

n.d. = not determinable

-- = feature missing

* = distance from medial corner of depression

Discussion

Enlarged Parietal Foramina

In the normal cranial vault there exist, either paired or single, a number of emissary veins which pass through various foramina in the cranial wall to establish communications between intracranial venous sinuses and extracranial veins. Among these is the parietal emissary vein which passes through the parietal foramen to connect the superior sagittal sinus with scalp veins; occassionally a branch of the occipital artery is also carried along. The parietal foramen in the normal state is usually 1 mm or less in diameter and located a few centimeters above lambda just lateral to the sagittal suture; it may appear as a paired or single opening, may be absent altogether, or be closed but still discernible (Newton and Potts 1971; Pendergrass et al. 1956; Warwick and Williams 1973). Very rarely, however, the parietal foramen may not ossify normally and result in a round or oval defect that may be several centimeters in diameter. This cranial anomaly is termed enlarged parietal foramina (*foramina parietalia permagna*).

The early anatomical literature gave mention of enlarged parietal foramina and in 1865 Turner published the first adequate description. The anomaly has also been called the "Catlin mark" after Goldsmith (1922) published an account of 16 cases in five generations of the Catlin family. Lother (1959) has described a series of five cases in two generations, thus helping establish the trait as familial and hereditary in origin. In his catalog of inherited phenotypes in man, McKusick (1975) lists the trait as an autosomal dominant and examination of the existing pedigrees mentioned (plus Miller and Keagy 1956) supports this. In those pedigrees where the pattern of inheritance does not seem to hold, the most reasonable explanation is there are individuals in which the originally enlarged parietal foramen has closed to such an extent that it cannot be detected radiographically or by palpation. That this happens with some regularity can be seen in the present series and surmised from the variation seen in other examples already cited or in Pepper and Pendergrass (1936) and Keats (1973).

Enlarged parietal foramina have been classified as atrophic (hypoplastic) changes in the cranial vault (Newton and Potts 1971:209) and are felt to be secondary to faulty ossification of the parietal fontanelle (also called the sagittal or third fontanelle [Warkany 1971:891]). This latter structure is very rarely mentioned in anatomy texts but is situated along the sagittal suture about 2/3 to 3/4 of its length posteriorly, i.e., at the *pars obelica* of the sagittal suture. Early in fetal life, and occasionally following birth (Goldsmith 1922; Miller and Keagy 1956; Murphy and Gooding 1970; Pendergrass and Pepper 1939), the parietal fontanelle forms a large single opening along the sagittal suture and later divides into two parts by a bridge of bone growing along the midline. The site of the divided parietal fontanelle is the same as normal parietal foramina. The result is two, roughly symmetrical, bilateral parietal defects just lateral to the sagittal suture and a few centimeters above lambda. The foramina often persist as large defects throughout life, or may partially or completely close; in the

latter instance there will usually be some gross manifestation of the remnant which may or may not be detectable except in dry, preserved crania. Warkany (1971: 891) provides an excellent description of this ossification sequence.

For the osteologist who handles dry bone on a regular basis, this anomaly is easily recognized by its characteristic appearance and location, although it may very rarely occur in the anterior 1/3 of the parietal bone (Epstein and Davidoff 1953:67). For the radiologist and others who must differentiate this phenomenon in the living individual from other, more serious possibilities, the differential diagnosis includes (after Pendergrass et al. 1956; Silverman 1968; Warkany 1971):

meningocoele

epidermoidoma

infection (yaws, syphilis)

histiocytosis X

dysostosis (cleidocranial) of the cranial bones

osteoporosis circumscripta

renal and celiac rickets

primary or secondary metastatic neoplasm

surgical defects (burr holes or trephine openings)

multiple myeloma.

As the present series demonstrates there is a rather wide range of variation in size and general morphology of enlarged parietal foramina. The foramina thus may present as large, oval defects which are easily detectable (e.g., LMA 12-5575, S.I. 276981), smaller foramina but still quite distinctive (e.g., S.A. 26, S.A. 49), or former openings which have nearly or completely closed (e.g., S.A. 25, S.A. 54). The foramina may appear as oval to round structures, rectangular openings, slits, dimpled depressions of irregular shape, or as irregular-shaped holes; the range of shape variation reflects to a great extent the degree of closure the previously open foramina have undergone.

In those specimens where the foramina are still patent, the edges are generally smooth, rounded, and give a bevelled appearance. The bevelling is present on both the endocranial and exocranial surfaces, with the latter usually showing a wider bevel space. The inside/outside nature of the bevelling should help to distinguish the phenomenon from trephine openings. Angel (personal communication) has also noted that "if one visualizes an interosseous membrane, as in the obturator foramen, formed from pericranium fusing with endocranium the edge is what one would expect." Angel also comments that "there are medial corner grooves...which ought to be for the emissary veins."

As with many other skeletal anomalies, enlarged parietal foramina are often associated with other defects (O'Rahilly and Twohig 1952; Pendergrass et al. 1956; Warkany and Weaver 1940; see Warkany 1971 for general review). Among the most frequently cited are cleidocranial dysostosis and metopism. The inability to associate postcranial material with the majority of the crania from the Ponce Mound lessened our attempt to detect the former association; in those crania with known postcranial material no abnormal clavicles were found. However, two skulls (S.A. 24 and LSJM 75.1055) manifest a persistent metopic suture. In none of the cases reported in the literature, though, was mention made of an interesting association found in the present series.

Since the basic defect in enlarged parietal foramina lies in faulty ossification of the parietal bones, one might expect to see abnormal ossification in other skeletal parts as well, particularly in nearby regions of the cranium. In the present series of 13 skulls, 10 manifest partial or complete closure of one or more major cranial vault sutures (i.e., coronal, sagittal, lambdoid). See Table 2. We must be careful, though, and recognize that some of these instances of suture closure merely reflect the biological age of the individual concerned. One difficulty with the present series, already noted, is the lack of associated postcranial material which would allow aging via the pubic symphysis. Thus, although we cannot age some of the individual skulls, and thereby state whether vault suture closure is premature or not, we can make some tentative predictions.

Premature closure of the major vault sutures produces characteristic vault deformities. Thus, craniostenosis of the sagittal suture produces scaphocephally or a skull with a "keel-shaped" vault with an osseous prominence where the obliterated suture had been. The portion of the parietals adjacent to the obliterated sagittal suture slope away and are flatter in appearance than the usual smoothly rounded vault; this is produced by the lateral pressure of the expanding brain mass. Early closure may occur at any time, but the later the craniostenosis occurs the less severe is the deformity. In the series under discussion, four of the crania that cannot be aged (S.A. 23,25,49; LMA 12-6246) show a mild or moderate keeling associated with complete or partial closure of the ectocranial aspect of the sagittal suture. I submit these as examples of partial or complete craniostenosis of the sagittal suture, albeit late in terms of the biological age of the specimens concerned.

The two Smithsonian skulls, one aged ca. 24 years, the other ca. 4 years, both show premature suture closure. In the infant this has resulted in the marked skewing of the vault (known as plagiocephaly) noted by Angel in the above description. With complete closure of the sutures in the 24 year old, we presume, as Angel notes, this individual represents an example of craniostenosis without deformation. Of the remaining crania, the degree of suture closure is compatible with the known age of the individual. Of our total series, then, six are considered to show an association of enlarged parietal foramina with craniostenosis of one or more major vault sutures, the amount of deformation produced ranging from severe to mild.

TABLE 2

DEGREE OF VAULT SUTURE CLOSURE IN CRANIA WITH ENLARGED PARIETAL FORAMINA

Specimen #	Age, in years*	Degree of suture closure** Sagittal	Coronal	Lambdoid	Appearance of foramina
S.I. 276981	ca. 24	C	O	C	large, open ovals
S.I. 276982[1]	ca. 4	C	C	P	open slits
S.A. 22	n.d.	O	O	O	large, open ovals
S.A. 23[2]	n.d.	P	P	O	small, round
S.A. 24	n.d.	P	O	O	large, open ovals
S.A. 25[2]	n.d.	C	C	C	partly closed
S.A. 26	n.d.	P	O	P	large, open ovals
S.A. 49[2]	n.d.	P	P	P	partly closed
S.A. 54	n.d.	P	O	O	partly closed
S.A. 83	ca. 20	O	O	O	large, open ovals
LSJM 75.1055	ca. 12	O	O	O	open, rectangular
LMA 12-5575	n.d.	C	P	P	large, open ovals
LMA 12-6246[2]	ca. 55	C	C	C	large, open ovals

* -n.d. = not determinable

** - C = closed
P = partially closed
O = open

1 - cranium deformed, i.e., plagiocephaly

2 - mild to moderate vault keeling

We should also note that the degree of suture closure, whether premature or not, is not associated with any particular degree of closure of the enlarged parietal foramina. The examples of craniostenosis are seen with large, open foramina or slits, while those crania with presumably normal suture closure have large open foramina or ones which are nearly closed. If there is some direct association between craniostenosis and enlarged parietal foramina, then it apparently does not involve the timing of the ossification processes.

Biological relationships in Central California

We noted at the outset of this paper that the reconstruction of prehistoric human biological relationships is essentially limited to the analysis of three kinds of data: morphologic, craniometric and nonmetric. Suchey (1975) has recently summarized these studies as they relate to prehistoric Central California. Actually, a fourth data set is available but, because of data preservation or the rarity of known data in this set, it is virtually unknown or unused in the context of assessing prehistoric biological relationships. We are referring here to traits that are known to be under strict genetic control with little or no environmental component in their expression. Data in this set include the myriad array of blood groups, serum proteins, genetic anomalies of various organ systems, and others. The lack of preservation of these 'soft tissue' indicators of underlying genetic structure is an obvious problem. But the skeleton contains numerous expressions of this sort which could potentially be used to solve the problem of prehistoric biological relationships. However, unlike the blood group and serum protein data which are seen as part of the broad range of normal human biological variation, these skeletal 'anomalies' are exceedingly rare and, unless one is dealing with an extremely localized problem, they are likely to be of little use. Fortunately this is the problem we are concerned with here.

The existence of a relatively large series of crania exhibiting enlarged parietal foramina from the greater San Francisco Bay region and adjacent interior is part of the lore among archaeologists who have worked in this region (Drs. Bert Gerow and Robert F. Heizer, personal communication). However, because of the lack of consistent reporting of this kind of material in such a way that it could be readily accessible to archaeologists and physical anthropologists, the implications of finding two groups of crania with this anomaly, of know pattern of inheritance, has not been made as strongly as it could have. Indeed, knowledge of the existence of this material was probably more widespread among the medical profession than among anthropologists through the publication of one of the Smithsonian crania (no. 276981) by Pepper and Pendergrass in 1936.

During a survey of New World skeletal material by Don R. Brothwell in the mid-1960's there was the first mention of the implications of this anomaly in assessing biological relationships. But here the record becomes rather confused and certainly incomplete. Brothwell notes:

> In discussing the inheritance of this condition in the living, Pepper and Pendergrass (1936) figure another ancient case, in this instance from a prehistoric Amerindian burial mound in Palo Alto, California....two further cases of this anomaly were noted from the Palo Alto site (one now in the Lowie Museum, Berkeley, California, and the other in the Smithsonian Institution, Washington). (Brothwell and Powers 1968:187-188)

The additional crania Brothwell mentions were found during his New World survey. We do not know, in fact, whether the specimen he 'found' in the Smithsonian was the same one (no. 276981) reported by Pepper and Pendergrass (1936) or if it was the second Smithsonian cranium (no. 276982) brought to my attention by J. L. Angel. Presumably it was the latter situation since Brothwell states that "two <u>further</u> cases of this anomaly were noted" and since he apparently was aware of the article by Pepper and Pendergrass (1936) which gives the catalogue number (276981) of the Smithsonian cranium displayed. However, the 'further case' housed in the Lowie Museum is apparently not from the Palo Alto site (a search of museum records and skeletal material has failed to disclose it) but is probably one from CCo-138, on the other side of San Francisco Bay and to the northeast in the interior some 50 miles away. And there is not one cranium in the Lowie Museum with this anomaly, but two--both from CCo-138. It is unfortunate, too, that Brothwell did not know of the existence of the series of crania housed at Stanford University which were from the same Palo Alto site mentioned. But even though the extant series from both sites was only partially known to him, Brothwell recognized the potential importance of the material:

> Although there is no certain evidence of the contemporaneity of these Amerindian cases, the proximity of the burials strongly suggests that we might have here prehistoric evidence of a marked anomaly influencing a family group (Brothwell and Powers 1968:188).

Had Brothwell known of the additional nine crania from Palo Alto, the certainty of having identified a family group would have been overwhelming. And had he known, or correctly identified, the Lowie Museum material as coming from an additional site in the interior region adjacent to San Francisco Bay, I feel certain he would have immediately grasped the implications of the distribution of the anomaly.

That we are dealing here with a single biological lineage can be argued from the rarity of the phenomenon and its localized distribution. As so many authors have noted, enlarged parietal foramina are rare hereditary, congenital anomalies. Hardly more than 100 examples have been reported in the medical and anatomical literature since Turner's first full exposition of the subject in 1865 and the vast majority of these represent clusterings in family groups. It apparently arises by spontaneous mutation and, because of its autosomal dominant pattern of inheritance, quickly spreads through succeeding generations. Since eleven of the present series of thirteen crania all derive from a single site we can probably say that they represent

a single prehistoric biological lineage. Because of the haphazard nature of the way the Palo Alto series was collected, however, we cannot state emphatically that this was the case.

The Palo Alto site (variously known as the Ponce Mound, Castro Mound, Mayfield Site, site 357, and SCl-1) had been a favorite local collection site for artifacts and skeletal material for nearly three-quarters of a century until its final burial beneath a recent construction project. In general, the Palo Alto material cannot be placed in any exact archaeological context because of its collection by untrained amateurs. In most cases we cannot even definitely associate postcranial remains with the crania. Despite the lack of good archaeological control for these specimens, it is generally recognized that the Ponce Mound dates from the Middle and Late Horizons of the Central California archaeological sequence.

Beardsley (1954) notes two occupation levels of the Ponce Mound site: component A and component B. Ponce A is known from burials located at depths of 12 to 39 or 52 inches and is felt to represent Phase I of the Late Horizon. Ponce B, of Middle Horizon context, is known from burials 39 or 52 or 93 inches in depth; in general, B component deposits are below a depth of 60 inches. The majority of the Stanford crania in this series were collected at the same time as other material presently housed in the Leland Stanford Junior Museum. Some of this latter material has brief original field notations which mention "specimen found at a depth of 3 feet" or merely "45 inches." If this, then, represents the general depth at which all or most of the Stanford Anatomy material was located, we may tentatively say this material is from component A and, therefore, is of Phase I, Late Horizon origin. This is partially supported by the fact that the Hotchkiss site (CCo-138) dates from Middle Phase I through Phase II of the Late Horizon (Bennyhoff in Cook and Heizer 1962). The lack of associated artifacts and/or archaeological control, however, limit the security of our dates for the Stanford Anatomy material.

We have, then, a series of thirteen crania, probably all dating from the Late Horizon, which manifest a very rare congenital skeletal anomaly of known autosomal dominant inheritance (McKusick 1975). They probably represent at least a portion of a biological lineage or "family." Obviously we cannot even begin to construct a pedigree, but that does not concern us so much here. Our concern and interest in this series stems from the fact it represents individuals from two widely separated sites in the San Francisco Bay area and adjacent interior; the Ponce or Castro Mound (SCl-1) from near Palo Alto in the southwest bay region and the Hotchkiss Site (CCo-138) to the northeast in the interior. That there was <u>some</u> degree of cultural continuity and contact in the greater San Francisco Bay region prehistorically has been noted by many authors (see general reviews in Heizer 1964, Frederickson 1974, Gerow and Force 1968, and Beardsley 1954) although the diversity among sites from various regions has been increasingly emphasized.

As noted above, Suchey (1975) has summarized all previous works on biological relationships among prehistoric Central California Indians and has also given us the most comprehensive study to date of this problem via her analysis of non-metric traits of the cranium. The real significance of this study, I believe, lies in its explicit recognition of the problems in interpreting biological distances based on non-metric data. Suchey notes (1975:127):

> A major question precipitated by this analysis was the extent to which environmental factors as well as genetic factors were being reflected in the MMD (based on the non-metric cranial traits). The hypothesized convergence of the Central California and Southern California coastal samples could only have been caused by natural selection or an environmental effect on the threshold. I suspect that it may be the latter since I find it difficult to see how these accessory sutures, foramina, and bony tori can be related to fitness, mate selection, or reproduction. Also certain similarities in the diet of these coastal samples seems to point in this direction.

The implications of this statement are great, especially when most biological distance studies implicitly assume that the 'distance' between two or more groups is some measure of their genetic distance. Often this assumption is quite explicitly stated, as for example in the following:

> The emphasis on discrete non-metric variants in this study underlies the identification of genetical patterns through morphological comparisons. Such traits have been found to be useful in delineating biological affinities among skeletal populations. (Cybulski 1975:17)

Until further studies are done which address themselves to the problems alluded to by Suchey, we should be very careful about statements which imply genetic relationships. And that is the advantage of using data such as enlarged parietal foramina. For although the data is very rare it is genetic in origin, and can be used, with caution, for saying something about genetic relationships in restricted localized areas. And so, for such a focal area in Central California, we have now fairly conclusive evidence that there was also direct biological contact, and not merely the mutual exchange of cultural goods between contiguous groups.

Was there really direct contact among the peoples of the Ponce and Hotchkiss sites? Obviously, we cannot say for certain. There may have been, as with the passage of trade goods "down the pike," exchange of genetic material between contiguous groups. But the lack of crania exhibiting enlarged enlarged parietal foramina in intervening populations weakens this idea. The original focus of the anomaly was probably in SCl-1 with subsequent diffusion of the gene outward. Perhaps a trading party or other group from SCl-1 made contact with the inhabitants of CCo-138 and the gene was then imparted into

the latter group. We could imagine any number of similar scenarios, all of which could be equally reasonable. But to do so would belabor the point.

The simplest explanation here, I think, is the most reasonable: there was direct biological contact between the populations, probably individuals from SCl-1 contacting those from CCo-138 at or near the Hotchkiss site itself. Whether there was a subsequent marriage or merely a fleeting relationship we cannot say; nor does it matter for the results would have been the same.

Summary and conclusion

A series of thirteen crania exhibiting a diverse pattern of variation in the expression of a hereditary, congenital skeletal anomaly has been presented. The crania with enlarged parietal foramina represent material from two widely separated sites in the San Francisco Bay region of California. Because of the rarity of this anomaly, its autosomal dominant mode of inheritance, and its focal appearance at two sites which are known to share some cultural material, it has been argued that we have represented here a portion of a prehistoric biological lineage and probably evidence for direct biological contact between the two sites which are some fifty land miles distant from one another.

It is important that archaeologists be cognizant of this kind of skeletal anomaly, including its variable expression, so they can alert interested osteologists for further analyses as well as recognizing for themselves the potential implications such material may have for their own archaeological reconstructions and interpretations.

Literature Cited

Anderson, James E.
1968 Skeletal 'anomalies' as genetic indicators. In Don R. Brothwell, ed., The Skeletal Biology of Earlier Human Populations, pp. 135-147. New York: Pergamon Press.

Beardsley, Richard K.
1954 Temporal and areal relationships in Central California archaeology. Part two. Univ. of Calif. Arch. Survey Rept. 25:63-127.

Brothwell, Don R. and Rosemary Powers
1968 Congenital malformations of the skeleton in earlier man. In Don R. Brothwell, ed., The Skeletal Biology of Earlier Human Populations, pp. 173-203. New York: Pergamon Press.

Cook, S.F. and R.F. Heizer
1962 Chemical analysis of the Hotchkiss Site (CCo-138). Univ. of Calif. Arch. Survey Rept. 57(1):1-25.

Cybulski, Jerome S.
1975 Skeletal variability in British Columbia coastal populations: a descriptive and comparative assessment of cranial morphology. National Museum of Man Mercury Series No. 30. Ottawa: National Museum of Canada.

Epstein, Bernard S. and Leo M. Davidoff
1953 An Atlas of Skull Roentgenograms. Philadelphia: Lea and Febiger.

Frederickson, David A.
1974 Cultural diversity in early Central California: a view from the North Coast ranges. Journal of California Anthropology 1(1):41-53.

Gerow, Bert A. and Roland W. Force
1968 An analysis of the University Village complex with a reappraisal of Central California archaeology. Stanford: Stanford Univ. Press.

Gifford, Edward Winslow
1926 Californian anthropometry. Univ. of Calif. Publ. in Amer. Arch. and Ethnol. 22(2):217-390.

Gilbert, B.M. and T.W. McKern
1973 A method for ageing the female os pubis. American Journal of Physical Anthropology 38:31-38.

Goldsmith, W.M.
1922 The Catlin mark; the inheritance of an unusual opening in the parietal bones. Journal of Heredity 13:69-71.

Heizer, Robert F.
1964 The western coast of North America. In J.D. Jennings and E. Norbeck, eds., Prehistoric Man in the New World, pp. 117-148. Chicago: Univ. of Chicago Press.

Howells, W.W.
1973 Cranial variation in man. Papers of the Peabody Museum 67:1-259.

Keats, Theodore E.
1973 Atlas of Normal Roentgen Variants that may simulate Disease. Chicago: Year Book Medical Publishers.

Kowalski, Charles J.
1972 A commentary on the use of multivariate statistical methods in anthropometric research. American Journal of Physical Anthropology 36:119-132.

Lother, K.
1959 Familiares vorkommen von foramina parietalia permagna. Archiv. Kinderheilk 160:156-168.

McKusick, Victor A.
1975 Mendelian Inheritance in Man, 4th ed. Baltimore: Johns Hopkins Univ. Press.

Miller, M.W. and R.M. Keagy
1956 Enlarged parietal foramina. Eight examples in four generations. Medical Radiography and Photography 32:74-76.

Murphy, James and Charles A. Gooding
1970 Evolution of persistently enlarged parietal foramina. Radiology 97:391-392.

Newton, Thomas H. and D. Gordon Potts, eds.
1971 Radiology of the Skull and Brain. The Skull, Vol. 1, Book 1. St. Louis: C.V. Mosby.

O'Rahilly, R. and M.J. Twohig
1952 Foramina parietalis permagna. American Journal of Roentgenology 67:551-561.

Pendergrass, E.P. and O.H.P. Pepper
1939 Observations of the process of ossification in the formation of persistent enlarged parietal foramina. American Journal of Roentgenology 41:343-346.

Pendergrass, E.P., J.P. Schaeffer, and P.J. Hoeds
1956 The Head and Neck in Roentgen Diagnosis. Vol. 1, 2nd ed. Springfield: C.C. Thomas.

Pepper, O.H.P. and E.P. Pendergrass
1936 Hereditary occurrence of enlarged parietal foramina. American Journal of Roentgenology 35(1):1-8.

Silverman, Frederick N.
1968 The bones and joints. In H.L. Barnett, ed., Pediatrics, 14th ed., pp. 1582-1583. New York: Appleton-Century-Crofts.

Suchey, Judy Myers
1975 Biological distance of prehistoric Central California populations derived from non-metric traits of the cranium. Unpublished Ph.D. dissertation, Dept. of Anthropology, Univ. of California, Riverside.

Turner, W.
1865 On some congenital deformities of the human cranium. Edinburgh Medical Journal 11:7-13, 133-141.

Warkany, Josef
1971 Congenital Malformations. Chicago: Year Book Medical Publishers.

Warkany, J. and T.S. Weaver
1940 Heredofamilial deviations: enlarged parietal foramens combined with obesity, hypogenitalism, microphthalmos and mental retardation. American Journal of Diseases in Children 60:1147-1154.

Warwick, R. and P.L. Williams
1973 Gray's Anatomy, 35th British ed. Philadelphia: W.B. Saunders.

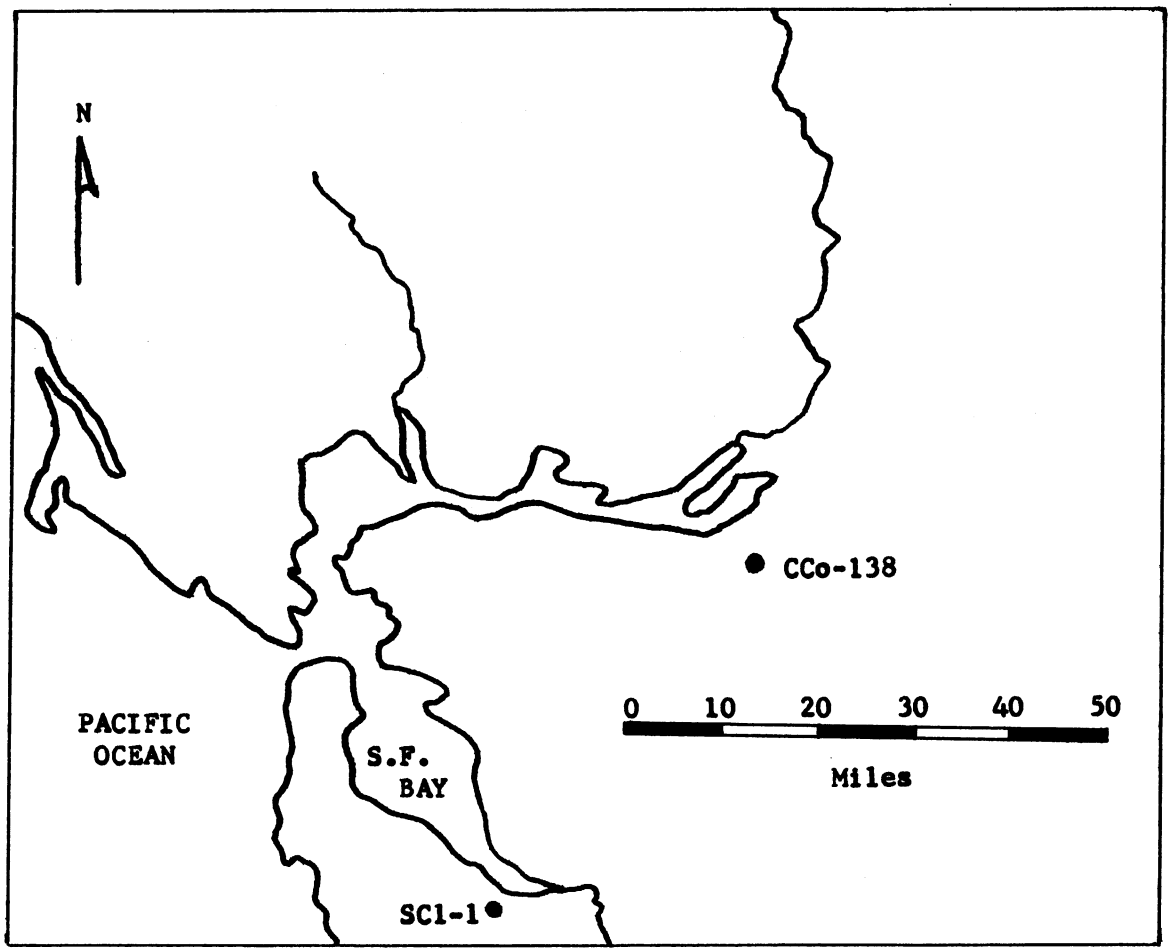

Figure 1: Geographic locations of SC1-1 (Ponce Mound) and CCo-138 (Hotchkiss Site)

Plate 1: Crania showing enlarged parietal foramina. (Photo courtesy of Dr. J.L. Angel, Smithsonian Institution, Washington, D.C.)
Left: S.I. #276981; right: S.I. #276982 (note skewing of cranial vault)

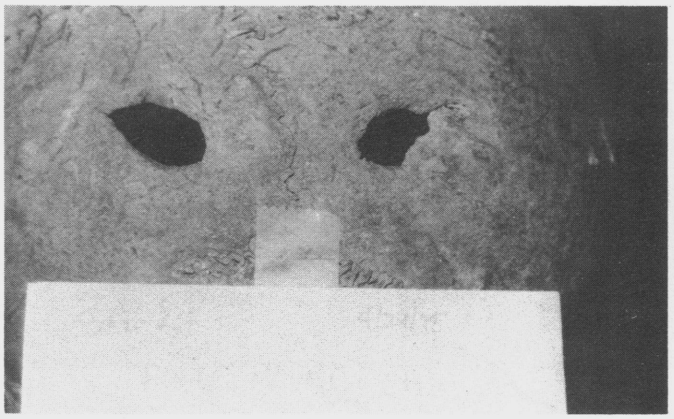



Plate 2: Crania showing enlarged parietal foramina. Top row: left, S.A. 22; right, S.A. 23. Bottom Row: left, S.A. 24; right, S.A. 25.





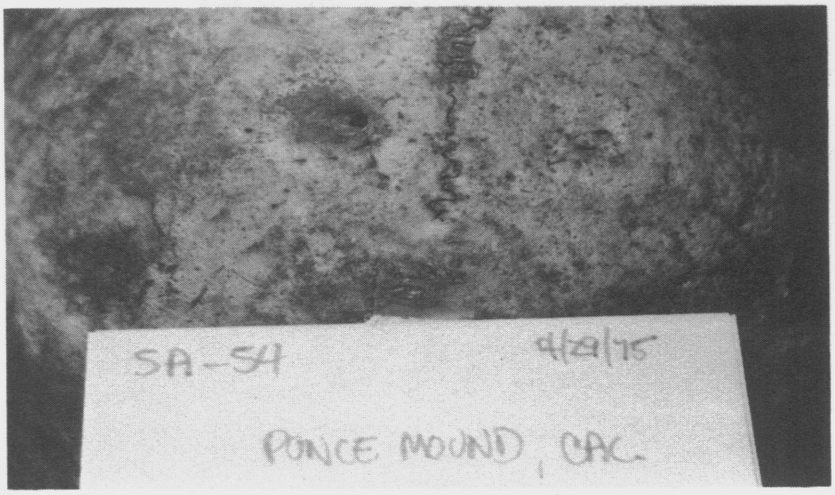

Plate 3: Crania showing enlarged parietal foramina. Top: S.A. 26; middle: S.A. 49; bottom: S.A. 54.



Plate 4: Crania showing enlarged parietal foramina. Top row: left, S.A. 83; LSJM #75.1055. Bottom row: left, LMA 12-5575; right, LMA 12-6246.

STUDIES IN CALIFORNIA PALEOPATHOLOGY:

IV. AN ACHONDROPLASTIC DWARF FROM THE AUGUSTINE SITE (CA-Sac-127)

by

J. Michael Hoffman

with a radiographic interpretation by Dr. James O. Johnston

INTRODUCTION

That dwarfs, especially the achondroplastic variety, have occupied a prominent place in paleopathological studies for many decades cannot be denied. Numerous reports of prehistoric examples of dwarfs in general and achondroplastics specifically, represented by indirect artistic and/or direct skeletal evidence, have been summarized for both the Old World (Brothwell 1967; Janssens 1970; Ruffer 1921; Warkany 1971; Wells 1964, et al.) and the New World (Coe 1965; Corson 1972; Linne 1943; Proskouriakoff 1949; Snow 1943; Thompson 1970; and von Winning 1974, among others).

Although the New World contains as many if not more artistic representations of dwarfs than the Old World, the latter has provided us with the majority of skeletal remains that can be considered prehistoric achondroplastics. Snow's (1943) review of prehistoric Native American dwarf skeletons indicates that this phenomenon was probably not so rare, given the number of specimens described. But as Brothwell (1967:434) notes, all specimens have been lost except for the two Moundville, Alabama, individuals reported in detail by Snow himself (1943).

There has recently been brought to light a previously unreported prehistoric achondroplastic dwarf from central California, now housed in the collections of the Lowie Museum of Anthropology (LMA), University of California, Berkeley. Since this individual apparently represents only the third extant prehistoric achondroplastic dwarf skeleton from the New World, a full description, interpretation and comments bearing upon its importance are presented herein. This paper, then, represents the detailed reporting of this specimen first mentioned by Hoffman (1975: 3) in a preliminary note.

Provenience

The specimen (LMA catalogue #12-6670) was excavated in 1938 by a field crew from Sacramento Junior College under the overall direction of Prof. J. B. Lillard. The locality, known as the Augustine Site (CA-Sac-127), is generally located one mile south of Sloughhouse, Sacramento County, California, or about 18 miles southeast of the city of Sacramento. The Augustine Site was initially excavated in 1933 by Sacramento Junior College which continued archaeological work at the site every year until 1938. Although a great deal of skeletal material was recovered during this period of time, the records relating to the individual under discussion are virtually nonexistent. The original field notes from the excavation (assembled by Franklin Fenenga in 1941 and now in the possession of the Archaeological Research Facility, UC-Berkeley, as Ms. 42) make no mention of the recovery of a dwarf except as the title for a photograph of the post-excavated, articulated bones at the end of the manuscript, "Sac-127. Final burial from 1938 diggings. 12-6670." An examination of all the written notes from the 1938 field season fails to disclose any additional information, except for a comment dated May 21, 1938, by Lillard himself, "We found holes (test pits) made five years ago and excavated a few fragmentary and one well-placed burial" (Ms. 42, p. 169). We

cannot, however, assume this was the dwarf, even though May 21 was the last date included in the field notes. The end result is the inability to assign any chronological placement for the dwarf based on direct archaeological associations. However, two other indirect lines of evidence may help in the dating problem.

As reported by Grady (1969), the original burial complex at the Augustine Site excavated by Sacramento Junior College during the 1933-1938 field seasons has been associated with the Late Horizon, Phase II (A.D. 1500-1800), of the central California archaeological sequence. Although we have no definitive documentation to support this, we might presume that the dwarf is part of that original complex. Additionally, an examination of the general condition of the dwarfed skeletal remains is consistent with other known Late Horizon material from the Augustine Site (Dr. James Bennyhoff, personal communication), and not with more recently excavated material from the Rooney Extension (CA-Sac-127R) which supposedly comes from Middle Horizon components of the site (Grady 1969). We may very tentatively, then, posit that the dwarf is from the Late Horizon and not the Middle Horizon as originally reported (Hoffman 1975: 3). We must note, almost parenthetically, that since this specimen is so unique and valuable no destruction of the skeleton proper can be justified for absolute dating purposes at this time.

'Rediscovery' of the dwarf in the Lowie Museum

It is difficult to ascertain the history of this skeleton after its arrival at the Lowie Museum in the 1940's. Original cataloguing information indicates that it was recognized as a dwarf at the time of accession but it apparently elicited no great interest for it was never, to our knowledge, formally reported in any publication. Discussions with museum personnel and other osteologists who have worked with the museum's skeletal collections indicate that various people knew of its existence at intermittent times over the last decade or more; given this knowledge it is still difficult to understand why such a unique and valuable individual was never formally reported. In addition, at some point in the past (probably since its arrival at the Lowie Museum), the individual was reconstructed and fully articulated, possible for display purposes.

When the skeleton was first brought to my attention in early spring, 1975, the results of the prior reconstruction were still quite evident. Individual plaster intervertebral discs had been made and the entire vertebral column glued together into four or five major segments. Various reconstructions were done in plaster, for the entire right innominate, portions of both femora and other miscellaneous areas. The three major long bones of each extremity were glued together in approximate anatomical position, as was the complete, partially reconstructed pelvis and the partial left tarsus. Before the morphological examination and description was begun, the skeleton was completely disarticulated by gently separating the vertebral elements from their plaster discs and soaking all glued parts in acetone to loosen and remove the polyvinyl-based cement. The reconstructed portions of the individual bones were left intact; these show up in the photographs as pure white areas and in various radiographs as solid radiopaque densities.

MORPHOLOGICAL DESCRIPTION

In the following descriptions the general outline presented by Snow (1943) is followed; this aids the comparative study of the Moundville and Augustine dwarfs. They are, in general, very similar.

Cranium

The cranial vault is a large, rounded structure overshadowing a small face. Snow's (1943: 14) description of "bulging" is an apt designation. There is mild lambdoid flattening, probably postural in origin. The cranial shape in norma verticalis most closely approximates the sphenoid category (Comas 1960, after Martin). Suture patterns vary from simple to complex. All sutures are intact exocranially except for the sagittal, of which only a one centimeter remnant remains anteriorly, and the left occipitomastoid which is obliterated. The frontal is high and broad with a very slight slope above the continuous brow ridges which are joined at a moderately developed glabellar eminence; there is moderate frontal bossing. The parietals are large with medium bossing, weakly developed temporal lines and a very small parietal foramen on the right side. The parieto-occipital articulations bilaterally are low when viewed laterally and give an appearance of a flattened (side to side) occipital.

The occipital has a good curve from lambda to opisthion. The nuchal region is moderately rugged with a broadly-thickened area in the region of the external occipital protuberance. The external occipital crest is well developed anterior to the inferior nuchal lines and is flanked by deep depressions (attachment sites for the rectus capitis posterior minor mm.). The foramen magnum is very small, 3.0 x 1.8 cm (a-p x lat), having an ovoid shape posteriorly and virtually straight borders on either side anteriorly. The cranial base around the foramen magnum is rather thick, especially at basion. The occipital condyles are curved and angled slightly outward posteriorly. There are bilateral, deep oval depressions situated posteriorly and somewhat lateral to the condyles; these form sites of secondary articulation of the atlas with the occipital, there being a bilateral, bulging development of the lateral masses of the atlas, posterolaterally, which fits nicely these post-condylar depressions. (See description of atlas below.) The depression on the left shows a smooth, round articular surface on its anterolateral aspect which corresponds to same on the left lateral mass of the atlas. The basilar portion of the occipital is markedly foreshortened and terminates in a relatively narrow basilar suture which is obliterated. In addition to being foreshortened, the cranial base is also compressed from side to side. Therefore all the normally well-spaced canals and foramina of the cranial base exhibit severe crowding and generally smaller size; there is nothing unusual about their morphological appearance except the crowding and reduced size of the individual structures.

The sphenoid shows a reduced body size, shallow yet broad pterygoid fossae, and broad greater wings; there is a small posterior nasal aperture. The temporals

show small squamae, moderately developed mastoid processes and relatively large, oval, deep mandibular fossae. The moderately thick tympanic plates enclose oval-shaped, straight external auditory meati; the latter are devoid of exostoses. The suprameatal crests are moderately developed and extend to the parietomastoid sutures; zygomatic processes are rather thick. The zygomatic bones are also relatively thick and show moderate anterior and lateral projections.

The suborbital fossae are deep with shallow lateral notches. The intact nasal bones are flat, short and broad with a transverse depression running across their middle, thus giving a concave appearance when viewed laterally. The left nasal sill is fairly sharp, the right dull; there is a small, partially eroded, nasal spine. The nasal aperture is short, broad and roughly oval in outline. Alveolar prognathism is pronounced, while the upper face appears recessed. As Snow (1943: 14) notes, "This, along with the depressed nasal root, gives the general facial profile a concavity, typical of this type of dwarf (Dish-faced)."

The mandible is of medium size with a well-formed mentum and moderate alveolar prognathism. The two genial tubercles are small. There are well-developed mylohyoid ridges and the mylohyoid grooves are bridged bilaterally. The mandibular foramina are large. The gonial regions show rather strong muscle markings inside and outside; there is moderate gonial eversion.

Dentition

The following chart summarizes the maxillary and mandibular dentitions.

Right																	Left
		ad		a ad	ad	ad					ad	a ad	a ad				
8	7	6	5	~~4~~	3	~~2~~	1			1	~~2~~	3	~~4~~	5	6	7	8
8	7	6	5	4	3	2	1			1	2	3	4	5	6	7	8
	ad	ad		ad	ad	ad s	s			s	ad s	ad			ad		

X - tooth lost antemortem
/ - tooth lost postmortem
a - periapical abcess
ad - alveolar dehiscence
s - shovelling

There is good edge-to-edge bite, but it is noted that the maxillary dental arcade has a slightly smaller transverse diameter overall than the mandibular arcade. There is mild-moderate alveolar resorbtion of both arcades. The anterior mandibular teeth show moderate crowding. There are no obvious caries, but slight calculus deposits on most teeth, and moderate-marked occlusal attrition with secondary dentine formation on most teeth.

Cranial pathologies

There is an elevated, blister-like lesion, three centimeters in diameter, in the left posterior aspect of the frontal bone, circular to oval in outline. While the inner table is intact, the elevated outer table has been eroded away in the central portion of the lesion; the edges are irregular and rough and show very fine porosities extending 1-2 mm from the edge. The cavity of the lesion shows fine porosities throughout its surface. The cavity is deepest and undermines the outer table in an anteromedial direction; it is fairly smooth in overall outline except for a small part of its anterior wall which shows a slight ridge. Just medial to the elevated outer table is a slight, round depression, ca. 5-6 mm in diameter, which shows a pitted concavity. The major differential diagnostic possibilities include an epidermoid inclusion cyst or cranial hemangioma.

Fine to relatively large porosities occur over much of the skull, the most prominent being in the nasal bones, the posterior parietals and the interparietal part of the occipital. Those in the latter two areas are generally 1-2 mm in diameter and expose the diploic bone of the vault.

Dental pathologies are summarized above.

Vertebral column

The vertebral column is intact and contains the normal complement of vertebrae per region (7-12-5-5); there are no coccygeal vertebrae present. Generally the thickness of the individual vertebral bodies is normal thus producing a total column length which probably would have been within normal limits for this population were it not for the gross pathologies it manifests. Mild to moderate degenerative disc disease exists throughout, manifested by roughening and erosion of the articular surfaces of the centra with some spicular bone formation.

The cervical vertebrae are generally unremarkable, with the following exceptions. The atlas shows bulging posterolateral extensions of the lateral masses; that on the left shows a round accessory articular surface on its lateral aspect for articulation with the cranium (see description of cranium above). These bulging extensions of the lateral masses form a hood over the sulci for the vertebral arteries as they leave the transverse foramina and course posteromedially to cross over the posterior arch and enter the foramen magnum. The tuberosities for the transverse ligament of the atlas are very prominent, extending well into the vertebral canal and thus possibly restricting the rotary motion between the atlas and axis. The sixth cervical vertebrae has a bifid transverse foramen on the right side. The seventh cervical has a small articular facet on the right superolateral surface of the centrum, probably for an anomalous unilateral cervical rib; correspondingly there is no right transverse foramen, only an unabridged groove. There is no cervical osteophytosis but the articular surfaces of the centra are generally concave and have erosions with bony spicules (indicating mild disc degeneration).

The first through the eighth thoracic vertebrae are generally unremarkable except for the concave articular surfaces of the centra and small spicules indicating some disc degeneration. T9 shows very mild lipping of the antero-inferior border of the centrum. T10 has mild anterior lipping of both the superior and inferior borders of the centrum; there is slight collapse of the centrum anterolaterally on the left which would have contributed to a slight kyphoscoliosis. T11 has a partial wedge-shaped centrum; there is moderate lipping on the superior border and marked on the inferior, the latter forming a broad platform with undulating edges. T12 is apparently hypoplastic (see radiographic interpretation by Dr. Johnston), having a true wedge-shaped centrum; there is marked lipping of both the superior and inferior borders on the right side which fuse together anteriorly.

The first lumbar has a partial wedge-shaped centrum with marked osteophytic growth from the right anterolateral aspect of the superior border; there is mild lipping of the inferior border. L2 is partially wedge-shaped; L2 and L3 show mild anterior lipping. The combination of partial wedge-shaped and hypoplastic bodies of T10 through L2 produces a kyphosis of approximately 90° in the thoracolumbar region. The posterior surfaces of the centra of L4 and L5 are strongly concave. The inferior border of L5 is tilted upward and backward producing a centrum with a reversed wedge-shape, i.e., anterior body thicker than posterior; this, in combination with the angulation of the S1 articular surface (see below) would have produced an extremely exaggerated lumbosacral lordosis. Overall there is a decreasing interpediculate space from L1 through L5, accompanied by some increase in the anteroposterior diameter of the vertebral canal: thus the shape of the canal changes from flat and broad to long and narrow from L1 through L5. See Table 1. The markedly constricted lumbar vertebral canal is further accentuated by the close approximation of the laminae of the posterior arch.

TABLE 1

Lumbar Vertebral Canal Dimensions, in mm

Vertebra	Interpediculate distance	Anteroposterior diameter
L1	20	9
L2	18	9
L3	15	10
L4	15	10
L5	14	11

The 5-segment sacrum is virtually uncurved in profile. A portion of the right auricular surface and adjacent ala are missing (with a partial plaster reconstruction attempted by previous workers). The sacrum is long and narrow overall with a prominent promontory. When held with the anterior surface in a true vertical position the S1 articular surface slopes backward approximately 45° (or with the S1 articular surface in a horizontal plane the sacrum slopes backward 45°); this S1 angulation helps produce

the exaggerated lordosis noted above. The S1 articular surface is also strongly concave and shows evidence of disc degeneration. The posterior sacral surface is deeply pitted at attachment sites of the sacroiliac ligaments. The left auricular surface is concave, especially inferiorly, rather undulating and with irregular borders.

Pelvis

The left innominate is intact; the right is represented only by a portion of the iliac crest. (We should remember that a right innominate had been reconstructed of plaster and the entire pelvic structure, innominates plus sacrum, glued together as a unit by previous workers.) This reconstituted pelvic structure demonstrated a pelvic inlet having a kidney-shape that was flattened anteroposteriorly with the sacral promontory so far advanced into the pelvic canal that vaginal childbirth would have been precluded if this were a female.

That this individual probably was a female is attested to by the following morphologic features of the pelvis: a very wide subpubic angle; a wide and broadly-curved greater sciatic notch; a very long pubis when compared to the ischium; and the presence of the three female criteria established by Phenice (1969): ventral arc, subpubic concavity and medial ridge of the ischiopubic ramus.

There is a very prominent pubic tubercle with a sharp spine directed superiorly. The left ilium is rather upright with little tendency toward lateral flaring. Of the three pelvic elements the ilium appears most greatly reduced in size; this is a general size reduction but appears most marked in the posterior ilium where there is an extremely small auricular surface. The acetabulum is shallow and ovoid in outline with a deep acetabular fossa and a somewhat flattened acetabular roof. Muscle attachments sites are well marked. When the sacrum is articulated with the left innominate, and the latter placed in approximate anatomical position, the sacrum assumes a nearly horizontal position. This again is part of the complex leading to an exaggerated lumbar lordosis.

Sternum

The large manubrium, partially damaged, is broad and unfused to the body (although it is presently glued to the latter). The body is short and broad, especially in the inferior half, and strongly curved when viewed laterally, thus presenting a convex anterior surface. All costal notches are deeply impressed. There is no xiphoid.

Ribs

The ribs are generally short and strongly curved, thus reducing the anteroposterior thoracic diameter. The sternal ends are broad and flaring. There are strong muscle markings.

Clavicles

These are essentially normal in appearance, but rugged and perhaps slightly short. They are well-curved and possess strong muscle and ligament attachment sites.

Scapulae

Both scapulae are intact except for slight, minor damage (the right coracoid process and portion of the glenoid cavity have been previously reconstructed in plaster). Although small they are rugged with strong muscle attachment sites. The left scapula has a deep scapular notch, the right a rather large foramen. The vertebral borders are moderately convex, with axillary borders moderately concave. The glenoid cavities are very shallow and roughly teardrop-shape in outline.

Post-cranium

The long bones show the most dramatic disturbances; they are short but with stout shafts, deformed, and with well-developed muscle markings. The left and right bones are essentially mirror images (reflecting the generalized, symmetrical nature of the dysplasia) so that the specific descriptions can be generalized to both bones.

Humeri

Both humeri are intact and can be characterized as having extremely short, robust shafts and flaring distal ends; their general appearance is similar to those of the Moundville individuals. The inferior borders of the humeral heads extend downward, thus giving a mushroom appearance to the inferior half of the heads where they are attached to the anatomical necks. The greater and lesser tuberosities are prominent, separated by a broad, shallow intertubercular groove. The groove, as it continues down the shaft, is bordered by broad, rugged crests for the attachment of teres major, latissimus dorsi and pectoralis major muscles along the anteromedial and anterolateral borders of the upper shaft. The large deltoid tuberosity on the posterolateral border of the shaft terminates just at midshaft. These large, rugged crests and the deltoid tuberosity give the proximal shaft a greatly expanded diameter compared to the more diminutive distal shaft. Additionally, the shafts are bowed in such a way as to present a concavity (especially in the distal part) when viewed anteriorly which serves to thrust the whole distal articular end forward away from the shaft.

There are no radial fossae and only small coronoid fossae, the latter on the right humerus being more deep impressed than the left. The olecranon fossae are narrow, oval slits, very deep and extending somewhat superiorly. The trochlea are broad and shallow anteriorly and as they continue posteriorly become deep V-shaped grooves. The capitular surfaces become narrowed inferiorly and generally show less articular surface than in normal individuals. The most inferior surface of the capitulum shows a small (10 x 6 mm) shallow oval depression in which fits the medial edge

of the radial head when the radius is in the standard anatomical position, i.e., supinated; apparently the radial head was dislocated normally, a not uncommon clinical finding in achondroplasia. The medial epicondyles are prominent, show a constricted base inferiorly, and greatly add to the flaring of the distal humeral extremities.

Ulnae

Both ulnae are present and intact. The olecranon processes are short and thick with broad superior aspects which taper backward and downward; the anterior spines are sharp but because of the narrow, restricted opening of the deep olecranon fossae they do not project very far into the latter structure. This bony obstruction leads to the inability to fully extend the forearm at the elbow; the carrying angles in the living individual are estimated at 135° on the left, 130° on the right. The trochlear notch is sharply divided by a median ridge into a large medial and smaller lateral aspect. The lateral aspect of the trochlear notch, at a line separating the olecranon and coronoid components of the notch, presents a discontinuity representing a nonarticular surface. This discontinuity is a groove which extends posteriorly, and somewhat laterally, to end in a deep oval pit situated just above the posterior end of the rather flat, poorly defined radial notch.

The supinator crest is moderately developed on the right ulna, mildly on the left. Anterior to each crest is an oval depression, well-marked on the right, less on the left, which Snow (1943: 28) stated was for the origin of the supinator muscle. Normally only the more posterior aspect of this depression is for the origin of the supinator. In this instance when the humerus, ulna and radius are all articulated the depression comes to hold the very prominent radial tuberosity when the radius is brought into pronation.

The upper 1/4 to 1/3 of the shafts posteriorly possesses a sharp, crest-like border most prominent superiorly. Generally the shafts are moderately well developed but with only poorly developed interosseous crests. The medial surface of the distal shaft shows a prominent, posteriorly curving crest for the attachment of the pronator quadratus. The posteriorly positioned styloid processes are nearly as large as the ulnar heads and are separated therefrom by a deep notch.

Radii

The two malformed radii are intact except for the loss of the right radial head and neck. The circumference of the left radial head is roughly circularly in outline. The superior articular surface is very shallowly depressed overall with a deeper central depression which comprises hardly more than a quarter of the diameter of the head. Anterolaterally the articular surface angles downward some 45°. The whole radial head is angled backward 30° and slightly laterally, the angulation reflecting the direction the radial neck takes from the main shaft. The neck itself is very short. The large, prominent radial tuberosity has its greatest diameter in a transverse direction and the

prominence is accentuated by the angulation of the neck on the shaft. In the anatomical position the radial tuberosity projects roughly anteromedially.

The shafts exhibit moderate lateral bowing which again serves to accentuate the prominence of the radial tuberosity and the angulation of the head and neck. Both shafts exhibit an anteroposterior flattening with prominent medial and lateral borders in the second fourth of their length. Distal to this flattening the shafts are prismatic and gradually expand in size as they progress distally.

The distal ends of the radii seem overly large compared to the short relatively modest shafts. There are prominent tubercles for attachment of the brachioradialis and extensor carpi radialis brevis muscles. The ulnar notch is well developed but shallow. The prominent styloid process serves to give a moderate curve to the distal articular surface.

Metacarpals

Three metacarpals are present: left second, and right second and third. All are reduced in length some 15-20% and have thin shafts. The normal longitudinal concavity of the palmar surfaces is rather exaggerated and is especially noticeable in the distal 1/2 to 1/3 where the curvature becomes greatest. Although the metacarpals are more curved than normal, it is much more apparent in the palmar concavity than in the dorsal convexity. This is due in part to the overall shortening of the shaft which accentuates the concavity more because the radius of the concavity is reduced proportionately more than the radius of the convex dorsal surface.

Femora

Both femora are nearly intact except for the following features which have been previously reconstructed in plaster: the tip of the left trochanter, the right femoral head and neck and a small portion of the shaft distal to the lesser trochanter.

The proximal ends are distinguished by the gross development of muscle and tendon attachment sites and short femoral necks. The left neck-shaft angle is 135°. The femoral head does not seem overly large given the reduced size of the shaft. As in the Moundville dwarfs, the femoral heads appear mushroomed along their entire free border except for a small extension of the head anterolaterally onto the femoral neck. As noted the femoral neck is short and of relatively small diameter except where the extension of the head is applied to the neck. The left foveal depression is of normal size and thus appears relatively large due to the small femoral head upon which it is impressed.

The greater trochanters are markedly developed with very deep trochanteric fossae. Anteriorly the greater trochanter ends in a well developed tubercle where the lateral band of the iliofemoral ligament attaches. There is hardly a suggested presence of an intertorchanteric line which consists of a small inferomedial roughness coming off

the tubercle mentioned above. Directly inferior to this tubercle is a shallow, circular depression about one centimeter in diameter. Posterior to the greater trochanter is a mildly developed quadrate tubercle which is connected to a greatly overdeveloped lesser trochanter via the elevated intertrochanteric crest. As Snow (1943: 41) notes, "the lesser trochanters extend medially as sharply defined finger-like processes."

Both femoral shafts are mildly bowed posteriorly and roughly quadrilateral in cross-section with the larger side anterior. Posteriorly the gluteal tuberosities are moderately developed and extend along the posterolateral border of the shaft rather than swinging medially to join the spiral (pectineal) line at the apex of the linea aspera. The spiral line itself is mildly developed and extends to where the linea aspera would normally begin. There is no true linea aspera, only the posterior surface of the quadrilateral shaft. This posterior surface is bounded medially and laterally by the inferior extensions of the spiral line and gluteal tuberosity respectively. Inferiorly this pseudo-linea aspera broadens into the large, concave, distally-flaring popliteal surface.

The distal femoral extremities are large, flaring, malformed structures. Most notable is the gross over development of the medial condyle (nearly twice the size of the lateral) which is separated from the lateral by a deep, narrow intercondylar fossa (slightly wider in its posterior than anterior aspect) which is discernible as much in an anterior view as a posterior one. The superior aspect of the patellar articular surface is greatly lengthened and there appears a depression in its uppermost part which is bordered superiorly by an overhanging lip of bone from the adjacent nonarticular metaphysis. The normal depression which separates the patellar articular surface into medial and lateral parts and which continues onto the inferior surface of the condyles is wholly confined to the superior half of the anterior condylar surfaces. The whole appearance of the distal extremity one receives is that of the entire condylar end being rotated 90° antero-inferiorly, thus bringing the intercondylar fossa forward and extending the patellar surface superiorly. The medial epicondyle is broad and extensive while the lateral is relatively diminished in size (although fairly prominent in its lateral projection) with a prominent popliteal sulcus inferiorly.

Tibiae

Both tibiae are wholly intact and are distinguished by very prominent, flaring extremities and pronounced attachment areas for muscles, tendons and ligaments. As with the Moundville material the proximal ends of both tibiae show pronounced posterior retroversion or backward overhang. The condylar surfaces are intact with the medial being larger than the lateral. The medial condyle presents a fairly normal shape (very slightly concave) but the lateral is strongly convex in an anteroposterior direction such that the most anterior portion of the lateral condyle faces directly forward instead of upward. In both tibiae the superior surface of the lateral condyle is some 2-3 mm above the superior surface of the medial condyle.

The tibial tuberosities are very prominent with the medial end of the left tuberosity ending in a small dimpled depression. There are well developed oval articular facets (1 x 1.5 cm) on the posterolateral aspect of the inferior surface of the backward overhanging lateral condyle; these are for the fibular heads which fit very nicely.

The shafts show slight bowing anteriorly, are of normal shape and just slightly smaller in diameter than normal. The soleal (popliteal) lines on the posterior surface of the upper shaft are moderately developed. The distal 1/3 of each shaft is curved very slightly medialward, possibly resulting in a slight varus deformity at the ankle.

The distal extremities are relatively large with well developed, broad medial malleoli which appear to extend further medially than normal. The inferior articular surfaces are smooth with somewhat exaggerated normal undulations; the left has a deep, conical pit in the middle. The fibular notches bilaterally are well-formed, deep impressions with prominent anterior and posterior boundaries that form tubercles.

Fibulae

Both fibulae are intact and longer than their respective tibiae. They have well developed heads which are rather normal in appearance. They possess strongly ridged shafts with very prominent interosseous borders. The well developed distal extremities have deep malleolar fossae but no obvious lateral malleolar sulci for peroneal tendons except for very slight impressions on the most inferior part of the malleoli.

Talus

Only the left talus is present. It is generally unremarkable other than its slightly reduced size from normal (it would probably fall within the lower range of normal size for females). The neck appears to be slightly shortened in its anteroposterior length. The articular surfaces are of normal arrangement and configuration. There is a slight porosity and roughening in the central region of the navicular articular surface which probably represents beginning degenerative joint disease at the talonavicular joint.

Calcaneus

Only the left calcaneus is present and like the talus, is rather unremarkable except for a slightly reduced size. Comparison with other calcanei indicate that the reduced length is accounted for primarily by reduction of the body, the posterior element of the calcaneus. The peroneal trochlea is very prominent in its lateral projection. The configuration of the articular surfaces is within the normal range of variation.

Cuboid

The slightly reduced in size left cuboid is of normal configuration. There is an articular facet on the tubercle for the sesamoid bone sometimes found in the peroneus longus tendon.

Metatarsals

Only the left fifth metatarsal remains; it is moderately shortened but of normal configuration and is not bowed like the metacarpals.

RADIOGRAPHIC INTERPRETATION

The following radiographic description, interpretation and differential diagnosis is by Dr. James O. Johnston, Chief, Department of Orthopedics, The Permanente Medical Group, Oakland, California. Dr. Johnston's time and interest in this case are gratefully acknowledged and appreciated.

On a lateral projection of the skull, not seen is the typical appearance of hydrocephaly and frontal bossing that one would like to see for a classical achondroplastic diagnosis. However, there is a fair amount of hypoplasia of the basilar portion of the skull, especially through the maxillary area and basis sphenoid area, suggesting achondroplastic diagnosis. An A/P projection provides a better case for achondroplasia, with bitemporal bossing and a small hypoplastic alveolar ridge with a narrow transverse dimension which frequently results in malocclusion problems when it attempts to articulate against the normal mandible, which is relatively larger than the opposing upper maxillary area.

On the film of the mandible, it is indeed larger in its transverse dimension and shows that this individual did have a malocclusion problem, which is typical of achondroplasia. The clavicles on the same film are small and quite compatible with achondroplasia. I cannot really comment on the sternum. A lateral view of the mandible shows a condylar area which is unusually short for articulation with the temporal bone. On this same film the ribs are short and certainly compatible with achondroplasia. Another bone on this film looks like os calcis and has a short tuberosity compatible with achondroplasia.

On a lateral view of the cervical and lumbar spine, these appear reasonably healthy. Of note is the odontoid process which is of good length and is well articulated with the ring of C-1. This tends to go against a diagnosis of Morquio's and the severe spondyloepiphyseal dysplastic dwarfs that might be considered. The lateral view of the lumbar spine reveals characteristic posterior concave deformity of the vertebral bodies, producing a "dumb bell"

myelogram (if such a study could have been done on this individual). The disc heights are reasonably well preserved and there is minimal deformity in most of the vertebrae except for the upper one, which is probably the portion that articulates with the kyphotic area seen on another film. This upper lumbar vertebra (probably L-2) has a definite wedge configuration and evidence of degenerative spurring because of its closeness to the severe kyphotic deformity.

...a lateral x-ray at the lumbodorsal junction shows a rather severe gibbus deformity of nearly 90° angulation with a considerable amount of secondary degenerative spurring in front, as the result of advanced degenerative disc disease resulting from this kyphotic deformity. This unusual manifestation of adult achondroplasia has been recorded in the literature, especially in the type of achondroplastic dwarf having a fair amount of ligamentous laxity and joint dislocation tendency. This type of gibbus deformity is more typically seen in the severe epiphyseal dysplastic group such as Morquio's and Hurler's or in other forms of dwarfism associated with collagen deficiency and resultant ligamentous laxity and scoliosis. This atypical vertebra is sometimes referred to as a hypoplastic vertebra but if one follows the child from infancy to adulthood it becomes apparent that the kyphosis is progressively developmental, secondary to laxity of the ligaments at the lumbodorsal junction and not truly a hypoplastic condition of the vertebra; more immediately evident at birth or shortly thereafter. Also seen on this lateral projection is the classical concave configuration of the posterior surface of the vertebral body, also typical of achondroplasia and not seen in pseudoachondroplastic conditions of the epiphyseal variety.

On a lateral view, the thoracic spine appears quite normal except for some hypoplasia of the posterior elements, including the facets and pedicles which seem short and certainly compatible with achondroplasia. The spinous processes appear unusually long, which I do not fully understand.

An A/P x-ray of the sacrum shows the classical findings of an achondroplastic type of dwarf, with the obvious restricted distance between the pedicles at the S-1 level and progressive stenosis (viewed in a caudal direction). This evidence of spinal stenosis is probably the most diagnostic feature of the achondroplastic dwarf and tends to rule out all other forms of short-limbed dwarfism, including all epiphyseal dyplasias such as Hurler's, Morquio's and severe forms of pseudoachondroplastic spondyloepiphyseal dysplasia.

Unfortunately, the lateral projection of the pelvis is difficult to interpret because good acetabulum detail cannot be seen. However, I can say that the sciatic notch is fairly sharp due to the inadequacy of the triradiate cartilage during the developmental years of the individual, typical of achondroplasia. On this film the fairly hypoplastic appearing scapula has no really specific

features on which to comment.

X-ray of the humerus, radius and ulna shows considerable dwarfism, especially of the humerus. This typical form of achondroplasia, more amplified in the proximal long bones than in those of the distal bones, is referred to as the rhizomelic form of dwarfism as compared to the acromelic form seen in the Ellis-van Creveld syndrome. Also seen is an excellent example of muscle effect on the humerus, with a dilated diaphyseal area at the mid-shaft of the humerus where the deltoid muscle tendon inserts, producing a rather rectangular shape to the upper metaphysis, typical of achondroplasia. The epiphyses appear well structured and strong, ruling out the severe epiphyseal pseudoachondroplastic forms of dwarfism. The ulna is short with a slight degree of bowing. The adjacent radius is more severly deformed, with considerable distortion of the proximal half due to the abnormal insertion of the biceps tendon, with a prominent bicipital tuberosity similar to the prominence of the lesser trochanter on the upper end of the femur. The radial head itself is deformed and strongly suggests that this was partially dislocated from the capitulum of the humerus, which is not unusual in this condition. The distal end of the radius and the ulna are transversely oriented, typical of achondroplasia and tending against the mucopolysaccharide group and the severe epiphyseal dysplastic dwarfs.

On x-ray, the femur is quite short with a narrow diaphysis of excellent cortical structure and a flared metaphyseal area on both ends, which is typical of achondroplasia. The epiphyses of this bone appear quite normal and well structured with good strength, which goes against a diagnosis of a pseudoachondroplastic form of dwarfism. There is a normal angle of the femoral neck to the shaft, which is typical of achondroplasia and tends to go against the diagnosis of epiphyseal dysplasia such as Morquio's. Prominence of the lesser trochanter is not atypical for achondroplasia. In fact, all the areas of tendinous insertion tend to be prominent and more elevated than in normal bones. The other bone seen on this x-ray is probably the fibula. Had it been x-rayed with the tibia one could see the excessive overgrowth of the fibula as compared to the tibia, which is typical of the achondroplastic dwarf. However, holding the x-ray of the fibula next to that of the tibia, one can see that the fibula is longer than it should be (assuming the tube length from the subject is the same for both of these x-rays and assuming these are bones from the same specimen); strongly compatible with a diagnosis of achondroplasia.

X-ray of the tibia also shows the characteristic narrow diaphysis with a flared metaphyseal area. There is no unusual sloping of the tibial plateau of valgus deformity of the ankle mortise as seen in epiphyseal dysplasias, again pointing strongly toward achondroplastic diagnosis. The smaller bones in this x-ray are undoubtedly metatarsal bones, as can been seen by the styloid process which represents the fifth metatarsal. Again, the pattern is

typical of achondroplasia, with shortening and a narrow diaphysis and flared metaphyseal area with no deformity of the distal epiphyses, suggesting a strong, normal joint articulation with the proximal phalanx, typical of achondroplasia. There is no proximal tapering of the metatarsals, which goes against a diagnosis of the epiphyseal dysplastic group, including Hurler's and Morquio's.

It is obvious this particular individual was of good, solid structure as far as functional capability. The individual had good joints, with no evidence of arthritis, and was obviously able to get around quite well. However, one thing that may have "done this dwarf in" is the rather severe lumbodorsal kyphosis, known to cause serious problems of cauda equina compression, with resultant weakness of the lower extremities and very difficult to treat surgically by posterior decompression. This individual may have become very weak in the lower extremities and died as the result of paraplegia. However, the structure of the bone in the lower extremities is quite good and does not show any significant degree of disuse osteoporosis that would suggest paraplegia of any duration. It is possible the individual developed an acute paraplegia following some relatively minor injury that might well have caused a neurogenic bladder syndrome, resulting in death from urological complications.

All in all, you have a good case for a true achondroplastic dwarf. I think we can safely rule out other forms of dwarfism because of the adequate x-ray evaluation. I have mentioned the differential diagnostic possibilities and need go no further. It is most fascinating to go over a case such as this. As you know, achondroplastic dwarfism is ancient, dating back 5000 years when dwarfs were known to be part of our society, as described by inscriptions in Egypt.

DISCUSSION

General characteristics of achondroplasia

Parrot (1878) first coined the term 'achondroplasia' (literally meaning without cartilage formation) to distinguish disproportionate dwarfism, i.e., dwarfism of the short-limbed type, from the proportionate type due to rickets. In 1892 Kaufmann substituted the term 'chondrodystrophia foetalis' to imply a deficient growth of the cartilaginous epiphyseal growth plate. These were broadly inclusive terms which, as the understanding of the specific deficit became clearer and other similar entities became differentiated, gradually took on a very specific meaning. Achondroplasia is the term in near-universal use today; synonyms include: chondrodystrophia, chondrodystrophia fetalis, chondrodystrophic dwarfism, chondrodysplasia fetalis, micromelia, and achondroplastic dwarfism.

Achondroplasia is the most common type of dwarfism and has been characterized as an "hereditary, congenital, familial disturbance in epiphyseal chondroblastic growth and maturation" (Aegerter and Kirkpatrick 1975: 101). It is inherited as an autosomal dominant characteristic whose incidence is variable and ranges from 1 in every 3000 to 9500 births, with approximately 80% of all live births dying in the first year (Warkany 1971: 768). If, however, the achondroplastic survives the first year or two of life he has a relatively good chance of reaching and surviving into adulthood. During later middle age, though, adult achondroplastics are apt to suffer from the symptoms caused by pressure upon the spinal cord and nerves (produced by the skeletal deformities of the vertebral column) with resultant backaches, sciatica, paresthesia and even paraplegia (Aegerter and Kirkpatrick 1975: 109; Greenfield 1975: 197) with all the attendant complications of the latter. The mental and sexual development of achondroplastics is usually normal.

Achondroplasia is characterized as a rhizomelic, micromelic type of dwarfism. This means the dwarfism displays overall short limbs (micromelia) which show a greater reduction in the proximal segments of the limb (rhizomelia) than in the distal segments, i.e., in the upper arms and thighs.

As Aegerter and Kirkpatrick (1975: 102) note, the relative frequency of achondroplasia is kept rather low because of the high rate of intrauterine deaths of the malformed fetus and to the difficult parturition in affected mothers because of the distorted pelvic canal. With an autosomal dominant mode of inheritance one would expect a much higher incidence of this type of dwarfism in the general population. Obviously, in countries with modern medical facilities this feto-pelvic disproportion can be obviated through caesarean section delivery of the fetus. In fact, the relative frequency of achondroplasia is probably higher than expected because of the ability of achondroplastic mothers to successfully deliver nonvaginally. In effect, then, the contemporarily reported frequencies of achondroplasia probably reflect a balance between high frequencies based on an autosomal dominant mode of inheritance and adequate medical care and the tendency to lowered frequencies based on fetopelvic disproportions, stillbirths and newborn inviability. The frequency of living achondroplastics in prehistoric times would obviously be much lower.

Achondroplasia has been classified as one of numerous skeletal dysplasias characterized by a disturbance in chondroid production related to an abnormal maturation of growth plate chondroblasts of unknown etiology, i.e., "an idiopathic disturbance of growth plate chondroblast maturation" (Aegerter and Kirkpatrick 1975: 101). The defective division and maturation of these growth plate chondroblasts results in a deficient chondroid lattice and subsequent zone of provisional calcification. Without an adequate calcified chondroid latticework, there is little opportunity for normal osteoid to be laid down (Aegerter and Kirkpatrick 1975: 101-109). The result is a marked decrease in the linear growth of endochondral bones. Since the defect is localized in bones of endochondral origin, actually in the chondroblasts themselves, intramembral and periosteal (appositional) bone formation are normal. The <u>apparent</u> abnormalities in the

latter osteogenic modes of development are probably the result of their accomodation to the malformations of adjacent endochondral bone. As Greenfield (1975: 197) and others have noted there may be periosteal strips of fibrous tissue which seal the epiphyseal line and thus negate further growth in a length of the bone. With normal periosteal ossification, appositional growth at the ends of long bones proceeds faster than epiphyseal growth and this, according to Edeiken and Hodes (1973: 65), is what gives these bones flared extremities. Aegerter and Kirkpatrick (1975: 109), however, imply that the stress on the epiphysis, in the face of a strong cortex with a deficient underlying spongiosa, may be the cause of the flaring.

The following account of the histological changes in achondroplastic growth plates summarizes very well how the disturbed epiphyseal chondroblastic maturation accounts for the major characteristics seen in this dysplasia.

> In the achondroplastic child the iliac-crest growth plate is histologically nearly normal whereas the growth plate of the fibula, and presumably of all the long bones, is very deranged. Similarly, bone growth is normal in the iliac crest and is very stunted in the fibula. Recent work in our laboratory indicates that the iliac-crest cartilage of achondroplastic patients contains normal amounts of hydroxyproline and some increase in amounts of galactosamine and glucosamine. The proteinpolysaccharides, however, which can easily be extracted from the iliac-crest cartilage of normal children, are difficult to extract from the cartilage of many of our achondroplastic patients. Perhaps the proteinpolysaccharides form large aggregates in the cateilage of the achondroplastic patients which could interfere with the formation and resorption of the growth plates more in the long bones than in the iliac-crest, possibly owing to the differences in cartilage matrix, collagen organization, and manner of ossification of these two structures.
>
> The cartilage-cell columns in the fibular epiphyseal plates of achondroplastic children are disarranged and are separated by wide cartilaginous septa rich in fibers. Visualized with polarized light, these seem to be collagen fibers, and with the electron microscope many wide, well banded fibrils are seen in these septa. This fibrotic cartilage appears to resist erosion by the invading vascular processes. Presumably, the splitting of the abnormal proteinpolysaccharide molecules, necessary for calcification and ossification, proceeds very slowly or is even blocked at some sites. Thus, vascular penetration of the plate and bone formation are very stunted and irregular. On the other hand, the matrix abnormality in the child with achondroplasia does not interfere with the type of calcification and ossification found in the iliac-crest at the termination of the large septa rich in collagen fibers. Here the process resembles intratendinous ossification, which is normal in children with achondroplasia as seen by their well developed trochanters, tuberosities, and epcondyles. Periosteal and intermembranous ossifications are also normal. Bone forms in all these sites without breakdown of collagen fibers or matrix.

> Assuming that the two growth plates of the vertebral bodies resemble the growth plate of the iliac crest in children with achondroplasia as they do in normal children, the discrepancy between the nearly normal growth in height of the vertebrae and iliac wings of these patients and the very short bones of their extremities can be attributed to the different structure of the respective growth plates.
>
> Several authors have observed that, in children with achondroplasia, fibrous connective tissue extends from the perichondrium into the epiphyseal plate. The hyaline cartilage at the periphery of the fibular plates of some of our patients contained many collagen fibers which often seemed to extend through the septa to the metaphysis. Abundant normal periosteal bone spread out in a funnel-shaped fashion underneath the peripheral margin of the plate and accounted for the flaring of the metaphysis (Ponseti 1970: 710-713).

Stature increase in achondroplastics is slow after birth and generally terminates prematurely; overall height rarely exceeds 140 cm (55 in), with an average in the neighborhood of 48-50 in (Warkany 1971: 774). The normal dentitional and other physical developmental milestones tend to be retarded to some degree. The onset of walking (at about 20 months) is accompanied by a rapidly developing lumbar lordosis, protuberant abdomen and prominent buttocks (Bailey 1973: 62-64) characteristic of this type of dwarfism. Good discussions of the developmental growth stages found in achondroplasia are presented in Bailey (1970, 1973), Langer et al. (1967), and Ponseti (1970), and need not be recounted here.

Interpretation of bony abnormalities

If we remember that the defect in this skeletal dysplasia directly affects only endochondral bone, many of the bony abnormalities seen in this individual become readily understandable. The basic problem in the cranium results from the fact that most bones of the cranial base (occipital, sphenoid, petromastoid portion of the temporals) are developed exclusively or primarily from cartilage while the vault and facial structure (parietals, frontal, temporal squama, nasals, maxillae, and mandible) are preformed in membrane bone. The result is a markedly foreshortened cranial base and reduction in its overall size accompanied by a recessed upper face and a relatively large vault which appears to bulge out in all directions over the diminutive base upon which it rests. There is a general lack of growth along the inter-sphenoid and spheno-occipital synchondroses. Whereas in the normal individual the four principle epiphyseal ossification centers of the cranial base normally close in early adulthood, they may ossify in utero or in infancy in achondroplasia. This accounts for the small cranial base, the decreased diameter of the foramen magnum, the prominent brachycephaly, and the depressed nasal bridge (Aegerter and Kirkpatrick 1975: 102-103). The brain is thus obliged to grow upward, forward and outward resulting in the characteristic high, bulging forehead, and frontal and parietal bossing. The bulging forehead also helps accentuate the saddle nose (Warkany 1971: 774).

Although most authors attribute the presence of the depressed nasal region to the generally foreshortened cranial base in concert with the bulging forehead, this is not a wholly satisfactory explanation. The nasal recession actually involves more than just the flattened nasal bones; it also involves the frontal processes of the maxillae such that the whole upper face, i.e., the nasomaxillary region, is actually recessed and flattened. Since the cranial base is not in direct contact with this nasomaxillary complex, its foreshortening probably only contributes indirectly to the problem. A more specific explanation probably lies in the fact that the ethmoid, upon which the nasomaxillary region is buttressed (directly and indirectly via the lacrimals) is of endochondral origin, being derived from the cartilaginous embryonic nasal capsule. The lacrimals themselves ossify from the membrane overlying the nasal capsule and thus might be expected to be generally reduced also. The probably diminished development of the cartilage-derived ethmoid, then, appears to be a more direct explanation for the depressed nasal bridge, albeit aided and accentuated by the bulging frontal bone and a generally shortened cranial base.

Since the mandible enlarges by both endochondral and intramembranous ossification (primarily the latter), it shows a relatively normal (although still somewhat small) development which makes it appear relatively large compared to the diminished facial structure; this also contributes greatly to the prominent prognathism of achondroplastics. These craniofacial features are generally so constant that most achondroplastics look like members of the same family (Aegerter and Kirkpatrick 1975: 102-103; Warkany 1971: 774).

Although the vertebral column is of cartilaginous origin, there is generally less inhibition of trunk growth than of the limbs (Aegerter and Kirkpatrick 1975: 103). In fact, the trunk may approach or even reach the limits of normal length. This may be due, in part, to the complex, intersegmental origin of the individual vertebrae and/or the overall segmented nature of the vertebral column, resulting in less general depression of vertebral body growth than if the trunk were composed of a single, longitudinal element (cf. Ponseti 1970: 712). Generally, though, there is some reduction in vertebral height, and overall development is usually abnormal to some degree. (Given the fact that vertebrae do arise from a cartilage model, it is surprising the trunks are not more malformed.)

In addition to a general reduction in size the vertebrae may be wedge-shaped, with the development of thoracolumbar kyphosis as we have seen in this individual. The posterior vertebral elements are usually more affected, producing a restricted neural canal which may compress the cord and/or spinal nerves. This is especially likely in the thoracolumbar region where a gibbus deformity may develop or in the lumbar region where the interpediculate spaces become progressively narrow. See Caffey (1958). Although this particular prehistoric Californian manifests this progressive diminution of the interpediculate distance, there may be some compensation here because the anteroposterior diameters of the vertebral canal increase slightly in the more inferior lumbar vertebrae (see Table 1). However, we should note that the pedicles are much shorter

than usual so that the overall vertebral canal is greatly reduced when compared to normal. In addition, the compression of the spinal cord and/or spinal nerves may not be due just to reduced interpediculate distance, short pedicles, or kyphotic deformity, but may also be contributed to by the close apposition of the laminar elements of the vertebral arch.

The pelvis of achondroplastics is generally reduced with a kidney-shaped inlet greatly reduced in its anteroposterior diameter, a result of the very prominent sacral promontory and the short caudal segment of the ilium. The pubis is nearly normal in size and configuration but may appear abnormal as it adapts to the more greatly reduced ischium and especially the ilium.

It is the long, cylindrical bones of the limbs which are most dramatically affected in achondroplasia, a direct result of their being entirely dependent upon endochondral growth for increase in length. The exaggerated bony prominences are easily understood as the result of a near-normal muscle mass being applied to a reduced, malformed skeletal framework. Possible explanations for the flaring bone ends were presented above and need not be repeated here. Since periosteal ossification is not affected in achondroplasia, the diaphyses generally show a near-normal cortical thickness associated with greatly reduced shaft lengths.

The inability to fully extend the elbow was noted above in the morphological description. Bailey (1971, 1973) has speculated on the causes of this sudden block to full extension and, on the basis of clinical and radiographic examinations, lists the following possible causes:

1) deformities of the radial head,
2) subluxation or dislocation of the radial head,
3) humeral impingement of the tip of the olecranon,
4) incongruous fit of the bones of the olecranon fossa,
5) abnormal bowing of the distal end of the humerus, and
6) tight soft tissue structures about the elbow (Bailey 1971: 77, 1973: 64).

Although Bailey has the advantage of numerous clinical experiences in trying to explain this phenomenon, we have an advantage here in being able to directly examine the bony relations at the elbow. It is easily seen that the major contributor to the full extension block is the extremely constricted opening of the olecranon fossa which allows no more than the extreme tip of the olecranon process to intrude, even though the fossa itself is quite deep. In effect, the lateral borders of the fossa so constrict the opening that the lateral aspects of the anterior tip of the olecranon process are blocked from further extension.

In addition, the small depression noted on the inferior surface of the capitulum (which accepts the edge of the radial head) may indicate that the dislocated radial head contributes to this extension block, i.e., the radial head only fits this depression when the elbow is in its fullest possible extension. Even if the above bony malformations were

normal, the anteriorly displaced distal articular end of the humerus may contribute to the apparent lack of full extension, i.e., the humero-ulnar articulation may actually be in full extension but, because of the anterior displacement of the distal articular end of the humerus, may appear to enclose a less obtuse angle. Obviously we cannot evaluate the contributions of tight soft tissue structures.

A tabulation of the osteometric data for this individual appears in Appendix A. Measurements follow those presented in Snow (1943) so they may be directly compared to the female and male achondroplastic skeletons from Moundville. In general, the measurements are quite comparable to those of the Moundville dwarfs, especially the craniometric data. The Augustine Site female, however, has shorter long bones than even the Moundville female (which are shorter than the Moundville male) and this observation helps support the probable diagnosis of female.

An accurate age estimation is difficult to make, given the abnormal bony development which probably affects the expression of those criteria normally used in skeletal aging. We can say the individual is an adult (all permanent dentition erupted, all epiphyses fused, spheno-occipital synchondrosis fused) and, given the amount of dental attrition, was probably in the third or fourth decade of life. Although not without its problems, the degree of exocranial suture closure generally confirms this. Pubic symphyseal aging was not done because the pelvic distortion (and muscular stresses placed upon it) and slight damage to the symphyseal face would have precluded meaningful results.

Differential diagnosis

In his radiographic analysis and interpretation, Dr. Johnston mentions several of the more prominent differential diagnostic possibilities to rule out a skeletal dysplasia of this kind. In general, the problem is one of distinguishing between the many forms of dwarfism; specifically, we are concerned with the short-limbed dwarf types, or those processes resulting in disproportionate short stature. To fully discuss the total array of possibilities would severely overburden the general anthropological audience to which this paper is directed. For those interested in this aspect of the problem, excellent reviews of the differential diagnosis of achondroplasia can be found in Aegerter and Kirkpatrick (1975), Bailey (1973), Caffey (1958), Edeiken and Hodes (1973) -- an especially good discussion, Greenfield (1975), and Jaffe (1972) among others.

Anthropological significance

In summarizing the importance of finding a dwarf (? chondrodistrophia hyperplastica) from medieval Yugoslavia, Farkas and Lengyel (1971/72: 207) note the following:

> The point of interest of the paleopathological diagnosis that can be regarded probable on the basis of the deformations described lies, on the one hand, in

> the rarity of pathological deformation (Nemeskeri-Harsanyi, 1959), and on the other hand, in the fact, interesting in itself, that the individual examined, in spite of the anomalies of osteogenesis, had lived up to a senile age.

The rarity of the phenomenon described and the attainment of adulthood are also points of interest in the present case of prehistoric achondroplasia.

Although contemporary frequencies would indicate that the birth of an achondroplastic individual is not so rare an event today, we briefly discussed above the possibility that the frequency would be much lower in prehistoric times, mainly on the basis of lack of access to modern medical care. An additional component of this probably lower frequency in prehistoric times relates to the possibility of infanticide, at least among those groups that practiced it on the basis of a newborn "appearing different" at birth. However, unless we have some sort of documentation (artistic, artefactual, etc.) to support this, it can only be conjectured and suggested as one of the many possibilities for the very infrequent recovery of this kind of prehistoric skeletal material. Indeed, we should probably feel very lucky that such a complete individual has been able to be recovered and studied. (Compared to the Moundville and other Old World specimens this may be the most completely preserved extant prehistoric achondroplastic individual.)

Given the health problems to which achondroplastics are prone during their lifetime, the attainment of at least the third or fourth decade of life in the individual under discussion is remarkable. It was noted above that 80% of liveborn achondroplastics die within the first year of life, but if they can survive the infant-childhood years they have a good chance of reaching adult status. Today, with adequate medical attention they can expect to achieve normal life spans, or at least a close approximation. Dr. Johnston has so well summarized the major possibilities that led to the death of this Augustine site individual that we can say little else that would add to his discussion, except to recommend that the reader go back to the final part of Dr. Johnston's report.

Since dwarfs and hunchbacks have apparently played important roles in the New World (at least Mesoamerica), as evidenced by their frequent portrayal in artefactual remains (see discussion above), we might wonder whether this hunchbacked dwarf from prehistoric California was also accorded special status among the Augustine Site inhabitants. Although we could plausibly argue for such, on the basis of the Mesoamerican archaeological and ethnographic record (Corson 1972: 318-325), to do so would be an exercise <u>in vacuo</u> since we have no associated artefactual remains in this instance. It would be interesting in this regard to learn of the existence of ethnographic reports that mention dwarfs in California, either factual accounts or in the folklore or mythology of California groups.

We would also like to know what general role this individual may have played in the economic support of the group, if any. If no special status was accorded this 'different' member of the group, was she able to carry out the normal daily activities

appropriate to her sex? Even if she were not paralyzed for any length of time her spinal deformity (of many years' duration) would have precluded certain physical tasks. Perhaps there were very specific tasks that were accorded to her and not others. But, again, this is only speculation. In any event, we can probably say that she did suffer some physical handicap, but the fact that she was able to live to adulthood would argue for the social group at the Augustine Site to have made various adjustments and accomodations to her disability. What these were we cannot specify.

The widespread depiction of dwarfs and/or hunchbacks in the literature of Mesoamerican archaeology brings up another point of anthropological interest that supports the presentation of such detailed osteological evidence as we have done in this report. And that concerns the actual medical diagnosis of the abnormalities depicted. That a full understanding of the biological base of achondroplasia (and other skeletal disorders for that matter), and the resultant, specific abnormalities manifested, is necessary before attempting to diagnose artistic representations can be illustrated with the following example. In his excellent book, The Shaft Tomb Figures of West Mexico, von Winning (1974) portrays a figurine (Figure 14, p. 98) diagnosed as "Syphilitic dwarf," the syphilis diagnosed primarily on the presence of a sunken nose. The figurine has other elements, in addition to the depressed nose, that strongly favor achondroplasia as the correct diagnosis (without having to allude to the enigmatic problem of pre-Columbian New World syphilis): bulging cranial vault, with a protruding forehead, and micromelia of the rhizomelic variety. Von Winning (personal communication) did not make the diagnosis of syphilis and has communicated that "this is questionable because it [the sunken nose] is also a symptom of achondroplasia." The point to be made here is that diagnoses so often made in the past have not entertained differential diagnostic possibilities that may be more reasonable, if not more exciting. (See Stewart [1975] for another example of this general problem.) Without actual skeletal and/or mummified remains that are much less equivocal, we should always be very careful in our pronouncements of the presence of specific disease entities.

A final point of anthropological interest, that also bears upon the detailed presentation of such rare skeletal abnormalities, concerns the identification and interpretation of faunal remains from archaeological or other contexts. By presenting detailed descriptions and photographs of such material, the faunal analyst should be able to specifically identify this process if the occasion ever arises. With the uncovering of a nearly complete skeleton, with cranium, this shouldn't present any problem as to its identification. But suppose only a few fragments of limb bones were available -- would the identification be so easy? Probably not! (In fact, several individuals have remarked on the very general similarity of the limb bones to various sea mammals. But when the skull and pelvis were introduced, these general appearances quickly dissipated.) In a sense, then, this is just one more item in the range of human (and vertebrate) skeletal variability that should always be kept in mind.

Medical significance

We have been primarily concerned in this paper with the anthropological aspects of a very rare paleopathological phenomenon. Can such a study contribute to the health sciences as well? Yes, in several different ways. First, we have an additional documentation from prehistory in a previously unreported region (the western United States) of a very rare genetically-based abnormality of skeletal growth. This geographic extension helps support the notion that geographic (hence, environmental) variability does not affect the manifestations of this growth abnormality. This is perhaps a minor point, but one which has important implications if the environment were seen to affect the expression of this genetic trait. Additionally, we have further evidence that this hereditary trait has remained stable in its expression over time; the implications of this fact parallel that mentioned above.

As should be apparent from the numerous citations from the medical literature, achondroplasia has elicited a great deal of interest among health professionals, especially the orthopedists who must deal directly with the problems arising from the bony abnormalities. In trying to interpret and understand these abnormalities the osteological paleopathologist has a distinct advantage over the clinician in that the former can directly examine the bony material itself, whereas the latter must rely on clinical information alone (unless he happens to be fortunate enough to acquire autopsy material for dissection). For the most part, this may not make any difference in the management of the patient but it can help in the overall understanding of why the problem exists. For example, Bailey (1971: 75) notes, "The surgical implications of deformities of the upper limbs in achondroplasia are minimal but the diagnostic significance, particularly of their elbow deformities, is great." It is hoped the present paper has contributed to that understanding.

SUMMARY

We have presented in this paper a full report on the third extant prehistoric achondroplastic dwarf skeleton (adult, female) from the New World, previously reported in a brief note (Hoffman 1975: 3). The nearly complete individual comes from the Augustine Site (CA-Sac-127), Sacramento County, California, and more likely dates from the Late Horizon, Phase II (AD 1500-1800), not the Middle Horizon as originally reported. No specific archaeological context could be determined. A detailed morphological description was presented and accompanied by a radiographic analysis and interpretation by Dr. James O. Johnston, Oakland, California.

The general biological characteristics of achondroplasia were presented as background for an interpretation of the bony abnormalities seen in this individual. Among the specific features noted were:

1) a more specific explanation for the depressed nasomaxillary region than had previously been reported,
2) a specific explanation for the lack of full elbow extension,

3) the observation that the interlaminar distance of the lumbar vertebrae is reduced which further contributes to the spinal stenosis in achondroplasia, and
4) the first reporting of an accessory atlanto-occipital articular facet in achondroplasia.

The anthropological significance of this individual was discussed and the following points noted:

1) the rarity of finding achondroplastic skeletal material,
2) the unusual attainment of adult age for a prehistoric achondroplastic,
3) the possible social position of the individual at the Augustine Site,
4) the problems of diagnosing diseases from artistic representation, and
5) its possible confusion with other faunal remains.

The paper concluded with some general comments on the importance of such paleopathological remains to the health professions, specifically:

1) a further demonstration of the temporospatial constancy of a known genetic trait, and
2) the unique contributions that osteological paleopathologists can made to our understanding of health-related problems through their direct examination of bony abnormalities.

Literature Cited

Aegerter, Ernest and John A. Kirkpatrick, Jr.
1975 Orthopedic Diseases, 4th ed. Philadelphia: W. B. Saunders.

Bailey, Joseph A., II
1970 Orthopaedic aspects of achondroplasia. Journal of Bone and Joint Surgery 52-A(7): 1285-1301.

1971 Elbow and other upper limb deformities in achondroplasia. Clinical Orthopaedics 80: 75-78.

1973 Disproportionate Short Stature. Philadelphia: W. B. Saunders.

Bass, William M.
1971 Human Osteology: a Laboratory and Field Manual of the Human Skeleton. Columbia: Missouri Archaeological Society.

Brothwell, Don
1967 Major congenital anomalies of the skeleton: evidence from earlier populations. In Don Brothwell and A. T. Sandison, eds., Diseases in Antiquity, pp. 423-443. Springfield: C. C. Thomas.

Caffey, John
1958 Achondroplasia of pelvis and lumbo-sacral spine. Some roentgenographic features. American Journal of Roentgenology 80(3): 449-457.

Coe, Michael D.
1965 The Jaguar's Children. New York; Museum of Primitive Art.

Comas, Juan
1960 Manual of Physical Anthropology. Springfield: C. C. Thomas.

Corson, Christopher Robert
1972 Stylistic history and culture-historical implications of the Maya figurine complex of Jaina, Campeche. Ph. D. Dissertation, Department of Anthropology, University of California, Berkeley.

Edeiken, Jack and Philip J. Hodes
1973 Roentgen Diagnosis of Diseases of Bones, 2nd. ed. Volume One. Baltimore: Williams and Wilkins.

Farkas, Gyula and Imre Lengyel
1971/72 Skeleton of a medieval dwarf from Ludos-Csurgo (Yugoslavia). A Mora Ferenc Muzeum Evkonyve 1971/72: 199-207.

Grady, Mark Allen
1969 An osteological analysis of selected burials from the Rooney extension of 4-Sac-127, Sacramento, California. Unpublished M.S. thesis, Sacramento State College.

Greenfield, George B.
1975 Radiology of bone diseases, 2nd. ed. Philadelphia: J.B. Lippincott.

Hoffman, J. Michael
1975 A prehistoric achondroplastic dwarf from California: a preliminary note. Paleopathology Newsletter 11: 3-4.

Jaffe, Henry L.
1972 Metabolic, Degenerative and Inflammatory Diseases of Bones and Joints. Philadelphia: Lea & Febiger.

Janssens, Paul A.
1970 Paleopathology. Diseases and Injuries of Prehistoric Man. New York: Humanities Press.

Kaufmann, E.
1892 Untersuchungen uber die Sogenannte foetale Rachitis (Chondrodystrophy Foetalis). Berlin: Georg Reimer.

Langer, Leonard O., Jr., Paul A. Baumann, and Robert J. Gorlin
1967 Achondroplasia. American Journal of Roentgenology 100(1): 12-26.

Linne, S.
1943 Humpbacks in ancient America. Ethnos 8: 161-186.

Nemeskeri, J. and L. Harsanyi
1959 Bie Bedeuting paleopathologischer Untersuchungen fur die historische Anthropoloie. Homo 10: 203-226.

Parrot, M.J.
1878 Sur la malformation achondroplasique et le dieu Phtah. Bull. Soc. Anthropol. Paris 1 (3rd ser.): 296-308.

Phenice, T.W.
1969 A newly developed visual method of sexing the os pubis. American Journal of Physical Anthropology 30: 297-302.

Ponseti, I.V.
1970 Skeletal growth in achondroplasia. Journal of Bone and Joint Surgery 52-A(4): 701-716.

Proskouriakoff, Tatiana
1949 Some non-classic traits in the sculpture of Yucatan. In: Sol Tax, ed., The Civilizations of Ancient America, Vol. 1, pp. 108-118. Chicago: University of Chicago Press.

Ruffer, Sir Marc Armand
1921 Studies in the Palaeopathology of Egypt. Roy L. Moodie, ed. Chicago: University of Chicago Press.

Snow, Charles E.
1943 Two prehistoric Indian dwarf skeletons from Moundville. Alabama Museum of Natural History, Museum Paper 21. University, Alabama.

Stewart, T.D.
1975 Cranial dysraphism mistaken for trephination. American Journal of Physical Anthropology 42: 435-438.

Thompson, J.E.S.
1970 Maya History and Religion. Norman: University of Oklahoma Press.

von Winning, Hasso
1974 The Shaft Tomb Figures of West Mexico. Southwest Museum Papers No. 24. Highland Park, Los Angeles, California.

Warkany, Josef
1971 Congenital Malformations. Notes and Comments. Chicago: Year Book Medical Publishers.

Wells, Calvin
1964 Bones, Bodies and Disease. New York: Praeger.

APPENDIX A. Osteometric data from achondroplastic dwarf from CA-Sac-127 (all measurements in mm)

CRANIUM		
Glabello-occipital length	170	
Maximum breadth	148	
Basion-bregma height	138	
Minimum frontal b.	96	
Basion-nasion l.	85	
Basion-prosthion l.	80	
Horizontal circumference	517	
Nasion-opisthion arc	385	
Bizygomatic b.	126	
Midfacial (bimaxillary) b.	92	
Total facial h.	108	
Upper facial h.	61	
Nasal h.	44	
Nasal b.	25	
Orbital h.	34L	34R
Orbital b. (maxil-front)	42L	42R
Orbital b. (dacryon)	36L	36R
Anterior interorbital b.		
(maxil-front)	20	
(dacryon)	28	
Biorbital b.	101	
Maxillo-alveolar l.	49	
Maxillo-alveolar b.	57	
MANDIBLE		
Condylo-symphyseal l.	95	
Bicondylar b.	116	
Bigonial b.	97	
Height of symphysis	34	
Mandibular h., right	56	
Min. b. ascending ramus	32	
Mandibular angle	116	

INDICES		
Cranial	87.1	
Length-height	81.2	
Breadth-height	93.2	
Mean height	86.8	
Cranial module	152	
Frontal-parietal	64.9	
Total facial	85.7	
Upper facial	48.4	
Nasal	56.8	
Orbital (max-front)	81.0L	81.0R
Orbital (dacryon)	94.4L	94.4R
Palatal	116.3	
Mandibular 1-br	81.9	
Mandibular 1-ht	58.9	

HUMERUS		
Maximum l.	157	159
Midshaft circumference	56	55
Max. diam. head	36	36
Max. diam. midshaft	21	20
Min. diam. midshaft	20	20
Index robustness*	35.7	34.6
Humeral-femoral index	70.7	70.4

RADIUS		
Maximum l.	127	--
Midshaft circumference	32	(34)
Index robustness	25.2	--
Humeral-radial index	80.9	--

ULNA		
Maximum l.	148	156
Midshaft circumference	38	38
Index robustness	25.7	24.4

SCAPULA		
Maximum l.	--	130
Maximum b.	83	85
Length of spine	--	99

CLAVICLE		
Maximum l.	114	117
Midshaft circumference	32	32
Index robustness	28.1	27.4
Clavicular-humeral index	20.4	20.4

FEMUR	Left	Right
Maximum l.	222	(226)
Midshaft circumference	67	(66)
Bicondylar l.	211	(219)
Max. diam. head	37	--
Subtroch. a-p diam.	20	18
Subtroch. lat. diam.	25	28
Midshaft a-p diam.	18	19
Midshaft lat. diam.	21	20
Platymeric index	80.0	64.3
Index robustness	30.2	(29.2)
TIBIA		
Maximum l.	193	194
Midshaft circumference	58	57
Nutrient a-p diam.	23	23
Nutrient lat. diam.	20	19
Midshaft a-p diam.	19	19
Midshaft lat. diam.	16	16
Platycnemic index	87.0	82.6
Index robustness	30.1	29.4
Tibio-femoral index	86.9	85.8
FIBULA		
Maximum l.	210	207
Midshaft circumference	39	43
SACRUM		
Height	96	
Breadth	(99)	
Index	(103.1)	
INNOMINATES		
Height	154	--
Breadth	122	--
Index	126.2	--

* All robusticity indices follow Snow, r.i. $= \frac{\text{midshaft circumference}}{\text{maximum length}}$, to keep indices comparable; this does not follow the formulae presented in Bass 1971.

ILLUSTRATIONS

Plate 1. Partially reconstructed dwarf prior to its disassembly

Top: Left - achondroplastic dwarf skeleton from CA-Sac-127, sans ribs and small bones of hands and feet

Middle - complete vertebral column from C1 through L5

Right - vertebrae T9 through T12; note plaster intervertebral disc reconstructions

Bottom: Left - anterior view of lower limb bones; note reconstructed right femoral head and excessive tarsal extension of both fibulae

Middle right - anterior view of upper limb long bones; note lack of full extension at elbow

Lower right - left anterosuperior view of reconstructed pelvis (right innominate is plaster mirror image of the left); note broad, shallow pelvic inlet (see Plate 5)

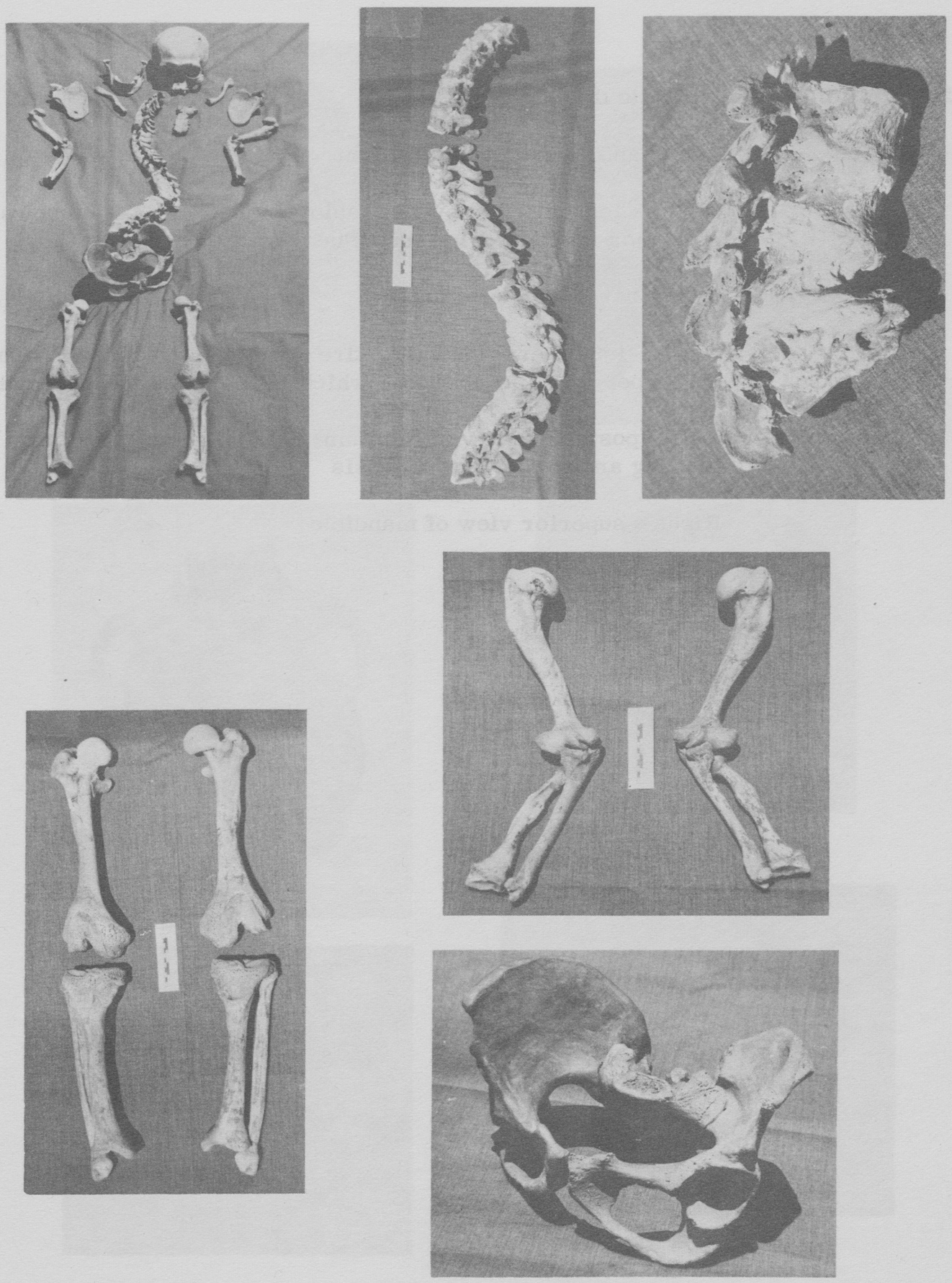

Plate 1

Plate 2. Skull of achondroplastic dwarf

Top:	Left - anterior view of cranium
	Right - left lateral view of cranium; note lesion (at arrows) in posterior frontal region (see Plate 3)
Middle:	Left - basal view of cranium
	Right - left lateral view of entire skull; note recessed nasal and upper maxillary regions which accentuates the prognathism
Bottom:	Left - posterior view of cranium; note extreme biparietal bossing and foci of osteoporosis
	Right - superior view of mandible

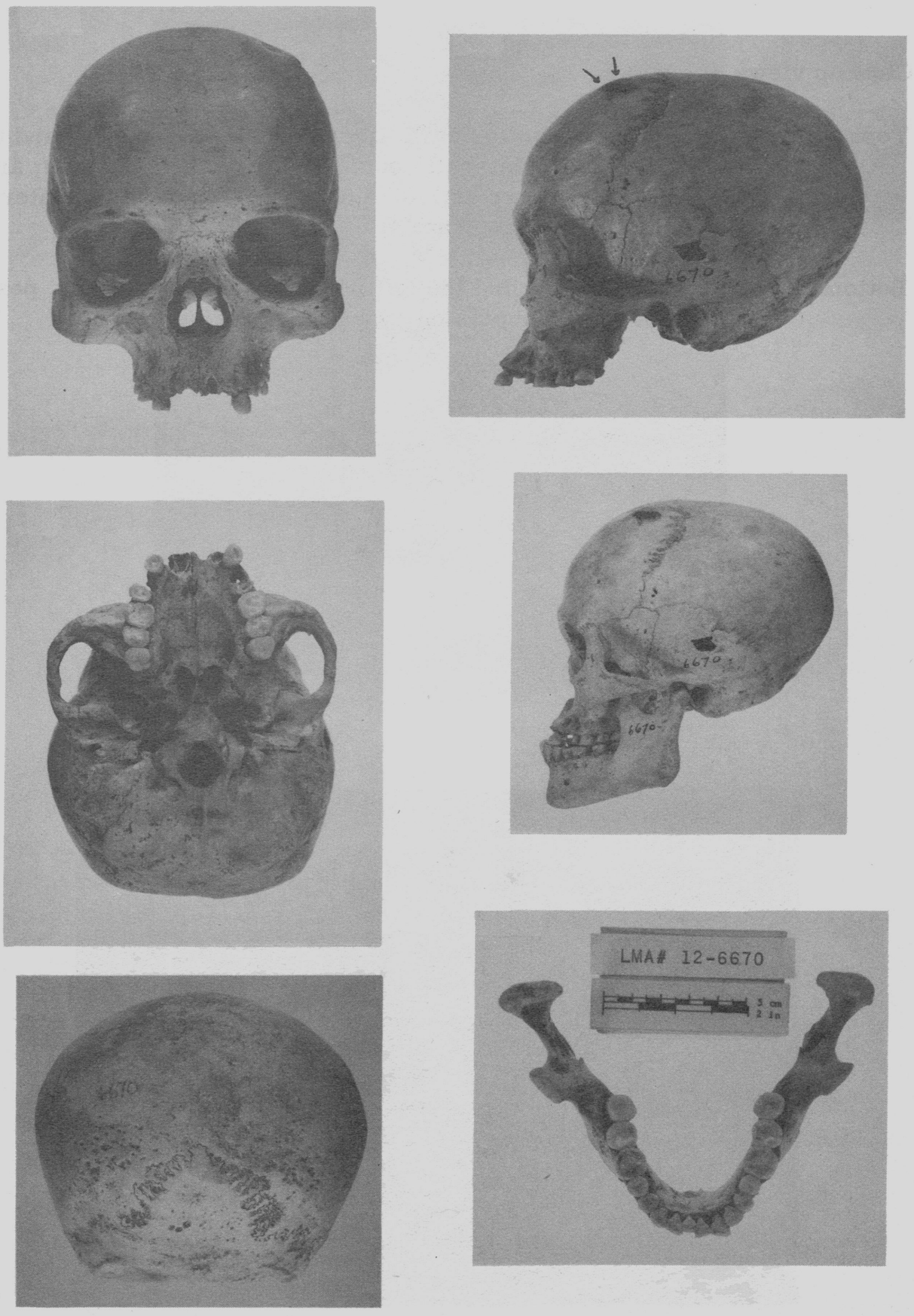

Plate 2

Plate 3. Closeup views of cranium

Top: cranial base; note small, angular foramen magnum and the foreshortened, laterally compressed base as a whole; arrows point to accessory articular facet for expanded left lateral mass of atlas (see Plate 4)

Bottom: the lesion involving the left posterior frontal region, possibly an epidermoid inclusion cyst or hemangioma

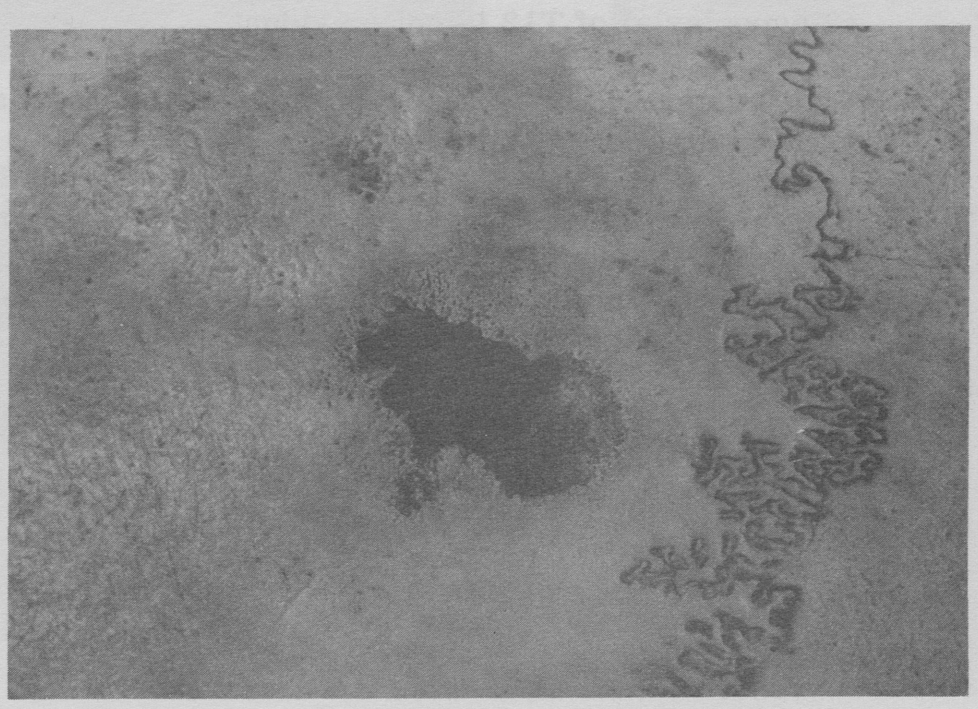

Plate 3

Plate 4. Vertebral column elements

Top: Left - superior view of articulated atlas and axis; note expanded lateral masses of atlas with accessory articular facet on left (at arrows)

Middle - right superolateral view of C7; note absence of right costal element (results in a notch for the vertebral artery rather than a closed transverse foramen); arrows point to articular facet for a right cervical rib; there is a partially bridged transverse foramen on the left

Right - superior view of L5; note extremely contracted vertebral canal, as much a result of the narrowed interlaminar distance as the reduced interpediculate distance; the actual length of the pedicles is reduced as well as the interpediculate distance.

Middle: Left - right lateral view of T11 through L1; note anterior wedging of all vertebrae (producing a prominent kyphotic deformity) and extensive anterior osteophytosis

Right - left lateral view of T11 through L1; the extreme wedging (? hypoplasia) of T12 is quite evident

Bottom: Left - anterior view of sacrum; note partial reconstruction of superior aspect of right ala

Right - left lateral view of sacrum with L5 in normal anatomical position; note complete lack of anterior sacral curvature, the exaggerated lumbosacral lordosis, and the reduced, deeply-concave auricular surface

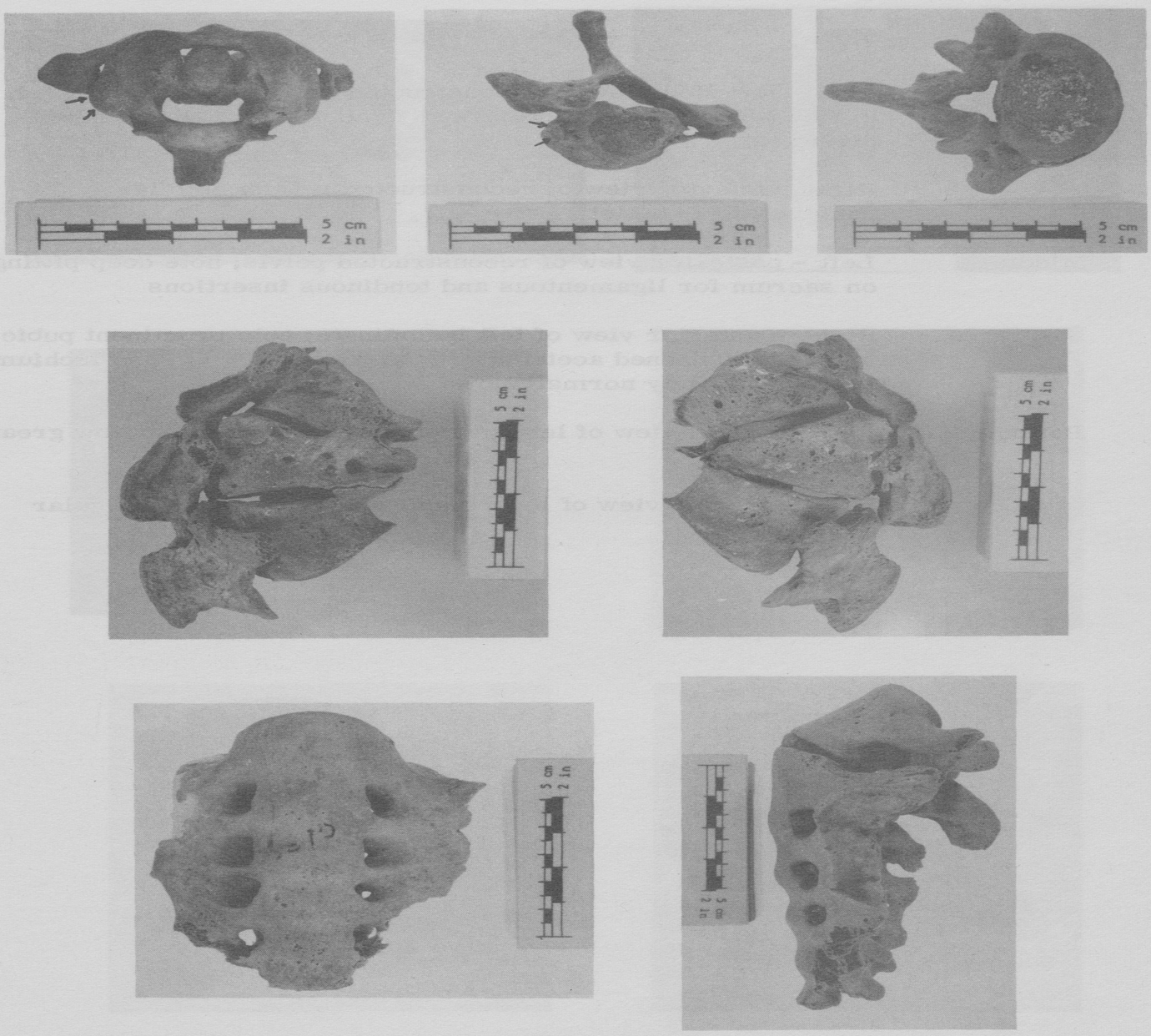

Plate 4

Plate 5. Pelvis

Top: Left - superior view of reconstructed pelvis; note contracted, kidney-shaped inlet with markedly reduced anteroposterior diameter

Right - inferior view of reconstructed pelvis; note large, expansive pelvic outlet

Middle: Left - posterior view of reconstructed pelvis; note deep pitting on sacrum for ligamentous and tendinous insertions

Right - anterior view of left innominate; note prominent pubic tubercle, flattened acetabular roof, reduced ilium and ischium with a relatively normal pubis

Bottom: Left - lateral view of left innominate; note wide, shallow greater sciatic notch

Right - medial view of left innominate; note small auricular surface

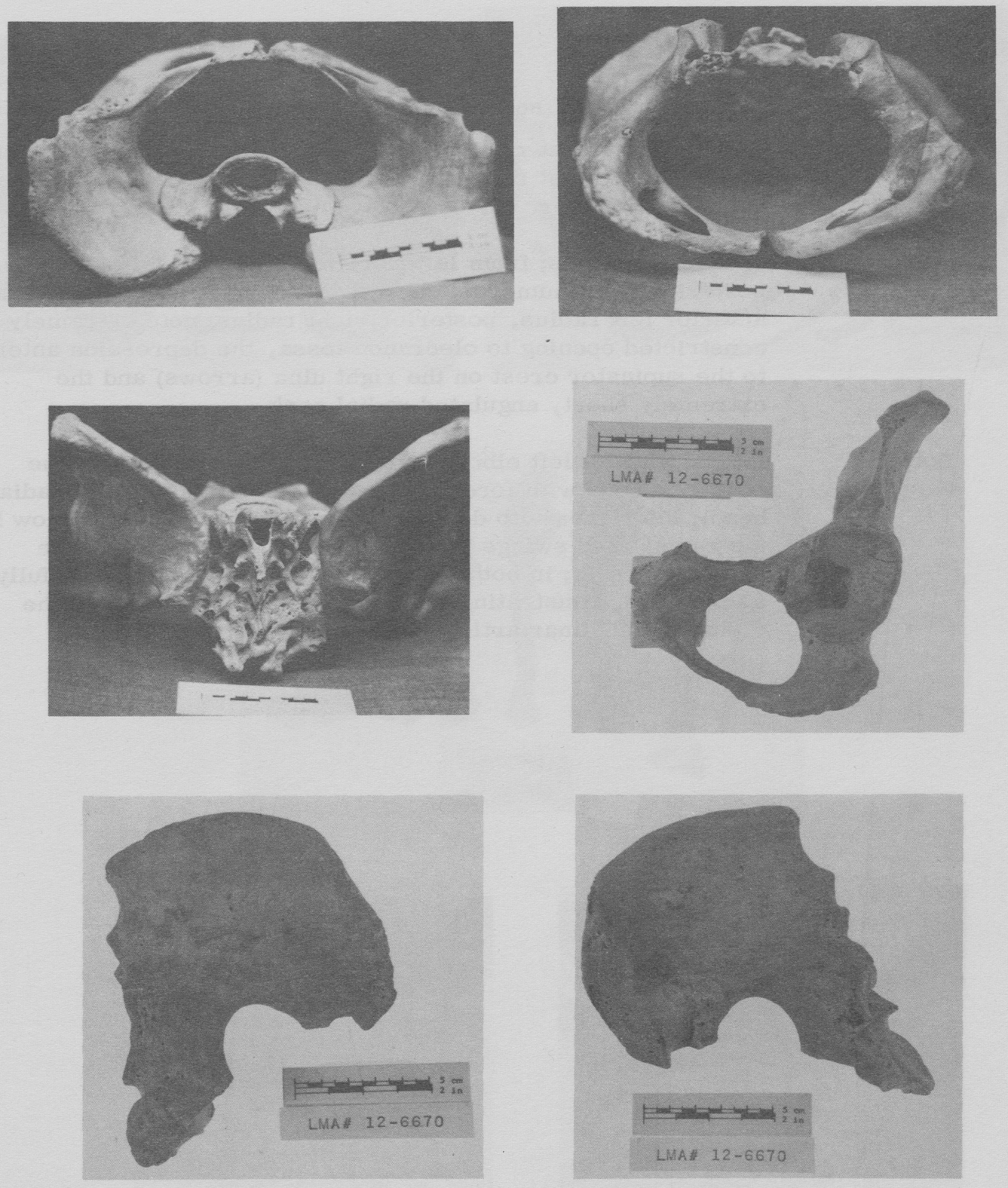

Plate 5

Plate 6. Thoracic and upper limb bones

Top: Left - clavicles, scapulae, and sternum sans xiphoid

Right - right first rib (top) and nine left ribs; note exaggerated curvature of most ribs, producing a constricted anteroposterior thoracic diameter

Middle: upper limb bones; from left to right - anterior left humerus, posterior right humerus, medial left ulna, lateral right ulna, anterior left radius, posterior right radius; note extremely constricted opening to olecranon fossa, the depression anterior to the supinator crest on the right ulna (arrows) and the extremely short, angulated radial neck

Bottom: lateral view of left elbow region; the left photo depicts the bony relations with forearm supinated (note dislocated radial head); the right photo depicts the forearm pronated to show how the radial head swings into the depression anterior to the supinator crest; in both photos the elbow is extended as fully as possible, illustrating the decreased carrying angle; the distal radial-ulnar articulations (not seen) are normal

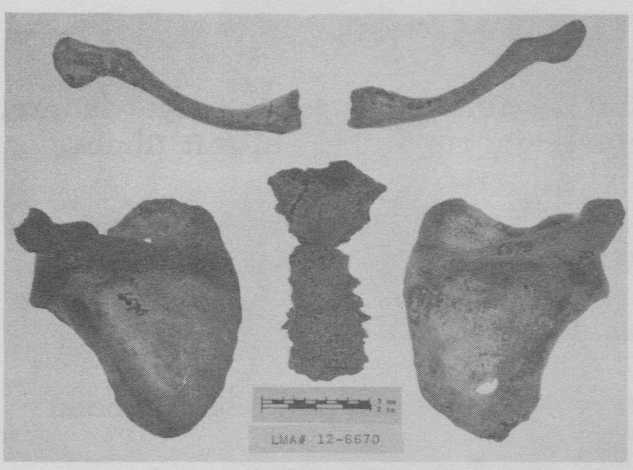



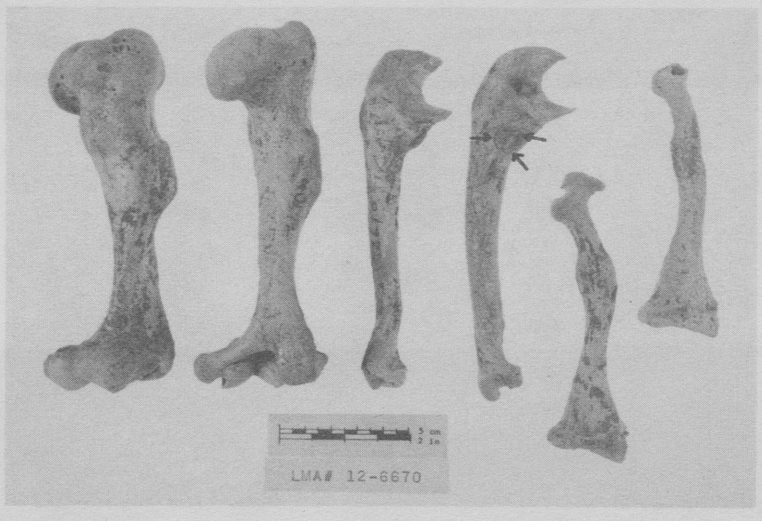

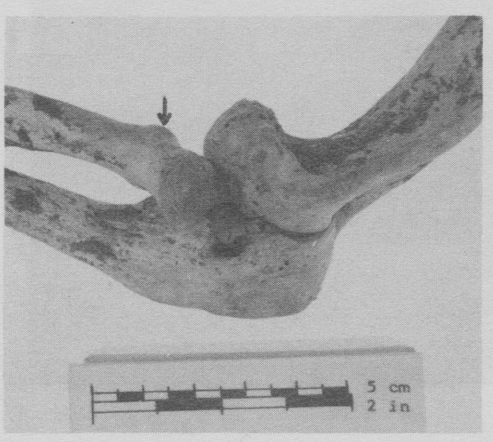

Plate 6

Plate 7. Lower limb bones, plus metacarpals

Top: from left to right - anterior left femur, posterior right femur, anterior left tibia, posterior right tibia, lateral left fibula, medial right fibula

Bottom: Left - left cuboid and calcaneus

Middle - left fifth metatarsal and talus

Right (top to bottom) - left second metacarpal, right second and third metacarpals

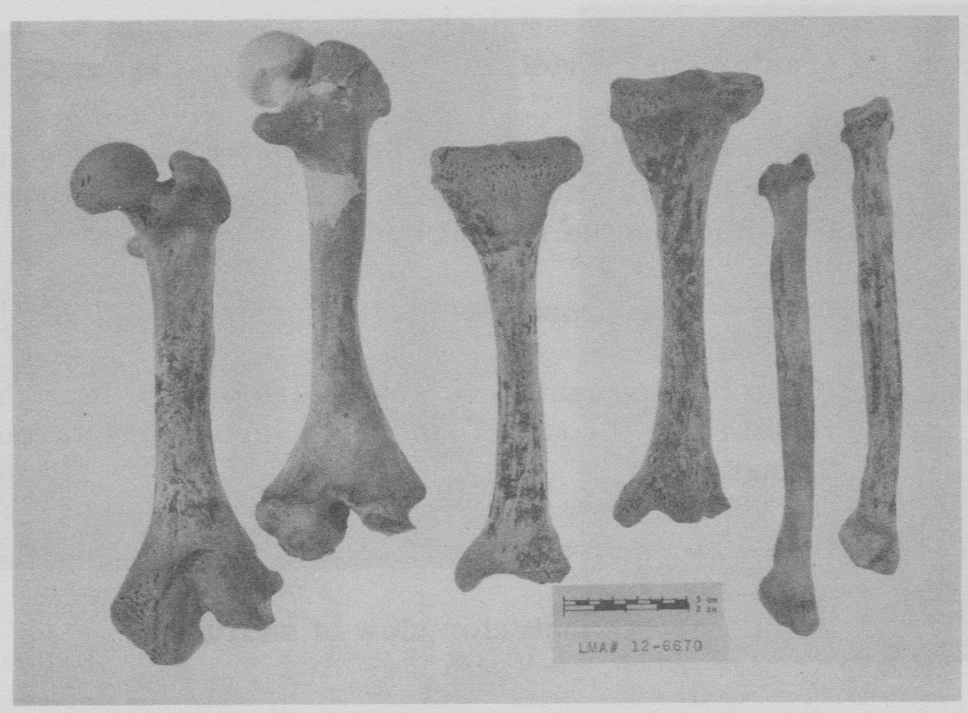

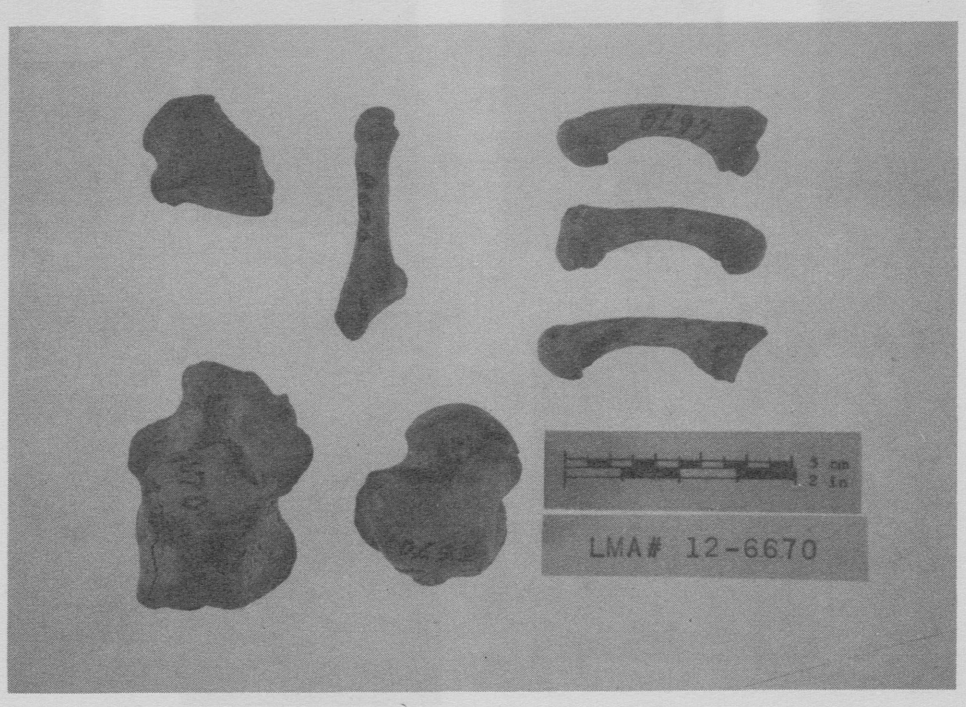

Plate 7

Plate 8. Radiographs of cranium and vertebral column (see text for description)

Top: Left - lateral radiograph of cranium; note shortened cranial base, hypoplastic upper face, and sclerotic borders surrounding the lesion on the frontal bone (posterior aspect)

Right - anteroposterior radiograph of cranium

Middle: (from left to right) - cervical vertebrae 1 through 7, thoracic vertebrae 1 through 5, thoracic vertebrae 6 through 10, T11 through L1

Bottom: Left - lumbar vertebrae 2 through 5

Right - anteroposterior view of sacrum

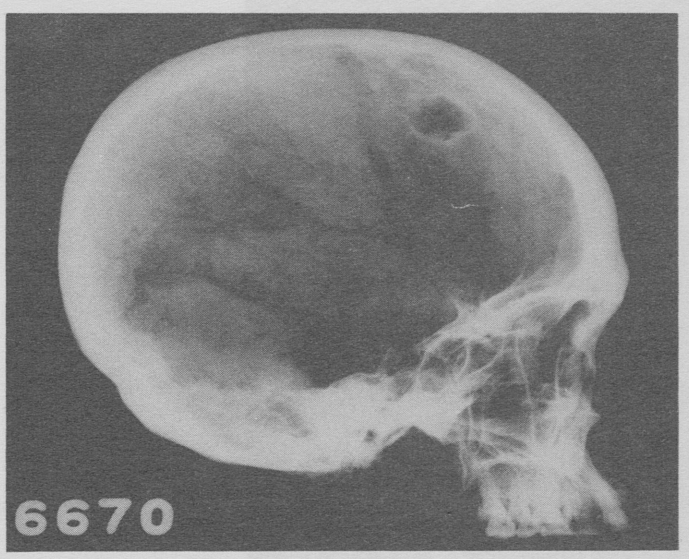

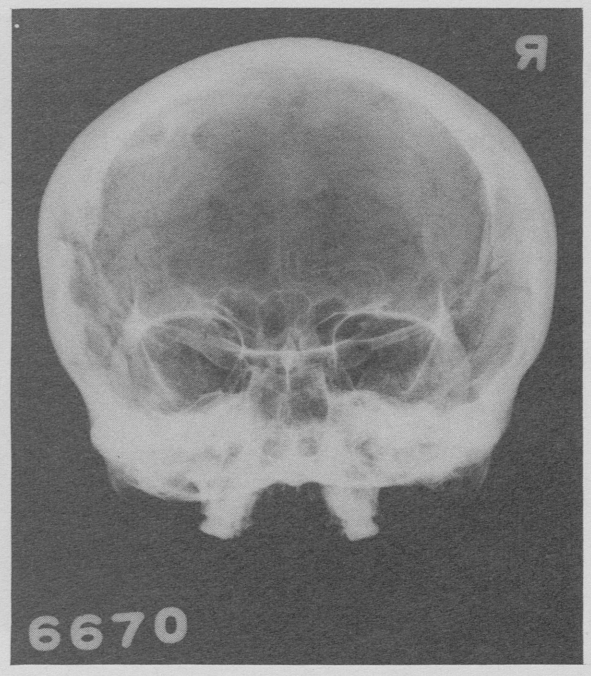

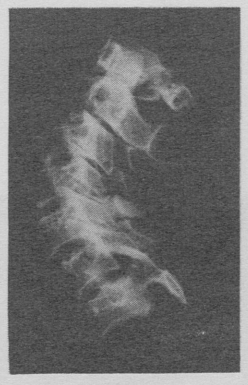

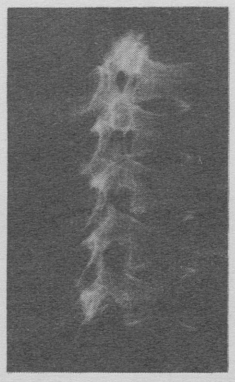

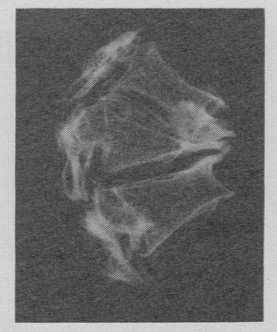

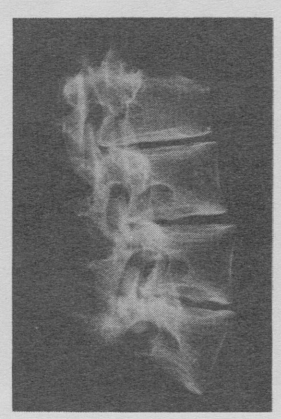

Plate 8

Plate 9. Radiographs of miscellaneous bones

Top: mandible, three ribs, left calcaneus

Bottom: Left - mandible, clavicles, sternum

Right - left innominate, scapulae

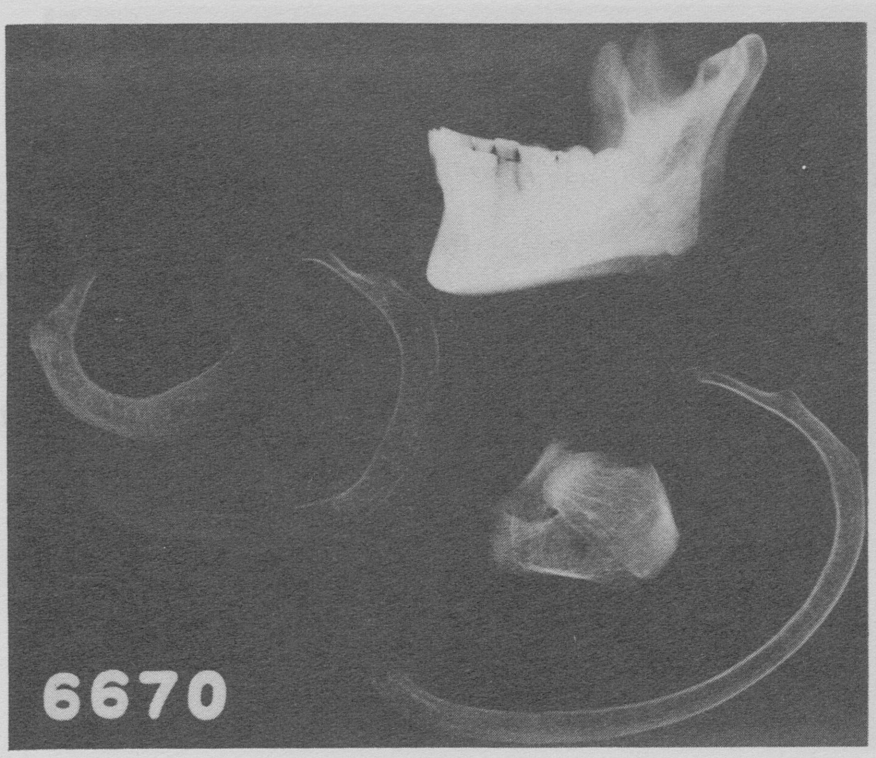

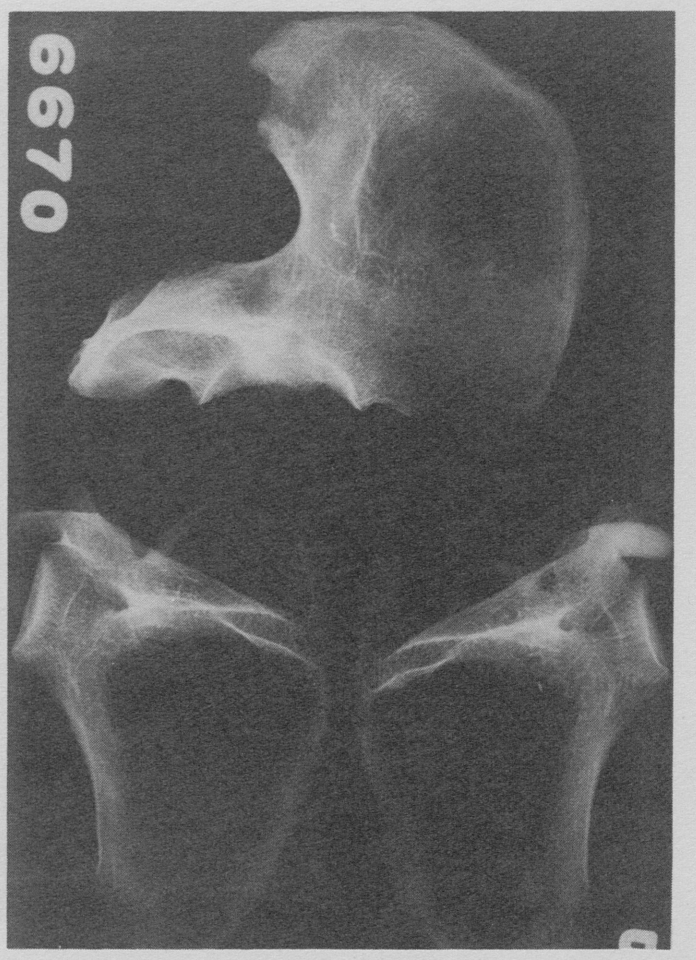

Plate 9

Plate 10. Radiographs of limb bones

Top: humeri, ulnae, radii

Bottom: Left - femora, fibulae; note plaster reconstruction in right femur

Right - tibiae, left fifth metatarsal and three metacarpals

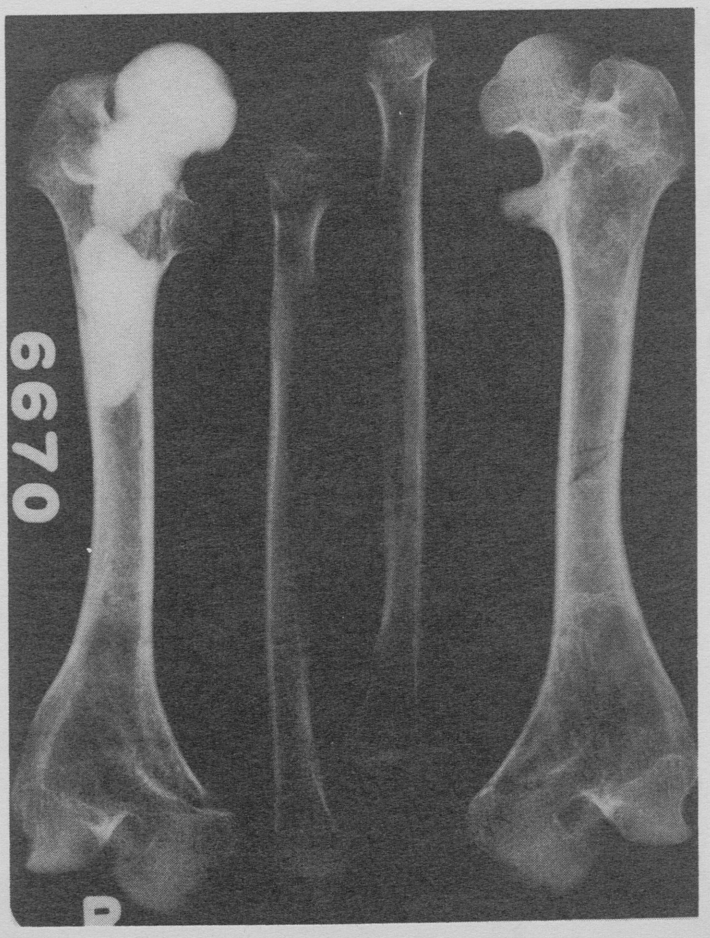

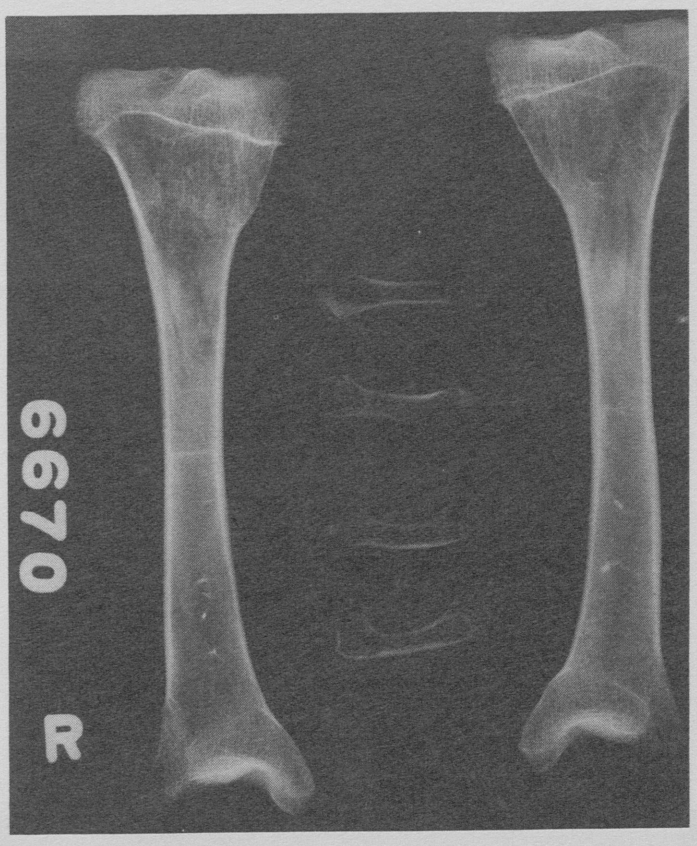

Plate 10