

UCSF

UC San Francisco Previously Published Works

Title

Invasive mucinous adenocarcinoma of the lung with bronchorrhea - A marked reduction volume of sputum after SARS-CoV-2 infection.

Permalink

<https://escholarship.org/uc/item/0fn8z53s>

Authors

Liu, Xin

Zhou, Xinyue

Zhang, Xiaocong

et al.

Publication Date

2024

DOI

10.1016/j.rmcr.2024.101982

Peer reviewed



Contents lists available at ScienceDirect

Respiratory Medicine Case Reports

journal homepage: www.elsevier.com/locate/rmcr

Case Report

Invasive mucinous adenocarcinoma of the lung with bronchorrhea — A marked reduction volume of sputum after SARS-CoV-2 infection

Xin Liu^{a,1}, Xinyue Zhou^{a,1}, Xiaocong Zhang^a, Lingling Sun^a, Guangdan Zhao^a,
Shitao Mao^a, Fangzhi Li^a, Xiu Gu^a, Paul J. Wolters^b, Shuo Liu^{a,*}

^a Department of Respiratory Medicine, The Fourth Hospital of China Medical University, Shenyang, Liaoning, 110032, PR China

^b Division of Pulmonary, Critical Care, Allergy and Sleep Medicine, Department of Medicine, University of California, San Francisco, CA, USA

ARTICLE INFO

Keywords:

Bronchorrhea
Invasive mucinous adenocarcinoma
COVID-19

ABSTRACT

Bronchorrhea is a watery sputum volume of at least 100 mL/day, which is commonly associated with lung malignancies. We report a 57-year-old woman was admitted to the hospital with a cough, profuse sputum. Chest CTs showed crazy paving pattern and lung nodules. Cell nests were visible on the Thinprep Cytologic Test. The case was considered an invasive mucinous adenocarcinoma of the lung combined with bronchorrhea. Significantly, the sputum volume declined rapidly and did not rise again when the patient was diagnosed with COVID-19 and treated with nirmatrelvir/ritonavir. This case is suggestive of studies related to regulatory mediators associated with bronchorrhea.

1. Introduction

Bronchorrhea is defined as excess production of watery sputum (≥ 100 mL/d) that can occur with primary and metastatic lung cancer. In this case we report a female patient suffered from invasive mucinous adenocarcinoma of the lung with bronchorrhea. She had an uncontrollable cough and sputum volume of up to 1500 mL/d. After the diagnosis of COVID-19 and administration of antiviral therapy, her sputum volume decreased dramatically.

2. Case presentation

A 57-year-old female patient was admitted to the hospital with complaints of cough, sputum, and progressive shortness of breath for the past 18 months. At the first visit to a local hospital in March 2022, a chest CT showed multiple hyperdense shadows in both lungs (Fig. 1A), which were considered pneumonia. She was treated with antibiotics without improvement. The higher hospital visited refined infection-related tests based on the CT done in March 2022, and made a diagnosis of interstitial lung disease, and treated with steroids (methylprednisolone 40mg iv bid*11d, prednisone 40mg po qd, tapering off by 10mg every 2 weeks) for more than 1 month, and with improved symptoms. The patient's dyspnea worsened in May 2022, and a consolidated lung infection was considered. After the administration of prednisone and gammaglobulin treatment, the condition improved. Chest CT showed ground-glass opacity and interlobular septal thickening (Fig. 1B) after treatment. One month before her hospital admission, she presented with a marked increase in white frothy sputum, with occasional blood in sputum, and shortness of breath at rest. One week before admis-

* Corresponding author.

E-mail address: cmu4hliushuo@126.com (S. Liu).

¹ These authors contributed equally to this work.

<https://doi.org/10.1016/j.rmcr.2024.101982>

Received 7 November 2023; Received in revised form 3 January 2024; Accepted 8 January 2024

Available online 12 January 2024

2213-0071/© 2024 Published by Elsevier Ltd.

This is an open access article under the CC BY-NC-ND license

(<http://creativecommons.org/licenses/by-nc-nd/4.0/>).

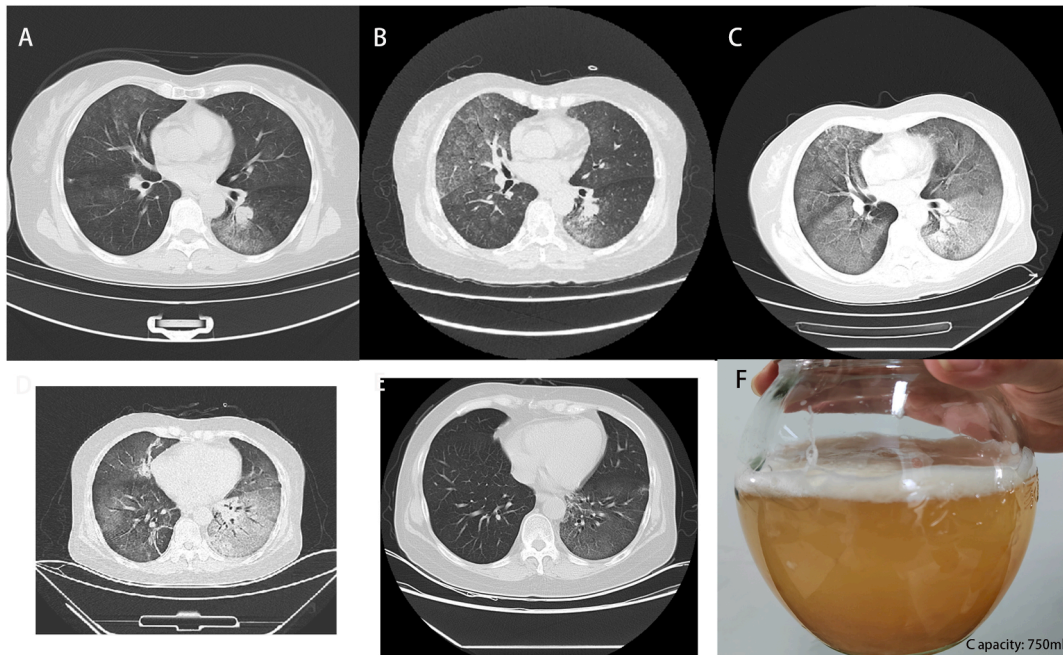


Fig. 1. Chest CT performed March 2022 found scattered ground-glass shadows in both lungs, with interlobular septal thickening predominantly in the left lower lung, and a well-margined nodule adjacent to the hilum in the left lower lobe of the lung (Fig. 1A). Chest CT performed May 2022 (Fig. 1B) and April 2023 (Fig. 1C) demonstrating increased opacities in a “crazy-paving” pattern, with no significant change in the left lung nodule. CT performed May 2023 showed an increase in the extent of solid lesions and a reduction in the ground glass shadow (Fig. 1D). CT in July 2023 showed a reduction in both the paving stone sign and solid shadows, with nodules still visible in the lower lobe of the left lung (Fig. 1E). Sputum collected before treatment settled over time in two layers, the upper layer showing a white foamy consistency and the lower layer showing a yellow mucus consistency (Fig. 1F).

sion, she was treated with steroids (methylprednisolone 40mg iv qd*3d, changed to 80mg iv bid *4d), anti-infective and antifungal therapy, with no improvement in symptoms or sputum volume.

The patient's respiratory rate was 30 beats/min, oxygen saturation of 88 % on room air, with mild cyanosis, diminished breath sounds in both lungs, fine crackles could be heard at the base of both lungs. The cough was uncontrollable and productive of a large volume of sputum up to 1500 mL/d. The sputum separated into 2 layers, an upper layer of white frothy sputum, and a lower layer of yellow plasma-like mucus (Fig. 1F). Partial pressure of oxygen was 63 mmHg, oxygenation index was 75 mmHg. Leukocytes (12.3×10^9 cells/L, reference-range (RR): $4\text{--}10 \times 10^9$ cells/L), neutrophils ratio (95.6 %, RR: 50–70 %) increased, lymphocyte ratio (1.3 %, RR: 20–40 %) decreased. Lactate dehydrogenase (299 U/L, RR: 120–246 U/L) interleukin-6 (19.33 pg/mL, RR: <7 pg/mL), Cytokeratin 19 (10.03 ng/mL, RR: 0.1–3.3 ng/mL) was elevated. The patient was admitted to the hospital with negative nucleic acid tests for SARS-CoV-2 and influenza A virus, and negative for other pathogenic respiratory-related microorganisms.

Chest CTs performed in March 2022 (Fig. 1A), May 2022 (Fig. 1B) and April 2023 (Fig. 1C) showed a left lung nodules with progressively worsening ground glass opacities in a crazy paving (CP) pattern in both lungs.

Bronchoscopy on the third day of admission revealed a large quantity of white foamy secretion in the lumen of the trachea. A cryobiopsy was performed. Cells nests were seen on the Thinprep Cytologic Test of sputum and BALF. Nests of wreath-like cells with micropapillary morphology, high nucleus-to-cytoplasm ratio, dark-stained nuclei, and absence of vascular centers are seen in the Thinprep Cytologic Test of BALF. A subsegmental biopsy of the anterior basal segment of the lower lobe of the left lung revealed atypical hyperplasia of the alveolar epithelium (Fig. 2). Positive periodic acid Schiff (PAS) staining material seen in BALF. Genetic testing for lung cancer showed EGFR mutations in exon 21 (mutation frequency: 32.87 %) and exon 18 (mutation frequency: 32.56 %), and PD-L1 expression <1 %.

The patient developed a fever on day 8 of admission. SARS-CoV-2 infection was identified. Antiviral therapy was administered: nirmatrelvir 300mg/ritonavir 100mg q12h orally, decadron (6mg qd iv). After one day of medication, the sputum volume decreased rapidly to 20 mL/d and stabilized thereafter. And the volume did not increase after COVID-19 treatment was completed. A repeat CT showed an increase in the extent of solid lesions in the lower lobes of both lungs and reduction in the ground glass opacities in the upper lobes of both lungs (Fig. 1D).

This patient was diagnosed as invasive mucinous adenocarcinoma of the lung with bronchorrhea and COVID-19. The patient was discharged from the hospital after stabilization and treated with afatinib dimaleate tablets 40mg qd orally. Follow-up two months later revealed significant improvement in clinical symptoms with almost no sputum, no respiratory secretions, and normal lung function. CT showed significant improvement of lung lesions, and nodules in the lower lobe of the left lung were still present (Fig. 1E).

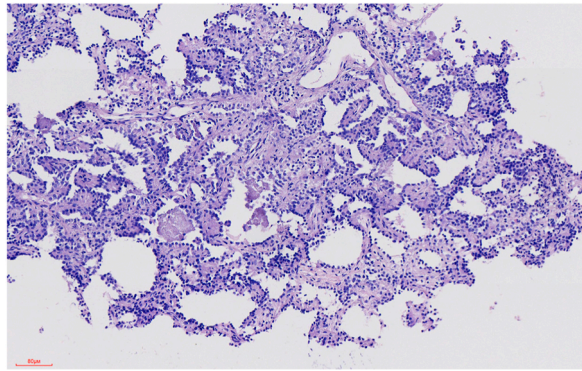


Fig. 2. Rapid H&E stain of a subsegment of the anterior basal segment of the lower lobe of the left lung reveals alveolar framework that structurally disorganized, with widened alveolar septa, visible papillary structures protruding into the alveolar lumen, partially lacking vascular centers, and nuclei directed away from the basement membrane.

3. Discussion

Bronchorrhea is commonly seen in malignant tumors [1]. In case reports on bronchorrhea, sputum volume usually exceeds several hundred milliliters and can be as high as 9 L/d [2]. There is no standardized treatment regimen for bronchial mucus overflow. In some case reports, a progressive decrease in respiratory secretions was observed after treatment with corticosteroids, macrolide antibiotics, inhaled indomethacin, octreotide, or tyrosine-kinase inhibitors [3].

Unlike previous cases, this case showed a precipitous drop in respiratory secretions following infection with SARS-CoV-2 and administration of nirmatrelvir/ritonavir. There are four possible explanations for this phenomenon: (1) SARS-CoV-2 invades the mucus-producing bronchial and alveolar epithelium, resulting in acute, extensive damage to the epithelium, as well as dysfunction, which in turn leads to a rapid decrease in respiratory secretion production. (2) Nirmatrelvir/ritonavir blocks or activates certain channels to correct the hypersecretory state of epithelial cells, which are widely distributed in the respiratory tract and are associated with fluid secretion, such as chloride channels and the aquaporin family. (3) The imaging presentation of CPs is a characteristic manifestation of pulmonary alveolar proteinosis (PAP) and usually suggests the possibility of secondary PAP. In this case, PAP cannot be completely excluded, however the sputum did not have a characteristic appearance of PAP secretions. PAP is associated with inhibition of normal phagocytosis by antibodies to Granulocyte-macrophage Colony Stimulating Factor (GM-CSF) [4]. In contrast, GM-CSF is elevated early in SARS-CoV-2 infection [5], which may allow macrophages to resume their function and clear respiratory secretions. (4) Steroids inhibit the secretion of glycoproteins and chloride, suppress the gene encoding inducible cyclooxygenase, and also directly inhibit the secretion of glycoproteins [3]. However, this patient presented with increased sputum volume prior to admission to the hospital, while high-dose steroids therapy was applied with no improvement in the symptoms. So in this case, it is unlikely that steroids contributed to the improvement in sputum production.

In conclusion, we report a unique case of mucinous adenocarcinoma and bronchorrhea that dramatically improved following SARS-CoV-2 infection. These observations may provide insight into mediators of the dysregulation of mucous production in cases of mucinous adenocarcinoma. In the detection of abnormal chest shadows and bronchorrhea, associated lung malignancies should be considered. Some tumors present similarly to infectious and interstitial lung diseases and require lung biopsy for early differentiation.

Funding

This research did not receive any specific grant from funding agencies in the public, commercial, or not-for-profit sectors.

CRediT authorship contribution statement

Xin Liu: Data curation, Writing – original draft. **Xinyue Zhou:** Data curation. **Xiacong Zhang:** Data curation. **Lingling Sun:** Data curation. **Guangdan Zhao:** Data curation. **Shitao Mao:** Data curation. **Fangzhi Li:** Data curation. **Xiu Gu:** Data curation. **Paul J. Wolters:** Writing – review & editing. **Shuo Liu:** Writing – review & editing.

Declaration of competing interest

The authors declare that they have no known competing financial interests or personal relationships that could have appeared to influence the work reported in this paper.

References

- [1] N.L. Roeder, J.D. Marshall, C.J. Britto, A woman in her 60s with lung adenocarcinoma presents with copious watery sputum and respiratory failure, *Chest* 152 (6) (2017) e143–e146.
- [2] N. Hidaka, K. Nagao, Bronchioloalveolar carcinoma accompanied by severe bronchorrhea, *Chest* 110 (1) (1996) 281–282.
- [3] C. Rémi, J. Rémi, C. Bausewein, Pharmacological management of bronchorrhea in malignant disease: a systematic literature review, *J. Pain Symptom Manag.* 51 (5) (2016) 916–925.

- [4] C. McCarthy, B.C. Carey, B.C. Trapnell, Autoimmune pulmonary alveolar proteinosis, *Am. J. Respir. Crit. Care Med.* 205 (9) (2022) 1016–1035.
- [5] R.S. Thwaites, A. Sanchez Sevilla Uruchurtu, M.K. Siggins, F. Liew, C.D. Russell, S.C. Moore, C. Fairfield, E. Carter, S. Abrams, C.E. Short, T. Thaventhiran, E. Bergstrom, Z. Gardener, S. Ascough, C. Chiu, A.B. Docherty, D. Hunt, Y.J. Crow, T. Solomon, G.P. Taylor, L. Turtle, E.M. Harrison, J. Dunning, M.G. Semple, J.K. Baillie, P.J. Openshaw, Inflammatory profiles across the spectrum of disease reveal a distinct role for GM-CSF in severe COVID-19, *Sci Immunol* 6 (57) (2021).