

UCSF

UC San Francisco Previously Published Works

Title

Neuroimaging in genetic frontotemporal dementia and amyotrophic lateral sclerosis

Permalink

<https://escholarship.org/uc/item/0gs5f9cm>

Authors

Häkkinen, Suvi
Chu, Stephanie A
Lee, Suzee E

Publication Date

2020-11-01

DOI

10.1016/j.nbd.2020.105063

Peer reviewed



Published in final edited form as:

Neurobiol Dis. 2020 November ; 145: 105063. doi:10.1016/j.nbd.2020.105063.

Neuroimaging in genetic frontotemporal dementia and amyotrophic lateral sclerosis

Suvi Häkkinen, PhD¹, Stephanie A. Chu, BSc¹, Suzee E. Lee, MD¹

¹Memory and Aging Center, Department of Neurology, University of California, San Francisco, San Francisco, CA, USA.

Abstract

Frontotemporal dementia (FTD) and amyotrophic lateral sclerosis (ALS) have a strong clinical, genetic and pathological overlap. This review focuses on the current understanding of structural, functional and molecular neuroimaging signatures of genetic FTD and ALS. We overview quantitative neuroimaging studies on the most common genes associated with FTD (*MAPT*, *GRN*), ALS (*SOD1*), and both (*C9orf72*), and summarize visual observations of images reported in the rarer genes (*CHMP2B*, *TARDBP*, *FUS*, *OPTN*, *VCP*, *UBQLN2*, *SQSTM1*, *TREM2*, *CHCHD10*, *TBK1*).

Keywords

frontotemporal dementia; amyotrophic lateral sclerosis; motor neuron disease; presymptomatic; genetics; neuroimaging

1 INTRODUCTION

Frontotemporal dementia (FTD) is a clinically heterogeneous group of neurodegenerative diseases characterized by early prominent changes in behavior and/or language accompanied by focal atrophy in frontal and temporal cortices. In contrast, amyotrophic lateral sclerosis (ALS) involves progressive degeneration of both upper and lower motor neurons, leading to progressive muscle weakness, and paralysis. Despite these distinctions in clinical presentation, the clinical, genetic, and pathological overlap between FTD and ALS has been well established, framing these diseases as part of a continuum. Clinically, 15% of patients with FTD develop motor neuron disease, and conversely, most patients with ALS develop increasing cognitive and behavioral deficits as their disease progresses (Burrell et al., 2011; Crockford et al., 2018; Lomen-Hoerth et al., 2002). Certain genetic variants such as the *C9orf72* expansion and mutations in *TBK1*, *VCP*, and *TARDBP* are known to cause FTD,

*Corresponding author: Suzee E. Lee, MD, UCSF Memory and Aging Center MC: 1207, 675 Nelson Rising Lane, San Francisco, CA 94109, suzee.lee@ucsf.edu.

Declarations of interest: none

Publisher's Disclaimer: This is a PDF file of an unedited manuscript that has been accepted for publication. As a service to our customers we are providing this early version of the manuscript. The manuscript will undergo copyediting, typesetting, and review of the resulting proof before it is published in its final form. Please note that during the production process errors may be discovered which could affect the content, and all legal disclaimers that apply to the journal pertain.

ALS, or both, whereas other genetic mutations are predominantly associated either with FTD or ALS (Fig. 1; Nguyen et al., 2018).

Because mutation-specific therapies are currently undergoing human clinical trials for genetic FTD and ALS, determining the neuroanatomical regions and selective cell populations that are targeted in each genetic mutation is critical for understanding disease trajectories. While the earliest imaging studies characterized patients by clinical syndrome, genotypic stratification has revealed mutation-specific vulnerabilities in neuroanatomical regions targeted in genetic FTD (Chen and Kantarci, 2020; Greaves and Rohrer, 2019) and ALS (Dharmadasa et al., 2018) that appear distinct from the sporadic forms of these diseases. For example, in FTD due to the *C9orf72* expansion, the characteristic frontotemporal atrophy may be milder or even absent and the atrophy pattern includes parietal (Cash et al., 2018; Irwin et al., 2013; Sha et al., 2012; Whitwell et al., 2012) and occipital (Sha et al., 2012; Whitwell et al., 2012) cortices. Patient-level findings in *C9orf72* expansion carriers suggest even greater heterogeneity with little or no atrophy in some patients with mild, slowly progressive, or even advanced dementia (Boeve et al., 2012; Khan et al., 2012).

Studying the genetic forms of FTD and ALS has also enabled the characterization of the earliest symptomatic and even presymptomatic phases in mutation carriers, with neuroimaging changes preceding symptom onset by years. Most studies have focused on identifying regional atrophy patterns as measured by brain volumetrics in structural T1-weighted magnetic resonance imaging (MRI) (Dopper et al., 2014; Olm et al., 2018; Panman et al., 2019; Rohrer et al., 2015). Microstructural changes (e.g. myelin thickness, axon density, cell swelling) in the white matter of presymptomatic carriers have been measured with diffusion MRI (Bertrand et al., 2018; Floeter et al., 2018; Olm et al., 2018; Panman et al., 2019). Functional MRI, which indirectly measures neural activity by assessing hemodynamics, has revealed presymptomatic abnormalities in resting-state or task-free network connectivity (Dopper et al., 2014; Lee et al., 2017; Menke et al., 2016). Metabolic and molecular imaging provide information about physiological changes such as abnormalities in cellular glucose metabolism measured by [¹⁸F]-fluorodeoxyglucose (FDG) positron emission tomography (PET) or perfusion weighted MRI (Dopper et al., 2016; Jacova et al., 2013; Mutsaerts et al., 2019), and in the concentrations of specific metabolites measured by proton magnetic resonance spectroscopy (¹H MRS) (Carew et al., 2011a; Chen et al., 2019d). While none of these imaging modalities enable identification of the specific neuropathological diagnoses in FTD or ALS, they provide useful data on alterations in brain function and structure. Here, we review neuroimaging studies of genetic mutations that cause 1) FTD, 2) ALS, and 3) FTD and/or ALS. First, we briefly examine neuroimaging studies in sporadic FTD and ALS as a backdrop to a more in-depth review of neuroimaging literature in patients with genetic forms of these diseases.

2 SPORADIC FTD AND ALS

2.1 FTD

FTD serves as an umbrella term for three clinical subtypes, which include behavioral variant FTD (bvFTD), and the semantic (svPPA) and nonfluent variants (nfvPPA) of primary

progressive aphasia (Gorno-Tempini et al., 2011; Neary et al., 1998; Rascovsky et al., 2011). While these three syndromes converge on frontotemporal atrophy (Gorno-Tempini et al., 2004; Rosen et al., 2002), each clinical syndrome targets a distinct network of regions whose dysfunction is associated with changes in social and emotional cognition and cognitive and motor function (Fig. 2; Seeley et al., 2009). Focal neurodegeneration can be asymmetric: in bvFTD, the right hemisphere often shows greater atrophy than the left, while the PPAs typically feature left hemispheric atrophy, corresponding to the higher frequency of left-sided language dominance in the population (Schroeter et al., 2007). With disease progression, atrophy spreads next to homologous regions in the contralateral hemisphere (Kumfor et al., 2016; Rohrer et al., 2009c, 2012).

2.1.1. bvFTD—BvFTD presents with early changes in personality or behavior, with absent or mild cognitive symptoms in early stages of the disease. Clinical criteria include a wide variety of neuropsychiatric behaviors, including disinhibited behavior, profound apathy, loss of empathy, repetitive or compulsive behavior, and hyperorality or rigid food preferences (Neary et al., 1998; Rascovsky et al., 2011). In bvFTD, neurodegeneration starts in the pregenual anterior cingulate and the frontoinsula cortex (Kim et al., 2012; Seeley et al., 2007a, 2008), with orbitofrontal cortex, striatum, amygdala, thalamus, and brainstem also targeted later in the disease (Broe et al., 2003). Unlike Alzheimer's disease, the parietal lobes are typically spared. Axonal degeneration, likely associated with gray matter neuron loss, often arises in the anterior corpus callosum, cingulum bundle and uncinate fasciculus (Agosta et al., 2012; Elahi et al., 2017; Lam et al., 2014; Mahoney et al., 2015, 2014; Whitwell et al., 2010; Zhang et al., 2013).

Studies show that specific types of behavioral symptoms in bvFTD are related to atrophy in distinct neuroanatomical regions. Disinhibited behavior has been associated with atrophy in right orbitofrontal cortex, while apathy is related to atrophy in anterior cingulate and medial prefrontal cortex (Rosen et al., 2005, 2002). Loss of empathy is associated with atrophy in several key hubs, including the right anterior temporal lobe, right anterior cingulate, anterior insula, and ventral striatum (Rankin et al., 2006). Simple stereotyped motor behavior relates to striatal atrophy, while more complex compulsions correlate with orbitofrontal, temporal lobe, and caudate atrophy (Josephs et al., 2008; Perry et al., 2012; Rosen et al., 2005; Rosso et al., 2001). Eating behaviors, which include increased carbohydrate consumption, eating of inedible objects, or rigid or ritualistic food preferences or schedules, are linked to degeneration of orbitofrontal cortex, right temporal lobe, right insula, striatum, and hypothalamus (Henry et al., 2014; Piguet et al., 2011; Whitwell et al., 2007b; Woolley et al., 2007).

Neurodegenerative syndromes target specific networks of distributed regions that are identifiable in healthy individuals, as measured by task-free fMRI intrinsic connectivity network (ICN) analysis (Greicius et al., 2004; Seeley et al., 2009). The key hubs of neurodegeneration in bvFTD form the salience network, proposed to evaluate the importance of emotionally significant stimuli (Seeley et al., 2007b). BvFTD typically is associated with disrupted connectivity within the salience network (Day et al., 2013; Filippi et al., 2013; Zhou et al., 2010), though some studies report hyperconnectivity or connectivity similar to controls (Farb et al., 2013; Hafkemeijer et al., 2015; Rytty et al., 2013). Intriguingly, the

default mode network, targeted in Alzheimer's disease, shows decreased but also increased connectivity in bvFTD, proposed to underlie enhanced visuospatial abilities and emerging visual artistic creativity in some patients (Zhou et al., 2010).

[¹⁸F]FDG-PET shows glucose hypometabolism within orbitofrontal, dorsomedial and dorsolateral prefrontal regions, anterior temporal pole and basal ganglia, which may be detectable in early stages before patients meet clinical criteria for probable bvFTD (Ber et al., 2006; Morbelli et al., 2016; Varma et al., 2002). Studies have reported that [¹⁸F]FDG-PET may distinguish patients with bvFTD from other patients with dementia (Buhour et al., 2017a; Diehl-Schmid et al., 2007; Morbelli et al., 2016; Tosun et al., 2016; Verfaillie et al., 2015; Vijverberg et al., 2016), yet frontal hypometabolism has also been reported in psychiatric disorders and Alzheimer's disease, which confounds diagnostic accuracy (Vijverberg et al., 2016). Tau PET tracers, such as [¹⁸F]flortaucipir, show limited sensitivity and specificity in FTD (Tsai et al., 2019).

2.1.2. svPPA—SvPPA is a progressive language disorder characterized by loss of word and object meaning and surface dyslexia, yet fluent, grammatically correct speech (Gorno-Tempini et al., 2011; Hodges and Patterson, 1996; Snowden et al., 1989). The anterior temporal lobe, typically more atrophied on the left compared with the right, shows prominent focal degeneration, sometimes with “knife-edge” gyri in patients with severe atrophy (Gorno-Tempini et al., 2004; Rogalski et al., 2011). DTI studies consistently show disruption in anterior and inferior temporal white matter tracts, including the inferior longitudinal fasciculi and uncinate fasciculi (Agosta et al., 2015, 2012; Lam et al., 2014; Mahoney et al., 2013; Schwindt et al., 2013; Tu et al., 2015; Zhang et al., 2013).

Task-free fMRI studies in healthy individuals show that the anterior temporal lobe has strong intrinsic connectivity to the anterior cingulate, orbitofrontal cortex, frontoinsula, striatum and thalamus (Guo et al., 2013; Seeley et al., 2009). Patients with svPPA also show disrupted connectivity within this anterior temporal network, also known as the semantic appraisal network, which processes semantic stimuli across various modalities (Agosta et al., 2014b; Guo et al., 2013).

Mirroring gray matter atrophy patterns, [¹⁸F]FDG-PET in svPPA typically features asymmetrical bilateral temporal hypometabolism (Cerami et al., 2017).

2.1.3. nfvPPA—In contrast to svPPA, the hallmarks of nfvPPA include effortful speech production and agrammatism with preservation of object knowledge and single-word comprehension (Gorno-Tempini et al., 2011; Grossman et al., 1996; Hodges and Patterson, 1996; Snowden et al., 1989). The left posterior frontoinsula and the left inferior frontal gyrus usually show the most profound atrophy (Gorno-Tempini et al., 2011, 2004). Left orbitofrontal and intrafrontal tracts, the superior longitudinal fasciculus and frontostriatal pathways are involved (Agosta et al., 2015, 2012; Lam et al., 2014; Mahoney et al., 2013; Mandelli et al., 2014; Schwindt et al., 2013; Zhang et al., 2013).

In healthy individuals, the inferior frontal gyrus is intrinsically connected to frontal operculum, middle frontal gyrus, primary and supplementary motor cortices, and inferior

parietal lobule, a network of regions critical for language and motor speech fluency (Battistella et al., 2020; Seeley et al., 2009), and patients with nvPPA show atrophy and reduced connectivity with these regions. [¹⁸F]FDG-PET shows hypometabolism reported in left inferior frontal gyrus, dorsolateral frontal cortex, anterior cingulate and insula (Cerami et al., 2017; Mesulam, 2003).

2.2 ALS

ALS is a progressive motor neuron disease that causes degeneration in upper and lower motor neurons. Clinical heterogeneity exists with respect to the site of onset, the degree of upper and lower motor neuron involvement, the rate of progression, and cognitive and behavioral symptoms (Strong et al., 2017). Patients with ALS have clinical overlap with FTD. Most patients develop some degree of behavioral and cognitive impairment with disease progression (Crockford et al., 2018; Lomen-Hoerth et al., 2002), with 15% of patients meeting clinical criteria for FTD (Ringholz et al., 2005).

Clinically, MRI has been used in ALS to exclude mimics of motor neuron disease, such as nerve root compression and neoplastic, vascular, and demyelinating diseases of the brain and spinal cord. Typically, conventional MRI shows mild or absent gray matter atrophy (Bede and Hardiman, 2018; Grieve et al., 2016; Walhout et al., 2015b). Upon visual assessment of the corticospinal tract or precentral gyrus, hypointensities on T2-weighted, fluid-attenuated inversion recovery or proton density sequences are variably noted, yet not adequately sensitive or specific to confirm a diagnosis of ALS (Filippi et al., 2010).

Quantitative MRI approaches such as voxel-based morphometry show that patients with ALS have atrophy in the precentral gyrus and inferior frontal cortex (Grosskreutz et al., 2006; Mezzapesa et al., 2013; Shen et al., 2016) with subcortical regions such as the striatum, thalamus and the cerebellum also targeted (Bede et al., 2013c; Bede and Hardiman, 2018; Menke et al., 2014; Westenberg et al., 2015). Cervical and upper thoracic spinal cord atrophy is associated with clinical severity and disease duration (El Mendili et al., 2014; Valsasina et al., 2006) and progressive longitudinal changes are detectable (Agosta et al., 2009; El Mendili et al., 2014). Those patients with bulbar versus limb onset show the expected corresponding atrophy within primary motor cortex (Bede et al., 2013a). Patients with ALS and FTD harbor more widespread frontotemporal atrophy (Lillo et al., 2012; Masuda et al., 2016; Omer et al., 2017).

Reflecting the disruption to upper motor neuron axons in ALS, diffusion MRI studies consistently revealed microstructural changes along the corticospinal tracts and in mid and posterior corpus callosum (Fig. 3; Bede and Hardiman, 2018; Broad et al., 2019; Müller et al., 2016; van der Graaff et al., 2011). Patients with primary lateral sclerosis, which involves upper motor neurons but not lower motor neurons, have more pronounced white matter disruption compared to patients with ALS (Agosta et al., 2014a). Studies of patients with lower motor neuron predominant presentations may also show extensive white matter disruption, suggesting that DTI may be capturing subclinical upper motor neuron disease in these patients (Müller et al., 2018). Patients with ALS who also feature behavioral or cognitive symptoms, including patients with frank bvFTD, additionally show white matter

involvement in frontotemporal tracts (Agosta et al., 2016; Lillo et al., 2012; Omer et al., 2017; Spinelli et al., 2016; Trojsi et al., 2013).

In task-free fMRI, the most consistent intrinsic connectivity network alteration is decreased sensorimotor network connectivity (Agosta et al., 2013; Douaud et al., 2011; Tedeschi et al., 2012; Trojsi et al., 2015). Most whole-brain investigations have additionally discovered connectivity decreases or increases between motor and non-motor regions and within extra-motor networks such as salience, default mode, and frontoparietal networks (Agosta et al., 2013; Menke et al., 2018; Mohammadi et al., 2009; Qiu et al., 2019; Tedeschi et al., 2012; Trojsi et al., 2015). Similarly, task-based fMRI studies have highlighted additional recruitment of non-motor brain regions during motor tasks in patients with ALS compared to controls (Abidi et al., 2019; Konrad et al., 2006; Poujois et al., 2013; Schoenfeld et al., 2005; Stanton et al., 2007). This functional reorganization is commonly interpreted to result from both degenerative and compensatory mechanisms.

Extra-motor involvement in ALS has been long suggested by PET studies, which show hypometabolism in non-motor cortex (Dalakas et al., 1987; Hatazawa et al., 1988; Kew et al., 1993). More recently, larger [^{18}F]FDG PET studies have converged on hypometabolism within the premotor and frontal cortices (Buhour et al., 2017b; Cistaro et al., 2012; Pagani et al., 2014; Van Laere et al., 2014). Several studies have also observed increased [^{18}F]FDG uptake, particularly in the brainstem (Cistaro et al., 2012; Pagani et al., 2014; Van Laere et al., 2014) and cervical spinal cord (Marini et al., 2016; Yamashita et al., 2017) of ALS patients, hypothesized to be due to glial cells surrounding degenerating neurons. Increased uptake of PET tracers that are associated with microglial activation and oxidative stress and decreased binding of GABAergic, serotonergic, and dopaminergic ligands has also been reported (Fu et al., 2017; Ikawa et al., 2015; Lloyd et al., 2000; Turner, 2005; Turner et al., 2005).

^1H MRS studies have revealed decreased NAA (an estimate of neuronal density) and, less consistently, low concentrations of myoinositol, glutamate, glutamine, and GABA along the corticospinal tract, posterior limb of the internal capsule, periventricular white matter (Atassi et al., 2017; Cheong et al., 2017; Pyra et al., 2010; Westeneng et al., 2017). NAA and myoinositol levels also correlate with measures of clinical severity in cervical spinal cord (Carew et al., 2011b; Ikeda et al., 2013) and prefrontal cortex (Hanstock et al., 2020).

Despite these advances, neuroimaging features alone are not able to diagnose bvFTD, PPA or ALS and instead are supportive in rendering clinical diagnoses. For bvFTD, frontal and/or anterior temporal atrophy on MRI or CT and/or hypoperfusion on PET and SPECT in these regions are supportive criteria in concert with symptoms, neuropsychological testing and functional assessment (Rascovsky et al., 2011). Similarly, diagnostic criteria for PPA also incorporate imaging features. Predominant left posterior fronto-insular atrophy on MRI or predominant left posterior fronto-insular hypoperfusion or hypometabolism on SPECT or PET supports the diagnosis of nvPPA (Gorno-Tempini et al., 2011). Predominant anterior temporal lobe atrophy (MRI) and/or hypoperfusion (SPECT/PET) support a diagnosis of svPPA. For ALS, neuroimaging studies are currently used only to exclude other conditions that may cause upper or lower neuron signs that mimic ALS (Brooks et al., 2000).

3 NEUROIMAGING STUDIES OF GENETIC MUTATIONS FOR FTD AND ALS

3.1 Genetic mutations for FTD and ALS: a brief overview

In 1994, autosomal dominant inheritance was first identified in a family with FTD and parkinsonism which was linked to chromosome 17q21.2 (Lynch et al., 1994) and the causative genetic mutation was identified as the microtubule protein-associated tau (*MAPT*) (Clark et al., 1998; Hutton et al., 1998; Poorkaj et al., 1998; Spillantini et al., 1998), which plays a role in microtubule stabilization and assembly. In 2006, the second autosomal dominant mutation for FTD was identified as *GRN*, a mere 6.2 MB away from *MAPT* (Baker et al., 2006). *GRN* encodes for progranulin, a protein that is ubiquitously expressed and involved in wound repair, inflammation and lysosomal function (Kao et al., 2017; Petkau and Leavitt, 2014).

For ALS, the first autosomal dominant mutation was discovered in a cytosolic, Cu/Zn-binding superoxide dismutase (*SOD1*). Although the clinical overlap between FTD and ALS syndromes had been noted as early as the 1980s, the discovery of rare genetic mutations such as *CHMP2B* (Gydesen et al., 2002), *TARDBP* (Sreedharan et al., 2008), *FUS* (Kwiatkowski et al., 2009; Sreedharan et al., 2008), and *VCP* (Johnson et al., 2010) that cause either FTD, ALS or both syndromes united these two syndromes based on their underlying pathobiology. In 2011, a hexanucleotide expansion in the *C9orf72* gene was discovered as the most common cause of familial and FTD and ALS (DeJesus-Hernandez et al., 2011; Renton et al., 2011). For ALS, the *C9orf72* expansion and *SOD1* mutations account for the majority of familial ALS in Caucasian populations, causing 30 to 40 percent and 15 to 20 percent of cases, respectively (Renton et al., 2014). Since the discovery of the *C9orf72* expansion, other rare mutations that cause either FTD and/or ALS have been identified, including *SQSTM1* (Fecto, 2011), *CHCHD10* (Bannwarth et al., 2014), and *TBK1* (Cirulli et al., 2015; Freischmidt et al., 2015).

3.2 Genetic FTD

3.2.1 *MAPT*—*MAPT* mutations typically cause bvFTD with or without parkinsonism. Some patients with parkinsonism meet criteria for progressive supranuclear palsy (PSP) or corticobasal syndrome (CBS) (Ghetti et al., 2011). Less commonly, *MAPT* mutations have been identified in patients with primary progressive aphasia (PPA) (Munoz et al., 2007; Rohrer et al., 2009b) and, rarely, ALS (Karch et al., 2018; Origone et al., 2018). Over 50 pathogenic mutations in *MAPT* have been described (Greaves and Rohrer, 2019), yet the rarity of *MAPT* mutations in the population and clinical heterogeneity found even within families carrying the same *MAPT* mutation (Janssen et al., 2002; van Herpen et al., 2003; Van Swieten et al., 1999) has made it challenging to ascertain genotype-phenotype correlations. Nevertheless, mutations that do not affect the splicing of exon 10 are typically associated with the bvFTD phenotype, while mutations that affect exon 10 splicing and increase the ratio of four repeat (4R) tau to three repeat (3R) tau most frequently cause bvFTD with PSP or parkinsonism (Delisle et al., 1999; Iijima et al., 1999; Skoglund et al., 2008).

Structural neuroimaging: Due to the rarity of *MAPT* mutations, most neuroimaging studies have examined *MAPT*-FTD cohorts with a mixture of mutation subtypes. *MAPT*-related neuroimaging studies are summarized in Supplementary Table S1. In general, *MAPT*-FTD features frontotemporal atrophy similar to sporadic disease, yet atrophy is typically relatively symmetric and most prominent within anterior and mesial temporal lobes, while involvement of orbitofrontal, lateral prefrontal, and parietal regions is less consistent (Fig. 4; Beck et al., 2008; Boeve, 2005; Cash et al., 2018; Deters et al., 2014; Fumagalli et al., 2018; Olney et al., 2020; Rohrer et al., 2010, 2011a; Whitwell et al., 2009a, 2009b, 2012). A distinctive feature of *MAPT*-FTD is pronounced mesial temporal lobe atrophy (Deters et al., 2014; Olney et al., 2020; Rohrer et al., 2010; Whitwell et al., 2009a), associated with correspondingly greater memory impairment than seen in sporadic bvFTD (Rascovsky et al., 2011; Rohrer and Warren, 2011; Ygland et al., 2018). Longitudinal studies suggest that atrophy progresses symmetrically within the regions atrophied at baseline, namely the anteromedial temporal lobes and orbitofrontal cortex (Rohrer et al., 2010; Whitwell et al., 2015). Different *MAPT* mutation subtypes may be associated with distinct atrophy patterns (Ghetti et al., 2015; Whitwell et al., 2009a), yet it remains unknown whether *MAPT* mutations that share pathophysiological mechanisms selectively target specific neuroanatomical regions.

Early studies with smaller cohorts suggested that presymptomatic *MAPT* mutation carriers may lack gray matter volume differences (Dopper et al., 2014; Whitwell et al., 2011). In contrast, studies with larger cohorts have shown that presymptomatic carriers have subtle gray matter deficits (Cash et al., 2018; Domínguez-Vivero et al., 2020; Fumagalli et al., 2018; Panman et al., 2019; Rohrer et al., 2015) in temporal lobe, cingulate and lingual cortices (Domínguez-Vivero et al., 2020) as well as hippocampi and amygdala (Rohrer et al., 2015). These mixed results across studies could be attributable to differences in cohort size or subject heterogeneity with respect to actual time from symptom onset. Yet, even in presymptomatic carriers with no gray matter deficits at baseline, greater longitudinal temporal lobe (Chen et al., 2019b) and hippocampal (Panman et al., 2019) grey matter volume decline compared to noncarriers has been reported. In 5 presymptomatic carriers converting to bvFTD, declines in frontal and temporal volume appeared around 2 years before symptom onset (Jiskoot et al., 2019). These studies suggest that the characteristic mesial temporal atrophy of *MAPT* mutations may also be detectable in presymptomatic carriers, but further studies are needed to determine this relationship.

Cross-sectional and longitudinal DTI studies have revealed that in *MAPT*-FTD the most prominent white matter deficits appear within entorhinal white matter, limbic tracts, and frontotemporal tracts such as the left uncinate fasciculus (Chen et al., 2019a; Jiskoot et al., 2018; Mahoney et al., 2015, 2014). Similarly, reduced white matter integrity arises in presymptomatic carriers principally within frontotemporal tracts such as the uncinate fasciculus and parahippocampal cingulum bundle (Chen et al., 2019a; Dopper et al., 2014; Jiskoot et al., 2018; Panman et al., 2019; Rohrer et al., 2015). White matter deficits are estimated to appear as early as 20–30 years before estimated onset and may predate low gray matter volume change during the presymptomatic phase (Dopper et al., 2014; Greaves and Rohrer, 2019; Jiskoot et al., 2018).

Functional and molecular neuroimaging: Studies have probed the question of whether brain function as measured by task-free fMRI, [¹⁸F]FDG-PET, and ¹H MRS may be more sensitive to early-stage or preclinical deficits. One task-free fMRI connectivity study of 9 presymptomatic *MAPT* mutation carriers showed no network connectivity alterations (Dopper et al., 2014), while another study of 8 carriers showed regions with increased and decreased default mode network connectivity compared to noncarriers (Whitwell et al., 2011). Both of these studies had small cohorts of *MAPT* carriers which may account for disparate results. Compared to healthy controls, patients with *MAPT*-FTD have reduced [¹⁸F]FDG uptake (Deters et al., 2014) or hypoperfusion (Seelaar et al., 2011) in frontal, temporal, and parietal lobes. Presymptomatic metabolic changes have been elusive with studies reporting either negative findings (Dopper et al., 2016; Mutsaerts et al., 2019) or hypometabolism in a medial temporal ROI (Deters et al., 2014). The disparate results may suggest that hypometabolism is not a prominent early imaging finding across all carriers or *MAPT* mutational variants, but hypometabolism has been found in two presymptomatic carriers known to have converted soon after imaging (Arvanitakis et al., 2007; Dopper et al., 2016).

Tau PET tracers such as [¹⁸F]AV 1451 and [¹¹C]PBB3 have been less promising in FTD, since off-target binding has led to false-positive tau positivity in subjects who are unlikely to harbor tau neuropathology (Tsai et al., 2019; Wang and Edison, 2019). [¹⁸F]AV-1451, however, has shown strong binding to neurofibrillary tangles matching the pattern of paired helical filament (PHF) immunochemistry in a subset of *MAPT* mutations such as V337M and R406W (Jones et al., 2018; Smith et al., 2016; Tsai et al., 2019). Other PET studies have reported high levels of microglial activation in *MAPT*-FTD postmortem (Lant et al., 2014) and dopaminergic dysfunction and glial activation in presymptomatic carriers (Bevan-Jones et al., 2019; Miyoshi et al., 2010; Wu et al., 2018). In ¹H MRS, patients with *MAPT*-FTD show abnormalities in the posterior cingulate and medial frontal cortex, such as decreased NAA/Cr and increased ml/Cr ratios in line with neuronal dysfunction and inflammation, respectively (Chen et al., 2019c; Kantarci et al., 2010), with abnormalities in medial frontal regions observed even presymptomatically (Chen et al., 2019d). In contrast, the posterior cingulate has increases in ml/Cr but normal NAA/Cr, which may reflect a period of reactive astrocytosis in *MAPT*-related degeneration (Chen et al., 2019d; Kantarci et al., 2010).

3.2.2 GRN—Mutations in the *GRN* gene cause missense and premature termination codons in *GRN* mRNA that are degraded by nonsense-mediated decay, which results in a haploinsufficiency of progranulin protein (Baker et al., 2006; Cruts et al., 2006), most commonly leading to bvFTD and less frequently PPA, CBS or an Alzheimer's-like amnesic syndrome (Le Ber et al., 2008). FTD-ALS has been reported infrequently in association with *GRN* mutations, and pure ALS is rare (Chen-Plotkin et al., 2011; Yu et al., 2010). Interestingly, *GRN* mutation carriers show the most clinical heterogeneity among the common FTD mutations, despite the fact that the 79 *GRN* mutations identified to date all cause a haploinsufficiency of progranulin which has been hypothesized to be the underlying cause of neurodegeneration. *GRN* mutation carriers also show incomplete disease penetrance, with 90% of carriers becoming symptomatic by age 70 (Cruts et al., 2006). TDP-43 type A neuropathology is most commonly found at autopsy (Beck et al., 2008;

Mackenzie et al., 2006), yet the mechanisms by which progranulin deficiency lead to TDP pathology remain unknown.

Structural neuroimaging: *GRN*-related neuroimaging findings are summarized in Supplementary Table S2. Patients with FTD due to *GRN* mutations may have markedly asymmetric cortical atrophy that involves frontotemporal but also parietal cortices (Fig. 4; Beck et al., 2008; Borroni et al., 2012; Bozzali et al., 2013; Cash et al., 2018; Fumagalli et al., 2018; Le Ber et al., 2008; Olm et al., 2018; Premi et al., 2016; Rohrer et al., 2010; Whitwell et al., 2015, 2012, 2009b, 2007a). Longitudinal studies suggest that atrophy in most brain regions is faster in FTD due to *GRN* mutations than atrophy in *MAPT* mutations and the *C9orf72* expansion (Whitwell et al., 2015). After symptom onset, atrophy accelerates particularly in the temporal cortex (Chen et al., 2020) and grows more asymmetrical in the later stages of disease (Rohrer et al., 2010)

Many studies using voxel-based morphometry or cortical thickness measurements in presymptomatic *GRN* mutation carriers have found no detectable abnormalities in gray matter (Borroni et al., 2012, 2008; Fumagalli et al., 2018; Jacova et al., 2013; Lee et al., 2019; Moreno et al., 2013; Panman et al., 2019; Popuri et al., 2018). Other studies of presymptomatic carriers have identified low cortical grey matter volume (Cash et al., 2018; Cruchaga et al., 2009; Dopfer et al., 2014; Olm et al., 2018; Olney et al., 2020; Rohrer et al., 2015), thickness (Pievani et al., 2014), and morphological abnormalities (Gazzina et al., 2018). Three longitudinal studies in presymptomatic carriers show converging evidence of volumetric loss in frontal cortex, though in contrast to studies of symptomatic carriers, insular, temporal and parietal involvement is less consistent (Caroppo et al., 2015b; Chen et al., 2020; Olm et al., 2018). In general, the studies that report low gray matter volume analyzed larger subject cohorts, suggesting that gray matter deficits may be detectable, yet subtle during the presymptomatic stage. Overall, the literature suggests that presymptomatic carriers may have targeted regions of gray matter deficits, but when present, these are mild. The mixed results across these studies may be attributable to heterogeneity across study cohorts with respect to subjects' age of future symptom onset and clinical syndrome or targeted neuroanatomy.

White matter hyperintensities are uncommon in FTD, yet several studies have reported white matter hyperintensities in some patients with *GRN*-FTD (Ameur et al., 2016; Caroppo et al., 2014; Le Ber et al., 2008; Paternicò et al., 2016; Sudre et al., 2017). Recent studies have revealed an association between longitudinal accumulation of white matter hyperintensities and atrophy and executive deficits in patients with *GRN*-FTD (Sudre et al., 2019) and also found white matter hyperintensities in presymptomatic carriers (Benussi et al., 2019; Sudre et al., 2019). A report of a patient with *GRN*-FTD with severe white matter hyperintensities showed that white matter disease on MRI scans (*in vivo* and cadaveric) corresponded to prominent microglial activation and microglial dystrophy at autopsy, but only mild axonal loss and minimal vascular pathology, supporting the notion that white matter hyperintensities in *GRN*-FTD are not due to small vessel cerebrovascular disease (Woollacott et al., 2018).

DTI studies show that white matter tracts such as the inferior longitudinal and uncinate fasciculi, anterior corpus callosum, and the long intrahemispheric association tracts have reduced integrity in *GRN*-FTD (Bozzali et al., 2013; Premi et al., 2016; Rohrer et al., 2010). Across various cross-sectional DTI studies, presymptomatic *GRN* mutation carriers also show diminished white matter integrity within tracts affected during the symptomatic phase. These tracts include the superior longitudinal and uncinate fasciculi, the corticospinal tract, and anterior corpus callosum (Borroni et al., 2008; Dopfer et al., 2014; Jiskoot et al., 2018; Olm et al., 2018; Pievani et al., 2014). Differences in white matter integrity have been proposed to develop 10 years before symptom onset (Jiskoot et al., 2018). Longitudinal DTI studies in presymptomatic carriers have been mixed, either showing no change (Panman et al., 2019) or a greater annualized FA reduction in the right superior longitudinal fasciculus and frontal corpus callosum (Olm et al., 2018). One possible explanation is that differences across studies could be attributable to subject heterogeneity, and subjects either farther from or closer to symptom onset could be driving the overall group result in each study.

Functional and molecular neuroimaging: The first studies that identified task-free fMRI connectivity alterations in presymptomatic FTD mutation carriers explored salience and default mode networks, which show prominent alterations in patients with sporadic FTD. For the salience network, a region of reduced connectivity was found in the midcingulate cortex in 9 presymptomatic *GRN* mutation carriers (Borroni et al., 2012), while another study of 28 presymptomatic *GRN* mutation carriers revealed connectivity disruption of an anterior midcingulate seed region and parietal regions including precuneus, posterior cingulate, and lateral parietal cortex (Dopfer et al., 2014). Neither of these studies showed default mode network differences in presymptomatic carriers compared to controls. A study of 5 carriers showed no differences within functional networks (Pievani et al., 2014), suggesting that the differences across studies are due to different sample sizes, methodological differences, and/or subject heterogeneity. Recently, Lee et al. (2019) showed that presymptomatic carriers have hyperconnectivity within the four networks that correspond to the most common clinical syndromes reported during the symptomatic stage of *GRN*, which included salience network for bvFTD, nfvPPA and CBS networks, and the default mode network for AD. For each four networks, hyperconnectivity converged in the thalamus, paralleling the finding in *GRN*^{-/-} mice that the thalamus is a key region implicated in *GRN* pathobiology (Lui et al., 2016).

In addition to these studies examining seed-based and ICA-derived connectivity network alterations, presymptomatic carriers and patients with FTD due to *GRN* mutations have shown alterations in measures of local connectivity (Premi et al., 2014). Another study compared the ability of various imaging modalities such as gray and white matter volume loss, ICA-derived connectivity networks (salience, frontoparietal, dorsal attentional, executive, and default mode), and local connectivity measures to classify *GRN*-FTD and presymptomatic *GRN* versus controls (Premi et al., 2016). Overall, reduced gray matter volume was able to best distinguish patients with *GRN*-FTD from controls, while decreases in local fMRI connectivity (fractional amplitude of low frequency fluctuations) in frontoparietal cortex and increases in local connectivity in prefrontal areas most accurately distinguished presymptomatic carriers from controls. Early involvement of the prefrontal

cortex in *GRN* related disease is also supported by task-based fMRI studies (Alexander et al., 2018; Cruchaga et al., 2009).

Metabolic imaging by [¹⁸F]FDG-PET and arterial spin labeling (ASL) MRI have revealed frontotemporal hypometabolism and hypoperfusion in *GRN* mutation carriers, even in presymptomatic carriers that show no significant differences in brain volume. Patients with *GRN*-FTD have [¹⁸F]FDG-PET hypometabolism in frontotemporal and parietal cortices, corresponding to regional atrophy patterns seen in structural imaging (Cruchaga et al., 2009; Huey et al., 2006). Similar to symptomatic carriers, group studies of presymptomatic carriers show discrete regions of hypometabolism appear in right anterior cingulate, insula and orbitofrontal cortex (Jacova et al., 2013), left lateral temporal lobe (Caroppo et al., 2015b), and frontal, parietal, and hippocampal regions (Le Ber et al., 2008). Longitudinally, more pronounced hypometabolism has been found within regions of lateral temporal and frontal cortex (Caroppo et al., 2015b). For ASL, presymptomatic *GRN* mutation carriers have shown hypoperfusion cross-sectionally in frontoparietal cortex, and longitudinally in frontal, temporal, parietal, and subcortical regions (Dopper et al., 2016). Across studies, metabolic changes are estimated to emerge 7–25 years before symptom onset (Alexander et al., 2019; Caroppo et al., 2015b; Jacova et al., 2013).

GRN-FTD is typically associated with TDP-43 type A pathology. While there is no molecular imaging available for TDP to date, Alzheimer's co-pathology has been described in *GRN* mutation carriers (Perry et al., 2013). Consistent with this report, *GRN*-FTD shows amyloid beta accumulation as measured by [¹¹C]PiB-PET more frequently than seen in sporadic disease and *MAPT* and *C9orf72* expansion carriers (Tan et al., 2017).

The hexanucleotide expansion in *C9orf72* is the most common cause of genetic FTD and ALS and neuroimaging studies are discussed in section 3.4.1 below.

3.3 Genetic ALS

3.3.1 SOD1—To date, more than 180 mutations in superoxide dismutase (*SOD1*) have been identified. Superoxide dismutase is an abundant enzyme ubiquitously expressed in the body and its main function is to bind copper and zinc to eliminate toxic superoxide radicals that cause oxidative stress. While it remains unknown how *SOD1* mutations lead to ALS, the mutations cause a toxic gain of function (Rothstein, 2009). The neuropathological hallmark of *SOD1*-ALS is the deposition of misfolded *SOD1* protein inclusions in motor neurons (Saber et al., 2015), and curiously, the TDP-43 pathology that is characteristic of sporadic ALS is absent (Mackenzie et al., 2007). Co-occurrence of FTD in *SOD1*-ALS is rare (Millecamps et al., 2012) but cognitive impairment, principally executive dysfunction, is seen in *SOD1*-ALS as in sporadic ALS (Agosta et al., 2018). *SOD1* variants show phenotypic heterogeneity. For example, D90A carriers have a markedly long disease duration ranging between 14–20 years in contrast to the 2–5 years typical of sporadic ALS (Andersen et al., 1996; Weber et al., 2000), while the A4V mutation is typically associated with death within a year of symptom onset (Aggarwal and Nicholson, 2005; Cudkovic et al., 1997).

SOD1-related neuroimaging studies are summarized in Supplementary Table S3. As in genetic FTD, most neuroimaging studies have investigated different *SOD1* mutations in a combined cohort, although some have focused exclusively on D90A homozygous recessive carriers. The earliest structural imaging studies focused on D90A *SOD1* mutation carriers with ALS and compared them to sporadic ALS. While both D90A *SOD1* and sporadic ALS have atrophy in motor and premotor cortex, D90A *SOD1*-ALS showed more prominent atrophy in anteromedial frontal cortex (Turner et al., 2007a). Patients with D90A *SOD1*-ALS show a lesser degree of corticospinal tract deficits than sporadic patients with similar disease severity (Blain et al., 2011; Stanton et al., 2009) as measured by DTI fractional anisotropy. PET imaging of GABAergic [¹¹C]flumazenil (Turner et al., 2005) and serotonergic [¹¹C]WAY100635 (Turner et al., 2007b) ligands have shown that both sporadic and D90A *SOD1*-ALS patients have reduced binding compared to controls. Interestingly, sporadic ALS had reduced binding of GABA in premotor and motor cortex and posterior motor association areas, while D90A *SOD1*-ALS was associated with lower binding in the left frontotemporal junction and anterior cingulate.

A multimodal imaging study with a larger cohort of 20 patients with *SOD1*-ALS, most of whom carried the L144F mutation, also found that *SOD1*-ALS showed distinct patterns of corticospinal tract and sensorimotor network functional connectivity compared with sporadic ALS despite no group differences on manual muscle testing (Agosta et al., 2018). Both sporadic ALS and *SOD1*-ALS showed decreased corticospinal tract white matter integrity compared to controls, but corticospinal tract integrity was more preserved in *SOD1*-ALS compared to sporadic ALS. Another DTI study, which included a wider range of *SOD1* mutations, did not find significant FA differences in the corticospinal tract and frontal and prefrontal tracts in *SOD1*-ALS patients compared to controls (Müller et al., 2020). Additionally, while sporadic ALS has been shown to be associated with alterations in sensorimotor network connectivity, Agosta et al. (2018) found that patients with *SOD1*-ALS had sensorimotor network connectivity similar to controls, but cervical cord atrophy greater than seen in sporadic disease. Overall, these DTI and task-free fMRI studies suggest that *SOD1*-ALS shows relatively spared motor networks and corticospinal tract integrity compared to sporadic disease, but with greater cervical cord atrophy which may be a distinguishing characteristic of *SOD1*-ALS. The relative sparing of motor networks may reflect the milder motor cortex and corticospinal tract involvement reported in certain patients with *SOD1*-ALS at autopsy when compared to sporadic ALS (Cudkovicz et al., 1998; Ince et al., 1998).

During the presymptomatic phase, *SOD1* carriers do not typically show structural brain deficits (Menke et al., 2016; Vucic et al., 2010), but one DTI study showed reduced integrity in the posterior limb of the internal capsule (Ng et al., 2008). Consistent with the notion that *SOD1*-ALS targets the cervical cord, presymptomatic *SOD1* carriers show in ¹H MRS reduced NAA/Cho and NAA/mIns ratios in the cervical spinal cord relative to healthy controls (Carew et al., 2011a). Echoing the finding that *SOD1*-ALS spares cortical motor networks, an fMRI functional connectivity study found no sensorimotor network alterations in presymptomatic *SOD1* carriers, although they showed increased precuneus-cingulate-middle frontal network connectivity as did the sporadic ALS patients in their study (Menke et al., 2016).

3.4 Mutations that cause either FTD or ALS, or both

The *C9orf72* expansion is the most common known genetic cause of FTD and ALS in people with Northern European ancestry. *CHMP2B*, *TARDBP*, *FUS*, *VCP*, *SQSTM1*, *TBK1*, *CHCHD10*, are all rare genes that may cause FTD or ALS.

3.4.1 C9orf72—Abnormal G₄C₂ hexanucleotide repeats in either the promoter region or the first intron of chromosome 9 open reading frame 72 (*C9orf72*) usually manifest as bvFTD, ALS, or both (DeJesus-Hernandez et al., 2011; Renton et al., 2011). Less commonly, *C9orf72* expansion carriers may have clinical phenotypes such as an Alzheimer's disease-like syndrome, a Huntington's disease-like syndrome, progressive muscular atrophy, or corticobasal or ataxic syndromes (Anor et al., 2015; Lesage et al., 2013; Lindquist et al., 2013; Liu et al., 2014). Although the function of the *C9orf72* protein remains unclear, three proposed pathophysiological mechanisms include haploinsufficiency of *C9orf72* protein, toxic gain-of-function due to the accumulation of aberrant RNA foci (DeJesus-Hernandez et al., 2011) and dipeptide repeat proteins both derived from the repeat expansion (Mori et al., 2013). Diverse neuropathological features have been described, but in addition to RNA foci and the dipeptide repeat proteins, TDP-43 type B pathology is most common at autopsy (Mackenzie et al., 2013; Murray et al., 2011; Snowden et al., 2012).

The age of onset in *C9orf72*-related FTD and ALS ranges widely between 30 to 90 years (Murphy et al., 2017). Similar to sporadic FTD, *C9orf72*-FTD has an average disease duration of 14 years (Kaivorinne et al., 2013), but with a subset of cases progressing considerably slower (Devenney et al., 2014; Gómez-Tortosa et al., 2014; Khan et al., 2012; Llamas-Velasco et al., 2018). *C9orf72*-ALS tends to progress more rapidly than sporadic and most other genetic ALS subtypes (Cooper-Knock et al., 2012; DeJesus-Hernandez et al., 2011; Millecamps et al., 2012). In FTD, the expansion is associated with an increased risk of psychosis, hallucinations, and parkinsonism (Cooper-Knock et al., 2012; Snowden et al., 2012). ALS patients with the *C9orf72* expansion have a three times higher frequency of cognitive impairment compared to those with sporadic ALS (Byrne et al., 2012; Smith et al., 2013). Factors such as the size of the repeat expansion, environmental influences, and disease-modifying genes have been speculative and are not clearly established (Chi et al., 2016).

Structural neuroimaging: Neuroimaging studies related to the *C9orf72* expansion are summarized in Supplementary Table S4. Similar to sporadic bvFTD, patients with bvFTD due to the *C9orf72* expansion have frontotemporal and insular atrophy that is often accompanied by parietal, occipital, thalamic, and cerebellar atrophy (Fig. 4; Boeve et al., 2012; Boxer et al., 2011; Cash et al., 2018; Irwin et al., 2013; Lee et al., 2014; Mahoney et al., 2012a; McMillan et al., 2015; Sha et al., 2012; Whitwell et al., 2012). Cortical atrophy is generally symmetric, and longitudinal changes are most apparent in core regions affected at baseline, such as frontotemporal cortex, thalamus and cerebellum (Boeve et al., 2012; Floeter et al., 2016; Le Blanc et al., 2020; Mahoney et al., 2012b; Whitwell et al., 2015). Individual patients have notable heterogeneity, at times exhibiting minimal atrophy (Boeve et al., 2012; Devenney et al., 2015, 2014; Solje et al., 2015) or a more posterior pattern with relatively spared frontal or temporal lobes (Boeve et al., 2012; Boxer et al., 2011; Sha et al.,

2012). *C9orf72* expansion carriers also show heterogeneity at the individual subject level with respect to which brain regions are most prominently targeted. For example, a recent data-driven modelling study suggested that *C9orf72*-FTD features two distinct subtypes of atrophy patterns, either predominantly frontotemporal atrophy or predominantly subcortical atrophy (Young et al., 2018).

C9orf72 expansion carriers with ALS or MND typically exhibit relatively symmetric volume loss and cortical thinning. *C9orf72*-ALS appears clinically similar to sporadic ALS, yet gray matter volume loss is pronounced in expansion carriers, particularly in frontotemporal and parieto-occipital cortex (Agosta et al., 2017; Bede et al., 2013b; Byrne et al., 2012; Floeter et al., 2016; van der Burgh et al., 2020; Westeneng et al., 2016) and in subcortical structures such as the thalamus, cerebellum, and hippocampi (Agosta et al., 2017; Bede et al., 2013c; Schönecker et al., 2018; van der Burgh et al., 2020; Westeneng et al., 2016). These cortical deficits correlate with the cognitive impairment in *C9orf72*-ALS (Bede et al., 2013b; Floeter et al., 2016). In parallel, frontotemporal and insular changes have been found to be associated with cognitive and behavioral impairments in sporadic ALS (Agosta et al., 2017, 2016; Christidi et al., 2018; Consonni et al., 2019; Tsujimoto et al., 2011; Westeneng et al., 2016). In addition to these cortical and subcortical volume differences, *C9orf72*-ALS do not have extensive cervical cord thinning compared to sporadic ALS (van der Burgh et al., 2019).

Patients with *C9orf72* with both FTD and ALS show a lesser degree of cortical atrophy compared with sporadic FTD-ALS (Omer et al., 2017) and a distinct pattern of subcortical atrophy mainly in thalamic nuclei connected to motor and sensory cortical areas (Bede et al., 2018). One hypothesis is that abnormalities in subcortical brain structures such as the thalamus and cerebellum may be a more robust imaging signature of the *C9orf72* expansion than cortical atrophy patterns (Mahoney et al., 2012b, 2012a). Low gray matter volume is detectable in presymptomatic *C9orf72* expansion carriers, generally within regions atrophied in *C9orf72*-bvFTD and *C9orf72*-ALS (Bertrand et al., 2018; Cash et al., 2018; De Vocht et al., 2020; Lee et al., 2017; Panman et al., 2019; Papma et al., 2017; Popuri et al., 2018; Rohrer et al., 2015; Walhout et al., 2015a). In particular, atrophy of the posterior thalamus correlates with disease severity in *C9orf72*-FTD and -ALS (Agosta et al., 2017; McMillan et al., 2015; Schönecker et al., 2018) and low gray matter in this region is apparent even in young presymptomatic carriers (Bertrand et al., 2018; Cash et al., 2018; Lee et al., 2017; Olney et al., 2020; Papma et al., 2017; Rohrer et al., 2015). Recent investigations focused on the involvement of individual thalamic nuclei in FTD-ALS have characterized pulvinar nucleus atrophy as unique to *C9orf72* expansion carriers with FTD (Bocchetta et al., 2020) but other thalamic nuclei have been associated with the *C9orf72* expansion with motor neuron disease (Chipika et al., 2020).

DTI studies reveal that white matter tracts are also disrupted in *C9orf72* expansion carriers. Studies of patients with *C9orf72*-bvFTD have revealed disruption of frontotemporal association tracts and corpus callosum similar to the white matter tracts affected in sporadic bvFTD (Mahoney et al., 2015, 2014). Both *C9orf72*-bvFTD and sporadic bvFTD show the greatest longitudinal decline in the paracallosal cingulum bundle (Mahoney et al., 2015). Patients with *C9orf72*-ALS/MND and varying degrees of cognitive impairment show motor

tract involvement similar to sporadic ALS, but also systematic involvement of frontotemporal tracts such as the uncinate fasciculus, superior longitudinal fasciculus, and inferior longitudinal fasciculus (Agosta et al., 2017; Bede et al., 2013b; Floeter et al., 2018; Müller et al., 2020; Omer et al., 2017; van der Burgh et al., 2019; Westeneng et al., 2016). Though gray matter atrophy patterns overlap in *C9orf72*-FTD and -ALS, white matter tract involvement may better reflect each phenotype than do volumetric deficits (Bertrand et al., 2018; Floeter et al., 2018; Querin et al., 2019). For example, a longitudinal DTI study on a cohort of *C9orf72* expansion carriers with different clinical diagnoses found that changes in cognitive-behavioral and motor symptom severity correlated with progressive deficits along the frontotemporal and corticospinal tracts, respectively, over a 6 month interval (Floeter et al., 2018).

In presymptomatic *C9orf72* expansion carriers, white matter deficits commonly appear in tracts connecting the frontal lobe, the thalamic radiation, and tracts associated with motor functioning (Bertrand et al., 2018; Jiskoot et al., 2018; Lee et al., 2017; Panman et al., 2019; Papma et al., 2017; Wen et al., 2018). Cross-sectionally, both gray and white matter deficits in presymptomatic carriers emerge early, up to 30 years before symptom onset (Jiskoot et al., 2018; Lee et al., 2017), and are present even in presymptomatic carriers younger than 40 years old (Bertrand et al., 2018; Le Blanc et al., 2020; Lee et al., 2017). These regions of low gray matter volume and reduced white matter integrity are generally congruent with regions of gray matter atrophy found during the symptomatic phase. In the cervical spinal cord, only presymptomatic carriers older than 40 years showed atrophy at each vertebral level, and corticospinal tract FA reductions were detectable at an 18 month follow up (Querin et al., 2019). Consistent with cross-sectional studies, a recent study of 137 carriers that included longitudinal data for a subset of subjects estimated that the thickness of the medial frontal and parietal cortex and scattered lateral frontal, parietal, and temporal regions begins to decline during the early thirties with no acceleration around the estimated age of symptom onset (Le Blanc et al., 2020). Longitudinal changes in grey matter volume (Floeter et al., 2016; Panman et al., 2019) and white matter integrity (Panman et al., 2019) have been elusive in presymptomatic cohorts thus far. Taken together, these studies point to gray and white matter deficits at an early age during the presymptomatic phase, suggesting that these abnormalities may represent neurodevelopmental differences in *C9orf72* expansion carriers (Bertrand et al., 2018; Lee et al., 2017).

Functional and molecular imaging: Although patients with *C9orf72*-bvFTD have a distinct, yet overlapping atrophy pattern compared to those with sporadic bvFTD, both converge on salience and sensorimotor network connectivity disruption, suggesting that ICN maps rather than atrophy patterns may better represent the clinical syndrome (Lee et al., 2014). Salience network connectivity disruption correlated with left medial pulvinar thalamic atrophy, suggesting that the medial pulvinar degeneration may contribute to the bvFTD syndrome in *C9orf72* by disrupting salience network connectivity. In contrast to sporadic bvFTD, which shows both default mode network connectivity increases and decreases, *C9orf72*-bvFTD shows default mode network connectivity similar to controls (Lee et al., 2014). A study comparing 7 *C9orf72*-bvFTD to those with sporadic disease described pronounced anti-correlation between thalamic nodes of the salience network and

the default mode network and also found connectivity increases within the right dorsal attention network (Rytty et al., 2014). A comparison between 19 *C9orf72*-MND and 24 sporadic MND with comparable cognitive deficits revealed that *C9orf72*-MND have sensorimotor network decreases but enhanced visual network connectivity (Agosta et al., 2017). During the presymptomatic stage, robust intrinsic connectivity network disruption is detectable in the salience, sensorimotor and default mode networks and to the medial pulvinar, and these anomalies are apparent as early as the third decade of life (Lee et al., 2017).

Metabolic imaging in patients with *C9orf72*-FTD typically reveals hypoperfusion and hypometabolism in the frontal and/or temporal lobes and limbic structures, in keeping with the clinical phenotype (Boeve et al., 2012; Castelnovo et al., 2019; Diehl-Schmid et al., 2019). Likely due to individual subject heterogeneity, a notable subset of patients with *C9orf72*-bvFTD lack hypometabolism in frontotemporal cortex or show at least a comparable degree of hypometabolism in the parietal lobe, thalamus, or cerebellum (Boeve et al., 2012; Devenney et al., 2014; Diehl-Schmid et al., 2019; Khan et al., 2012; Solje et al., 2015). Compared to sporadic bvFTD, *C9orf72*-bvFTD show pronounced focal hypometabolism in bilateral thalami (Diehl-Schmid et al., 2019). In *C9orf72*-ALS, metabolic signatures are more variable (Castelnovo et al., 2019). Group studies in patients with ALS suggest, however, that the expansion is associated with pronounced [¹⁸F]FDG-PET hypometabolism in thalamus and posterior cingulate (Cistaro et al., 2014; Van Laere et al., 2014; Verschueren et al., 2013) and hypermetabolism in midbrain and occipital and inferior temporal cortices (Cistaro et al., 2014). Metabolic abnormalities also occur in presymptomatic *C9orf72* expansion carriers (De Vocht et al., 2020; Mutsaerts et al., 2019; Westeneng et al., 2017). Mutsaerts et al. (2019) estimated that insular, temporal, and parietal hypoperfusion emerges early, at least 12 years from estimated symptom onset. De Vocht et al. (2020) identified [¹⁸F]FDG-PET hypometabolism in the insular cortices, central opercular cortex, and thalami in 82% of presymptomatic participants studied, whereas abnormally low gray matter volume and elevated neurofilament light levels (a marker of axonal injury) were less frequently observed (62% and 19%, respectively).

3.5 Rare genetic mutations that cause either FTD or ALS

In recent years, genome-wide association studies have revealed a range of causal and risk variants for FTD and ALS. While rare genes such as *CHMP2B* and *TREM2* have been associated with FTD and *OPTN* has been associated with ALS, other genes including *TARDBP*, *DCTN1*, *FUS*, *VCP*, *UBQLN2*, *SQSTM1*, *CHCHD10*, *TBK1*, *CCNF*, are associated with a heterogeneous array of disorders in the FTD-ALS spectrum. Below we review imaging findings for these rarer genetic FTD or ALS variants, including studies reporting visual assessment of structural MRI brain or [¹⁸F]FDG-PET scans in addition to quantitative neuroimaging studies.

3.5.1 CHMP2B—Charged multivesicular body protein 2B (CHMP2B) is expressed in multiple human tissues, including frontal and temporal lobes. CHMP2B protein is a component of the endosomal secretory complex required for transport III, and in cell culture, mutations in *CHMP2B* disrupt the protein's localization and results in the formation of

dysmorphic organelles of the late endosomal pathway (Skibinski et al., 2005). The pathology associated with *CHMP2B* mutations is poorly understood, with the FTLD UPS aggregates either representing an unknown disease-specific protein or a more general defect in endosomal trafficking and lysosomal protein degradation (Neumann and Mackenzie, 2019). *CHMP2B* mutations comprise less than 1% of FTD mutations, and have been described in large Danish and Belgian families (Gydesen et al., 2002; van der Zee et al., 2008), but are rare in other cohorts. Most *CHMP2B* mutation carriers develop bvFTD, although FTD-ALS and CBS and PSP syndromes have been reported (Isaacs et al., 2011). Dyscalculia, limb apraxia and dynamic aphasia have also been described (Gydesen et al., 2002).

Patients with bvFTD due to truncating *CHMP2B* mutations generally show atrophy and reduced cerebral blood flow in frontotemporal and sometimes parietal regions (Gydesen et al., 2002; Isaacs et al., 2011; Lindquist et al., 2008). In contrast to sporadic FTD, FTD due to *CHMP2B* mutations additionally involves parietal and posterior central regions, hypothesized to correspond to dyscalculia and limb apraxia, also unusual features of sporadic FTD (Gydesen et al., 2002; Isaacs et al., 2011). Both FTD and ALS have also been associated with missense *CHMP2B* mutations (Isaacs et al., 2011). Autopsy studies reveal that truncating and missense *CHMP2B* mutations have pathologically distinct features (Neumann and Mackenzie, 2019), but the associated imaging signatures of each type of mutation have not been systematically compared.

Group comparisons between presymptomatic carriers of truncating *CHMP2B* mutations and non-carrier family members have revealed focal atrophy in inferotemporal, superior frontal, and insular cortex (Eskildsen et al., 2009; Rohrer et al., 2009a). Presymptomatic *CHMP2B* carriers also show significantly decreased cerebral blood flow in occipital and parietal regions (Lunau et al., 2012).

3.5.2 TARDBP—TAR DNA-binding protein (TARDBP) is a nuclear protein involved with RNA processing and metabolism (Xia et al., 2016). During stress conditions, hyperphosphorylated, ubiquitinated and cleaved TDP-43 deposits aggregate in the cytoplasm. In addition to TDP pathology, other neuropathologies such as tau, amyloid and alpha-synuclein have been found in *TARDBP* mutation carriers (Gelipi et al., 2014; Kovacs et al., 2009; Moreno et al., 2015). *TARDBP* mutations account for 3% of familial ALS, but rarely cause dementia or parkinsonism (Lattante et al., 2013b), and account for less than 1% of patients with FTD (Caroppo et al., 2016). When *TARDBP* mutation carriers develop dementia, bvFTD is the most frequent syndrome, though both nonfluent and semantic PPA have been reported (Caroppo et al., 2016; Floris et al., 2015), and less than half develop motor neuron disease (Caroppo et al., 2016). Among the FTD syndromes, svPPA is usually sporadic and not genetic, yet patients with *TARDBP* mutations develop svPPA at a higher rate compared to patients with the *C9orf72* expansion and *MAPT* and *GRN* mutations (Caroppo et al., 2016).

Case series describe that patients with *TARDBP*-FTD have atrophy in frontotemporal and less commonly in parietal cortex, hippocampus, and amygdala (Caroppo et al., 2016; Cheng et al., 2016; Floris et al., 2015; Synofzik et al., 2014). Correspondingly, hypoperfusion and

hypometabolism has been observed in frontotemporal cortex and more rarely in parietal cortex and the caudate (Benajiba et al., 2009; Borroni et al., 2009; Caroppo et al., 2016; Cheng et al., 2016; Floris et al., 2015; Synofzik et al., 2014). As expected, those with the svPPA syndrome typically develop left-lateralized anterior temporal and sometimes frontal gray matter loss, hypoperfusion and hypometabolism (Benajiba et al., 2009; Caroppo et al., 2016; Cheng et al., 2016; Floris et al., 2015; Gelpi et al., 2014; González-Sánchez et al., 2018).

Most case reports on pure *TARDBP*-MND or -ALS have found no apparent imaging abnormalities upon visual inspection of brain or cervical cord MRI (Agosta et al., 2020; Cheng et al., 2016; Chiò et al., 2010; Del Bo et al., 2009), but individual imaging reports have described abnormalities such as frontotemporal hypometabolism in SPECT and [¹⁸F]FDG-PET (Borghero et al., 2011) and temporal atrophy (Del Bo et al., 2009). In *TARDBP*-ALS with concomitant FTD or behavioral deficits, cortical atrophy and metabolic changes appear common within frontal and/or temporal lobes and less often involve parietal and anterior cingulate cortex and the head of the caudate (Cheng et al., 2016; Chiò et al., 2010).

3.5.3 FUS—*FUS* encodes the fused in sarcoma protein, an RNA-binding protein involved in cell proliferation, DNA repair, transcription regulation, and RNA splicing and transport (Deleon and Miller, 2018). ALS patients with *FUS* mutations show aggregated FUS protein in the cytoplasm. Interestingly, no patient with FTLT with FUS neuropathology has yet been identified to carry a *FUS* mutation (Neumann and Mackenzie, 2019).

Studies in patients with FTD or FTD-ALS with *FUS* mutations have reported frontal, temporal and parietal atrophy and hypometabolism (Akiyama et al., 2016; Blair et al., 2010; Broustal et al., 2010; Huey et al., 2012). Individual case reports on *FUS*-ALS generally describe normal brain imaging (Blair et al., 2010; Chiò et al., 2009; Rademakers et al., 2010; Zhou et al., 2020), although other reports have described instances of individual patients with cortical and cerebellar atrophy (Yan et al., 2010), nonspecific scattered white matter changes (Wongworawat et al., 2020), and decreases in cerebral blood flow in the right striatum, thalamus, and frontotemporal lobe (Tateishi et al., 2010).

3.5.4 OPTN—The *OPTN* gene encodes optineurin, a multifunctional protein involved in protein degradation via autophagy. *OPTN* mutations are associated with ALS, primary open-angle glaucoma (Rezaie, 2002), and Paget's disease of bone (Albagha et al., 2010). *OPTN* mutations have been reported in 1–2 % of familial ALS and up to 3.5 % of sporadic cases (Belzil et al., 2011; Del Bo et al., 2011). While *OPTN* mutations are rarely found in patients with FTD, they are not considered causative of FTD (Pottier et al., 2015). Imaging reports on patients with *OPTN*-ALS have reported atrophy in frontal, temporal and motor cortices (Feng et al., 2019; Ito et al., 2011; Kamada et al., 2014; Ueno et al., 2011) as well as brainstem and cerebellum (Ueno et al., 2011).

3.5.5 VCP—The valosin-containing protein (*VCP*) gene is involved with various cellular activities, and pathological mutations are hypothesized to disrupt its role in protein degradation (Watts et al., 2004; Wehl et al., 2009). *VCP* mutations are associated with a

disease characterized by inclusion body myopathy, Paget's disease of bone, early onset FTD (IBMPFD) (Taylor, 2015; Watts et al., 2004) and other clinical syndromes including ALS (Johnson et al., 2010). The FTD phenotype develops in about one third of *VCP* mutation carriers, whereas ALS is rarer (Abramzon et al., 2012; Al-Obeidi et al., 2018; Johnson et al., 2010; Kimonis and Watts, 2005; Koppers et al., 2012).

Imaging reports on *VCP*-FTD range from having no apparent atrophy to focal frontotemporal or diffuse cortical and subcortical atrophy (Djamshidian et al., 2009; Kimonis et al., 2008; Kovach et al., 2001; Saracino et al., 2018; van der Zee et al., 2009). Rare reports also describe hippocampal or parietal atrophy (Fanganiello et al., 2011; Kim et al., 2011; Rohrer et al., 2011b). [¹⁸F]FDG-PET typically shows predominantly frontotemporal hypometabolism with parietal and cerebellar involvement in patients with *VCP*-FTD (Kim et al., 2011; Rohrer et al., 2011b; van der Zee et al., 2009; Viassolo et al., 2008). Compared to sporadic svPPA, patients with *VCP*-svPPA have more extensive frontal (Krause et al., 2007) or posterolateral temporal and parietal cortical atrophy (Kim et al., 2011), and curiously, the anterior temporal lobe is relatively spared. *VCP*-FTD and *VCP*-ALS have been suggested to share a focal atrophy in the temporal lobes and hippocampi (Hirano et al., 2017, 2015).

3.5.6 UBQLN2—The ubiquilin-2 (*UBQLN2*) gene encodes for a protein involved in proteasomal degradation (Deng et al., 2011; Hjerpe et al., 2016). *UBQLN2* mutations have been associated with juvenile and adult onset ALS (Daoud et al., 2012; Deng et al., 2011; Gellera et al., 2013) and more rarely with FTD, FTD-ALS, and PSP (Synofzik et al., 2012; Vengoechea et al., 2013). Imaging reports in two *UBQLN2*-related FTD cases described bilateral frontotemporal atrophy and hypometabolism (Leger et al., 2017; Synofzik et al., 2012), whereas findings in *UBQLN2*-ALS with cognitive impairment have ranged from a lack of apparent atrophy (Kotan et al., 2016) to diffuse atrophy patterns in a family with heterogeneous clinical presentations (Fahed et al., 2014).

3.5.7 SQSTM1—The sequestome 1 (*SQSTM1*) gene encodes for p62, a multi-functional protein that targets specific cargoes for autophagy (Rea et al., 2014). *SQSTM1* mutations are associated with Paget's disease of bone (Goode and Layfield, 2010), FTD (Rubino et al., 2012) and ALS (Fecto, 2011; Yilmaz et al., 2020). In FTD and ALS cohorts, the mutation frequency of *SQSTM1* is estimated to be 1–3% and *SQSTM1* mutations are associated with TDP-43 neuropathology (Fecto, 2011; Le Ber, 2013; Rubino et al., 2012; van der Zee et al., 2014).

Imaging findings of individual patients with *SQSTM1*-bvFTD suggest atrophy and hypometabolism predominantly in frontotemporal and cingulate cortices, putamen, and basal ganglia, often more pronounced in one hemisphere (Kovacs et al., 2016; Le Ber, 2013; Rubino et al., 2012; Sun et al., 2018). Compared to sporadic FTD, ten patients with *SQSTM1*-FTD showed pronounced atrophy in inferior and medial orbitofrontal cortex, anterior insula, and precentral gyri (Luis et al., 2016). Brain imaging signatures in *SQSTM1*-ALS have not yet been systematically investigated.

3.5.8 TREM2—*TREM2* (triggering receptor expressed on myeloid cells 2) encodes a receptor exclusively expressed in immune cells, and is thought to interfere with anti-inflammatory function and the removal of apoptotic tissue (Giraldo et al., 2013). *TREM2* mutations were first detected in Nasu-Hakola disease, which manifests as recurrent bone fractures and early-onset dementia (Paloneva et al., 2002). Since then, *TREM2* variants have been identified to cause familial FTD and to increase risk of AD and FTD without bone involvement (Borroni et al., 2014; Giraldo et al., 2013; Guerreiro et al., 2013; Lattante et al., 2013a; Le Ber et al., 2014). Parkinsonism is common in *TREM2* mutation carriers, but genetic association studies do not support an association with ALS (Rayaprolu et al., 2013). Characteristic neuroimaging features in Nasu-Hakola disease include atrophy and white matter abnormalities most prominent in frontal cortices along with calcifications of the basal ganglia (Klünemann et al., 2005). Mild hypoperfusion in basal ganglia has also been reported in two preclinical *TREM2* carriers (Montalbetti et al., 2005). *TREM2* carriers with a pure FTD diagnosis exhibit frontal and/or temporal atrophy with parietal and hippocampal involvement along with extensive white matter lesions and reduced thickness of the corpus callosum (Giraldo et al., 2013; Guerreiro et al., 2013; Le Ber et al., 2014).

3.5.9 CHCHD10—*CHCHD10* encodes for coiled-coil-helix-coiled-coil-helix domain containing protein 10, a mitochondrial protein located in the intermembrane space and enriched at cristae junctions (Bannwarth et al., 2014). Mutations in *CHCHD10* cause structural abnormalities of mitochondria leading to fragmentation and suggest a role for mitochondrial dysfunction in FTD-ALS. The first report of a family with a *CHCHD10* mutation revealed clinical heterogeneity within the family and included features such as motor neuron disease, cerebellar ataxia, frontal cognitive and behavioral changes, parkinsonism, and mitochondrial myopathy (Bannwarth et al., 2014). Subsequent reports have described other clinical phenotypes including pure ALS and pure FTD, mitochondrial myopathy, and spinal motor neuronopathy (Ajroud-Driss et al., 2015; Dols-Icardo et al., 2015; Jiao et al., 2016; Penttilä et al., 2015; Zhang et al., 2015). Based on mutation frequencies in ethnically matched FTD and ALS cohorts, *CHCHD10* mutations appear to be more frequently associated with FTD phenotypes than with pure ALS (Chausseot et al., 2014; Jiao et al., 2016; Marroquin et al., 2016; Teyssou et al., 2016; Wong et al., 2015). Disease progression in *CHCHD10*-related FTD and MND/ALS can be markedly slow, lasting up to 40 years (Bannwarth et al., 2014; Müller et al., 2014; Zhang et al., 2015).

Neuroimaging in patients with *CHCHD10*-related FTD and ALS with cognitive impairment generally shows atrophy or [¹⁸F]FDG-PET hypometabolism in frontal regions, and insular, temporal, parietal and cerebellar involvement have also been described (Bannwarth et al., 2014; Chausseot et al., 2014; Dols-Icardo et al., 2015; Zhang et al., 2015). Structural MRI scans of *CHCHD10* mutation carriers with a pure MND/ALS phenotype, however, have not shown apparent abnormalities upon visual inspection (Bannwarth et al., 2014; Müller et al., 2014; Ronchi et al., 2015).

3.5.10 TBK1—The tumor necrosis factor receptor-associated factor NF- κ B activator (TANK)-binding kinase 1 (*TBK1*) gene encodes for a protein that is active in autophagy and inflammatory signaling (Weidberg and Elazar, 2011). Clinically, *TBK1* loss-of-function

mutations manifest as bvFTD, PPA, and ALS and are associated with TDP-43 type B pathology (Freischmidt et al., 2015; Gijssels et al., 2015). Movement disorders such as PSP and cerebellar syndromes have also been reported (Wilke et al., 2018). It is estimated that over half of carriers develop a pure ALS phenotype and less than fifth develop FTD or a mixed phenotype, yet cognitive impairment is among the most common initial symptoms and found in up to half of *TBK1* carriers (Freischmidt et al., 2015; Yu et al., 2019). In addition to bvFTD-ALS, patients with *TBK1* may develop svPPA-ALS and nfvPPA-ALS (Caroppo et al., 2015a).

Imaging reports of *TBK1*-FTD show asymmetrical atrophy and hypometabolism in frontal and/or temporal lobes, reflecting the clinical phenotype (Caroppo et al., 2015a; Hirsch-Reinshagen et al., 2019; Koriath et al., 2017; Lamb et al., 2019; Pottier et al., 2015; Van Mossevelde et al., 2016; Yu et al., 2019). In the majority of *TBK1*-FTD patients, hypometabolism extends to parietal regions (Hirsch-Reinshagen et al., 2019; Koriath et al., 2017; Schönecker et al., 2016; Van Mossevelde et al., 2016), though parietal symptoms are not common. The few reports with imaging on pure ALS and FTD-ALS due to *TBK1* mutations have described variable vulnerable brain regions, but involvement of temporal cortex, hippocampi, and cerebellum appear common across various reports (Jiao et al., 2018; McCombe et al., 2018; Tohnai et al., 2018; Van Mossevelde et al., 2016).

4 DISCUSSION

Literature overview

Taken together, neuroimaging studies of genetic FTD and ALS suggest that each genetic mutation shows a distinct pattern of targeted neuroanatomy that overlaps with the focal degeneration seen in the sporadic forms of these diseases. Because clinical trials for disease-modifying treatments have failed in symptomatic patients thus far, an ongoing hypothesis in the field of neurodegenerative diseases is that treatments may only be effective prior to profound neurodegeneration and may need to be administered during the presymptomatic phase. Numerous studies spanning various imaging modalities have revealed abnormalities in presymptomatic genetic mutation carriers for FTD and ALS, which generally converge within anatomical regions affected during the symptomatic stage. These studies suggest that abnormalities in functional connectivity networks, brain metabolism, gray matter volume and white matter integrity are detectable prior to the onset of profound neurodegeneration.

Clinical application of neuroimaging findings

As mentioned in the sections describing sporadic FTD and ALS, the clinical diagnostic criteria for bvFTD and PPA incorporate neuroimaging findings such as atrophy patterns on structural MRI or regions of hypometabolism on PET as supportive criteria. For ALS, neuroimaging is currently used only to exclude other conditions that may mimic ALS. In our opinion, the literature supports the idea that certain imaging features that may increase the clinician's suspicion of genetic FTD or ALS. Although the ultimate confirmation of genetic FTD or ALS is made by genetic testing and not with neuroimaging, the following neuroimaging features may raise the index of suspicion for a genetic etiology, perhaps even in people without a known family history. For FTD or ALS due to the *C9orf72* expansion,

structural and functional MRI studies suggest that subcortical structures, the thalamus in particular, are more likely to be involved compared to sporadic disease. Patients with bvFTD due to *MAPT* mutations often have early memory impairment with corresponding focal mesial temporal involvement (atrophy or hypometabolism), both of which are not typical in sporadic bvFTD, *GRN* or *C9orf72*. Parietal lobe involvement has been reported in *C9orf72*, *GRN* and *TBK1* carriers, while sporadic bvFTD typically spares the parietal lobes. Patients with FTD due to *GRN* or *TBK1* mutations have been reported to have prominently asymmetric atrophy, most evident in the late stages of disease. Compared to sporadic ALS, more widespread frontotemporal involvement emerges in *C9orf72*-ALS, even in the absence of cognitive or behavioral symptoms, and many *SOD1* variants are associated with more prominent cervical spinal cord atrophy with relative sparing of cortical motor networks.

Limitations in the current literature and future directions

Thus far, many neuroimaging studies of genetic FTD and ALS have however been performed in relatively small cohorts in group analyses using cross-sectional data. In the past decade, international consortia for genetic FTD and ALS that collect harmonized multisite data have addressed this need for larger longitudinal cohorts. These longitudinal studies have begun building neuroimaging biomarker trajectories for different genetic mutations. For example, research on both genetic FTD and ALS suggests that patients with different mutations show differences in the order of involvement and rate of decline of specific brain structures (Jiskoot et al., 2019; Müller et al., 2020; Rohrer et al., 2015; van der Burgh et al., 2020; Whitwell et al., 2012; Young et al., 2018). Cross-sectional fMRI connectivity studies suggest that network connectivity may change dynamically throughout the lifespan in carriers of *GRN* (Borroni et al., 2012; Lee et al., 2019) or *SOD1* (Menke et al., 2016) mutations, or the *C9orf72* expansion (Agosta et al., 2017; Lee et al., 2017).

While these studies have been groundbreaking, group analyses are more vulnerable to individual subject heterogeneity and have limited ability to determine trajectories in individual patients. Assessing longitudinal trajectories at the individual-subject level will be necessary for developing neuroimaging as a biomarker for disease detection and monitoring.

Supplementary Material

Refer to Web version on PubMed Central for supplementary material.

ACKNOWLEDGEMENTS

This work was supported by NIH AG058233, Tau Consortium, Bluefield Project to Cure FTD, and the Päivikki and Sakari Sohlberg foundation. The authors alone are responsible for the content and writing of the paper.

REFERENCES

- Abidi M, de Marco G, Couillandre A, Feron M, Mseddi E, Termoz N, Querin G, Pradat P, Bede P, 2019 Adaptive functional reorganisation in amyotrophic lateral sclerosis: coexisting degenerative and compensatory changes. *Eur J Neurol*. doi:10.1111/ene.14042
- Abramzon Y, Johnson JO, Scholz SW, Taylor JP, Brunetti M, Calvo A, Mandrioli J, Benatar M, Mora G, Restagno G, Chiò A, Traynor BJ, 2012 Valosin-containing protein (VCP) mutations in sporadic

amyotrophic lateral sclerosis. *Neurobiol Aging* 33, 2231.e1–2231.e6. doi:10.1016/j.neurobiolaging.2012.04.005

- Aggarwal A, Nicholson G, 2005 Age-dependent penetrance of three different superoxide dismutase 1 (SOD1) mutations. *Int J Neurosci* 115, 1119–1130. doi:10.1080/00207450590914392 [PubMed: 16040355]
- Agosta F, Canu E, Valsasina P, Riva N, Prella A, Comi G, Filippi M, 2013 Divergent brain network connectivity in amyotrophic lateral sclerosis. *Neurobiol Aging* 34, 419–427. doi:10.1016/j.neurobiolaging.2012.04.015 [PubMed: 22608240]
- Agosta F, Ferraro PM, Riva N, Spinelli EG, Chiò A, Canu E, Valsasina P, Lunetta C, Iannaccone S, Copetti M, Prudente E, Comi G, Falini A, Filippi M, 2016 Structural brain correlates of cognitive and behavioral impairment in MND. *Hum Brain Mapp* 37, 1614–1626. doi:10.1002/hbm.23124 [PubMed: 26833930]
- Agosta F, Ferraro PM, Riva N, Spinelli EG, Domi T, Carrera P, Copetti M, Falzone Y, Ferrari M, Lunetta C, Comi G, Falini A, Quattrini A, Filippi M, 2017 Structural and functional brain signatures of C9orf72 in motor neuron disease. *Neurobiol Aging* 57, 206–219. doi:10.1016/j.neurobiolaging.2017.05.024 [PubMed: 28666709]
- Agosta F, Galantucci S, Magnani G, Marcone A, Martinelli D, Antonietta Volontè M, Riva N, Iannaccone S, Ferraro PM, Caso F, Chiò A, Comi G, Falini A, Filippi M, 2015 MRI signatures of the frontotemporal lobar degeneration continuum. *Hum Brain Mapp* 36, 2602–2614. doi:10.1002/hbm.22794 [PubMed: 25821176]
- Agosta F, Galantucci S, Riva N, Chiò A, Messina S, Iannaccone S, Calvo A, Silani V, Copetti M, Falini A, Comi G, Filippi M, 2014a Intrahemispheric and interhemispheric structural network abnormalities in PLS and ALS. *Hum Brain Mapp* 35, 1710–1722. doi:10.1002/hbm.22286 [PubMed: 23633431]
- Agosta F, Galantucci S, Valsasina P, Canu E, Meani A, Marcone A, Magnani G, Falini A, Comi G, Filippi M, 2014b Disrupted brain connectome in semantic variant of primary progressive aphasia. *Neurobiol Aging* 35, 2646–2655. doi:10.1016/j.neurobiolaging.2014.05.017 [PubMed: 24970567]
- Agosta F, Rocca MA, Valsasina P, Sala S, Caputo D, Perini M, Salvi F, Prella A, Filippi M, 2009 A longitudinal diffusion tensor MRI study of the cervical cord and brain in amyotrophic lateral sclerosis patients. *J Neurol Neurosurg Psychiatry* 80, 53–55. doi:10.1136/jnnp.2008.154252 [PubMed: 18931009]
- Agosta F, Scola E, Canu E, Marcone A, Magnani G, Sarro L, Copetti M, Caso F, Cerami C, Comi G, Cappa SF, Falini A, Filippi M, 2012 White matter damage in frontotemporal lobar degeneration spectrum. *Cereb Cortex* 22, 2705–2714. doi:10.1093/cercor/bhr288 [PubMed: 21988828]
- Agosta F, Spinelli E, Ghirelli A, Riva N, Magnani G, Caso F, Caroppo P, Prioni S, Tremolizzo L, Appollonio I, Silani V, Carrera P, Filippi M, 2020 Deep grey matter and hippocampal involvement in genetic cases of frontotemporal lobar degeneration (1508). *Neurology* 94, 1508.
- Agosta F, Spinelli EG, Marjanovic IV, Stevic Z, Pagani E, Valsasina P, Salak-Djokic B, Jankovic M, Lavrnjic D, Kostic VS, Filippi M, 2018 Unraveling ALS due to *SOD1* mutation through the combination of brain and cervical cord MRI. *Neurology* 90, e707–e716. doi:10.1212/WNL.0000000000005002 [PubMed: 29367447]
- Ajroud-Driss S, Fecto F, Ajroud K, Lalani I, Calvo SE, Mootha VK, Deng H-X, Siddique N, Tahmouh AJ, Heiman-Patterson TD, Siddique T, 2015 Mutation in the novel nuclear-encoded mitochondrial protein CHCHD10 in a family with autosomal dominant mitochondrial myopathy. *Neurogenetics* 16, 1–9. doi:10.1007/s10048-014-0421-1 [PubMed: 25193783]
- Akiyama T, Warita H, Kato M, Nishiyama A, Izumi R, Ikeda C, Kamada M, Suzuki N, Aoki M, 2016 Genotype-phenotype relationships in familial amyotrophic lateral sclerosis with *FUS/TLS* mutations in Japan: *FUS/TLS* linked FALS in Japan. *Muscle Nerve* 54, 398–404. doi:10.1002/mus.25061 [PubMed: 26823199]
- Albagha OME, Visconti MR, Alonso N, Langston AL, Cundy T, Dargie R, Dunlop MG, Fraser WD, Hooper MJ, Isaia G, Nicholson GC, del Pino Montes J, Gonzalez-Sarmiento R, di Stefano M, Tenesa A, Walsh JP, Ralston SH, 2010 Genome-wide association study identifies variants at *CSF1*, *OPTN* and *TNFRSF11A* as genetic risk factors for Paget's disease of bone. *Nat Genet* 42, 520–524. doi:10.1038/ng.562 [PubMed: 20436471]

- Alexander C, Pisner D, Jacova C, 2019 Predementia brain changes in progranulin mutation: a systematic review of neuroimaging evidence. *Dement Geriatr Cogn Disord* 47, 1–18. doi:10.1159/000494968 [PubMed: 30630176]
- Alexander C, Zeithamova D, Hsiung G-YR, Mackenzie IR, Jacova C, 2018 Decreased prefrontal activation during matrix reasoning in predementia progranulin mutation carriers. *J Alzheimers Dis* 62, 583–589. doi:10.3233/JAD-170716 [PubMed: 29480174]
- Al-Obeidi E, Al-Tahan S, Surampalli A, Goyal N, Wang AK, Hermann A, Omizo M, Smith C, Mozaffar T, Kimonis V, 2018 Genotype-phenotype study in patients with valosin-containing protein mutations associated with multisystem proteinopathy. *Clin Genet* 93, 119–125. doi:10.1111/cge.13095 [PubMed: 28692196]
- Ameur F, Colliot O, Caroppo P, Ströer S, Dormont D, Brice A, Azuar C, Dubois B, Le Ber I, Bertrand A, 2016 White matter lesions in FTL D: distinct phenotypes characterize *GRN* and *C9ORF72* mutations. *Neurol Genet* 2, e47. doi:10.1212/NXG.0000000000000047 [PubMed: 27066584]
- Andersen PM, Forsgren L, Binzer M, Nilsson P, Ala-Hurula V, Keranen ML, Bergmark L, Saarinen A, Haltia T, Tarvainen I, Kinnunen E, Udd B, Marklund SL, 1996 Autosomal recessive adult-onset amyotrophic lateral sclerosis associated with homozygosity for Asp90Ala CuZn-superoxide dismutase mutation. A clinical and genealogical study of 36 patients. *Brain* 119 (Pt 4), 1153–1172. doi:10.1093/brain/119.4.1153 [PubMed: 8813280]
- Anor CJ, Xi Z, Zhang M, Moreno D, Sato C, Rogaeva E, Tartaglia MC, 2015 Mutation analysis of C9orf72 in patients with corticobasal syndrome. *Neurobiol Aging* 36, 2905.e1–2905.e5. doi:10.1016/j.neurobiolaging.2015.06.008
- Arvanitakis Z, Witte RJ, Dickson DW, Tsuboi Y, Uitti RJ, Slowinski J, Hutton ML, Lin S-C, Boeve BF, Cheshire WP, Pooley RA, Liss JM, Caviness JN, Strongosky AJ, Wszolek ZK, 2007 Clinical-pathologic study of biomarkers in FTDP-17 (PPND family with N279K tau mutation). *Parkinsonism Relat Disord* 13, 230–239. doi:10.1016/j.parkreldis.2006.10.007 [PubMed: 17196872]
- Atassi N, Xu M, Triantafyllou C, Keil B, Lawson R, Cernasov P, Ratti E, Long CJ, Paganoni S, Murphy A, Salibi N, Seethamraju R, Rosen B, Ratai E-M, 2017 Ultra high-field (7tesla) magnetic resonance spectroscopy in amyotrophic lateral sclerosis. *PLoS One* 12, e0177680. doi:10.1371/journal.pone.0177680 [PubMed: 28498852]
- Baker M, Mackenzie IR, Pickering-Brown SM, Gass J, Rademakers R, Lindholm C, Snowden J, Adamson J, Sadovnick AD, Rollinson S, Cannon A, Dwosh E, Neary D, Melquist S, Richardson A, Dickson D, Berger Z, Eriksen J, Robinson T, Zehr C, Dickey CA, Crook R, McGowan E, Mann D, Boeve B, Feldman H, Hutton M, 2006 Mutations in progranulin cause tau-negative frontotemporal dementia linked to chromosome 17. *Nature* 442, 916–919. doi:10.1038/nature05016 [PubMed: 16862116]
- Bannwarth S, Ait-El-Mkadem S, Chaussonot A, Genin EC, Lacas-Gervais S, Fragaki K, Berg-Alonso L, Kageyama Y, Serre V, Moore DG, Verschuere A, Rouzier C, Le Ber I, Augé G, Cochaud C, Lespinasse F, N’Guyen K, de Septenville A, Brice A, Yu-Wai-Man P, Sesaki H, Pouget J, Paquis-Flucklinger V, 2014 A mitochondrial origin for frontotemporal dementia and amyotrophic lateral sclerosis through CHCHD10 involvement. *Brain* 137, 2329–2345. doi:10.1093/brain/awu138 [PubMed: 24934289]
- Battistella G, Borghesani V, Henry M, Shwe W, Lauricella M, Miller Z, Deleon J, Miller BL, Dronkers N, Brambati SM, Seeley WW, Mandelli ML, Gorno-Tempini ML, 2020 Task-free functional language networks: reproducibility and clinical application. *J Neurosci* 40, 1311–1320. doi:10.1523/JNEUROSCI.1485-19.2019 [PubMed: 31852732]
- Beck J, Rohrer JD, Campbell T, Isaacs A, Morrison KE, Goodall EF, Warrington EK, Stevens J, Revesz T, Holton J, Al-Sarraj S, King A, Scahill R, Warren JD, Fox NC, Rossor MN, Collinge J, Mead S, 2008 A distinct clinical, neuropsychological and radiological phenotype is associated with progranulin gene mutations in a large UK series. *Brain* 131, 706–720. doi:10.1093/brain/awm320 [PubMed: 18234697]
- Bede P, Bokde A, Elamin M, Byrne S, McLaughlin RL, Jordan N, Hampel H, Gallagher L, Lynch C, Fagan AJ, Pender N, Hardiman O, 2013a Grey matter correlates of clinical variables in amyotrophic lateral sclerosis (ALS): a neuroimaging study of ALS motor phenotype heterogeneity

and cortical focality. *J Neurol Neurosurg Psychiatry* 84, 766–773. doi:10.1136/jnnp-2012-302674 [PubMed: 23085933]

- Bede P, Bokde ALW, Byrne S, Elamin M, McLaughlin RL, Kenna K, Fagan AJ, Pender N, Bradley DG, Hardiman O, 2013b Multiparametric MRI study of ALS stratified for the C9orf72 genotype. *Neurology* 81, 361–369. doi:10.1212/WNL.0b013e31829c5eee [PubMed: 23771489]
- Bede P, Elamin M, Byrne S, McLaughlin RL, Kenna K, Vajda A, Pender N, Bradley DG, Hardiman O, 2013c Basal ganglia involvement in amyotrophic lateral sclerosis. *Neurology* 81, 2107–2115. doi:10.1212/01.wnl.0000437313.80913.2c [PubMed: 24212388]
- Bede P, Hardiman O, 2018 Longitudinal structural changes in ALS: a three time-point imaging study of white and gray matter degeneration. *Amyotroph Lateral Scler Frontotemporal Degener* 19, 232–241. doi:10.1080/21678421.2017.1407795 [PubMed: 29214883]
- Bede P, Omer T, Finegan E, Chipika RH, Iyer PM, Doherty MA, Vajda A, Pender N, McLaughlin RL, Hutchinson S, Hardiman O, 2018 Connectivity-based characterisation of subcortical grey matter pathology in frontotemporal dementia and ALS: a multimodal neuroimaging study. *Brain Imaging Behav* 12, 1696–1707. doi:10.1007/s11682-018-9837-9 [PubMed: 29423814]
- Belzil VV, Daoud H, Desjarlais A, Bouchard J-P, Dupré N, Camu W, Dion PA, Rouleau GA, 2011 Analysis of OPTN as a causative gene for amyotrophic lateral sclerosis. *Neurobiol Aging* 32, 555.e13–555.e14. doi:10.1016/j.neurobiolaging.2010.10.001
- Benajiba L, Le Ber I, Camuzat A, Lacoste M, Thomas-Anterion C, Couratier P, Legallic S, Salachas F, Hannequin D, Decousus M, Lacomblez L, Guedj E, Golfier V, Camu W, Dubois B, Campion D, Meininger V, Brice A, French Clinical and Genetic Research Network on Frontotemporal Lobar Degeneration/Frontotemporal Lobar Degeneration with Motoneuron Disease, 2009 *TARDBP* mutations in motoneuron disease with frontotemporal lobar degeneration. *Ann Neurol* 65, 470–473. doi:10.1002/ana.21612 [PubMed: 19350673]
- Benussi A, Gazzina S, Premi E, Cosseddu M, Archetti S, Dell’Era V, Cantoni V, Cotelli MS, Alberici A, Micheli A, Benussi L, Ghidoni R, Padovani A, Borroni B, 2019 Clinical and biomarker changes in presymptomatic genetic frontotemporal dementia. *Neurobiol Aging* 76, 133–140. doi:10.1016/j.neurobiolaging.2018.12.018 [PubMed: 30711676]
- Ber IL, Guedj E, Gabelle A, Verpillat P, Volteau M, Thomas-Anterion C, Decousus M, Hannequin D, Vera P, Lacomblez L, Camuzat A, Didic M, Puel M, Lotterie JA, Golfier V, Bernard A-M, Vercelletto M, Magne C, Sellal F, Namer I, Michel BF, Pasquier J, Salachas F, Bochet J, Brice A, Habert MO, Dubois B, 2006 Demographic, neurological and behavioural characteristics and brain perfusion SPECT in frontal variant of frontotemporal dementia. *Brain* 129, 3051–3065. doi:10.1093/brain/awl288 [PubMed: 17071924]
- Bertrand A, Wen J, Rinaldi D, Houot M, Sayah S, Camuzat A, Fournier C, Fontanella S, Routier A, Couratier P, Pasquier F, Habert M-O, Hannequin D, Martinaud O, Caroppo P, Levy R, Dubois B, Brice A, Durrleman S, Colliot O, Le Ber I, for the Predict to Prevent Frontotemporal Lobar Degeneration and Amyotrophic Lateral Sclerosis (PREV-DEMALS) Study Group, 2018 Early cognitive, structural, and microstructural changes in presymptomatic *C9orf72* carriers younger than 40 years. *JAMA Neurol* 75, 236. doi:10.1001/jamaneurol.2017.4266 [PubMed: 29197216]
- Bevan-Jones WR, Cope TE, Jones PS, Passamonti L, Hong YT, Fryer T, Arnold R, Coles JP, Aigbirhio FI, O’Brien JT, Rowe JB, 2019 In vivo evidence for presymptomatic neuroinflammation in a MAPT mutation carrier. *Ann Clin Transl Neurol* 6, 373–378. doi:10.1002/acn3.683 [PubMed: 30847369]
- Blain CRV, Brunton S, Williams VC, Leemans A, Turner MR, Andersen PM, Catani M, Stanton BR, Ganesalingham J, Jones DK, Williams SCR, Leigh PN, Simmons A, 2011 Differential corticospinal tract degeneration in homozygous “D90A” SOD-1 ALS and sporadic ALS. *J Neurol Neurosurg Psychiatry* 82, 843–849. doi:10.1136/jnnp.2010.236018 [PubMed: 21515558]
- Blair IP, Williams KL, Warraich ST, Durnall JC, Thoeng AD, Manavis J, Blumbergs PC, Vucic S, Kiernan MC, Nicholson GA, 2010 FUS mutations in amyotrophic lateral sclerosis: clinical, pathological, neurophysiological and genetic analysis. *J Neurol Neurosurg Psychiatry* 81, 639–645. doi:10.1136/jnnp.2009.194399 [PubMed: 19965854]
- Bocchetta M, Iglesias JE, Neason M, Cash DM, Warren JD, Rohrer JD, 2020 Thalamic nuclei in frontotemporal dementia: Mediodorsal nucleus involvement is universal but pulvinar atrophy is

unique to *C9orf72*. *Hum Brain Mapp* 41, 1006–1016. doi:10.1002/hbm.24856 [PubMed: 31696638]

- Boeve BF, 2005 Longitudinal characterization of two siblings with frontotemporal dementia and parkinsonism linked to chromosome 17 associated with the S305N tau mutation. *Brain* 128, 752–772. doi:10.1093/brain/awh356 [PubMed: 15615814]
- Boeve BF, Boylan KB, Graff-Radford NR, DeJesus-Hernandez M, Knopman DS, Pedraza O, Vemuri P, Jones D, Lowe V, Murray ME, Dickson DW, Josephs KA, Rush BK, Machulda MM, Fields JA, Ferman TJ, Baker M, Rutherford NJ, Adamson J, Wszolek ZK, Adeli A, Savica R, Boot B, Kuntz KM, Gavrilova R, Reeves A, Whitwell J, Kantarci K, Jack CR, Parisi JE, Lucas JA, Petersen RC, Rademakers R, 2012 Characterization of frontotemporal dementia and/or amyotrophic lateral sclerosis associated with the GGGGCC repeat expansion in C9ORF72. *Brain* 135, 765–783. doi:10.1093/brain/aws004 [PubMed: 22366793]
- Borghero G, Floris G, Cannas A, Marrosu MG, Murru MR, Costantino E, Parish LD, Pugliatti M, Ticca A, Traynor BJ, Calvo A, Cammarosano S, Moglia C, Cistaro A, Brunetti M, Restagno G, Chiò A, 2011 A patient carrying a homozygous p.A382T TARDBP missense mutation shows a syndrome including ALS, extrapyramidal symptoms, and FTD. *Neurobiol Aging* 32, 2327.e1–2327.e5. doi:10.1016/j.neurobiolaging.2011.06.009
- Borroni B, Alberici A, Cercignani M, Premi E, Serra L, Cerini C, Cosseddu M, Pettenati C, Turla M, Archetti S, Gasparotti R, Caltagirone C, Padovani A, Bozzali M, 2012 Granulin mutation drives brain damage and reorganization from preclinical to symptomatic FTL. *Neurobiol Aging* 33, 2506–2520. doi:10.1016/j.neurobiolaging.2011.10.031 [PubMed: 22130207]
- Borroni B, Alberici A, Premi E, Archetti S, Garibotto V, Agosti C, Gasparotti R, Di Luca M, Perani D, Padovani A, 2008 Brain magnetic resonance imaging structural changes in a pedigree of asymptomatic progranulin mutation carriers. *Rejuvenation Res* 11, 585–595. doi:10.1089/rej.2007.0623 [PubMed: 18593276]
- Borroni B, Bonvicini C, Alberici A, Buratti E, Agosti C, Archetti S, Papetti A, Stuardi C, Di Luca M, Gennarelli M, Padovani A, 2009 Mutation within *TARDBP* leads to frontotemporal dementia without motor neuron disease. *Hum Mutat* 30, E974–E983. doi:10.1002/humu.21100 [PubMed: 19655382]
- Borroni B, Ferrari F, Galimberti D, Nacmias B, Barone C, Bagnoli S, Fenoglio C, Piaceri I, Archetti S, Bonvicini C, Gennarelli M, Turla M, Scarpini E, Sorbi S, Padovani A, 2014 Heterozygous TREM2 mutations in frontotemporal dementia. *Neurobiol Aging* 35, 934.e7–934.e10. doi:10.1016/j.neurobiolaging.2013.09.017
- Boxer AL, Mackenzie IR, Boeve BF, Baker M, Seeley WW, Crook R, Feldman H, Hsiung G-YR, Rutherford N, Laluz V, Whitwell J, Foti D, McDade E, Molano J, Karydas A, Wojtas A, Goldman J, Mirsky J, Sengdy P, DeArmond S, Miller BL, Rademakers R, 2011 Clinical, neuroimaging and neuropathological features of a new chromosome 9p-linked FTD-ALS family. *J Neurol Neurosurg Psychiatry* 82, 196–203. doi:10.1136/jnnp.2009.204081 [PubMed: 20562461]
- Bozzali M, Battistoni V, Premi E, Alberici A, Giulietti G, Archetti S, Turla M, Gasparotti R, Cercignani M, Padovani A, Borroni B, 2013 Structural brain signature of FTL driven by Granulin mutation. *J Alzheimers Dis* 33, 483–494. doi:10.3233/JAD-2012-121273 [PubMed: 22986778]
- Broad RJ, Gabel MC, Dowell NG, Schwartzman DJ, Seth AK, Zhang H, Alexander DC, Cercignani M, Leigh PN, 2019 Neurite orientation and dispersion density imaging (NODDI) detects cortical and corticospinal tract degeneration in ALS. *J Neurol Neurosurg Psychiatry* 90, 404–411. doi:10.1136/jnnp-2018-318830 [PubMed: 30361295]
- Broe M, Hodges JR, Schofield E, Shepherd CE, Kril JJ, Halliday GM, 2003 Staging disease severity in pathologically confirmed cases of frontotemporal dementia. *Neurology* 60, 1005–1011. doi:10.1212/01.WNL.0000052685.09194.39 [PubMed: 12654969]
- Brooks BR, Miller RG, Swash M, Munsat TL, 2000 El Escorial revisited: Revised criteria for the diagnosis of amyotrophic lateral sclerosis. *Amyotroph Lateral Scler Other Motor Neuron Disord* 1, 293–299. doi:10.1080/146608200300079536 [PubMed: 11464847]
- Broustal O, Camuzat A, Guillot-Noel L, Guy N, Millicamps S, Deffond D, Lacomblez L, Golfier V, Hannequin D, Salachas F, Camu W, Didic M, Dubois B, Meininger V, Le Ber I, Brice A, French clinical and genetic research network on FTD/FTD-MND., 2010 FUS mutations in frontotemporal

lobar degeneration with amyotrophic lateral sclerosis. *J Alzheimers Dis* 22, 765–769. [PubMed: 21158017]

- Buhour M-S, Doidy F, Laisney M, Pitel AL, de La Sayette V, Viader F, Eustache F, Desgranges B, 2017a Pathophysiology of the behavioral variant of frontotemporal lobar degeneration: a study combining MRI and FDG-PET. *Brain Imaging Behav* 11, 240–252. doi:10.1007/s11682-016-9521-x [PubMed: 26852326]
- Buhour M-S, Doidy F, Mondou A, Pélerin A, Carlier L, Eustache F, Viader F, Desgranges B, 2017b Voxel-based mapping of grey matter volume and glucose metabolism profiles in amyotrophic lateral sclerosis. *EJNMMI Res* 7. doi:10.1186/s13550-017-0267-2
- Burrell JR, Kiernan MC, Vucic S, Hodges JR, 2011 Motor Neuron dysfunction in frontotemporal dementia. *Brain* 134, 2582–2594. doi:10.1093/brain/awr195 [PubMed: 21840887]
- Byrne S, Elamin M, Bede P, Shatunov A, Walsh C, Corr B, Heverin M, Jordan N, Kenna K, Lynch C, McLaughlin RL, Iyer PM, O'Brien C, Phukan J, Wynne B, Bokde AL, Bradley DG, Pender N, Al-Chalabi A, Hardiman O, 2012 Cognitive and clinical characteristics of patients with amyotrophic lateral sclerosis carrying a C9orf72 repeat expansion: a population-based cohort study. *Lancet Neurol* 11, 232–240. doi:10.1016/S1474-4422(12)70014-5 [PubMed: 22305801]
- Carew JD, Nair G, Andersen PM, Wu J, Gronka S, Hu X, Benatar M, 2011a Presymptomatic spinal cord neurometabolic findings in SOD1-positive people at risk for familial ALS. *Neurology* 77, 1370–1375. doi:10.1212/WNL.0b013e318231526a [PubMed: 21940617]
- Carew JD, Nair G, Pineda-Alonso N, Usher S, Hu X, Benatar M, 2011b Magnetic resonance spectroscopy of the cervical cord in amyotrophic lateral sclerosis. *Amyotroph Lateral Scler* 12, 185–191. doi:10.3109/17482968.2010.515223 [PubMed: 21143004]
- Caroppo P, Camuzat A, De Septenville A, Couratier P, Lacomblez L, Auriacombe S, Flabeau O, Journéa L, Blanc F, Sellal F, Cretin B, Meininger V, Fleury M-C, Couarch P, Dubois B, Brice A, Le Ber I, 2015a Semantic and nonfluent aphasic variants, secondarily associated with amyotrophic lateral sclerosis, are predominant frontotemporal lobar degeneration phenotypes in TBK1 carriers. *Alzheimers Dement (Amst)* 1, 481–486. doi:10.1016/j.dadm.2015.10.002 [PubMed: 27239526]
- Caroppo P, Camuzat A, Guillot-Noel L, Thomas-Antérion C, Couratier P, Wong TH, Teichmann M, Golfier V, Auriacombe S, Belliard S, Laurent B, Lattante S, Millecamps S, Clot F, Dubois B, van Swieten JC, Brice A, Le Ber I, 2016 Defining the spectrum of frontotemporal dementias associated with *TARDBP* mutations. *Neurol Genet* 2, e80. doi:10.1212/NXG.0000000000000080 [PubMed: 27280171]
- Caroppo P, Durrleman S, Funkiewiez A, Perlberg V, Hahn V, Bertin H, Gaubert M, Routier A, Hannequin D, Deramecourt V, Pasquier F, Rivaud-Pechoux S, Vercelletto M, Edouart G, Valabregue R, Lejeune P, Didic M, Corvol J-C, Benali H, Lehericy S, Dubois B, Colliot O, Brice A, Le Ber I, 2015b Lateral temporal lobe: an early imaging marker of the presymptomatic GRN disease? *J Alzheimers Dis* 47, 751–759. doi:10.3233/JAD-150270 [PubMed: 26401709]
- Caroppo P, Le Ber I, Camuzat A, Clot F, Naccache L, Lamari F, De Septenville A, Bertrand A, Belliard S, Hannequin D, Colliot O, Brice A, 2014 Extensive white matter involvement in patients with frontotemporal lobar degeneration: think progranulin. *JAMA Neurol* 71, 1562. doi:10.1001/jamaneurol.2014.1316 [PubMed: 25317628]
- Cash DM, Bocchetta M, Thomas DL, Dick KM, van Swieten JC, Borroni B, Galimberti D, Masellis M, Tartaglia MC, Rowe JB, Graff C, Tagliavini F, Frisoni GB, Laforce R, Finger E, de Mendonça A, Sorbi S, Rossor MN, Ourselin S, Rohrer JD, Andersson C, Archetti S, Arighi A, Benussi L, Black S, Cosseddu M, Fallström M, Ferreira C, Fenoglio C, Fox N, Freedman M, Fumagalli G, Gazzina S, Ghidoni R, Grisoli M, Jelic V, Jiskoot L, Keren R, Lombardi G, Maruta C, Mead S, Meeter L, van Minkelen R, Nacmias B, Öijerstedt L, Padovani A, Panman J, Pievani M, Polito C, Premi E, Prioni S, Rademakers R, Redaelli V, Rogaeva E, Rossi G, Rossor M, Scarpini E, Tang-Wai D, Tartaglia C, Thonberg H, Tiraboschi P, Verdelho A, Warren J, 2018 Patterns of gray matter atrophy in genetic frontotemporal dementia: results from the GENFI study. *Neurobiol Aging* 62, 191–196. doi:10.1016/j.neurobiolaging.2017.10.008 [PubMed: 29172163]
- Castelnovo V, Caminiti SP, Riva N, Magnani G, Silani V, Perani D, 2019 Heterogeneous brain FDG-PET metabolic patterns in patients with C9orf72 mutation. *Neurol Sci* 40, 515–521. doi:10.1007/s10072-018-3685-7 [PubMed: 30554355]

- Cerami C, Dodich A, Greco L, Iannaccone S, Magnani G, Marcone A, Pelagallo E, Santangelo R, Cappa SF, Perani D, 2017 The role of single-subject brain metabolic patterns in the early differential diagnosis of primary progressive aphasias and in prediction of progression to dementia. *J Alzheimers Dis* 55, 183–197. doi:10.3233/JAD-160682 [PubMed: 27662315]
- Chausseot A, Le Ber I, Ait-El-Mkadem S, Camuzat A, de Septenville A, Bannwarth S, Genin EC, Serre V, Augé G, Brice A, Pouget J, Paquis-Flucklinger V, 2014 Screening of CHCHD10 in a French cohort confirms the involvement of this gene in frontotemporal dementia with amyotrophic lateral sclerosis patients. *Neurobiol Aging* 35, 2884.e1–2884.e4. doi:10.1016/j.neurobiolaging.2014.07.022 [PubMed: 25155093]
- Chen Q, Boeve BF, Schwarz CG, Reid R, Tosakulwong N, Lesnick TG, Bove J, Brannely P, Brushaber D, Coppola G, Dheel C, Dickerson BC, Dickinson S, Faber K, Fields J, Fong J, Foroud T, Forsberg L, Gavrilova RH, Gearhart D, Ghoshal N, Goldman J, Graff-Radford J, Graff-Radford NR, Grossman M, Haley D, Heuer HW, Hsiung G-YR, Huey E, Irwin DJ, Jack CR, Jones DT, Jones L, Karydas AM, Knopman DS, Kornak J, Kramer J, Kremers W, Kukull WA, Lapid M, Lucente D, Lungu C, Mackenzie IRA, Manoochchri M, McGinnis S, Miller BL, Pearlman R, Petrucelli L, Potter M, Rademakers R, Ramos EM, Rankin KP, Rascovsky K, Sengdy P, Shaw L, Syrjanen J, Tatton N, Taylor J, Toga AW, Trojanowski J, Weintraub S, Wong B, Boxer AL, Rosen H, Wszolek Z, Kantarci K, 2019a Tracking white matter degeneration in asymptomatic and symptomatic MAPT mutation carriers. *Neurobiol Aging* 83, 54–62. doi:10.1016/j.neurobiolaging.2019.08.011 [PubMed: 31585367]
- Chen Q, Boeve BF, Senjem M, Tosakulwong N, Lesnick T, Brushaber D, Dheel C, Fields J, Forsberg L, Gavrilova R, Gearhart D, Graff-Radford J, Graff-Radford N, Jack CR, Jones D, Knopman D, Kremers WK, Lapid M, Rademakers R, Ramos EM, Syrjanen J, Boxer AL, Rosen H, Wszolek ZK, Kantarci K, 2020 Trajectory of lobar atrophy in asymptomatic and symptomatic GRN mutation carriers: a longitudinal MRI study. *Neurobiol Aging* 88, 42–50. doi:10.1016/j.neurobiolaging.2019.12.004 [PubMed: 31918955]
- Chen Q, Boeve BF, Senjem M, Tosakulwong N, Lesnick TG, Brushaber D, Dheel C, Fields J, Forsberg L, Gavrilova R, Gearhart D, Graff-Radford J, Graff-Radford NR, Jack CR, Jones DT, Knopman DS, Kremers WK, Lapid M, Rademakers R, Syrjanen J, Boxer AL, Rosen H, Wszolek ZK, Kantarci K, 2019b Rates of lobar atrophy in asymptomatic MAPT mutation carriers. *Alzheimers Dement (N Y)* 5, 338–346. doi:10.1016/j.trci.2019.05.010 [PubMed: 31388560]
- Chen Q, Boeve BF, Tosakulwong N, Lesnick T, Brushaber D, Dheel C, Fields J, Forsberg L, Gavrilova R, Gearhart D, Haley D, Gunter JL, Graff-Radford J, Jones D, Knopman D, Graff-Radford N, Kraft R, Lapid M, Rademakers R, Syrjanen J, Wszolek ZK, Rosen H, Boxer AL, Kantarci K, 2019c Frontal lobe ¹H MR spectroscopy in asymptomatic and symptomatic MAPT mutation carriers. *Neurology* 93, e758–e765. doi:10.1212/WNL.0000000000007961 [PubMed: 31315971]
- Chen Q, Boeve BF, Tosakulwong N, Lesnick T, Brushaber D, Dheel C, Fields J, Forsberg L, Gavrilova R, Gearhart D, Haley D, Gunter JL, Graff-Radford J, Jones D, Knopman D, Graff-Radford N, Kraft R, Lapid M, Rademakers R, Wszolek ZK, Rosen H, Boxer AL, Kantarci K, 2019d Brain MR spectroscopy changes precede frontotemporal lobar degeneration phenocconversion in Mapt mutation carriers. *J Neuroimaging* 29, 624–629. doi:10.1111/jon.12642 [PubMed: 31173437]
- Chen Q, Kantarci K, 2020 Imaging Biomarkers for neurodegeneration in presymptomatic familial frontotemporal lobar degeneration. *Front Neurol* 11. doi:10.3389/fneur.2020.00080
- Cheng YW, Lee MJ, Chen TF, Cheng TW, Lai YM, Hua MS, Chiu MJ, 2016 A single nucleotide TDP-43 mutation within a Taiwanese family: a multifaceted demon. *Amyotroph Lateral Scler Frontotemporal Degener* 17, 292–294. doi:10.3109/21678421.2015.1111905 [PubMed: 26581115]
- Chen-Plotkin AS, Martinez-Lage M, Sleiman PMA, Hu W, Greene R, Wood EM, Bing S, Grossman M, Schellenberg GD, Hatanpaa KJ, Weiner MF, White CL, Brooks WS, Halliday GM, Kril JJ, Gearing M, Beach TG, Graff-Radford NR, Dickson DW, Rademakers R, Boeve BF, Pickering-Brown SM, Snowden J, van Swieten JC, Heutink P, Seelaar H, Murrell JR, Ghetti B, Spina S, Grafman J, Kaye JA, Woltjer RL, Mesulam M, Bigio E, Lladó A, Miller BL, Alzualde A, Moreno F, Rohrer JD, Mackenzie IRA, Feldman HH, Hamilton RL, Cruts M, Engelborghs S, De Deyn PP, Van Broeckhoven C, Bird TD, Cairns NJ, Goate A, Frosch MP, Riederer PF, Bogdanovic N, Lee VMY, Trojanowski JQ, Van Deerlin VM, 2011 Genetic and clinical features of progranulin-associated frontotemporal lobar degeneration. *Arch Neurol* 68, 488. doi:10.1001/archneurol.2011.53 [PubMed: 21482928]

- Cheong I, Marjaska M, Deelchand DK, Eberly LE, Walk D, Öz G, 2017 Ultra-high field proton MR spectroscopy in early-stage amyotrophic lateral sclerosis. *Neurochem Res* 42, 1833–1844. doi:10.1007/s11064-017-2248-2 [PubMed: 28367604]
- Chi S, Jiang T, Tan L, Yu J-T, 2016 Distinct neurological disorders with C9orf72 mutations: genetics, pathogenesis, and therapy. *Neurosci Biobehav Rev* 66, 127–142. doi:10.1016/j.neubiorev.2016.03.033 [PubMed: 27139021]
- Chiò A, Calvo A, Moglia C, Restagno G, Ossola I, Brunetti M, Montuschi A, Cistaro A, Ticca A, Traynor BJ, Schymick JC, Mutani R, Marrosu MG, Murru MR, Borghero G, 2010 Amyotrophic lateral sclerosis–frontotemporal lobar dementia in 3 families with p.Ala382Thr TARDBP mutations. *Arch Neurol* 67, 1002–1009. doi:10.1001/archneurol.2010.173 [PubMed: 20697052]
- Chiò A, Restagno G, Brunetti M, Ossola I, Calvo A, Mora G, Sabatelli M, Monsurò MR, Battistini S, Mandrioli J, Salvi F, Spataro R, Schymick J, Traynor BJ, La Bella V, 2009 Two Italian kindreds with familial amyotrophic lateral sclerosis due to FUS mutation. *Neurobiol Aging* 30, 1272–1275. doi:10.1016/j.neurobiolaging.2009.05.001 [PubMed: 19450904]
- Chipika RH, Finegan E, Li Hi Shing S, McKenna MC, Christidi F, Chang KM, Doherty MA, Hengeveld JC, Vajda A, Pender N, Hutchinson S, Donaghy C, McLaughlin RL, Hardiman O, Bede P, 2020 “Switchboard” malfunction in motor neuron diseases: Selective pathology of thalamic nuclei in amyotrophic lateral sclerosis and primary lateral sclerosis. *NeuroImage Clin* 27, 102300. doi:10.1016/j.nicl.2020.102300 [PubMed: 32554322]
- Christidi F, Karavasilis E, Riederer F, Zalonis I, Ferentinos P, Velonakis G, Xirou S, Rentzos M, Argiropoulos G, Zouvelou V, Zambelis T, Athanasakos A, Toulas P, Vadikolias K, Efstathopoulos E, Kollias S, Karandreas N, Kelekis N, Evdokimidis I, 2018 Gray matter and white matter changes in non-demented amyotrophic lateral sclerosis patients with or without cognitive impairment: A combined voxel-based morphometry and tract-based spatial statistics whole-brain analysis. *Brain Imaging Behav* 12, 547–563. doi:10.1007/s11682-017-9722-y [PubMed: 28425061]
- Cirulli ET, Lasseigne BN, Petrovski S, Sapp PC, Dion PA, Leblond CS, Couthouis J, Lu Y-F, Wang Q, Krueger BJ, Ren Z, Keebler J, Han Y, Levy SE, Boone BE, Wimbish JR, Waite LL, Jones AL, Carulli JP, Day-Williams AG, Staropoli JF, Xin WW, Chesi A, Raphael AR, McKenna-Yasek D, Cady J, Vianney de Jong JMB, Kenna KP, Smith BN, Topp S, Miller J, Gkazi A, FALS Sequencing Consortium, Al-Chalabi A, van den Berg LH, Veldink J, Silani V, Ticozzi N, Shaw CE, Baloh RH, Appel S, Simpson E, Lagier-Tourenne C, Pulst SM, Gibson S, Trojanowski JQ, Elman L, McCluskey L, Grossman M, Shneider NA, Chung WK, Ravits JM, Glass JD, Sims KB, Van Deerlin VM, Maniatis T, Hayes SD, Ordureau A, Swarup S, Landers J, Baas F, Allen AS, Bedlack RS, Harper JW, Gitler AD, Rouleau GA, Brown R, Harms MB, Cooper GM, Harris T, Myers RM, Goldstein DB, 2015 Exome sequencing in amyotrophic lateral sclerosis identifies risk genes and pathways. *Science* 347, 1436–1441. doi:10.1126/science.aaa3650 [PubMed: 25700176]
- Cistaro A, Pagani M, Montuschi A, Calvo A, Moglia C, Canosa A, Restagno G, Brunetti M, Traynor BJ, Nobili F, Carrara G, Fania P, Lopiano L, Valentini MC, Chiò A, 2014 The metabolic signature of C9ORF72-related ALS: FDG PET comparison with nonmutated patients. *Eur J Nucl Med Mol Imaging* 41, 844–852. doi:10.1007/s00259-013-2667-5 [PubMed: 24445987]
- Cistaro A, Valentini MC, Chiò A, Nobili F, Calvo A, Moglia C, Montuschi A, Morbelli S, Salmasso D, Fania P, Carrara G, Pagani M, 2012 Brain hypermetabolism in amyotrophic lateral sclerosis: a FDG PET study in ALS of spinal and bulbar onset. *Eur J Nucl Med Mol Imaging* 39, 251–259. doi:10.1007/s00259-011-1979-6 [PubMed: 22089661]
- Clark LN, Poorkaj P, Wszolek Z, Geschwind DH, Nasreddine ZS, Miller B, Li D, Payami H, Awert F, Markopoulou K, Andreadis A, D’Souza I, Lee VM, Reed L, Trojanowski JQ, Zhukareva V, Bird T, Schellenberg G, Wilhelmsen KC, 1998 Pathogenic implications of mutations in the tau gene in pallido-ponto-nigral degeneration and related neurodegenerative disorders linked to chromosome 17. *Proc Natl Acad Sci U S A* 95, 13103–13107. doi:10.1073/pnas.95.22.13103 [PubMed: 9789048]
- Consonni M, Cappa SF, Dalla Bella E, Contarino VE, Lauria G, 2019 Cortical correlates of behavioural change in amyotrophic lateral sclerosis. *J Neurol Neurosurg Psychiatry* 90, 380–386. doi:10.1136/jnnp-2018-318619 [PubMed: 30322899]
- Cooper-Knock J, Hewitt C, Highley JR, Brockington A, Milano A, Man S, Martindale J, Hartley J, Walsh T, Gelsthorpe C, Baxter L, Forster G, Fox M, Bury J, Mok K, McDermott CJ, Traynor BJ,

- Kirby J, Wharton SB, Ince PG, Hardy J, Shaw PJ, 2012 Clinico-pathological features in amyotrophic lateral sclerosis with expansions in C9ORF72. *Brain* 135, 751–764. doi:10.1093/brain/awr365 [PubMed: 22366792]
- Crockford C, Newton J, Lonergan K, Chiwera T, Booth T, Chandran S, Colville S, Heverin M, Mays I, Pal S, Pender N, Pinto-Grau M, Radakovic R, Shaw CE, Stephenson L, Swingler R, Vajda A, Al-Chalabi A, Hardiman O, Abrahams S, 2018 ALS-specific cognitive and behavior changes associated with advancing disease stage in ALS. *Neurology* 91, e1370–e1380. doi:10.1212/WNL.0000000000006317 [PubMed: 30209236]
- Cruchaga C, Fernández-Seara MA, Seiyo-Martínez M, Samaranch L, Lorenzo E, Hinrichs A, Irigoyen J, Maestro C, Prieto E, Martí-Climent JM, Arbizu J, Pastor MA, Pastor P, 2009 Cortical atrophy and language network reorganization associated with a novel progranulin mutation. *Cereb Cortex* 19, 1751–1760. doi:10.1093/cercor/bhn202 [PubMed: 19020205]
- Cruts M, Gijselink I, van der Zee J, Engelborghs S, Wils H, Pirici D, Rademakers R, Vandenberghe R, Dermaut B, Martin J-J, van Duijn C, Peeters K, Sciot R, Santens P, De Pooter T, Mattheijssens M, Van den Broeck M, Cuijt I, Vennekens K, De Deyn PP, Kumar-Singh S, Van Broeckhoven C, 2006 Null mutations in progranulin cause ubiquitin-positive frontotemporal dementia linked to chromosome 17q21. *Nature* 442, 920–924. doi:10.1038/nature05017 [PubMed: 16862115]
- Cudkowicz ME, McKenna-Yasek D, Chen C, Hedley-Whyte ET, Brown RH, 1998 Limited corticospinal tract involvement in amyotrophic lateral sclerosis subjects with the A4V mutation in the copper/zinc superoxide dismutase gene. *Ann Neurol* 43, 703–710. doi:10.1002/ana.410430604 [PubMed: 9629839]
- Cudkowicz ME, McKenna-Yasek D, Sapp PE, Chin W, Geller B, Hayden DL, Schoenfeld DA, Hosler BA, Horvitz HR, Brown RH, 1997 Epidemiology of mutations in superoxide dismutase in amyotrophic lateral sclerosis. *Ann Neurol* 41, 210–221. doi:10.1002/ana.410410212 [PubMed: 9029070]
- Dalakas MC, Hatazawa J, Brooks RA, Di Chiro G, 1987 Lowered cerebral glucose utilization in amyotrophic lateral sclerosis. *Ann Neurol* 22, 580–586. doi:10.1002/ana.410220504 [PubMed: 3501273]
- Daoud H, Suhail H, Szuto A, Camu W, Salachas F, Meininger V, Bouchard J-P, Dupré N, Dion PA, Rouleau GA, 2012 UBQLN2 mutations are rare in French and French–Canadian amyotrophic lateral sclerosis. *Neurobiol Aging* 33, 2230.e1–2230.e5. doi:10.1016/j.neurobiolaging.2012.03.015
- Day GS, Farb NAS, Tang-Wai DF, Masellis M, Black SE, Freedman M, Pollock BG, Chow TW, 2013 Saliency network resting-state activity: prediction of frontotemporal dementia progression. *JAMA Neurol* 70, 1249–1253. doi:10.1001/jamaneurol.2013.3258 [PubMed: 23959214]
- De Vocht J, Blommaert J, Devrome M, Radwan A, Van Weehaeghe D, De Schaepdryver M, Ceccarini J, Rezaei A, Schramm G, van Aalst J, Chiò A, Pagani M, Stam D, Van Esch H, Lamaire N, Verhaegen M, Mertens N, Poesen K, van den Berg LH, van Es MA, Vandenberghe R, Vandembulcke M, Van den Stock J, Koole M, Dupont P, Van Laere K, Van Damme P, 2020 Use of multimodal imaging and clinical biomarkers in presymptomatic carriers of C9orf72 repeat expansion. *JAMA Neurol*. doi:10.1001/jamaneurol.2020.1087
- DeJesus-Hernandez M, Mackenzie IR, Boeve BF, Boxer AL, Baker M, Rutherford NJ, Nicholson AM, Finch NA, Flynn H, Adamson J, Kouri N, Wojtas A, Sengdy P, Hsiung G-YR, Karydas A, Seeley WW, Josephs KA, Coppola G, Geschwind DH, Wszolek ZK, Feldman H, Knopman DS, Petersen RC, Miller BL, Dickson DW, Boylan KB, Graff-Radford NR, Rademakers R, 2011 Expanded GGGCC hexanucleotide repeat in noncoding region of C9ORF72 causes chromosome 9p-linked FTD and ALS. *Neuron* 72, 245–256. doi:10.1016/j.neuron.2011.09.011 [PubMed: 21944778]
- Del Bo R, Ghezzi S, Corti S, Pandolfo M, Ranieri M, Santoro D, Ghione I, Prella A, Orsetti V, Mancuso M, Sorarù G, Briani C, Angelini C, Siciliano G, Bresolin N, Comi GP, 2009 TARDBP (TDP-43) sequence analysis in patients with familial and sporadic ALS: identification of two novel mutations. *Eur J Neurol* 16, 727–732. doi:10.1111/j.1468-1331.2009.02574.x [PubMed: 19236453]
- Del Bo R, Tiloca C, Pensato V, Corrado L, Ratti A, Ticozzi N, Corti S, Castellotti B, Mazzini L, Soraru G, Cereda C, D'Alfonso S, Gellera C, Comi GP, Silani V, The SLAGEN Consortium, 2011 Novel optineurin mutations in patients with familial and sporadic amyotrophic lateral

sclerosis. *J Neurol Neurosurg Psychiatry* 82, 1239–1243. doi:10.1136/jnnp.2011.242313 [PubMed: 21613650]

- Deleon J, Miller BL, 2018 Frontotemporal dementia, in: *Handbook of Clinical Neurology*. Elsevier, pp. 409–430. doi:10.1016/B978-0-444-64076-5.00027-2
- Delisle MB, Murrell JR, Richardson R, Trofatter JA, Rascol O, Soulages X, Mohr M, Calvas P, Ghetti B, 1999 A mutation at codon 279 (N279K) in exon 10 of the Tau gene causes a tauopathy with dementia and supranuclear palsy. *Acta Neuropathol.* 98, 62–77. [PubMed: 10412802]
- Deng H-X, Chen W, Hong S-T, Boycott KM, Gorrie GH, Siddique N, Yang Y, Fecto F, Shi Y, Zhai H, Jiang H, Hirano M, Rampersaud E, Jansen GH, Donkervoort S, Bigio EH, Brooks BR, Ajroud K, Sufit RL, Haines JL, Mugnaini E, Pericak-Vance MA, Siddique T, 2011 Mutations in UBQLN2 cause dominant X-linked juvenile and adult-onset ALS and ALS/dementia. *Nature* 477, 211–215. doi:10.1038/nature10353 [PubMed: 21857683]
- Deters KD, Risacher SL, Farlow MR, Unverzagt FW, Kareken DA, Hutchins GD, Yoder KK, Murrell JR, Spina S, Epperson F, Gao S, Saykin AJ, Ghetti B, 2014 Cerebral hypometabolism and grey matter density in MAPT intron 10 +3 mutation carriers. *Am J Neurodegener Dis* 3, 103–114. [PubMed: 25628962]
- Devenney E, Foxe D, Dobson-Stone C, Kwok JB, Kiernan MC, Hodges JR, 2015 Clinical heterogeneity of the *C9orf72* genetic mutation in frontotemporal dementia. *Neurocase* 21, 535–541. doi:10.1080/13554794.2014.951058 [PubMed: 25138488]
- Devenney E, Hornberger M, Irish M, Mioshi E, Burrell J, Tan R, Kiernan MC, Hodges JR, 2014 Frontotemporal dementia associated with the *C9ORF72* mutation: a unique clinical profile. *JAMA Neurol* 71, 331. doi:10.1001/jamaneurol.2013.6002 [PubMed: 24445580]
- Dharmadasa T, Huynh W, Tsugawa J, Shimatani Y, Ma Y, Kiernan MC, 2018 Implications of structural and functional brain changes in amyotrophic lateral sclerosis. *Expert Rev Neurother* 18, 407–419. doi:10.1080/14737175.2018.1464912 [PubMed: 29667443]
- Diehl-Schmid J, Goldhardt O, Förstl H, Yakushew I, Otto M, Anderl-Straub S, Beer A, Ludolph AC, Landwehrmeyer GB, Levin J, Danek A, Fliessbach K, Spottke A, Fassbender K, Lyros E, Prudlo J, Krause BJ, Volk A, Edbauer D, Schroeter ML, Drzezga A, Kornhuber J, Lauer M, Grimmer T, Lauer M, Grimmer T, 2019 FDG-PET underscores the key role of the thalamus in frontotemporal lobar degeneration caused by C9ORF72 mutations. *Transl Psychiatry* 9. doi:10.1038/s41398-019-0381-1
- Diehl-Schmid J, Grimmer T, Drzezga A, Bornschein S, Riemenschneider M, Förstl H, Schwaiger M, Kurz A, 2007 Decline of cerebral glucose metabolism in frontotemporal dementia: a longitudinal 18F-FDG-PET-study. *Neurobiol Aging* 28, 42–50. doi:10.1016/j.neurobiolaging.2005.11.002 [PubMed: 16448722]
- Djamshidian A, Schaefer J, Haubenberger D, Stogmann E, Zimprich F, Auff E, Zimprich A, 2009 A novel mutation in the VCP gene (G157R) in a german family with inclusion-body myopathy with paget disease of bone and frontotemporal dementia. *Muscle Nerve* 39, 389–391. doi:10.1002/mus.21225 [PubMed: 19208399]
- Dols-Icardo O, Nebot I, Gorostidi A, Ortega-Cubero S, Hernández I, Rojas-García R, García-Redondo A, Povedano M, Lladó A, Álvarez V, Sánchez-Juan P, Pardo J, Jericó I, Vázquez-Costa J, Sevilla T, Cardona F, Indakoechea B, Moreno F, Fernández-Torrón R, Muñoz-Llahuna L, Moreno-Grau S, Rosende-Roca M, Vela Á, Muñoz-Blanco JL, Combarros O, Coto E, Alcolea D, Fortea J, Lleó A, Sánchez-Valle R, Esteban-Pérez J, Ruiz A, Pastor P, López De Munain A, Pérez-Tur J, Clarimón J, on behalf of the Dementia Genetics Spanish Consortium (DEGESCO), 2015 Analysis of the *CHCHD10* gene in patients with frontotemporal dementia and amyotrophic lateral sclerosis from Spain. *Brain* 138, e400–e400. doi:10.1093/brain/awv175 [PubMed: 26152333]
- Domínguez-Vivero C, Wu L, Lee S, Manoochehri M, Cines S, Brickman AM, Rizvi B, Chesebro A, Gazes Y, Fallon E, Lynch T, Heidebrink JL, Paulson H, Goldman JS, Huey E, Cosentino S, 2020 Structural brain changes in pre-clinical FTD MAPT mutation carriers. *J Alzheimers Dis* 1–12. doi:10.3233/JAD-190820
- Dopper EGP, Chalos V, Ghariq E, den Heijer T, Hafkemeijer A, Jiskoot LC, de Koning I, Seelaar H, van Minkelen R, van Osch MJP, Rombouts SARB, van Swieten JC, 2016 Cerebral blood flow in

- presymptomatic MAPT and GRN mutation carriers: A longitudinal arterial spin labeling study. *NeuroImage Clin* 12, 460–465. doi:10.1016/j.nicl.2016.08.001 [PubMed: 27625986]
- Dopper EGP, Rombouts SARB, Jiskoot LC, den Heijer T, de Graaf JRA, de Koning I, Hammerschlag AR, Seelaar H, Seeley WW, Veer IM, van Buchem MA, Rizzu P, van Swieten JC, 2014 Structural and functional brain connectivity in presymptomatic familial frontotemporal dementia. *Neurology* 83, e19–e26. doi:10.1212/WNL.0000000000000583 [PubMed: 25002573]
- Douaud G, Filippini N, Knight S, Talbot K, Turner MR, 2011 Integration of structural and functional magnetic resonance imaging in amyotrophic lateral sclerosis. *Brain* 134, 3470–3479. doi:10.1093/brain/awr279 [PubMed: 22075069]
- El Mendili M-M, Cohen-Adad J, Pelegrini-Issac M, Rossignol S, Morizot-Koutlidis R, Marchand-Pauvert V, Iglesias C, Sangari S, Katz R, Lehericy S, Benali H, Pradat P-F, 2014 Multi-parametric spinal cord MRI as potential progression marker in amyotrophic lateral sclerosis. *PLoS One* 9, e95516. doi:10.1371/journal.pone.0095516 [PubMed: 24755826]
- Elahi FM, Marx G, Cobigo Y, Staffaroni AM, Kornak J, Tosun D, Boxer AL, Kramer JH, Miller BL, Rosen HJ, 2017 Longitudinal white matter change in frontotemporal dementia subtypes and sporadic late onset Alzheimer's disease. *NeuroImage Clin* 16, 595–603. doi:10.1016/j.nicl.2017.09.007 [PubMed: 28975068]
- Eskildsen SF, Østergaard LR, Rodell AB, Østergaard L, Nielsen JE, Isaacs AM, Johannsen P, 2009 Cortical volumes and atrophy rates in FTD-3 CHMP2B mutation carriers and related non-carriers. *NeuroImage* 45, 713–721. doi:10.1016/j.neuroimage.2008.12.024 [PubMed: 19150504]
- Fahed AC, McDonough B, Gouvion CM, Newell KL, Dure LS, Bebin M, Bick AG, Seidman JG, Harter DH, Seidman CE, 2014 *UBQLN2* mutation causing heterogeneous X-linked dominant neurodegeneration. *Ann Neurol* 75, 793–798. doi:10.1002/ana.24164 [PubMed: 24771548]
- Fanganiello RD, Kimonis VE, Côrte CC, Nitrini R, Passos-Bueno MR, 2011 A Brazilian family with hereditary inclusion body myopathy associated with Paget disease of bone and frontotemporal dementia. *Braz J Med Biol Res* 44, 374–380. doi:10.1590/S0100-879X2011007500028 [PubMed: 21412659]
- Farb NAS, Grady CL, Strother S, Tang-Wai DF, Masellis M, Black S, Freedman M, Pollock BG, Campbell KL, Hasher L, Chow TW, 2013 Abnormal network connectivity in frontotemporal dementia: evidence for prefrontal isolation. *Cortex* 49, 1856–1873. doi:10.1016/j.cortex.2012.09.008 [PubMed: 23092697]
- Fecto F, 2011 SQSTM1 mutations in familial and sporadic amyotrophic lateral sclerosis. *Arch Neurol* 68, 1440. doi:10.1001/archneurol.2011.250 [PubMed: 22084127]
- Feng Shu-Man, Che C, Feng Shu-Yan, Liu C, Li L, Li Y, Huang H, Zou Z, 2019 Novel mutation in optineurin causing aggressive ALS+/-frontotemporal dementia. *Ann Clin Transl Neurol* 6, 2377–2383. doi:10.1002/acn3.50928 [PubMed: 31838784]
- Filippi M, Agosta F, Abrahams S, Fazekas F, Grosskreutz J, Kalra S, Kassubek J, Silani V, Turner MR, Masdeu JC, 2010 EFNS guidelines on the use of neuroimaging in the management of motor neuron diseases. *Eur J Neurol* 17, 526–e20. doi:10.1111/j.1468-1331.2010.02951.x [PubMed: 20136647]
- Filippi M, Agosta F, Scola E, Canu E, Magnani G, Marcone A, Valsasina P, Caso F, Copetti M, Comi G, Cappa SF, Falini A, 2013 Functional network connectivity in the behavioral variant of frontotemporal dementia. *Cortex* 49, 2389–2401. doi:10.1016/j.cortex.2012.09.017 [PubMed: 23164495]
- Floeter MK, Bageac D, Danielian LE, Braun LE, Traynor BJ, Kwan JY, 2016 Longitudinal imaging in C9orf72 mutation carriers: relationship to phenotype. *NeuroImage Clin* 12, 1035–1043. doi:10.1016/j.nicl.2016.10.014 [PubMed: 27995069]
- Floeter MK, Danielian LE, Braun LE, Wu T, 2018 Longitudinal diffusion imaging across the C9orf72 clinical spectrum. *J Neurol Neurosurg Psychiatry* 89, 53–60. doi:10.1136/jnnp-2017-316799 [PubMed: 29054917]
- Floris G, Borghero G, Cannas A, Di Stefano F, Murru MR, Corongiu D, Cuccu S, Tranquilli S, Cherchi MV, Serra A, Loi G, Marrosu MG, Chiò A, Marrosu F, 2015 Clinical phenotypes and radiological findings in frontotemporal dementia related to TARDBP mutations. *J Neurol* 262, 375–384. doi:10.1007/s00415-014-7575-5 [PubMed: 25408367]

- Freischmidt A, Wieland T, Richter B, Ruf W, Schaeffer V, Müller K, Marroquin N, Nordin F, Hübers A, Weydt P, Pinto S, Press R, Millicamps S, Molko N, Bernard E, Desnuelle C, Soriani M-H, Dorst J, Graf E, Nordström U, Feiler MS, Putz S, Boeckers TM, Meyer T, Winkler AS, Winkelman J, de Carvalho M, Thal DR, Otto M, Brännström T, Volk AE, Kursula P, Danzer KM, Lichtner P, Dikic I, Meitinger T, Ludolph AC, Strom TM, Andersen PM, Weishaupt JH, 2015 Haploinsufficiency of *TBK1* causes familial ALS and frontotemporal dementia. *Nat Neurosci* 18, 631–636. doi:10.1038/nn.4000 [PubMed: 25803835]
- Fu X, Zhu W, Guo Z, Shu G, Cui F, Yang F, Zhang Y, Ren Y, Zhang Xiaojun, Zhang Xiaolan, Chen Z, Ling L, Huang X, Zhang J, 2017 18 F-fallypride PET-CT of dopamine D2/D3 receptors in patients with sporadic amyotrophic lateral sclerosis. *J Neurol Sci* 377, 79–84. doi:10.1016/j.jns.2017.03.013 [PubMed: 28477714]
- Fumagalli GG, Basilico P, Arighi A, Bocchetta M, Dick KM, Cash DM, Harding S, Mercurio M, Fenoglio C, Pietroboni AM, Ghezzi L, van Swieten J, Borroni B, de Mendonça A, Masellis M, Tartaglia MC, Rowe JB, Graff C, Tagliavini F, Frisoni GB, Laforce R, Finger E, Sorbi S, Scarpini E, Rohrer JD, Galimberti D, Andersson C, Archetti S, Benussi L, Binetti G, Black S, Cosseddu M, Fallström M, Ferreira C, Fox NC, Freedman M, Gazzina S, Ghidoni R, Grisoli M, Jelic V, Jiskoot L, Keren R, Lombardi G, Maruta C, Mead S, Meeter L, van Minkelen R, Nacmias B, Öjjerstedt L, Ourselin S, Padovani A, Panman J, Pievani M, Polito C, Premi E, Prioni S, Rademakers R, Redaelli V, Rogaeva E, Rossi G, Rossor MN, Tang-Wai D, Thomas DL, Thonberg H, Tiraboschi P, Verdelho A, Warren JD, on behalf of the Genetic FTD Initiative (GENFI), 2018 Distinct patterns of brain atrophy in Genetic Frontotemporal Dementia Initiative (GENFI) cohort revealed by visual rating scales. *Alzheimers Res Ther* 10, 46. doi:10.1186/s13195-018-0376-9 [PubMed: 29793546]
- Gazzina S, Benussi A, Premi E, Paternicò D, Cristillo V, Dell’Era V, Cosseddu M, Archetti S, Alberici A, Gasparotti R, Padovani A, Borroni B, 2018 Neuroanatomical correlates of transcranial magnetic stimulation in presymptomatic granulin mutation carriers. *Brain Topogr* 31, 488–497. doi:10.1007/s10548-017-0612-9 [PubMed: 29256051]
- Gellera C, Tiloca C, Del Bo R, Corrado L, Pensato V, Agostini J, Cereda C, Ratti A, Castellotti B, Corti S, Bagarotti A, Cagnin A, Milani P, Gabelli C, Riboldi G, Mazzini L, Sorarù G, D’Alfonso S, Taroni F, Comi GP, Ticozzi N, Silani V, Consortium TS, 2013 *Ubiquilin 2* mutations in Italian patients with amyotrophic lateral sclerosis and frontotemporal dementia. *J Neurol Neurosurg Psychiatry* 84, 183–187. doi:10.1136/jnnp-2012-303433 [PubMed: 23138764]
- Gelpi E, van der Zee J, Turon Estrada A, Van Broeckhoven C, Sanchez-Valle R, 2014 *TARDBP* mutation p.Ile383Val associated with semantic dementia and complex proteinopathy. *Neuropathol Appl Neurobiol* 40, 225–230. doi:10.1111/nan.12063 [PubMed: 23692129]
- Ghetti B, Oblak AL, Boeve BF, Johnson KA, Dickerson BC, Goedert M, 2015 Invited review: Frontotemporal dementia caused by microtubule-associated protein tau gene (*MAPT*) mutations: a chameleon for neuropathology and neuroimaging: *MAPT* mutations and FTD. *Neuropathol Appl Neurobiol* 41, 24–46. doi:10.1111/nan.12213 [PubMed: 25556536]
- Ghetti B, Wszolek ZK, Boeve BF, Spina S, Goedert M, 2011 Frontotemporal Dementia and Parkinsonism Linked to Chromosome 17, in: Dickson DW, Weller RO (Eds.), *Neurodegeneration: The Molecular Pathology of Dementia and Movement Disorders*. Wiley-Blackwell, Oxford, UK, pp. 110–134. doi:10.1002/9781444341256.ch14
- Gijssels I, Van Mossevelde S, van der Zee J, Sieben A, Philtjens S, Heeman B, Engelborghs S, Vandenbulcke M, De Baets G, Bäumer V, Cuijt I, Van den Broeck M, Peeters K, Mattheijssens M, Rousseau F, Vandenbergh R, De Jonghe P, Cras P, De Deyn PP, Martin J-J, Cruts M, Van Broeckhoven C, 2015 Loss of *TBK1* is a frequent cause of frontotemporal dementia in a Belgian cohort. *Neurology* 85, 2116–2125. doi:10.1212/WNL.0000000000002220 [PubMed: 26581300]
- Giraldo M, Lopera F, Siniard AL, Corneveaux JJ, Schrauwen I, Carvajal J, Muñoz C, Ramirez-Restrepo M, Gaiteri C, Myers AJ, Caselli RJ, Kosik KS, Reiman EM, Huentelman MJ, 2013 Variants in triggering receptor expressed on myeloid cells 2 are associated with both behavioral variant frontotemporal lobar degeneration and Alzheimer’s disease. *Neurobiol Aging* 34, 2077.e11–2077.e18. doi:10.1016/j.neurobiolaging.2013.02.016
- Gómez-Tortosa E, Serrano S, de Toledo M, Pérez-Pérez J, Sainz MJ, 2014 Familial benign frontotemporal deterioration with C9ORF72 hexanucleotide expansion. *Alzheimers Dement* 10, S284–S289. doi:10.1016/j.jalz.2013.09.013 [PubMed: 24439166]

- González-Sánchez M, Puertas-Martín V, Esteban-Pérez J, García-Redondo A, Borrego-Hernández D, Méndez-Guerrero A, Llamas-Velasco S, Herrero-San Martín A, Cordero-Vázquez P, Herrero-Manso MC, Pérez-Martínez DA, Villarejo-Galende A, 2018 TARDBP mutation associated with semantic variant primary progressive aphasia, case report and review of the literature. *Neurocase* 24, 301–305. doi:10.1080/13554794.2019.1581225 [PubMed: 30773994]
- Goode A, Layfield R, 2010 Recent advances in understanding the molecular basis of Paget disease of bone. *J Clin Pathol* 63, 199–203. doi:10.1136/jcp.2009.064428 [PubMed: 19858527]
- Gorno-Tempini ML, Dronkers NF, Rankin KP, Ogar JM, Phengrasamy L, Rosen HJ, Johnson JK, Weiner MW, Miller BL, 2004 Cognition and anatomy in three variants of primary progressive aphasia. *Ann Neurol* 55, 335–346. doi:10.1002/ana.10825 [PubMed: 14991811]
- Gorno-Tempini ML, Hillis AE, Weintraub S, Kertesz A, Mendez M, Cappa SF, Ogar JM, Rohrer JD, Black S, Boeve BF, Manes F, Dronkers NF, Vandenberghe R, Rascovsky K, Patterson K, Miller BL, Knopman DS, Hodges JR, Mesulam MM, Grossman M, 2011 Classification of primary progressive aphasia and its variants. *Neurology* 76, 1006–1014. doi:10.1212/WNL.0b013e31821103e6 [PubMed: 21325651]
- Greaves CV, Rohrer JD, 2019 An update on genetic frontotemporal dementia. *J Neurol* 266, 2075–2086. doi:10.1007/s00415-019-09363-4 [PubMed: 31119452]
- Greicius MD, Srivastava G, Reiss AL, Menon V, 2004 Default-mode network activity distinguishes Alzheimer's disease from healthy aging: Evidence from functional MRI. *Proc Natl Acad Sci U S A* 101, 4637–4642. doi:10.1073/pnas.0308627101 [PubMed: 15070770]
- Grieve SM, Menon P, Korgaonkar MS, Gomes L, Foster S, Kiernan MC, Vucic S, 2016 Potential structural and functional biomarkers of upper motor neuron dysfunction in ALS. *Amyotroph Lateral Scler Frontotemporal Degener* 17, 85–92. doi:10.3109/21678421.2015.1074707
- Grosskreutz J, Kaufmann J, Frädriich J, Dengler R, Heinze H-J, Peschel T, 2006 Widespread sensorimotor and frontal cortical atrophy in Amyotrophic Lateral Sclerosis. *BMC Neurol* 6, 17. doi:10.1186/1471-2377-6-17 [PubMed: 16638121]
- Grossman M, Mickanin J, Onishi K, Hughes E, D'Esposito M, Ding X-S, Alavi A, Reivich M, 1996 Progressive nonfluent aphasia: language, cognitive, and PET measures contrasted with probable Alzheimer's disease. *J Cogn Neurosci* 8, 135–154. doi:10.1162/jocn.1996.8.2.135 [PubMed: 23971420]
- Guerreiro RJ, Lohmann E, Brás JM, Gibbs JR, Rohrer JD, Gurunlian N, Dursun B, Bilgic B, Hanagasi H, Gurvit H, Emre M, Singleton A, Hardy J, 2013 Using exome sequencing to reveal mutations in TREM2 presenting as a frontotemporal dementia-like syndrome without bone involvement. *JAMA Neurol* 70, 78–84. doi:10.1001/jamaneurol.2013.579 [PubMed: 23318515]
- Guo CC, Gorno-Tempini ML, Gesierich B, Henry M, Trujillo A, Shany-Ur T, Jovicich J, Robinson SD, Kramer JH, Rankin KP, Miller BL, Seeley WW, 2013 Anterior temporal lobe degeneration produces widespread network-driven dysfunction. *Brain* 136, 2979–2991. doi:10.1093/brain/awt222 [PubMed: 24072486]
- Gydesen S, Brown JM, Brun A, Chakrabarti L, Gade A, Johannsen P, Rossor M, Thusgaard T, Grove A, Yancopoulou D, Spillantini MG, Fisher EMC, Collinge J, Sorensen SA, 2002 Chromosome 3 linked frontotemporal dementia (FTD-3). *Neurology* 59, 1585–1594. doi:10.1212/01.WNL.0000034763.54161.1F [PubMed: 12451202]
- Hafkemeijer A, Möller C, Dopper EGP, Jiskoot LC, Schouten TM, van Swieten JC, van der Flier WM, Vrenken H, Pijnenburg YAL, Barkhof F, Scheltens P, van der Grond J, Rombouts SARB, 2015 Resting state functional connectivity differences between behavioral variant frontotemporal dementia and Alzheimer's disease. *Front Hum Neurosci* 9, 474. doi:10.3389/fnhum.2015.00474 [PubMed: 26441584]
- Hanstock C, Sun K, Choi C, Eurich D, Camicioli R, Johnston W, Kalra S, 2020 Spectroscopic markers of neurodegeneration in the mesial prefrontal cortex predict survival in ALS. *Amyotroph Lateral Scler Frontotemporal Degener* 1–6. doi:10.1080/21678421.2020.1727926
- Hatazawa J, Brooks RA, Dalakas MC, Mansi L, Chiro GD, 1988 Cortical motor-sensory hypometabolism in amyotrophic lateral sclerosis: a PET study. *J Comput Assist Tomogr* 12, 630–636. doi:10.1097/00004728-198807000-00019 [PubMed: 3260610]

- Henry JD, Phillips LH, von Hippel C, 2014 A meta-analytic review of theory of mind difficulties in behavioural-variant frontotemporal dementia. *Neuropsychologia* 56, 53–62. doi:10.1016/j.neuropsychologia.2013.12.024 [PubMed: 24412701]
- Hirano M, Nakamura Y, Saigoh K, Sakamoto H, Ueno S, Isono C, Mitsui Y, Kusunoki S, 2015 VCP gene analyses in Japanese patients with sporadic amyotrophic lateral sclerosis identify a new mutation. *Neurobiol Aging* 36, 1604.e1–1604.e6. doi:10.1016/j.neurobiolaging.2014.10.012
- Hirano M, Yamagishi Y, Yanagimoto S, Saigoh K, Nakamura Y, Kusunoki S, 2017 Time course of radiological imaging and variable interindividual symptoms in amyotrophic lateral sclerosis and frontotemporal dementia associated with p.Arg487His mutation in the *VCP* gene. *Eur Neurol* 78, 78–83. doi:10.1159/000478906 [PubMed: 28738334]
- Hirsch-Reinshagen V, Alfaify OA, Hsiung G-YR, Pottier C, Baker M, Perkerson RB, Rademakers R, Briemberg H, Foti DJ, Mackenzie IR, 2019 Clinicopathologic correlations in a family with a *TBK1* mutation presenting as primary progressive aphasia and primary lateral sclerosis. *Amyotroph Lateral Scler Frontotemporal Degener* 20, 568–575. doi:10.1080/21678421.2019.1632347 [PubMed: 31244341]
- Hjerpe R, Bett JS, Keuss MJ, Solovyova A, McWilliams TG, Johnson C, Sahu I, Varghese J, Wood N, Wightman M, Osborne G, Bates GP, Glickman MH, Trost M, Knebel A, Marchesi F, Kurz T, 2016 UBQLN2 mediates autophagy-independent protein aggregate clearance by the proteasome. *Cell* 166, 935–949. doi:10.1016/j.cell.2016.07.001 [PubMed: 27477512]
- Hodges JR, Patterson K, 1996 Nonfluent progressive aphasia and semantic dementia: a comparative neuropsychological study. *J Int Neuropsychol Soc* 2, 511–524. doi:10.1017/S1355617700001685 [PubMed: 9375155]
- Huey ED, Ferrari R, Moreno JH, Jensen C, Morris CM, Potocnik F, Kalaria RN, Tierney M, Wassermann EM, Hardy J, Grafman J, Momeni P, 2012 FUS and TDP43 genetic variability in FTD and CBS. *Neurobiol Aging* 33, 1016.e9–1016.e17. doi:10.1016/j.neurobiolaging.2011.08.004
- Huey ED, Grafman J, Wassermann EM, Pietrini P, Tierney MC, Ghetti B, Spina S, Baker M, Hutton M, Elder JW, Berger SL, Heflin KA, Hardy J, Momeni P, 2006 Characteristics of frontotemporal dementia patients with a *Progranulin* mutation. *Ann Neurol* 60, 374–380. doi:10.1002/ana.20969 [PubMed: 16983677]
- Hutton M, Lendon CL, Rizzu P, Baker M, Froelich S, Houlden H, Pickering-Brown S, Chakraverty S, Isaacs A, Grover A, Hackett J, Adamson J, Lincoln S, Dickson D, Davies P, Petersen RC, Stevens M, de Graaff E, Wauters E, van Baren J, Hillebrand M, Joosse M, Kwon JM, Nowotny P, Che LK, Norton J, Morris JC, Reed LA, Trojanowski J, Basun H, Lannfelt L, Neystat M, Fahn S, Dark F, Tannenber T, Dodd PR, Hayward N, Kwok JB, Schofield PR, Andreadis A, Snowden J, Craufurd D, Neary D, Owen F, Oostra BA, Hardy J, Goate A, van Swieten J, Mann D, Lynch T, Heutink P, 1998 Association of missense and 5'-splice-site mutations in tau with the inherited dementia FTDP-17. *Nature* 393, 702–705. doi:10.1038/31508 [PubMed: 9641683]
- Iijima M, Tabira T, Poorkaj P, Schellenberg G, Trojanowski J, Lee V, Schmidt M, Takahashi K, Nabika T, Matsumoto T, Yamashita Y, Yoshioka S, Ishino H, 1999 A distinct familial presenile dementia with a novel missense mutation in the tau gene. *Neuroreport* 10, 497–501. [PubMed: 10208578]
- Ikawa M, Okazawa H, Tsujikawa T, Matsunaga A, Yamamura O, Mori T, Hamano T, Kiyono Y, Nakamoto Y, Yoneda M, 2015 Increased oxidative stress is related to disease severity in the ALS motor cortex: A PET study. *Neurology* 84, 2033–2039. doi:10.1212/WNL.0000000000001588 [PubMed: 25904686]
- Ikeda K, Murata K, Kawase Y, Kawabe K, Kano O, Yoshii Y, Takazawa T, Hirayama T, Iwasaki Y, 2013 Relationship between cervical cord ¹H-magnetic resonance spectroscopy and clinico-electromyographic profile in amyotrophic lateral sclerosis. *Muscle Nerve* 47, 61–67. doi:10.1002/mus.23467 [PubMed: 23042532]
- Ince PG, Tomkins J, Slade JY, Thatcher NM, Shaw PJ, 1998 Amyotrophic lateral sclerosis associated with genetic abnormalities in the gene encoding Cu/Zn superoxide dismutase: molecular pathology of five new cases, and comparison with previous reports and 73 sporadic cases of ALS. *J Neuropath Exp Neur* 57, 895–904. doi:10.1097/00005072-199810000-00002 [PubMed: 9786240]

- Irwin DJ, McMillan CT, Brettschneider J, Libon DJ, Powers J, Rascovsky K, Toledo JB, Boller A, Bekisz J, Chandrasekaran K, Wood EM, Shaw LM, Woo JH, Cook PA, Wolk DA, Arnold SE, Van Deerlin VM, McCluskey LF, Elman L, Lee VM-Y, Trojanowski JQ, Grossman M, 2013 Cognitive decline and reduced survival in *C9orf72* expansion frontotemporal degeneration and amyotrophic lateral sclerosis. *J Neurol Neurosurg Psychiatry* 84, 163–169. doi:10.1136/jnnp-2012-303507 [PubMed: 23117491]
- Isaacs AM, Johannsen P, Holm I, Nielsen E, J., Consortium, Fr., 2011 Frontotemporal dementia caused by CHMP2B mutations. *Curr Alzheimer Res* 8, 246–251. doi:10.2174/156720511795563764 [PubMed: 21222599]
- Ito H, Nakamura M, Komure O, Ayaki T, Wate R, Maruyama H, Nakamura Y, Fujita K, Kaneko S, Okamoto Y, Ihara M, Konishi T, Ogasawara K, Hirano A, Kusaka H, Kaji R, Takahashi R, Kawakami H, 2011 Clinicopathologic study on an ALS family with a heterozygous E478G optineurin mutation. *Acta Neuropathol* 122, 223–229. doi:10.1007/s00401-011-0842-y [PubMed: 21644038]
- Jacova C, Hsiung G-YR, Tawankanjanachot I, Dinelle K, McCormick S, Gonzalez M, Lee H, Sengdy P, Bouchard-Kerr P, Baker M, Rademakers R, Sossi V, Stoessl AJ, Feldman HH, Mackenzie IR, 2013 Anterior brain glucose hypometabolism predates dementia in progranulin mutation carriers. *Neurology* 81, 1322–1331. doi:10.1212/WNL.0b013e3182a8237e [PubMed: 24005336]
- Janssen JC, Warrington EK, Morris HR, Lantos P, Brown J, Revesz T, Wood N, Khan MN, Cipolotti L, Fox NC, Rossor MN, 2002 Clinical features of frontotemporal dementia due to the intronic *tau* 10⁺¹⁶ mutation. *Neurology* 58, 1161–1168. doi:10.1212/WNL.58.8.1161 [PubMed: 11971081]
- Jiao B, Sun Q, Yuan Z, Wang J, Zhou L, Yan X, Tang B, Shen L, 2018 Rare TBK1 variants in patients with frontotemporal dementia and amyotrophic lateral sclerosis in a Chinese cohort. *Transl Neurodegener* 7, 31. doi:10.1186/s40035-018-0136-6 [PubMed: 30534373]
- Jiao B, Xiao T, Hou L, Gu X, Zhou Y, Zhou L, Tang B, Xu J, Shen L, 2016 High prevalence of *CHCHD10* mutation in patients with frontotemporal dementia from China. *Brain* 139, e21–e21. doi:10.1093/brain/awv367 [PubMed: 26719383]
- Jiskoot LC, Bocchetta M, Nicholas JM, Cash DM, Thomas D, Modat M, Ourselin S, Rombouts SARB, Dopper EGP, Meeter LH, Panman JL, van Minkelen R, van der Ende EL, Donker Kaat L, Pijnenburg YAL, Borroni B, Galimberti D, Masellis M, Tartaglia MC, Rowe J, Graff C, Tagliavini F, Frisoni GB, Laforce R, Finger E, de Mendonça A, Sorbi S, on behalf of the Genetic Frontotemporal dementia Initiative (GENFI), Papma JM, van Swieten JC, Rohrer JD, 2018 Presymptomatic white matter integrity loss in familial frontotemporal dementia in the GENFI cohort: a cross-sectional diffusion tensor imaging study. *Ann Clin Transl Neurol* 5, 1025–1036. doi:10.1002/acn3.601 [PubMed: 30250860]
- Jiskoot LC, Panman JL, Meeter LH, Dopper EGP, Donker Kaat L, Franzen S, van der Ende EL, van Minkelen R, Rombouts SARB, Papma JM, van Swieten JC, 2019 Longitudinal multimodal MRI as prognostic and diagnostic biomarker in presymptomatic familial frontotemporal dementia. *Brain* 142, 193–208. doi:10.1093/brain/awy288 [PubMed: 30508042]
- Johnson JO, Mandrioli J, Benatar M, Abramzon Y, Van Deerlin VM, Trojanowski JQ, Gibbs JR, Brunetti M, Gronka S, Wu J, Ding J, McCluskey L, Martinez-Lage M, Falcone D, Hernandez DG, Arepalli S, Chong S, Schymick JC, Rothstein J, Landi F, Wang Y-D, Calvo A, Mora G, Sabatelli M, Monsurro MR, Battistini S, Salvi F, Spataro R, Sola P, Borghero G, Galassi G, Scholz SW, Taylor JP, Restagno G, Chiò A, Traynor BJ, 2010 Exome sequencing reveals VCP mutations as a cause of familial ALS. *Neuron* 68, 857–864. doi:10.1016/j.neuron.2010.11.036 [PubMed: 21145000]
- Jones DT, Knopman DS, Graff-Radford J, Syrjanen JA, Senjem ML, Schwarz CG, Dheel C, Wszolek Z, Rademakers R, Kantarci K, Petersen RC, Jack CR, Lowe VJ, Boeve BF, 2018 In vivo 18 F-AV-1451 tau PET signal in MAPT mutation carriers varies by expected tau isoforms. *Neurology* 90, e947–e954. doi:10.1212/WNL.0000000000005117 [PubMed: 29440563]
- Josephs KA, Whitwell JL, Jack CR, 2008 Anatomic correlates of stereotypies in frontotemporal lobar degeneration. *Neurobiol Aging* 29, 1859–1863. doi:10.1016/j.neurobiolaging.2007.04.027 [PubMed: 17574708]

- Kaivorinne A-L, Bode MK, Paavola L, Tuominen H, Kallio M, Renton AE, Traynor BJ, Moilanen V, Remes AM, 2013 Clinical characteristics of C9ORF72-linked frontotemporal lobar degeneration. *Dement Geriatr Cogn Disord Extra* 3, 251–262. doi:10.1159/000351859
- Kamada M, Izumi Y, Ayaki T, Nakamura M, Kagawa S, Kudo E, Sako W, Maruyama H, Nishida Y, Kawakami H, Ito H, Kaji R, 2014 Clinicopathologic features of autosomal recessive amyotrophic lateral sclerosis associated with optineurin mutation: Autosomal recessive OPTN-ALS. *Neuropathology* 34, 64–70. doi:10.1111/neup.12051 [PubMed: 23889540]
- Kantarci K, Boeve BF, Wszolek ZK, Rademakers R, Whitwell JL, Baker MC, Senjem ML, Samikoglu AR, Knopman DS, Petersen RC, Jack CR, 2010 MRS in presymptomatic MAPT mutation carriers: a potential biomarker for tau-mediated pathology. *Neurology* 75, 771–778. doi:10.1212/WNL.0b013e3181f073c7 [PubMed: 20805522]
- Kao AW, McKay A, Singh PP, Brunet A, Huang EJ, 2017 Progranulin, lysosomal regulation and neurodegenerative disease. *Nat Rev Neurosci* 18, 325–333. doi:10.1038/nrn.2017.36 [PubMed: 28435163]
- Karch CM, Wen N, Fan CC, Yokoyama JS, Kouri N, Ross OA, Höglinger G, Müller U, Ferrari R, Hardy J, Schellenberg GD, Sleiman PM, Momeni P, Hess CP, Miller BL, Sharma M, Van Deerlin V, Smeland OB, Andreassen OA, Dale AM, Desikan RS, for the International Frontotemporal Dementia (FTD)–Genomics Consortium, International Collaboration for Frontotemporal Dementia, Progressive Supranuclear Palsy (PSP) Genetics Consortium, and International Parkinson’s Disease Genomics Consortium, 2018 Selective genetic overlap between amyotrophic lateral sclerosis and diseases of the frontotemporal dementia spectrum. *JAMA Neurol* 75, 860–875. doi:10.1001/jamaneurol.2018.0372 [PubMed: 29630712]
- Kew JJM, Goldstein LH, Leigh PN, Abrahams S, Cosgrave N, Passingham RE, Frackowiak RSJ, Brooks DJ, 1993 The relationship between abnormalities of cognitive function and cerebral activation in amyotrophic lateral sclerosis: A neuropsychological and positron emission tomography study. *Brain* 116, 1399–1423. doi:10.1093/brain/116.6.1399 [PubMed: 8293278]
- Khan BK, Yokoyama JS, Takada LT, Sha SJ, Rutherford NJ, Fong JC, Karydas AM, Wu T, Kettle RS, Baker MC, Hernandez M-D, Coppola G, Geschwind DH, Rademakers R, Lee SE, Rosen HJ, Rabinovici GD, Seeley WW, Rankin KP, Boxer AL, Miller BL, 2012 Atypical, slowly progressive behavioural variant frontotemporal dementia associated with *C9ORF72* hexanucleotide expansion. *J Neurol Neurosurg Psychiatry* 83, 358–364. doi:10.1136/jnnp-2011-301883 [PubMed: 22399793]
- Kim E-J, Park Y-E, Kim D-S, Ahn B-Y, Kim H-S, Chang YH, Kim S-J, Kim H-J, Lee H-W, Seeley WW, Kim S, 2011 Inclusion body myopathy with Paget disease of bone and frontotemporal dementia linked to VCP p.Arg155Cys in a Korean family. *Arch Neurol* 68, 787–796. doi:10.1001/archneurol.2010.376 [PubMed: 21320982]
- Kim E-J, Sidhu M, Gaus SE, Huang EJ, Hof PR, Miller BL, DeArmond SJ, Seeley WW, 2012 Selective fronto-insular von Economo neuron and fork cell loss in early behavioral variant frontotemporal dementia. *Cereb Cortex* 22, 251–259. doi:10.1093/cercor/bhr004 [PubMed: 21653702]
- Kimonis VE, Watts GDJ, 2005 Autosomal dominant inclusion body myopathy, Paget disease of bone, and frontotemporal dementia. *Alzheimer Dis Assoc Disord* 19, S44–S47. doi:10.1097/01.wad.0000183081.76820.5a [PubMed: 16317258]
- Kimonis Virginia.E., Mehta SG, Fulchiero EC, Thomasova D, Pasquali M, Boycott K, Neilan EG, Kartashov A, Forman MS, Tucker S, Kimonis K, Mumm S, Whyte MP, Smith CD, Watts GDJ, 2008 Clinical studies in familial VCP myopathy associated with Paget disease of bone and frontotemporal dementia. *Am J Med Genet A* 146A, 745–757. doi:10.1002/ajmg.a.31862 [PubMed: 18260132]
- Klünemann HH, Ridha BH, Magy L, Wherrett JR, Hemelsoet DM, Keen RW, De Bleecker JL, Rossor MN, Marienhagen J, Klein HE, Peltonen L, Paloneva J, 2005 The genetic causes of basal ganglia calcification, dementia, and bone cysts: DAP12 and TREM2. *Neurology* 64, 1502–1507. doi:10.1212/01.WNL.0000160304.00003.CA [PubMed: 15883308]
- Konrad C, Jansen A, Henningsen H, Sommer J, Turski PA, Brooks BR, Knecht S, 2006 Subcortical reorganization in amyotrophic lateral sclerosis. *Exp Brain Res* 172, 361–369. doi:10.1007/s00221-006-0352-7 [PubMed: 16463149]

- Koppers M, van Blitterswijk MM, Vlam L, Rowicka PA, van Vught PWJ, Groen EJM, Spliet WGM, Engelen-Lee J, Schelhaas HJ, de Visser M, van der Kooij AJ, van der Pol W-L, Pasterkamp RJ, Veldink JH, van den Berg LH, 2012 VCP mutations in familial and sporadic amyotrophic lateral sclerosis. *Neurobiol Aging* 33, 837.e7–837.e13. doi:10.1016/j.neurobiolaging.2011.10.006
- Koriath CAM, Bocchetta M, Brotherhood E, Woollacott IOC, Norsworthy P, Simón-Sánchez J, Blauwendraat C, Dick KM, Gordon E, Harding SR, Fox NC, Crutch S, Warren JD, Revesz T, Lashley T, Mead S, Rohrer JD, 2017 The clinical, neuroanatomical, and neuropathologic phenotype of *TBKI*-associated frontotemporal dementia: a longitudinal case report. *Alzheimers Dement (Amst)* 6, 75–81. doi:10.1016/j.dadm.2016.10.003 [PubMed: 28229125]
- Kotan D, Iskender C, Ozoguz Erimis A, Basak AN, 2016 A Turkish Family with a Familial ALS-positive UBQLN2-S340I Mutation. *Arch Neuropsychiatr* 53, 283–285. doi:10.5152/npa.2016.12371
- Kovach MJ, Waggoner B, Leal SM, Gelber D, Khardori R, Levenstien MA, Shanks CA, Gregg G, Al-Lozi MT, Miller T, Rakowicz W, Lopate G, Florence J, Glosser G, Simmons Z, Morris JC, Whyte MP, Pestronk A, Kimonis VE, 2001 Clinical delineation and localization to chromosome 9p13.3-p12 of a unique dominant disorder in four families: hereditary inclusion body myopathy, Paget disease of bone, and frontotemporal dementia. *Mol Genet Metab* 74, 458–475. doi:10.1006/mgme.2001.3256 [PubMed: 11749051]
- Kovacs GG, Murrell JR, Horvath S, Haraszti L, Majtenyi K, Molnar MJ, Budka H, Ghetti B, Spina S, 2009 TARDBP variation associated with frontotemporal dementia, supranuclear gaze palsy, and chorea. *Mov Disord* 24, 1842–1847. doi:10.1002/mds.22697
- Kovacs GG, van der Zee J, Hort J, Kristoferitsch W, Leitha T, Höftberger R, Ströbel T, Van Broeckhoven C, Matej R, 2016 Clinicopathological description of two cases with *SQSTM1* gene mutation associated with frontotemporal dementia: clinicopathology of *SQSTM1* gene mutations. *Neuropathology* 36, 27–38. doi:10.1111/neup.12233 [PubMed: 26234378]
- Krause S, Göhringer T, Walter MC, Schoser BGH, Reilich P, Linn J, Pöpperl GE, Frölich L, Hentschel F, Lochmüller H, Danek A, 2007 Brain imaging and neuropsychology in late-onset dementia due to a novel mutation (R93C) of valosin-containing protein. *Clin Neuropathol* 26, 232–240. doi:10.5414/NPP26232 [PubMed: 17907600]
- Kumar V, Islam A, Hassan Md.I., Ahmad F, 2016 Delineating the relationship between amyotrophic lateral sclerosis and frontotemporal dementia: Sequence and structure-based predictions. *Biochim Biophys Acta* 1862, 1742–1754. doi:10.1016/j.bbadis.2016.06.011 [PubMed: 27318084]
- Kumfor F, Landin-Romero R, Devenney E, Hutchings R, Grasso R, Hodges JR, Piguet O, 2016 On the right side? A longitudinal study of left- versus right-lateralized semantic dementia. *Brain* 139, 986–998. doi:10.1093/brain/awv387 [PubMed: 26811253]
- Kwiatkowski TJ, Bosco DA, LeClerc AL, Tamrazian E, Vandenburg CR, Russ C, Davis A, Gilchrist J, Kasarskis EJ, Munsat T, Valdmanis P, Rouleau GA, Hosler BA, Cortelli P, de Jong PJ, Yoshinaga Y, Haines JL, Pericak-Vance MA, Yan J, Ticozzi N, Siddique T, McKenna-Yasek D, Sapp PC, Horvitz HR, Landers JE, Brown RH, 2009 Mutations in the FUS/TLS gene on chromosome 16 cause familial amyotrophic lateral sclerosis. *Science* 323, 1205–1208. doi:10.1126/science.1166066 [PubMed: 19251627]
- Lam BYK, Halliday GM, Irish M, Hodges JR, Piguet O, 2014 Longitudinal white matter changes in frontotemporal dementia subtypes. *Hum Brain Mapp* 35, 3547–3557. doi:10.1002/hbm.22420 [PubMed: 25050433]
- Lamb R, Rohrer JD, Real R, Lubbe SJ, Waite AJ, Blake DJ, Walters RJ, Lashley T, Revesz T, Holton JL, Morris HR, 2019 A novel *TBKI* mutation in a family with diverse frontotemporal dementia spectrum disorders. *Cold Spring Harb Mol Case Stud* 5, a003913. doi:10.1101/mcs.a003913 [PubMed: 31160356]
- Lant SB, Robinson AC, Thompson JC, Rollinson S, Pickering-Brown S, Snowden JS, Davidson YS, Gerhard A, Mann DMA, 2014 Patterns of microglial cell activation in frontotemporal lobar degeneration: Microglia and frontotemporal lobar degeneration. *Neuropathol Appl Neurobiol* 40, 686–696. doi:10.1111/nan.12092 [PubMed: 24117616]
- Lattante S, Le Ber I, Camuzat A, Dayan S, Godard C, Van Bortel I, De Septenville A, Ciura S, Brice A, Kabashi E, 2013a TREM2 mutations are rare in a French cohort of patients with

- frontotemporal dementia. *Neurobiol Aging* 34, 2443.e1–2443.e2. doi:10.1016/j.neurobiolaging.2013.04.030 [PubMed: 23759145]
- Lattante S, Rouleau GA, Kabashi E, 2013b *TARDBP* and *FUS* mutations associated with amyotrophic lateral sclerosis: summary and update. *Hum Mutat* 34, 812–826. doi:10.1002/humu.22319 [PubMed: 23559573]
- Le Ber I, 2013 *SQSTM1* mutations in French patients with frontotemporal dementia or frontotemporal dementia with amyotrophic lateral sclerosis. *JAMA Neurol* 70, 1403–1410. doi:10.1001/jamaneurol.2013.3849 [PubMed: 24042580]
- Le Ber I, Camuzat A, Hannequin D, Pasquier F, Guedj E, Rovelet-Lecrux A, Hahn-Barma V, van der Zee J, Clot F, Bakchine S, Puel M, Ghanim M, Lacomblez L, Mikol J, Deramecourt V, Lejeune P, de la Sayette V, Belliard S, Vercelletto M, Meyrignac C, Van Broeckhoven C, Lambert J-C, Verpillat P, Champion D, Habert M-O, Dubois B, Brice A, 2008 Phenotype variability in progranulin mutation carriers: a clinical, neuropsychological, imaging and genetic study. *Brain* 131, 732–746. doi:10.1093/brain/awn012 [PubMed: 18245784]
- Le Ber I, De Septenville A, Guerreiro R, Bras J, Camuzat A, Caroppo P, Lattante S, Couarch P, Kabashi E, Bouya-Ahmed K, Dubois B, Brice A, 2014 Homozygous *TREM2* mutation in a family with atypical frontotemporal dementia. *Neurobiol Aging* 35, 2419.e23–2419.e25. doi:10.1016/j.neurobiolaging.2014.04.010
- Le Blanc G, Jetté Pomerleau V, McCarthy J, Borroni B, van Swieten J, Galimberti D, Sanchez-Valle R, LaForce R, Moreno F, Synofzik M, Graff C, Masellis M, Tartaglia MC, Rowe JB, Vandenberghe R, Finger E, Tagliavini F, de Mendonça A, Santana I, Butler C, Gerhard A, Danek A, Levin J, Otto M, Frisoni G, Sorbi S, Rohrer JD, Ducharme S, GENetic Frontotemporal dementia Initiative (GENFI), 2020 Faster cortical thinning and surface area loss in presymptomatic and symptomatic *C9orf72* repeat expansion adult carriers. *Ann Neurol*. doi:10.1002/ana.25748
- Lee SE, Khazenzon AM, Trujillo AJ, Guo CC, Yokoyama JS, Sha SJ, Takada LT, Karydas AM, Block NR, Coppola G, Pribadi M, Geschwind DH, Rademakers R, Fong JC, Weiner MW, Boxer AL, Kramer JH, Rosen HJ, Miller BL, Seeley WW, 2014 Altered network connectivity in frontotemporal dementia with *C9orf72* hexanucleotide repeat expansion. *Brain* 137, 3047–3060. doi:10.1093/brain/awu248 [PubMed: 25273996]
- Lee SE, Sias AC, Kosik EL, Flagan TM, Deng J, Chu SA, Brown JA, Vidovszky AA, Ramos EM, Gorno-Tempini ML, Karydas AM, Coppola G, Geschwind DH, Rademakers R, Boeve BF, Boxer AL, Rosen HJ, Miller BL, Seeley WW, 2019 Thalamo-cortical network hyperconnectivity in preclinical progranulin mutation carriers. *NeuroImage Clin* 22, 101751. doi:10.1016/j.nicl.2019.101751 [PubMed: 30921613]
- Lee SE, Sias AC, Mandelli ML, Brown JA, Brown AB, Khazenzon AM, Vidovszky AA, Zanto TP, Karydas AM, Pribadi M, Dokuru D, Coppola G, Geschwind DH, Rademakers R, Gorno-Tempini ML, Rosen HJ, Miller BL, Seeley WW, 2017 Network degeneration and dysfunction in presymptomatic *C9ORF72* expansion carriers. *NeuroImage Clin* 14, 286–297. doi:10.1016/j.nicl.2016.12.006 [PubMed: 28337409]
- Leger GC, Banks SJ, Leverenz JB, Bekris LM, 2017 Behavioral variant FTD caused by UBQLN2 P525S mutation, without evidence of motor neuron disease. *Alzheimers Dement* 13, P1492. doi:10.1016/j.jalz.2017.07.579
- Lesage S, Le Ber I, Condroyer C, Broussolle E, Gabelle A, Thobois S, Pasquier F, Mondon K, Dion PA, Rochefort D, Rouleau GA, Dürr A, Brice A, for the French Parkinson's Disease Genetics (PDG) Study Group, 2013 *C9orf72* repeat expansions are a rare genetic cause of parkinsonism. *Brain* 136, 385–391. doi:10.1093/brain/aws357 [PubMed: 23413259]
- Lillo P, Mioshi E, Burrell JR, Kiernan MC, Hodges JR, Hornberger M, 2012 Grey and white matter changes across the amyotrophic lateral sclerosis-frontotemporal dementia continuum. *PLoS One* 7, e43993. doi:10.1371/journal.pone.0043993 [PubMed: 22952843]
- Lindquist S, Duno M, Batbayli M, Puschmann A, Braendgaard H, Mardosiene S, Svenstrup K, Pinborg L, Vestergaard K, Hjerminde L, Stokholm J, Andersen B, Johannsen P, Nielsen J, 2013 Corticobasal and ataxia syndromes widen the spectrum of *C9ORF72* hexanucleotide expansion disease. *Clin Genet* 83, 279–283. doi:10.1111/j.1399-0004.2012.01903.x [PubMed: 22650353]
- Lindquist SG, Braendgaard H, Svenstrup K, Isaacs AM, Nielsen JE, on behalf of the FReJA Consortium, 2008 Frontotemporal dementia linked to chromosome 3 (FTD-3) - current concepts

and the detection of a previously unknown branch of the Danish FTD-3 family: frontotemporal dementia linked to chromosome 3. *Eur J Neurol* 15, 667–670. doi:10.1111/j.1468-1331.2008.02144.x [PubMed: 18484988]

- Liu Y, Yu J-T, Zong Y, Zhou J, Tan L, 2014 C9ORF72 mutations in neurodegenerative diseases. *Mol Neurobiol* 49, 386–398. doi:10.1007/s12035-013-8528-1 [PubMed: 23934648]
- Llamas-Velasco S, García-Redondo A, Herrero-San Martín A, Puertas Martín V, González-Sánchez M, Pérez-Martínez DA, Villarejo-Galende A, 2018 Slowly progressive behavioral frontotemporal dementia with C9orf72 mutation. Case report and review of the literature. *Neurocase* 24, 68–71. doi:10.1080/13554794.2018.1428353 [PubMed: 29355451]
- Lloyd CM, Richardson MP, Brooks DJ, Al-Chalabi A, Leigh PN, 2000 Extramotor involvement in ALS: PET studies with the GABAA ligand [¹¹C]flumazenil. *Brain* 123, 2289–2296. doi:10.1093/brain/123.11.2289 [PubMed: 11050028]
- Lomen-Hoerth C, Anderson T, Miller B, 2002 The overlap of amyotrophic lateral sclerosis and frontotemporal dementia. *Neurology* 59, 1077–1079. doi:10.1212/WNL.59.7.1077 [PubMed: 12370467]
- Lui H, Zhang J, Makinson SR, Cahill MK, Kelley KW, Huang H-Y, Shang Y, Oldham MC, Martens LH, Gao F, Coppola G, Sloan SA, Hsieh CL, Kim CC, Bigio EH, Weintraub S, Mesulam M-M, Rademakers R, Mackenzie IR, Seeley WW, Karydas A, Miller BL, Borroni B, Ghidoni R, Farese RV, Paz JT, Barres BA, Huang EJ, 2016 Progranulin deficiency promotes circuit-specific synaptic pruning by microglia via complement activation. *Cell* 165, 921–935. doi:10.1016/j.cell.2016.04.001 [PubMed: 27114033]
- Luis E, Ortiz A, Eudave L, Ortega-Cubero S, Borroni B, van der Zee J, Gazzina S, Caroppo P, Rubino E, D'Agata F, Le Ber I, Santana I, Cunha G, Almeida MR, Boutoleau-Bretonnière C, Hannequin D, Wallon D, Rainero I, Galimberti D, Van Broeckhoven C, Pastor MA, Pastor P, 2016 Neuroimaging correlates of frontotemporal dementia associated with SQSTM1 mutations. *J Alzheimers Dis* 53, 303–313. doi:10.3233/JAD-160006 [PubMed: 27163810]
- Lunau L, Mouridsen K, Rodell A, Østergaard L, Nielsen JE, Isaacs A, Johannsen P, The FREJA Consortium, 2012 Presymptomatic cerebral blood flow changes in CHMP2B mutation carriers of familial frontotemporal dementia (FTD-3), measured with MRI. *BMJ Open* 2, e000368. doi:10.1136/bmjopen-2011-000368
- Lynch T, Sano M, Marder KS, Bell KL, Foster NL, Defendini RF, Sima AA, Keohane C, Nygaard TG, Fahn S, 1994 Clinical characteristics of a family with chromosome 17-linked disinhibition-dementia-parkinsonism-amyotrophy complex. *Neurology* 44, 1878–1884. doi:10.1212/wnl.44.10.1878 [PubMed: 7936241]
- Mackenzie IR, Arzberger T, Kremmer E, Troost D, Lorenzl S, Mori K, Weng S-M, Haass C, Kretschmar HA, Edbauer D, Neumann M, 2013 Dipeptide repeat protein pathology in C9ORF72 mutation cases: clinico-pathological correlations. *Acta Neuropathol* 126, 859–879. doi:10.1007/s00401-013-1181-y [PubMed: 24096617]
- Mackenzie IRA, Baker M, Pickering-Brown S, Hsiung G-YR, Lindholm C, Dwosh E, Gass J, Cannon A, Rademakers R, Hutton M, Feldman HH, 2006 The neuropathology of frontotemporal lobar degeneration caused by mutations in the progranulin gene. *Brain* 129, 3081–3090. doi:10.1093/brain/awl271 [PubMed: 17071926]
- Mackenzie IRA, Bigio EH, Ince PG, Geser F, Neumann M, Cairns NJ, Kwong LK, Forman MS, Ravits J, Stewart H, Eisen A, McClusky L, Kretschmar HA, Monoranu CM, Highley JR, Kirby J, Siddique T, Shaw PJ, Lee VM-Y, Trojanowski JQ, 2007 Pathological TDP-43 distinguishes sporadic amyotrophic lateral sclerosis from amyotrophic lateral sclerosis with SOD1 mutations. *Ann Neurol* 61, 427–434. doi:10.1002/ana.21147 [PubMed: 17469116]
- Mahoney CJ, Beck J, Rohrer JD, Lashley T, Mok K, Shakespeare T, Yeatman T, Warrington EK, Schott JM, Fox NC, Rossor MN, Hardy J, Collinge J, Revesz T, Mead S, Warren JD, 2012a Frontotemporal dementia with the C9ORF72 hexanucleotide repeat expansion: clinical, neuroanatomical and neuropathological features. *Brain* 135, 736–750. doi:10.1093/brain/awr361 [PubMed: 22366791]
- Mahoney CJ, Downey LE, Ridgway GR, Beck J, Clegg S, Blair M, Finnegan S, Leung KK, Yeatman T, Golden H, Mead S, Rohrer JD, Fox NC, Warren JD, 2012b Longitudinal neuroimaging and

neuropsychological profiles of frontotemporal dementia with C9ORF72 expansions. *Alzheimers Res Ther* 4, 41. doi:10.1186/alzrt144 [PubMed: 23006986]

- Mahoney CJ, Malone IB, Ridgway GR, Buckley AH, Downey LE, Golden HL, Ryan NS, Ourselin S, Schott JM, Rossor MN, Fox NC, Warren JD, 2013 White matter tract signatures of the progressive aphasias. *Neurobiol Aging* 34, 1687–1699. doi:10.1016/j.neurobiolaging.2012.12.002 [PubMed: 23312804]
- Mahoney CJ, Ridgway GR, Malone IB, Downey LE, Beck J, Kinnunen KM, Schmitz N, Golden HL, Rohrer JD, Schott JM, Rossor MN, Ourselin S, Mead S, Fox NC, Warren JD, 2014 Profiles of white matter tract pathology in frontotemporal dementia. *Hum Brain Mapp* 35, 4163–4179. doi:10.1002/hbm.22468 [PubMed: 24510641]
- Mahoney CJ, Simpson IJA, Nicholas JM, Fletcher PD, Downey LE, Golden HL, Clark CN, Schmitz N, Rohrer JD, Schott JM, Zhang H, Ourselin S, Warren JD, Fox NC, 2015 Longitudinal diffusion tensor imaging in frontotemporal dementia. *Ann Neurol* 77, 33–46. doi:10.1002/ana.24296 [PubMed: 25363208]
- Mandelli ML, Caverzasi E, Binney RJ, Henry ML, Lobach I, Block N, Amirbekian B, Dronkers N, Müller BL, Henry RG, Gorno-Tempini ML, 2014 Frontal white matter tracts sustaining speech production in primary progressive aphasia. *J Neurosci* 34, 9754–9767. doi:10.1523/JNEUROSCI.3464-13.2014 [PubMed: 25031413]
- Marini C, Cistaro A, Campi C, Calvo A, Caponnetto C, Nobili FM, Fania P, Beltrametti MC, Moglia C, Novi G, Buschiazzi A, Perasso A, Canosa A, Scialò C, Pomposelli E, Massone AM, Bagnara MC, Cammarosano S, Bruzzi P, Morbelli S, Sambuceti G, Mancardi G, Piana M, Chiò A, 2016 A PET/CT approach to spinal cord metabolism in amyotrophic lateral sclerosis. *Eur J Nucl Med Mol Imaging* 43, 2061–2071. doi:10.1007/s00259-016-3440-3 [PubMed: 27421971]
- Marroquin N, Stranz S, Müller K, Wieland T, Ruf WP, Brockmann SJ, Danzer KM, Borck G, Hübers A, Weydt P, Meitinger T, Strom T-M, Rosenbohm A, Ludolph AC, Weishaupt JH, 2016 Screening for *CHCHD10* mutations in a large cohort of sporadic ALS patients: no evidence for pathogenicity of the p.P34S variant. *Brain* 139, e8–e8. doi:10.1093/brain/awv218 [PubMed: 26362909]
- Masuda M, Senda J, Watanabe H, Epifanio B, Tanaka Y, Imai K, Riku Y, Li Y, Nakamura R, Ito M, Ishigaki S, Atsuta N, Koike H, Katsuno M, Hattori N, Naganawa S, Sobue G, 2016 Involvement of the caudate nucleus head and its networks in sporadic amyotrophic lateral sclerosis-frontotemporal dementia continuum. *Amyotroph Lateral Scler Frontotemporal Degener* 17, 571–579. doi:10.1080/21678421.2016.1211151 [PubMed: 27684890]
- McCombe PA, Ngo ST, Guo CC, Fazlollahi A, Bollmann S, Wang L, Hu X, Barth M, Salvado O, Davis M, Ceslis A, Robinson G, Henderson RD, Steyn FJ, 2018 Patient with ALS with a novel TBK1 mutation, widespread brain involvement, behaviour changes and metabolic dysfunction. *J Neurol Neurosurg Psychiatry* 90, 952–954. doi:10.1136/jnnp-2018-318823 [PubMed: 30196251]
- McMillan CT, Russ J, Wood EM, Irwin DJ, Grossman M, McCluskey L, Elman L, Van Deerlin V, Lee EB, 2015 C9orf72 promoter hypermethylation is neuroprotective: Neuroimaging and neuropathologic evidence. *Neurology* 84, 1622–1630. doi:10.1212/WNL.0000000000001495 [PubMed: 25795648]
- Menke RAL, Körner S, Filippini N, Douaud G, Knight S, Talbot K, Turner MR, 2014 Widespread grey matter pathology dominates the longitudinal cerebral MRI and clinical landscape of amyotrophic lateral sclerosis. *Brain* 137, 2546–2555. doi:10.1093/brain/awu162 [PubMed: 24951638]
- Menke RAL, Proudfoot M, Talbot K, Turner MR, 2018 The two-year progression of structural and functional cerebral MRI in amyotrophic lateral sclerosis. *NeuroImage Clin* 17, 953–961. doi:10.1016/j.nicl.2017.12.025 [PubMed: 29321969]
- Menke RAL, Proudfoot M, Wu J, Andersen PM, Talbot K, Benatar M, Turner MR, 2016 Increased functional connectivity common to symptomatic amyotrophic lateral sclerosis and those at genetic risk. *J Neurol Neurosurg Psychiatry* 87, 580–588. doi:10.1136/jnnp-2015-311945 [PubMed: 26733601]
- Mesulam M-M, 2003 Primary progressive aphasia — a language-based dementia. *N Engl J Med* 349, 1535–1542. doi:10.1056/NEJMr022435 [PubMed: 14561797]
- Mezzapesa DM, D’Errico E, Tortelli R, Distaso E, Cortese R, Tursi M, Federico F, Zoccollella S, Logroscino G, Dicuonzo F, Simone IL, 2013 Cortical thinning and clinical heterogeneity in

amyotrophic lateral sclerosis. *PLoS One* 8, e80748. doi:10.1371/journal.pone.0080748 [PubMed: 24278317]

- Millecamps S, Boillée S, Le Ber I, Seilhean D, Teyssou E, Giraudeau M, Moigneu C, Vandenberghe N, Danel-Brunaud V, Corcia P, Pradat P-F, Le Forestier N, Lacomblez L, Bruneteau G, Camu W, Brice A, Cazeneuve C, LeGuern E, Meininger V, Salachas F, 2012 Phenotype difference between ALS patients with expanded repeats in *C9ORF72* and patients with mutations in other ALS-related genes. *J Med Genet* 49, 258–263. doi:10.1136/jmedgenet-2011-100699 [PubMed: 22499346]
- Miyoshi M, Shinotoh H, Wszolek ZK, Strongosky AJ, Shimada H, Arakawa R, Higuchi M, Ikoma Y, Yasuno F, Fukushi K, Irie T, Ito H, Suhara T, 2010 In vivo detection of neuropathologic changes in presymptomatic MAPT mutation carriers: a PET and MRI study. *Parkinsonism Relat Disord* 16, 404–408. doi:10.1016/j.parkreldis.2010.04.004 [PubMed: 20452812]
- Mohammadi B, Kollwe K, Samii A, Krampfl K, Dengler R, Münte TF, 2009 Changes of resting state brain networks in amyotrophic lateral sclerosis. *Exp Neurol* 217, 147–153. doi:10.1016/j.expneurol.2009.01.025 [PubMed: 19416664]
- Montalbetti L, Ratti MT, Greco B, Aprile C, Moglia A, Soragna D, 2005 Neuropsychological tests and functional nuclear neuroimaging provide evidence of subclinical impairment in Nasu-Hakola disease heterozygotes. *Funct Neurol* 20, 71–75. [PubMed: 15966270]
- Morbelli S, Ferrara M, Fiz F, Dessi B, Arnaldi D, Picco A, Bossert I, Buschiazzo A, Accardo J, Picori L, Girtler N, Mandich P, Pagani M, Sambuceti G, Nobili F, 2016 Mapping brain morphological and functional conversion patterns in predementia late-onset bvFTD. *Eur J Nucl Med Mol I* 43, 1337–1347. doi:10.1007/s00259-016-3335-3
- Moreno F, Rabinovici GD, Karydas A, Miller Z, Hsu SC, Legati A, Fong J, Schonhaut D, Esselmann H, Watson C, Stephens ML, Kramer J, Wiltfang J, Seeley WW, Miller BL, Coppola G, Grinberg LT, 2015 A novel mutation P112H in the TARDBP gene associated with frontotemporal lobar degeneration without motor neuron disease and abundant neuritic amyloid plaques. *Acta Neuropathol Commun* 3, 19. doi:10.1186/s40478-015-0190-6 [PubMed: 25853458]
- Moreno F, Sala-Llonch R, Barandiaran M, Sánchez-Valle R, Estanga A, Bartrés-Faz D, Sistiaga A, Alzualde A, Fernández E, Martí Massó JF, López de Munain A, Indakoetxea B, 2013 Distinctive age-related temporal cortical thinning in asymptomatic granulin gene mutation carriers. *Neurobiol Aging* 34, 1462–1468. doi:10.1016/j.neurobiolaging.2012.11.005 [PubMed: 23218900]
- Mori K, Weng S-M, Arzberger T, May S, Rentzsch K, Kremmer E, Schmid B, Kretzschmar HA, Cruts M, Van Broeckhoven C, Haass C, Edbauer D, 2013 The C9orf72 GGGGCC repeat is translated into aggregating dipeptide-repeat proteins in FTL/ALS. *Science* 339, 1335–1338. doi:10.1126/science.1232927 [PubMed: 23393093]
- Müller H-P, Agosta F, Riva N, Spinelli EG, Comi G, Ludolph AC, Filippi M, Kassubek J, 2018 Fast progressive lower motor neuron disease is an ALS variant: A two-centre tract of interest-based MRI data analysis. *NeuroImage Clin* 17, 145–152. doi:10.1016/j.nicl.2017.10.008 [PubMed: 29071208]
- Müller H-P, Del Tredici K, Lulé D, Müller K, Weishaupt JH, Ludolph AC, Kassubek J, 2020 In vivo histopathological staging in C9orf72-associated ALS: A tract of interest DTI study. *NeuroImage Clin* 27, 102298. doi:10.1016/j.nicl.2020.102298 [PubMed: 32505118]
- Müller H-P, Turner MR, Grosskreutz J, Abrahams S, Bede P, Govind V, Prudlo J, Ludolph AC, Filippi M, Kassubek J, 2016 A large-scale multicentre cerebral diffusion tensor imaging study in amyotrophic lateral sclerosis. *J Neurol Neurosurg Psychiatry* 87, 570–579. doi:10.1136/jnnp-2015-311952 [PubMed: 26746186]
- Müller K, Andersen PM, Hübers A, Marroquin N, Volk AE, Danzer KM, Meitinger T, Ludolph AC, Strom TM, Weishaupt JH, 2014 Two novel mutations in conserved codons indicate that CHCHD10 is a gene associated with motor neuron disease. *Brain* 137, e309–e309. doi:10.1093/brain/awu227 [PubMed: 25113787]
- Munoz DG, Ros R, Fatas M, Bermejo F, de Yébenes JG, 2007 Progressive nonfluent aphasia associated with a new mutation V363I in tau gene. *Am J Alzheimers Dis Other Demen* 22, 294–299. doi:10.1177/1533317507302320 [PubMed: 17712160]

- Murphy NA, Arthur KC, Tienari PJ, Houlden H, Chiò A, Traynor BJ, 2017 Age-related penetrance of the C9orf72 repeat expansion. *Sci Rep* 7, 2116. doi:10.1038/s41598-017-02364-1 [PubMed: 28522837]
- Murray ME, DeJesus-Hernandez M, Rutherford NJ, Baker M, Duara R, Graff-Radford NR, Wszolek ZK, Ferman TJ, Josephs KA, Boylan KB, Rademakers R, Dickson DW, 2011 Clinical and neuropathologic heterogeneity of c9FTD/ALS associated with hexanucleotide repeat expansion in C9ORF72. *Acta Neuropathol* 122, 673–690. doi:10.1007/s00401-011-0907-y [PubMed: 22083254]
- Mutsaerts HJMM, Mirza SS, Petr J, Thomas DL, Cash DM, Bocchetta M, de Vita E, Metcalfe AWS, Shirzadi Z, Robertson AD, Tartaglia MC, Mitchell SB, Black SE, Freedman M, Tang-Wai D, Keren R, Rogaeva E, van Swieten J, Laforce R, Tagliavini F, Borroni B, Galimberti D, Rowe JB, Graff C, Frisoni GB, Finger E, Sorbi S, de Mendonça A, Rohrer JD, MacIntosh BJ, Masellis M, GENetic Frontotemporal dementia Initiative (GENFI), Andersson, C., Archetti S, Arighi A, Benussi L, Binetti G, Cosseddu M, Dick KM, Fallström M, Ferreira C, Fenoglio C, Fox NC, Fumagalli G, Gazzina S, Ghidoni R, Grisoli M, Jelic V, Jiskoot L, Lombardi G, Maruta C, Mead S, Meeter L, van Minkelen R, Nacmias B, Öjjerstedt L, Ourselin S, Padovani A, Panman J, Pievani M, Polito C, Premi E, Prioni S, Rademakers R, Redaelli V, Rossi G, Rossor MN, Scarpini E, Thonberg H, Tiraboschi P, Verdelho A, Warren JD, 2019 Cerebral perfusion changes in presymptomatic genetic frontotemporal dementia: a GENFI study. *Brain* 142, 1108–1120. doi:10.1093/brain/awz039 [PubMed: 30847466]
- Neary D, Snowden JS, Gustafson L, Passant U, Stuss D, Black S, Freedman M, Kertesz A, Robert PH, Albert M, Boone K, Miller BL, Cummings J, Benson DF, 1998 Frontotemporal lobar degeneration: a consensus on clinical diagnostic criteria. *Neurology* 51, 1546–1554. doi:10.1212/WNL.51.6.1546 [PubMed: 9855500]
- Neumann M, Mackenzie IRA, 2019 Review: neuropathology of non-tau frontotemporal lobar degeneration. *Neuropathol Appl Neurobiol* 45, 19–40. doi:10.1111/nan.12526 [PubMed: 30357887]
- Ng M-C, Ho JT, Ho S-L, Lee R, Li G, Cheng T-S, Song Y-Q, Ho PW-L, Fong GC-Y, Mak W, Chan K-H, Li LS-W, Luk KD-K, Hu Y, Ramsden DB, Leong LL-Y, 2008 Abnormal diffusion tensor in nonsymptomatic familial amyotrophic lateral sclerosis with a causative superoxide dismutase 1 mutation. *J Magn Reson Imaging* 27, 8–13. doi:10.1002/jmri.21217 [PubMed: 18022844]
- Nguyen HP, Van Broeckhoven C, van der Zee J, 2018 ALS genes in the genomic era and their implications for FTD. *Trends Genet* 34, 404–423. doi:10.1016/j.tig.2018.03.001 [PubMed: 29605155]
- Olm CA, McMillan CT, Irwin DJ, Van Deerlin VM, Cook PA, Gee JC, Grossman M, 2018 Longitudinal structural gray matter and white matter MRI changes in presymptomatic progranulin mutation carriers. *NeuroImage Clin* 19, 497–506. doi:10.1016/j.nicl.2018.05.017 [PubMed: 29984158]
- Olney NT, Ong E, Goh S-YM, Bajorek L, Dever R, Staffaroni AM, Cobigo Y, Bock M, Chiang K, Ljubenkov P, Kornak J, Heuer HW, Wang P, Rascovsky K, Wolf A, Appleby B, Bove J, Bordelon Y, Brannelly P, Brushaber D, Caso C, Coppola G, Dickerson BC, Dickinson S, Domoto-Reilly K, Faber K, Ferrall J, Fields J, Fishman A, Fong J, Foroud T, Forsberg LK, Gearhart DJ, Ghazanfari B, Ghoshal N, Goldman J, Graff-Radford J, Graff-Radford NR, Grant I, Grossman M, Haley D, Hsiung G, Huey ED, Irwin DJ, Jones DT, Kantarci K, Karydas AM, Kaufer D, Kerwin D, Knopman DS, Kramer JH, Kraft R, Kremers W, Kukull W, Lapid MI, Litvan I, Mackenzie IR, Maldonado M, Manoochehri M, McGinnis SM, McKinley EC, Mendez MF, Miller BL, Onyike C, Pantelyat A, Pearlman R, Petrucelli L, Potter M, Rademakers R, Ramos EM, Rankin KP, Roberson ED, Rogalski E, Sengdy P, Shaw LM, Syrjanen J, Tartaglia MC, Tatton N, Taylor J, Toga A, Trojanowski JQ, Weintraub S, Wong B, Wszolek Z, Boxer AL, Boeve BF, Rosen HJ, 2020 Clinical and volumetric changes with increasing functional impairment in familial frontotemporal lobar degeneration. *Alzheimers Dement* 16, 49–59. doi:10.1016/j.jalz.2019.08.196 [PubMed: 31784375]
- Omer T, Finegan E, Hutchinson S, Doherty M, Vajda A, McLaughlin RL, Pender N, Hardiman O, Bede P, 2017 Neuroimaging patterns along the ALS-FTD spectrum: a multiparametric imaging study. *Amyotroph Lateral Scler Frontotemporal Degener* 18, 611–623. doi:10.1080/21678421.2017.1332077 [PubMed: 28562080]

- Origone P, Geroldi A, Lamp M, Sanguineri F, Caponnetto C, Cabona C, Gotta F, Trevisan L, Bellone E, Manganelli F, Devigili G, Mandich P, 2018 Role of *MAPT* in pure motor neuron disease: report of a recurrent mutation in Italian patients. *Neurodegener Dis* 18, 310–314. doi:10.1159/000497820 [PubMed: 30893702]
- Pagani M, Chio A, Valentini MC, Oberg J, Nobili F, Calvo A, Moglia C, Bertuzzo D, Morbelli S, De Carli F, Fania P, Cistaro A, 2014 Functional pattern of brain FDG-PET in amyotrophic lateral sclerosis. *Neurology* 83, 1067–1074. doi:10.1212/WNL.0000000000000792 [PubMed: 25122207]
- Paloneva J, Manninen T, Christman G, Hovanes K, Mandelin J, Adolfsson R, Bianchin M, Bird T, Miranda R, Salmaggi A, Tranebjærg L, Kontinen Y, Peltonen L, 2002 Mutations in two genes encoding different subunits of a receptor signaling complex result in an identical disease phenotype. *Am J Hum Genet* 71, 656–662. doi:10.1086/342259 [PubMed: 12080485]
- Panman JL, Jiskoot LC, Bouts MJRJ, Meeter LHH, van der Ende EL, Poos JM, Feis RA, Kievit AJA, van Minkelen R, Dopfer EGP, Rombouts SARB, van Swieten JC, Papma JM, 2019 Gray and white matter changes in presymptomatic genetic frontotemporal dementia: a longitudinal MRI study. *Neurobiol Aging* 76, 115–124. doi:10.1016/j.neurobiolaging.2018.12.017 [PubMed: 30711674]
- Papma JM, Jiskoot LC, Panman JL, Dopfer EG, den Heijer T, Donker Kaat L, Pijnenburg YAL, Meeter LH, van Minkelen R, Rombouts SARB, van Swieten JC, 2017 Cognition and gray and white matter characteristics of presymptomatic *C9orf72* repeat expansion. *Neurology* 89, 1256–1264. doi:10.1212/WNL.0000000000004393 [PubMed: 28855404]
- Paternicò D, Premi E, Gazzina S, Cosseddu M, Alberici A, Archetti S, Cotelli MS, Micheli A, Turla M, Gasparotti R, Padovani A, Borroni B, 2016 White matter hyperintensities characterize monogenic frontotemporal dementia with granulin mutations. *Neurobiol Aging* 38, 176–180. doi:10.1016/j.neurobiolaging.2015.11.011 [PubMed: 26827655]
- Penttilä S, Jokela M, Bouquin H, Saukkonen AM, Toivanen J, Udd B, 2015 Late onset spinal motor neuronopathy is caused by mutation in *CHCHD10*. *Ann Neurol* 77, 163–172. doi:10.1002/ana.24319 [PubMed: 25428574]
- Perry DC, Lehmann M, Yokoyama JS, Karydas A, Lee JJ, Coppola G, Grinberg LT, Geschwind D, Seeley WW, Miller BL, Rosen H, Rabinovici G, 2013 Progranulin mutations as risk factors for Alzheimer disease. *JAMA Neurol* 70, 774–778. doi:10.1001/2013.jamaneurol.393 [PubMed: 23609919]
- Perry DC, Whitwell JL, Boeve BF, Pankratz VS, Knopman DS, Petersen RC, Jack CR, Josephs KA, 2012 Voxel-based morphometry in patients with obsessivecompulsive behaviors in behavioral variant frontotemporal dementia: Compulsions in FTD. *Eur J Neurol* 19, 911–917. doi:10.1111/j.1468-1331.2011.03656.x
- Petkau TL, Leavitt BR, 2014 Progranulin in neurodegenerative disease. *Trends Neurosci* 37, 388–398. doi:10.1016/j.tins.2014.04.003 [PubMed: 24800652]
- Pievani M, Paternicò D, Benussi L, Binetti G, Orlandini A, Cobelli M, Magnaldi S, Ghidoni R, Frisoni GB, 2014 Pattern of structural and functional brain abnormalities in asymptomatic granulin mutation carriers. *Alzheimers Dement* 10, S354–S363.e1. doi:10.1016/j.jalz.2013.09.009 [PubMed: 24418059]
- Piguet O, Petersén Å, Yin Ka Lam B, Gabery S, Murphy K, Hodges JR, Halliday GM, 2011 Eating and hypothalamus changes in behavioral-variant frontotemporal dementia. *Ann Neurol* 69, 312–319. doi:10.1002/ana.22244 [PubMed: 21387376]
- Poorkaj P, Bird TD, Wijsman E, Nemens E, Garruto RM, Anderson L, Andreadis A, Wiederholt WC, Raskind M, Schellenberg GD, 1998 Tau is a candidate gene for chromosome 17 frontotemporal dementia. *Ann Neurol* 43, 815–825. doi:10.1002/ana.410430617 [PubMed: 9629852]
- Popuri K, Dowds E, Beg MF, Balachandar R, Bhalla M, Jacova C, Buller A, Slack P, Sengdy P, Rademakers R, Wittenberg D, Feldman HH, Mackenzie IR, Hsiung G-YR, 2018 Gray matter changes in asymptomatic *C9orf72* and *GRN* mutation carriers. *NeuroImage Clin* 18, 591–598. doi:10.1016/j.nicl.2018.02.017 [PubMed: 29845007]
- Pottier C, Bieniek KF, Finch N, van de Vorst M, Baker M, Perkerson R, Brown P, Ravenscroft T, van Blitterswijk M, Nicholson AM, DeTure M, Knopman DS, Josephs KA, Parisi JE, Petersen RC, Boylan KB, Boeve BF, Graff-Radford NR, Veltman JA, Gilissen C, Murray ME, Dickson DW,

- Rademakers R, 2015 Whole-genome sequencing reveals important role for TBK1 and OPTN mutations in frontotemporal lobar degeneration without motor neuron disease. *Acta Neuropathol* 130, 77–92. doi:10.1007/s00401-015-1436-x [PubMed: 25943890]
- Poujois A, Schneider FC, Faillenot I, Camdessanché J-P, Vandenberghe N, Thomas-Antérion C, Antoine JC, 2013 Brain plasticity in the motor network is correlated with disease progression in amyotrophic lateral sclerosis: functional cerebral reorganization, disease progression, and ALS. *Hum Brain Mapp* 34, 2391–2401. doi:10.1002/hbm.22070 [PubMed: 22461315]
- Premi E, Cauda F, Costa T, Diano M, Gazzina S, Gualeni V, Alberici A, Archetti S, Magoni M, Gasparotti R, Padovani A, Borroni B, 2016 Looking for neuroimaging markers in frontotemporal lobar degeneration clinical trials: a multi-voxel pattern analysis study in granulin disease. *J Alzheimers Dis* 51, 249–262. doi:10.3233/JAD-150340 [PubMed: 26836150]
- Premi E, Cauda F, Gasparotti R, Diano M, Silvana Archetti, Padovani A, Borroni B, 2014 Multimodal fMRI resting-state functional connectivity in granulin mutations: the case of fronto-parietal dementia. *PLoS One* 9, e106500. doi:10.1371/journal.pone.0106500 [PubMed: 25188321]
- Pyra T, Hui B, Hanstock C, Concha L, Wong JCT, Beaulieu C, Johnston W, Kalra S, 2010 Combined structural and neurochemical evaluation of the corticospinal tract in amyotrophic lateral sclerosis. *Amyotroph Lateral Scler* 11, 157–165. doi:10.3109/17482960902756473 [PubMed: 19242831]
- Qiu T, Zhang Y, Tang X, Liu X, Wang Y, Zhou C, Luo C, Zhang J, 2019 Precentral degeneration and cerebellar compensation in amyotrophic lateral sclerosis: a multimodal MRI analysis. *Hum Brain Mapp* 40, 3464–3474. doi:10.1002/hbm.24609 [PubMed: 31020731]
- Querin G, Bede P, El Mendili MM, Li M, Péligrini-Issac M, Rinaldi D, Catala M, Saracino D, Salachas F, Camuzat A, Marchand-Pauvert V, Cohen-Adad J, Colliot O, Le Ber I, Pradat P, for The Predict to Prevent Frontotemporal Lobar Degeneration and Amyotrophic Lateral Sclerosis (PREV DEMALS) Study Group, 2019 Presymptomatic spinal cord pathology in *c9orf72* mutation carriers: a longitudinal neuroimaging study. *Ann Neurol*. doi:10.1002/ana.25520
- Rademakers R, Stewart H, DeJesus-Hernandez M, Krieger C, Graff-Radford N, Fabros M, Briemberg H, Cashman N, Eisen A, Mackenzie IRA, 2010 *Fus* gene mutations in familial and sporadic amyotrophic lateral sclerosis. *Muscle Nerve* 42, 170–176. doi:10.1002/mus.21665 [PubMed: 20544928]
- Rankin KP, Gorno-Tempini ML, Allison SC, Stanley CM, Glenn S, Weiner MW, Miller BL, 2006 Structural anatomy of empathy in neurodegenerative disease. *Brain* 129, 2945–2956. doi:10.1093/brain/awl254 [PubMed: 17008334]
- Rascovsky K, Hodges JR, Knopman D, Mendez MF, Kramer JH, Neuhaus J, van Swieten JC, Seelaar H, Dopper EGP, Onyike CU, Hillis AE, Josephs KA, Boeve BF, Kertesz A, Seeley WW, Rankin KP, Johnson JK, Gorno-Tempini M-L, Rosen H, Prioleau-Latham CE, Lee A, Kipps CM, Lillo P, Piguet O, Rohrer JD, Rossor MN, Warren JD, Fox NC, Galasko D, Salmon DP, Black SE, Mesulam M, Weintraub S, Dickerson BC, Diehl-Schmid J, Pasquier F, Deramecourt V, Lebert F, Pijnenburg Y, Chow TW, Manes F, Grafman J, Cappa SF, Freedman M, Grossman M, Miller BL, 2011 Sensitivity of revised diagnostic criteria for the behavioural variant of frontotemporal dementia. *Brain* 134, 2456–2477. doi:10.1093/brain/awr179 [PubMed: 21810890]
- Rayaprolu S, Mullen B, Baker M, Lynch T, Finger E, Seeley WW, Hatanpaa KJ, Lomen-Hoerth C, Kertesz A, Bigio EH, Lippa C, Josephs KA, Knopman DS, White CL, Caselli R, Mackenzie IR, Miller BL, Boczarska-Jedynak M, Opala G, Krygowska-Wajs A, Barcikowska M, Younkin SG, Petersen RC, Ertekin-Taner N, Uitti RJ, Meschia JF, Boylan KB, Boeve BF, Graff-Radford NR, Wszolek ZK, Dickson DW, Rademakers R, Ross OA, 2013 TREM2 in neurodegeneration: evidence for association of the p.R47H variant with frontotemporal dementia and Parkinson's disease. *Mol Neurodegener* 8, 19. doi:10.1186/1750-1326-8-19 [PubMed: 23800361]
- Rea SL, Majcher V, Searle MS, Layfield R, 2014 SQSTM1 mutations – bridging Paget disease of bone and ALS/FTLD. *Exp Cell Res* 325, 27–37. doi:10.1016/j.yexcr.2014.01.020 [PubMed: 24486447]
- Renton AE, Chiò A, Traynor BJ, 2014 State of play in amyotrophic lateral sclerosis genetics. *Nat Neurosci* 17, 17–23. doi:10.1038/nn.3584 [PubMed: 24369373]
- Renton AE, Majounie E, Waite A, Simón-Sánchez J, Rollinson S, Gibbs JR, Schymick JC, Laaksovirta H, van Swieten JC, Myllykangas L, Kalimo H, Paetau A, Abramzon Y, Remes AM, Kaganovich A, Scholz SW, Duckworth J, Ding J, Harmer DW, Hernandez DG, Johnson JO, Mok K, Ryten M,

Trabzuni D, Guerreiro RJ, Orrell RW, Neal J, Murray A, Pearson J, Jansen IE, Sondervan D, Seelaar H, Blake D, Young K, Halliwell N, Callister JB, Toulson G, Richardson A, Gerhard A, Snowden J, Mann D, Neary D, Nalls MA, Peuralinna T, Jansson L, Isoviiita V-M, Kaivorinne A-L, Hölttä-Vuori M, Ikonen E, Sulkava R, Benatar M, Wu J, Chiò A, Restagno G, Borghero G, Sabatelli M, Heckerman D, Rogaeva E, Zinman L, Rothstein JD, Sendtner M, Drepper C, Eichler EE, Alkan C, Abdullaev Z, Pack SD, Dutra A, Pak E, Hardy J, Singleton A, Williams NM, Heutink P, Pickering-Brown S, Morris HR, Tienari PJ, Traynor BJ, 2011 A hexanucleotide repeat expansion in C9ORF72 is the cause of chromosome 9p21-linked ALS-FTD. *Neuron* 72, 257–268. doi:10.1016/j.neuron.2011.09.010 [PubMed: 21944779]

- Rezaie T, 2002 Adult-onset primary open-angle glaucoma caused by mutations in optineurin. *Science* 295, 1077–1079. doi:10.1126/science.1066901 [PubMed: 11834836]
- Ringholz GM, Appel SH, Bradshaw M, Cooke NA, Mosnik DM, Schulz PE, 2005 Prevalence and patterns of cognitive impairment in sporadic ALS. *Neurology* 65, 586–590. doi:10.1212/01.wnl.0000172911.39167.b6 [PubMed: 16116120]
- Rogalski E, Cobia D, Harrison TM, Wieneke C, Weintraub S, Mesulam M-M, 2011 Progression of language decline and cortical atrophy in subtypes of primary progressive aphasia. *Neurology* 76, 1804–1810. doi:10.1212/WNL.0b013e31821ccd3c [PubMed: 21606451]
- Rohrer JD, Ahsan RL, Isaacs AM, Nielsen JE, Ostergaard L, Scahill R, Warren JD, Rossor MN, Fox NC, Johannsen P, 2009a Presymptomatic generalized brain atrophy in frontotemporal dementia caused by CHMP2B mutation. *Dement Geriatr Cogn Disord* 27, 182–186. doi:10.1159/000200466 [PubMed: 19202337]
- Rohrer JD, Clarkson MJ, Kittus R, Rossor MN, Ourselin S, Warren JD, Fox NC, 2012 Rates of hemispheric and lobar atrophy in the language variants of frontotemporal lobar degeneration. *J Alzheimers Dis* 30, 407–411. doi:10.3233/JAD-2012-111556 [PubMed: 22406442]
- Rohrer JD, Guerreiro R, Vandrovicova J, Uphill J, Reiman D, Beck J, Isaacs AM, Authier A, Ferrari R, Fox NC, Mackenzie IRA, Warren JD, de Silva R, Holton J, Revesz T, Hardy J, Mead S, Rossor MN, 2009b The heritability and genetics of frontotemporal lobar degeneration. *Neurology* 73, 1451–1456. doi:10.1212/WNL.0b013e3181bf997a [PubMed: 19884572]
- Rohrer JD, Lashley T, Schott JM, Warren JE, Mead S, Isaacs AM, Beck J, Hardy J, de Silva R, Warrington E, Troakes C, Al-Sarraj S, King A, Borroni B, Clarkson MJ, Ourselin S, Holton JL, Fox NC, Revesz T, Rossor MN, Warren JD, 2011a Clinical and neuroanatomical signatures of tissue pathology in frontotemporal lobar degeneration. *Brain* 134, 2565–2581. doi:10.1093/brain/awr198 [PubMed: 21908872]
- Rohrer JD, Nicholas JM, Cash DM, van Swieten J, Dopper E, Jiskoot L, van Minkelen R, Rombouts SA, Cardoso MJ, Clegg S, Espak M, Mead S, Thomas DL, De Vita E, Masellis M, Black SE, Freedman M, Keren R, MacIntosh BJ, Rogaeva E, Tang-Wai D, Tartaglia MC, Laforce R, Tagliavini F, Tiraboschi P, Redaelli V, Prioni S, Grisoli M, Borroni B, Padovani A, Galimberti D, Scarpini E, Arighi A, Fumagalli G, Rowe JB, Coyle-Gilchrist I, Graff C, Fallström M, Jelic V, Ståhlbom AK, Andersson C, Thonberg H, Lilius L, Frisoni GB, Binetti G, Pievani M, Bocchetta M, Benussi L, Ghidoni R, Finger E, Sorbi S, Nacmias B, Lombardi G, Polito C, Warren JD, Ourselin S, Fox NC, Rossor MN, 2015 Presymptomatic cognitive and neuroanatomical changes in genetic frontotemporal dementia in the Genetic Frontotemporal dementia Initiative (GENFI) study: a cross-sectional analysis. *Lancet Neurol* 14, 253–262. doi:10.1016/S1474-4422(14)70324-2 [PubMed: 25662776]
- Rohrer JD, Ridgway GR, Modat M, Ourselin S, Mead S, Fox NC, Rossor MN, Warren JD, 2010 Distinct profiles of brain atrophy in frontotemporal lobar degeneration caused by progranulin and tau mutations. *NeuroImage* 53, 1070–1076. doi:10.1016/j.neuroimage.2009.12.088 [PubMed: 20045477]
- Rohrer JD, Warren JD, 2011 Phenotypic signatures of genetic frontotemporal dementia. *Curr Opin Neurol* 24, 542–549. doi:10.1097/WCO.0b013e32834cd442 [PubMed: 21986680]
- Rohrer JD, Warren JD, Modat M, Ridgway GR, Douiri A, Rossor MN, Ourselin S, Fox NC, 2009c Patterns of cortical thinning in the language variants of frontotemporal lobar degeneration. *Neurology* 72, 1562–1569. doi:10.1212/WNL.0b013e3181a4124e [PubMed: 19414722]

- Rohrer JD, Warren JD, Reiman D, Uphill J, Beck J, Collinge J, Rossor MN, Isaacs AM, Mead S, 2011b A novel exon 2 I27V VCP variant is associated with dissimilar clinical syndromes. *J Neurol* 258, 1494–1496. doi:10.1007/s00415-011-5966-4 [PubMed: 21387114]
- Ronchi D, Riboldi G, Del Bo R, Ticozzi N, Scarlato M, Galimberti D, Corti S, Silani V, Bresolin N, Comi GP, 2015 *CHCHD10* mutations in Italian patients with sporadic amyotrophic lateral sclerosis. *Brain* 138, e372–e372. doi:10.1093/brain/awu384 [PubMed: 25576308]
- Rosen HJ, Allison SC, Schauer GF, Gorno-Tempini ML, Weiner MW, Miller BL, 2005 Neuroanatomical correlates of behavioural disorders in dementia. *Brain* 128, 2612–2625. doi:10.1093/brain/awh628 [PubMed: 16195246]
- Rosen HJ, Gorno-Tempini ML, Goldman WP, Perry RJ, Schuff N, Weiner M, Feiwell R, Kramer JH, Miller BL, 2002 Patterns of brain atrophy in frontotemporal dementia and semantic dementia. *Neurology* 58, 198–208. doi:10.1212/WNL.58.2.198 [PubMed: 11805245]
- Rosso SM, Roks G, Stevens M, de Koning I, Tanghe HLJ, Kamphorst W, Ravid R, Niermeijer MF, van Swieten JC, 2001 Complex compulsive behaviour in the temporal variant of frontotemporal dementia. *J Neurol* 248, 965–970. doi:10.1007/s004150170049 [PubMed: 11757960]
- Rothstein JD, 2009 Current hypotheses for the underlying biology of amyotrophic lateral sclerosis. *Ann Neurol* 65, S3–S9. doi:10.1002/ana.21543 [PubMed: 19191304]
- Rubino E, Rainero I, Chiò A, Rogaeva E, Galimberti D, Fenoglio P, Grinberg Y, Isaia G, Calvo A, Gentile S, Bruni AC, St. George-Hyslop PH, Scarpini E, Gallone S, Pinessi L, For the TODDEM Study Group, 2012 SQSTM1 mutations in frontotemporal lobar degeneration and amyotrophic lateral sclerosis. *Neurology* 79, 1556–1562. doi:10.1212/WNL.0b013e31826e25df [PubMed: 22972638]
- Rytty R, Nikkinen J, Paavola L, Abou Elseoud A, Moilanen V, Visuri A, Tervonen O, Renton AE, Traynor BJ, Kiviniemi V, Remes AM, 2013 GroupICA dual regression analysis of resting state networks in a behavioral variant of frontotemporal dementia. *Front Hum Neurosci* 7, 461. doi:10.3389/fnhum.2013.00461 [PubMed: 23986673]
- Rytty R, Nikkinen J, Suhonen N, Moilanen V, Renton AE, Traynor BJ, Tervonen O, Kiviniemi V, Remes AM, 2014 Functional MRI in patients with the C9ORF72 expansion associate frontotemporal dementia. *Mol Biol* 03. doi:10.4172/2168-9547.1000117
- Saberi S, Stauffer JE, Schulte DJ, Ravits J, 2015 Neuropathology of amyotrophic lateral sclerosis and its variants. *Neurol Clin* 33, 855–876. doi:10.1016/j.ncl.2015.07.012 [PubMed: 26515626]
- Saracino D, Clot F, Camuzat A, Anquetil V, Hannequin D, Guyant-Maréchal L, Didic M, Guillot-Noël L, Rinaldi D, Latouche M, Forlani S, Ghassab Y, Coppola C, Di Iorio G, David I, Le Guern E, Brice A, Le Ber I, 2018 Novel VCP mutations expand the mutational spectrum of frontotemporal dementia. *Neurobiol Aging* 72, 187.e11–187.e14. doi:10.1016/j.neurobiolaging.2018.06.037
- Schoenfeld MA, Tempelmann C, Gaul C, Kühnel GR, Düzel E, Hopf J-M, Feistner H, Zierz S, Heinze H-J, Vielhaber S, 2005 Functional motor compensation in amyotrophic lateral sclerosis. *J Neurol* 252, 944–952. doi:10.1007/s00415-005-0787-y [PubMed: 15750701]
- Schönecker S, Brendel M, van der Zee J, van Broeckhoven C, Rominger A, Danek A, Levin J, 2016 Ein Geschwisterpaar mit frontotemporaler Lobärdegeneration und amyotropher Lateralsklerose und einer neuen Mutation im TBK1-Gen (Thr462Lysfs). *Fortschr Neurol Psychiatr* 84, 494–498. doi:10.1055/s-0042-110653 [PubMed: 27570907]
- Schönecker S, Neuhofer C, Otto M, Ludolph A, Kassubek J, Landwehrmeyer B, Anderl-Straub S, Semler E, Diehl-Schmid J, Prix C, Vollmar C, Forste J, Deutsches FTLD-Konsortium, Huppertz H-J, Arzberger T, Edbauer D, Feddersen B, Dieterich M, Schroeter ML, Volk AE, Fließbach K, Schneider A, Kornhuber J, Maler M, Prudlo J, Jahn H, Boeckh-Behrens T, Danek A, Klopstock T, Levin J, 2018 Atrophy in the thalamus but not cerebellum is specific for C9orf72 FTD and ALS patients – an atlas-based volumetric MRI study. *Front Aging Neurosci* 10, 45. doi:10.3389/fnagi.2018.00045 [PubMed: 29599716]
- Schroeter ML, Raczka K, Neumann J, Yves von Cramon D, 2007 Towards a nosology for frontotemporal lobar degenerations—A meta-analysis involving 267 subjects. *NeuroImage* 36, 497–510. doi:10.1016/j.neuroimage.2007.03.024 [PubMed: 17478101]
- Schwindt GC, Graham NL, Rochon E, Tang-Wai DF, Lobaugh NJ, Chow TW, Black SE, 2013 Whole-brain white matter disruption in semantic and nonfluent variants of primary progressive aphasia. *Hum Brain Mapp* 34, 973–984. doi:10.1002/hbm.21484 [PubMed: 22109837]

- Seelaar H, Papma JM, Garraux G, de Koning I, Reijs AE, Valkema R, Rozemuller AJM, Salmon E, van Swieten JC, 2011 Brain perfusion patterns in familial frontotemporal lobar degeneration. *Neurology* 77, 384–392. doi:10.1212/WNL.0b013e3182270456 [PubMed: 21753175]
- Seeley WW, Allman JM, Carlin DA, Crawford RK, Macedo MN, Greicius MD, DeArmond SJ, Miller BL, 2007a Divergent social functioning in behavioral variant frontotemporal dementia and Alzheimer disease: reciprocal networks and neuronal evolution. *Alzheimer Dis Assoc Disord* 21, S50–S57. doi:10.1097/WAD.0b013e31815c0f14 [PubMed: 18090425]
- Seeley WW, Crawford R, Rascovsky K, Kramer JH, Weiner M, Miller BL, Gorno-Tempini ML, 2008 Frontal paralimbic network atrophy in very mild behavioral variant frontotemporal dementia. *Arch Neurol* 65. doi:10.1001/archneurol.2007.38
- Seeley WW, Crawford RK, Zhou J, Miller BL, Greicius MD, 2009 Neurodegenerative diseases target large-scale human brain networks. *Neuron* 62, 42–52. doi:10.1016/j.neuron.2009.03.024 [PubMed: 19376066]
- Seeley WW, Menon V, Schatzberg AF, Keller J, Glover GH, Kenna H, Reiss AL, Greicius MD, 2007b Dissociable intrinsic connectivity networks for salience processing and executive control. *J Neurosci* 27, 2349–2356. doi:10.1523/JNEUROSCI.5587-06.2007 [PubMed: 17329432]
- Sha SJ, Takada LT, Rankin KP, Yokoyama JS, Rutherford NJ, Fong JC, Khan B, Karydas A, Baker MC, DeJesus-Hernandez M, Pribadi M, Coppola G, Geschwind DH, Rademakers R, Lee SE, Seeley W, Miller BL, Boxer AL, 2012 Frontotemporal dementia due to C9ORF72 mutations: clinical and imaging features. *Neurology* 79, 1002–1011. doi:10.1212/WNL.0b013e318268452e [PubMed: 22875087]
- Shen D, Cui L, Fang J, Cui B, Li D, Tai H, 2016 Voxel-wise meta-analysis of gray matter changes in amyotrophic lateral sclerosis. *Front Aging Neurosci* 8, 64. doi:10.3389/fnagi.2016.00064 [PubMed: 27065078]
- Skibinski G, Parkinson NJ, Brown JM, Chakrabarti L, Lloyd SL, Hummerich H, Nielsen JE, Hodges JR, Spillantini MG, Thusgaard T, Brandner S, Brun A, Rossor MN, Gade A, Johannsen P, Sørensen SA, Gydesen S, Fisher EM, Collinge J, 2005 Mutations in the endosomal ESCRTIII-complex subunit CHMP2B in frontotemporal dementia. *Nat Genet* 37, 806–808. doi:10.1038/ng1609 [PubMed: 16041373]
- Skoglund L, Viitanen M, Kalimo H, Lannfelt L, Jonhagen ME, Ingelsson M, Glaser A, Herva R, 2008 The tau S305S mutation causes frontotemporal dementia with parkinsonism. *Eur J Neurol* 15, 156–161. doi:10.1111/j.1468-1331.2007.02017.x [PubMed: 18093153]
- Smith BN, Newhouse S, Shatunov A, Vance C, Topp S, Johnson L, Miller J, Lee Y, Troakes C, Scott KM, Jones A, Gray I, Wright J, Hortobágyi T, Al-Sarraj S, Rogelj B, Powell J, Lupton M, Lovestone S, Sapp PC, Weber M, Nestor PJ, Schelhaas HJ, Asbroek A.A. ten, Silani V, Gellera C, Taroni F, Ticozzi N, Van den Berg L, Veldink J, Van Damme P, Robberecht W, Shaw PJ, Kirby J, Pall H, Morrison KE, Morris A, de Belleruche J, Vianney de Jong JMB, Baas F, Andersen PM, Landers J, Brown RH, Weale ME, Al-Chalabi A, Shaw CE, 2013 The C9ORF72 expansion mutation is a common cause of ALS+/-FTD in Europe and has a single founder. *Eur J Hum Genet* 21, 102–108. doi:10.1038/ejhg.2012.98 [PubMed: 22692064]
- Smith R, Puschmann A, Schöll M, Ohlsson T, van Swieten J, Honer M, Englund E, Hansson O, 2016 ¹⁸F-AV-1451 tau PET imaging correlates strongly with tau neuropathology in *MAPT* mutation carriers. *Brain* 139, 2372–2379. doi:10.1093/brain/aww163 [PubMed: 27357347]
- Snowden JS, Goulding PJ, Neary D, 1989 Semantic dementia: a form of circumscribed cerebral atrophy. *Behav Neurol* 2, 167–182.
- Snowden JS, Rollinson S, Thompson JC, Harris JM, Stopford CL, Richardson AMT, Jones M, Gerhard A, Davidson YS, Robinson A, Gibbons L, Hu Q, DuPlessis D, Neary D, Mann DMA, Pickering-Brown SM, 2012 Distinct clinical and pathological characteristics of frontotemporal dementia associated with C9ORF72 mutations. *Brain* 135, 693–708. doi:10.1093/brain/awr355 [PubMed: 22300873]
- Solje E, Aaltokallio H, Koivumaa-Honkanen H, Suhonen NM, Moilanen V, Kiviharju A, Traynor B, Tienari PJ, Hartikainen P, Remes AM, 2015 The phenotype of the C9ORF72 expansion carriers according to revised criteria for bvFTD. *PLoS One* 10, e0131817. doi:10.1371/journal.pone.0131817 [PubMed: 26146826]

- Spillantini MG, Murrell JR, Goedert M, Farlow MR, Klug A, Ghetti B, 1998 Mutation in the tau gene in familial multiple system tauopathy with presenile dementia. *Proc Natl Acad Sci U S A* 95, 7737–7741. doi:10.1073/pnas.95.13.7737 [PubMed: 9636220]
- Spinelli EG, Agosta F, Ferraro PM, Riva N, Lunetta C, Falzone YM, Comi G, Falini A, Filippi M, 2016 Brain MR imaging in patients with lower motor neuronpredominant disease. *Radiology* 280, 545–556. doi:10.1148/radiol.2016151846 [PubMed: 26963576]
- Sreedharan J, Blair IP, Tripathi VB, Hu X, Vance C, Rogelj B, Ackerley S, Durnall JC, Williams KL, Buratti E, Baralle F, de Bellerocche J, Mitchell JD, Leigh PN, Al-Chalabi A, Miller CC, Nicholson G, Shaw CE, 2008 TDP-43 mutations in familial and sporadic amyotrophic lateral sclerosis. *Science* 319, 1668–1672. doi:10.1126/science.1154584 [PubMed: 18309045]
- Stanton BR, Shihmar D, Turner MR, Williams VC, Williams SCR, Blain CRV, Giampietro VP, Catani M, Leigh PN, Andersen PM, Simmons A, 2009 Diffusion tensor imaging in sporadic and familial (D90A SOD1) forms of amyotrophic lateral sclerosis. *Arch Neurol* 66. doi:10.1001/archneurol.2008.527
- Stanton BR, Williams VC, Leigh PN, Williams SCR, Blain CRV, Jarosz JM, Simmons A, 2007 Altered cortical activation during a motor task in ALS: evidence for involvement of central pathways. *J Neurol* 254, 1260–1267. doi:10.1007/s00415-006-0513-4 [PubMed: 17385077]
- Strong MJ, Abrahams S, Goldstein LH, Woolley S, McLaughlin P, Snowden J, Mioshi E, Roberts-South A, Benatar M, Hortobágyi T, Rosenfeld J, Silani V, Ince PG, Turner MR, 2017 Amyotrophic lateral sclerosis - frontotemporal spectrum disorder (ALS-FTSD): revised diagnostic criteria. *Amyotroph Lateral Scler Frontotemporal Degener* 18, 153–174. doi:10.1080/21678421.2016.1267768 [PubMed: 28054827]
- Sudre CH, Bocchetta M, Cash D, Thomas DL, Woollacott I, Dick KM, van Swieten J, Borroni B, Galimberti D, Masellis M, Tartaglia MC, Rowe JB, Graff C, Tagliavini F, Frisoni G, Laforce R, Finger E, de Mendonça A, Sorbi S, Ourselin S, Cardoso MJ, Rohrer JD, Andersson C, Archetti S, Arighi A, Benussi L, Binetti G, Black S, Cosseddu M, Fallström M, Ferreira C, Fenoglio C, Fox NC, Freedman M, Fumagalli G, Gazzina S, Ghidoni R, Grisoli M, Jelic V, Jiskoot L, Keren R, Lombardi G, Maruta C, Mead S, Meeter L, van Minkelen R, Nacmias B, Öjjerstedt L, Padovani A, Panman J, Pievani M, Polito C, Premi E, Prioni S, Rademakers R, Redaelli V, Rogaeva E, Rossi G, Rossor MN, Scarpini E, Tang-Wai D, Thonberg H, Tiraboschi P, Verdelho A, Warren JD, 2017 White matter hyperintensities are seen only in GRN mutation carriers in the GENFI cohort. *NeuroImage Clin* 15, 171–180. doi:10.1016/j.nicl.2017.04.015 [PubMed: 28529873]
- Sudre CH, Bocchetta M, Heller C, Convery R, Neason M, Moore KM, Cash DM, Thomas DL, Woollacott IOC, Foini M, Heslegrave A, Shafei R, Greaves C, van Swieten J, Moreno F, Sanchez-Valle R, Borroni B, Laforce R, Masellis M, Tartaglia MC, Graff C, Galimberti D, Rowe JB, Finger E, Synofzik M, Vandenberghe R, de Mendonça A, Tagliavini F, Santana I, Ducharme S, Butler C, Gerhard A, Levin J, Danek A, Frisoni GB, Sorbi S, Otto M, Zetterberg H, Ourselin S, Cardoso MJ, Rohrer JD, 2019 White matter hyperintensities in progranulin-associated frontotemporal dementia: A longitudinal GENFI study. *NeuroImage Clin* 24, 102077. doi:10.1016/j.nicl.2019.102077 [PubMed: 31835286]
- Sun L, Rong Z, Li W, Zheng H, Xiao S, Li X, 2018 Identification of a novel hemizygous SQSTM1 nonsense mutation in atypical behavioral variant frontotemporal dementia. *Front Aging Neurosci* 10, 26. doi:10.3389/fnagi.2018.00026 [PubMed: 29467647]
- Synofzik M, Born C, Rominger A, Lummel N, Schöls L, Biskup S, Schüle C, Grasshoff U, Klopstock T, Adamczyk C, 2014 Targeted high-throughput sequencing identifies a TARDBP mutation as a cause of early-onset FTD without motor neuron disease. *Neurobiol Aging* 35, 1212.e1–1212.e5. doi:10.1016/j.neurobiolaging.2013.10.092
- Synofzik M, Maetzler W, Grehl T, Prudlo J, vom Hagen JM, Haack T, Rebassoo P, Munz M, Schöls L, Biskup S, 2012 Screening in ALS and FTD patients reveals 3 novel UBQLN2 mutations outside the PXX domain and a pure FTD phenotype. *Neurobiol Aging* 33, 2949.e13–2949.e17. doi:10.1016/j.neurobiolaging.2012.07.002
- Tan RH, Kril JJ, Yang Y, Tom N, Hodges JR, Villemagne VL, Rowe CC, Leyton CE, Kwok JBJ, Ittner LM, Halliday GM, 2017 Assessment of amyloid β in pathologically confirmed frontotemporal dementia syndromes. *Alzheimers Dement (Amst)* 9, 10–20. doi:10.1016/j.dadm.2017.05.005 [PubMed: 28653036]

- Tateishi T, Hokonohara T, Yamasaki R, Miura S, Kikuchi H, Iwaki A, Tashiro H, Furuya H, Nagara Y, Ohyagi Y, Nukina N, Iwaki T, Fukumaki Y, Kira J, 2010 Multiple system degeneration with basophilic inclusions in Japanese ALS patients with FUS mutation. *Acta Neuropathol* 119, 355–364. doi:10.1007/s00401-009-0621-1 [PubMed: 19967541]
- Taylor JP, 2015 Multisystem proteinopathy: intersecting genetics in muscle, bone, and brain degeneration. *Neurology* 85, 658–660. doi:10.1212/WNL.0000000000001862 [PubMed: 26208960]
- Tedeschi G, Trojsi F, Tessitore A, Corbo D, Sagnelli A, Paccone A, D'Ambrosio A, Piccirillo G, Cirillo M, Cirillo S, Monsurrò MR, Esposito F, 2012 Interaction between aging and neurodegeneration in amyotrophic lateral sclerosis. *Neurobiol Aging* 33, 886–898. doi:10.1016/j.neurobiolaging.2010.07.011 [PubMed: 20739098]
- Teysou E, Chartier L, Albert M, Bouscary A, Antoine J-C, Camdessanché J-P, Rotolo F, Couratier P, Salachas F, Seilhean D, Millecamps S, 2016 Genetic analysis of CHCHD10 in French familial amyotrophic lateral sclerosis patients. *Neurobiol Aging* 42, 218.e1–218.e3. doi:10.1016/j.neurobiolaging.2016.03.022 [PubMed: 27095681]
- Tohnai G, Nakamura R, Sone J, Nakatochi M, Yokoi D, Katsuno M, Watanabe Hazuki, Watanabe Hirohisa, Ito M, Li Y, Izumi Y, Morita M, Taniguchi A, Kano O, Oda M, Kuwabara S, Abe K, Aiba I, Okamoto K, Mizoguchi K, Hasegawa K, Aoki M, Hattori N, Onodera O, Naruse H, Mitsui J, Takahashi Y, Goto J, Ishiura H, Morishita S, Yoshimura J, Doi K, Tsuji S, Nakashima K, Kaji R, Atsuta N, Sobue G, 2018 Frequency and characteristics of the TBK1 gene variants in Japanese patients with sporadic amyotrophic lateral sclerosis. *Neurobiol Aging* 64, 158.e15–158.e19. doi:10.1016/j.neurobiolaging.2017.12.005
- Tosun D, Schuff N, Rabinovici GD, Ayakta N, Miller BL, Jagust W, Kramer J, Weiner MM, Rosen HJ, 2016 Diagnostic utility of ASL-MRI and FDG-PET in the behavioral variant of FTD and AD. *Ann Clin Transl Neurol* 3, 740–751. doi:10.1002/acn3.330 [PubMed: 27752510]
- Trojsi F, Corbo D, Caiazzo G, Piccirillo G, Monsurrò MR, Cirillo S, Esposito F, Tedeschi G, 2013 Motor and extramotor neurodegeneration in amyotrophic lateral sclerosis: A 3T high angular resolution diffusion imaging (HARDI) study. *Amyotroph Lateral Scler Frontotemporal Degener* 14, 553–561. doi:10.3109/21678421.2013.785569 [PubMed: 23586325]
- Trojsi F, Esposito F, de Stefano M, Buonanno D, Conforti FL, Corbo D, Piccirillo G, Cirillo M, Monsurrò MR, Montella P, Tedeschi G, 2015 Functional overlap and divergence between ALS and bvFTD. *Neurobiol Aging* 36, 413–423. doi:10.1016/j.neurobiolaging.2014.06.025 [PubMed: 25063233]
- Tsai RM, Bejanin A, Lesman-Segev O, LaJoie R, Visani A, Bourakova V, O'Neil JP, Janabi M, Baker S, Lee SE, Perry DC, Bajorek L, Karydas A, Spina S, Grinberg LT, Seeley WW, Ramos EM, Coppola G, Gorno-Tempini ML, Miller BL, Rosen HJ, Jagust W, Boxer AL, Rabinovici GD, 2019 18F-flortaucipir (AV-1451) tau PET in frontotemporal dementia syndromes. *Alzheimers Res Ther* 11, 13. doi:10.1186/s13195-019-0470-7 [PubMed: 30704514]
- Tsujimoto M, Senda J, Ishihara T, Niimi Y, Kawai Y, Atsuta N, Watanabe H, Tanaka F, Naganawa S, Sobue G, 2011 Behavioral changes in early ALS correlate with voxel-based morphometry and diffusion tensor imaging. *J Neurol Sci* 307, 34–40. doi:10.1016/j.jns.2011.05.025 [PubMed: 21641004]
- Tu S, Leyton CE, Hodges JR, Piguet O, Hornberger M, 2015 Divergent longitudinal propagation of white matter degradation in logopenic and semantic variants of primary progressive aphasia. *J Alzheimers Dis* 49, 853–861. doi:10.3233/JAD-150626
- Turner MR, 2005 [11C]-WAY100635 PET demonstrates marked 5-HT1A receptor changes in sporadic ALS. *Brain* 128, 896–905. doi:10.1093/brain/awh428 [PubMed: 15689356]
- Turner MR, Hammers A, Al-Chalabi A, Shaw CE, Andersen PM, Brooks DJ, Leigh PN, 2005 Distinct cerebral lesions in sporadic and “D90A” SOD1 ALS: studies with [11C]flumazenil PET. *Brain* 128, 1323–1329. doi:10.1093/brain/awh509 [PubMed: 15843422]
- Turner MR, Hammers A, Allsop J, Al-Chalabi A, Shaw CE, Brooks DJ, Nigel Leigh P, Andersen PM, 2007a Volumetric cortical loss in sporadic and familial amyotrophic lateral sclerosis. *Amyotroph Lateral Scler* 8, 343–347. doi:10.1080/17482960701538734 [PubMed: 18033592]

- Turner MR, Rabiner EA, Al-Chalabi A, Shaw CE, Brooks DJ, Leigh PN, Andersen PM, 2007b Cortical 5-HT1A receptor binding in patients with homozygous D90A SOD1 vs sporadic ALS. *Neurology* 68, 1233–1235. doi:10.1212/01.wnl.0000259083.31837.64 [PubMed: 17420412]
- Ueno H, Kobatake K, Matsumoto M, Morino H, Maruyama H, Kawakami H, 2011 Severe brain atrophy after long-term survival seen in siblings with familial amyotrophic lateral sclerosis and a mutation in the optineurin gene: a case series. *J Med Case Rep* 5, 573. doi:10.1186/1752-1947-5-573 [PubMed: 22152722]
- Valsasina P, Agosta F, Benedetti B, Caputo D, Perini M, Salvi F, Prella A, Filippi M, 2006 Diffusion anisotropy of the cervical cord is strictly associated with disability in amyotrophic lateral sclerosis. *J Neurol Neurosurg Psychiatry* 78, 480–484. doi:10.1136/jnnp.2006.100032 [PubMed: 17030586]
- van der Burgh HK, Westeneng H-J, Meier JM, van Es MA, Veldink JH, Hendrikse J, van den Heuvel MP, van den Berg LH, 2019 Cross-sectional and longitudinal assessment of the upper cervical spinal cord in motor neuron disease. *NeuroImage: Clinical* 24, 101984. doi:10.1016/j.nicl.2019.101984
- van der Burgh HK, Westeneng H-J, Walhout R, van Veenhuijzen K, Tan HHG, Meier JM, Bakker LA, Hendrikse J, van Es MA, Veldink JH, van den Heuvel MP, van den Berg LH, 2020 Multimodal longitudinal study of structural brain involvement in amyotrophic lateral sclerosis. *Neurology* 94, e2592–e2604. doi:10.1212/WNL.0000000000009498 [PubMed: 32414878]
- van der Graaff MM, Sage CA, Caan MWA, Akkerman EM, Lavini C, Majoie CB, Nederveen AJ, Zwinderman AH, Vos F, Brugman F, van den Berg LH, de Rijk MC, van Doorn PA, Van Hecke W, Peeters RR, Robberecht W, Sunaert S, de Visser M, 2011 Upper and extra-motoneuron involvement in early motoneuron disease: a diffusion tensor imaging study. *Brain* 134, 1211–1228. doi:10.1093/brain/awr016 [PubMed: 21362631]
- van der Zee J, Pirici D, Van Langenhove T, Engelborghs S, Vandenberghe R, Hoffmann M, Pusswald G, Van den Broeck M, Peeters K, Mattheijssens M, Martin J-J, De Deyn PP, Cruts M, Haubenberger D, Kumar-Singh S, Zimprich A, Van Broeckhoven C, 2009 Clinical heterogeneity in 3 unrelated families linked to VCP p.Arg159His. *Neurology* 73, 626–632. doi:10.1212/WNL.0b013e3181b389d9 [PubMed: 19704082]
- van der Zee J, Urwin H, Engelborghs S, Bruyland M, Vandenberghe R, Dermaut B, De Pooter T, Peeters K, Santens P, De Deyn PP, Fisher EM, Collinge J, Isaacs AM, Van Broeckhoven C, 2008 CHMP2B C-truncating mutations in frontotemporal lobar degeneration are associated with an aberrant endosomal phenotype in vitro. *Hum Mol Genet* 17, 313–322. doi:10.1093/hmg/ddm309 [PubMed: 17956895]
- van der Zee J, Van Langenhove T, Kovacs GG, Dillen L, Deschamps W, Engelborghs S, Mat j R, Vandembulcke M, Sieben A, Dermaut B, Smets K, Van Damme P, Merlin C, Laureys A, Van Den Broeck M, Mattheijssens M, Peeters K, Benussi L, Binetti G, Ghidoni R, Borroni B, Padovani A, Archetti S, Pastor P, Razquin C, Ortega-Cubero S, Hernández I, Boada M, Ruiz A, de Mendonça A, Miltenberger-Miltényi G, do Couto FS, Sorbi S, Nacmias B, Bagnoli S, Graff C, Chiang H-H, Thonberg H, Pernecky R, Diehl-Schmid J, Alexopoulos P, Frisoni GB, Bonvicini C, Synofzik M, Maetzler W, vom Hagen JM, Schöls L, Haack TB, Strom TM, Prokisch H, Dols-Icardo O, Clarimón J, Lleó A, Santana I, Almeida MR, Santiago B, Heneka MT, Jessen F, Ramirez A, Sanchez-Valle R, Llado A, Gelpi E, Sarafov S, Tournev I, Jordanova A, Parobkova E, Fabrizi GM, Testi S, Salmon E, Ströbel T, Santens P, Robberecht W, De Jonghe P, Martin J-J, Cras P, Vandenberghe R, De Deyn PP, Cruts M, Sleegers K, Van Broeckhoven C, 2014 Rare mutations in SQSTM1 modify susceptibility to frontotemporal lobar degeneration. *Acta Neuropathol* 128, 397–410. doi:10.1007/s00401-014-1298-7 [PubMed: 24899140]
- van Herpen E, Rosso SM, Serverijnen L-A, Yoshida H, Breedveld G, Van De Graaf R, Kamphorst W, Ravid R, Willemsen R, Dooijes D, Majoor-Krakauer D, Kros JM, Crowther RA, Goedert M, Heutink P, Van Swieten JC, 2003 Variable phenotypic expression and extensive tau pathology in two families with the noveltau mutation L315R. *Ann Neurol* 54, 573–581. doi:10.1002/ana.10721 [PubMed: 14595646]
- Van Laere K, Vanhee A, Verschueren J, De Coster L, Driesen A, Dupont P, Robberecht W, Van Damme P, 2014 Value of ¹⁸fluorodeoxyglucose-positron-emission tomography in amyotrophic lateral sclerosis: a prospective study. *JAMA Neurol* 71, 553. doi:10.1001/jamaneurol.2014.62 [PubMed: 24615479]

- Van Mossevelde S, van der Zee J, Gijselinc I, Engelborghs S, Sieben A, Van Langenhove T, De Bleeker J, Baets J, Vandenbulcke M, Van Laere K, Ceyssens S, Van den Broeck M, Peeters K, Mattheijssens M, Cras P, Vandenberghe R, De Jonghe P, Martin J-J, De Deyn PP, Cruts M, Van Broeckhoven C, 2016 Clinical features of *TBK1* carriers compared with *C9orf72*, *GRN* and non-mutation carriers in a Belgian cohort. *Brain* 139, 452–467. doi:10.1093/brain/awv358 [PubMed: 26674655]
- Van Swieten JC, Stevens M, Rosso SM, Rizzu P, Joosse M, De Koning I, Kamphorst W, Ravid R, Spillantini MG, Niermeijer MF, Heutink P, 1999 Phenotypic variation in hereditary frontotemporal dementia with tau mutations. *Ann Neurol* 46, 617–626. doi:10.1002/1531-8249(199910)46:4<617::AID-ANA10>3.0.CO;2-I [PubMed: 10514099]
- Varma AR, Adams W, Lloyd JJ, Carson KJ, Snowden JS, Testa HJ, Jackson A, Neary D, 2002 Diagnostic patterns of regional atrophy on MRI and regional cerebral blood flow change on SPECT in young onset patients with Alzheimer's disease, frontotemporal dementia and vascular dementia. *Acta Neurol Scand* 105, 261–269. doi:10.1034/j.1600-0404.2002.1o148.x [PubMed: 11939938]
- Vengoechea J, David MP, Yaghi SR, Carpenter L, Rudnicki SA, 2013 Clinical variability and female penetrance in X-linked familial FTD/ALS caused by a P506S mutation in UBQLN2. *Amyotroph Lateral Scler Frontotemporal Degener* 14, 615–619. doi:10.3109/21678421.2013.824001 [PubMed: 23944734]
- Verfaillie SCJ, Adriaanse SM, Binnewijzend MAA, Benedictus MR, Ossenkuppe R, Wattjes MP, Pijnenburg YAL, van der Flier WM, Lammertsma AA, Kuijper JPA, Boellaard R, Scheltens P, van Berckel BNM, Barkhof F, 2015 Cerebral perfusion and glucose metabolism in Alzheimer's disease and frontotemporal dementia: two sides of the same coin? *Eur Radiol* 25, 3050–3059. doi:10.1007/s00330-015-3696-1 [PubMed: 25899416]
- Verschueren J, Vanhee A, De Coster L, Van Damme P, Van Laere K, 2013 Impact of the C9Orf72 expansion on brain glucose metabolism in ALS patients. *J Nucl Med* 54, 155–155.
- Viassolo V, Previtali S, Schiatti E, Magnani G, Minetti C, Zara F, Grasso M, Dagnà-Bricarelli F, Di Maria E, 2008 Inclusion body myopathy, Paget's disease of the bone and frontotemporal dementia: recurrence of the VCP R155H mutation in an Italian family and implications for genetic counselling. *Clin Genet* 74, 54–60. doi:10.1111/j.1399-0004.2008.00984.x [PubMed: 18341608]
- Vijverberg EGB, Wattjes MP, Dols A, Krudop WA, Möller C, Peters A, Kerssens CJ, Gossink F, Prins ND, Stek ML, Scheltens P, van Berckel BNM, Barkhof F, Pijnenburg YAL, 2016 Diagnostic accuracy of MRI and additional [18F]FDG-PET for behavioral variant frontotemporal dementia in patients with late onset behavioral changes. *J Alzheimers Dis* 53, 1287–1297. doi:10.3233/JAD-160285 [PubMed: 27372646]
- Vucic S, Winhammar JMC, Rowe DB, Kiernan MC, 2010 Corticomotoneuronal function in asymptomatic SOD-1 mutation carriers. *Clin Neurophysiol* 121, 1781–1785. doi:10.1016/j.clinph.2010.02.164 [PubMed: 20362497]
- Walhout R, Schmidt R, Westeneng H-J, Verstraete E, Seelen M, van Rheenen W, de Reus MA, van Es MA, Hendrikse J, Veldink JH, van den Heuvel MP, van den Berg LH, 2015a Brain morphologic changes in asymptomatic *C9orf72* repeat expansion carriers. *Neurology* 85, 1780–1788. doi:10.1212/WNL.0000000000002135 [PubMed: 26497991]
- Walhout R, Westeneng H-J, Verstraete E, Hendrikse J, Veldink JH, van den Heuvel MP, van den Berg LH, 2015b Cortical thickness in ALS: towards a marker for upper motor neuron involvement. *J Neurol Neurosurg Psychiatry* 86, 288–294. doi:10.1136/jnnp-2013-306839 [PubMed: 25121571]
- Wang YT, Edison P, 2019 Tau imaging in neurodegenerative diseases using positron emission tomography. *Curr Neurol Neurosci Rep* 19, 45. doi:10.1007/s11910-019-0962-7 [PubMed: 31172290]
- Watts GDJ, Wymer J, Kovach MJ, Mehta SG, Mumm S, Darvish D, Pestronk A, Whyte MP, Kimonis VE, 2004 Inclusion body myopathy associated with Paget disease of bone and frontotemporal dementia is caused by mutant valosin-containing protein. *Nat Genet* 36, 377–381. doi:10.1038/ng1332 [PubMed: 15034582]
- Weber M, Eisen A, Stewart HG, Andersen PM, 2000 Preserved slow conducting corticomotoneuronal projections in amyotrophic lateral sclerosis with autosomal recessive D90A CuZn-superoxide

- dismutase mutation. *Brain* 123 (Pt 7), 1505–1515. doi:10.1093/brain/123.7.1505 [PubMed: 10869061]
- Weidberg H, Elazar Z, 2011 TBK1 mediates crosstalk between the innate immune response and autophagy. *Sci Signal* 4, p e39. doi:10.1126/scisignal.2002355
- Wen J, Zhang H, Alexander DC, Durrleman S, Routier A, Rinaldi D, Houot M, Couratier P, Hannequin D, Pasquier F, Zhang J, Colliot O, Le Ber I, Bertrand A, 2018 Neurite density is reduced in the presymptomatic phase of *C9orf72* disease. *J Neurol Neurosurg Psychiatry* 90, 387–394. doi:10.1136/jnnp-2018-318994 [PubMed: 30355607]
- Westeneng HJ, Verstraete E, Walhout R, Schmidt R, Hendrikse J, Veldink JH, van den Heuvel MP, van den Berg LH, 2015 Subcortical structures in amyotrophic lateral sclerosis. *Neurobiol Aging* 36, 1075–1082. doi:10.1016/j.neurobiolaging.2014.09.002 [PubMed: 25281019]
- Westeneng HJ, Walhout R, Straathof M, Schmidt R, Hendrikse J, Veldink JH, van den Heuvel MP, van den Berg LH, 2016 Widespread structural brain involvement in ALS is not limited to the *C9orf72* repeat expansion. *J Neurol Neurosurg Psychiatry* 87, 1354–1360. doi:10.1136/jnnp-2016-313959 [PubMed: 27756805]
- Westeneng HJ, Wismans C, Nitert A, Walhout R, Lujiten P, Wijnen J, van den Berg LH, 2017 Metabolic differences between asymptomatic *C9orf72* carriers and non-carriers assessed by brain 7T MRSI. Proceedings of the 25th Annual Meeting of ISMRM, Honolulu, USA Abstract 0028.
- Whitwell JL, Avula R, Senjem ML, Kantarci K, Weigand SD, Samikoglu A, Edmonson HA, Vemuri P, Knopman DS, Boeve BF, Petersen RC, Josephs KA, Jack CR, 2010 Gray and white matter water diffusion in the syndromic variants of frontotemporal dementia. *Neurology* 74, 1279–1287. doi:10.1212/WNL.0b013e3181d9edde [PubMed: 20404309]
- Whitwell JL, Boeve BF, Weigand SD, Senjem ML, Gunter JL, Baker MC, DeJesus-Hernandez M, Knopman DS, Wszolek ZK, Petersen RC, Rademakers R, Jack CR, Josephs KA, 2015 Brain atrophy over time in genetic and sporadic frontotemporal dementia: a study of 198 serial magnetic resonance images. *Eur J Neurol* 22, 745–752. doi:10.1111/ene.12675 [PubMed: 25683866]
- Whitwell JL, Jack CR, Baker M, Rademakers R, Adamson J, Boeve BF, Knopman DS, Parisi JF, Petersen RC, Dickson DW, Hutton ML, Josephs KA, 2007a Voxel-based morphometry in frontotemporal lobar degeneration with ubiquitin-positive inclusions with and without progranulin mutations. *Arch Neurol* 64, 371. doi:10.1001/archneur.64.3.371 [PubMed: 17353379]
- Whitwell JL, Jack CR, Boeve BF, Senjem ML, Baker M, Ivnik RJ, Knopman DS, Wszolek ZK, Petersen RC, Rademakers R, Josephs KA, 2009a Atrophy patterns in IVS10+16, IVS10+3, N279K, S305N, P301L, and V337M MAPT mutations. *Neurology* 73, 1058–1065. doi:10.1212/WNL.0b013e3181b9c8b9 [PubMed: 19786698]
- Whitwell JL, Jack CR, Boeve BF, Senjem ML, Baker M, Rademakers R, Ivnik RJ, Knopman DS, Wszolek ZK, Petersen RC, Josephs KA, 2009b Voxel-based morphometry patterns of atrophy in FTLTD with mutations in MAPT or PGRN. *Neurology* 72, 813–820. doi:10.1212/01.wnl.0000343851.46573.67 [PubMed: 19255408]
- Whitwell JL, Josephs KA, Avula R, Tosakulwong N, Weigand SD, Senjem ML, Vemuri P, Jones DT, Gunter JL, Baker M, Wszolek ZK, Knopman DS, Rademakers R, Petersen RC, Boeve BF, Jack CR, 2011 Altered functional connectivity in asymptomatic MAPT subjects: a comparison to bvFTD. *Neurology* 77, 866–874. doi:10.1212/WNL.0b013e31822c61f2 [PubMed: 21849646]
- Whitwell JL, Sampson EL, Loy CT, Warren JE, Rossor MN, Fox NC, Warren JD, 2007b VBM signatures of abnormal eating behaviours in frontotemporal lobar degeneration. *NeuroImage* 35, 207–213. doi:10.1016/j.neuroimage.2006.12.006 [PubMed: 17240166]
- Whitwell JL, Weigand SD, Boeve BF, Senjem ML, Gunter JL, DeJesus-Hernandez M, Rutherford NJ, Baker M, Knopman DS, Wszolek ZK, Parisi JE, Dickson DW, Petersen RC, Rademakers R, Jack CR, Josephs KA, 2012 Neuroimaging signatures of frontotemporal dementia genetics: *C9ORF72*, tau, progranulin and sporadics. *Brain* 135, 794–806. doi:10.1093/brain/aws001 [PubMed: 22366795]
- Wilke C, Baets J, De Bleecker JL, Deconinck T, Biskup S, Hayer SN, Züchner S, Schüle R, De Jonghe P, Synofzik M, 2018 Beyond ALS and FTD: the phenotypic spectrum of TBK1 mutations

includes PSP-like and cerebellar phenotypes. *Neurobiol Aging* 62, 244.e9–244.e13. doi:10.1016/j.neurobiolaging.2017.10.010

- Wong CH, Topp S, Gkazi AS, Troakes C, Miller JW, de Majo M, Kirby J, Shaw PJ, Morrison KE, de Bellerocche J, Vance CA, Al-Chalabi A, Al-Sarraj S, Shaw CE, Smith BN, 2015 The CHCHD10 P34S variant is not associated with ALS in a UK cohort of familial and sporadic patients. *Neurobiol Aging* 36, 2908.e17–2908.e18. doi:10.1016/j.neurobiolaging.2015.07.014
- Wongworawat YC, Liu YA, Raghavan R, White CL, Dietz R, Zuppan C, Rosenfeld J, 2020 Aggressive FUS-mutant motor neuron disease without profound spinal cord pathology. *J Neuropath Exp Neur* 79, 365–369. doi:10.1093/jnen/nlaa011 [PubMed: 32142142]
- Woollacott IOC, Bocchetta M, Sudre CH, Ridha BH, Strand C, Courtney R, Ourselin S, Cardoso MJ, Warren JD, Rossor MN, Revesz T, Fox NC, Holton JL, Lashley T, Rohrer JD, 2018 Pathological correlates of white matter hyperintensities in a case of progranulin mutation associated frontotemporal dementia. *Neurocase* 24, 166–174. doi:10.1080/13554794.2018.1506039 [PubMed: 30112957]
- Woolley JD, Gorno-Tempini M-L, Seeley WW, Rankin K, Lee SS, Matthews BR, Miller BL, 2007 Binge eating is associated with right orbitofrontal-insular-striatal atrophy in frontotemporal dementia. *Neurology* 69, 1424–1433. doi:10.1212/01.wnl.0000277461.06713.23 [PubMed: 17909155]
- Wu L, Liu J, Feng X, Dong J, Qin W, Liu Y, Wang J, Lu J, Chen K, Wang Y, Jia J, 2018 11C-CFT-PET in presymptomatic FTDP-17: a potential biomarker predicting onset. *J Alzheimers Dis* 61, 613–618. doi:10.3233/JAD-170561 [PubMed: 29226866]
- Xia Q, Wang G, Wang H, Hu Q, Ying Z, 2016 Folliculin, a tumor suppressor associated with Birt–Hogg–Dubé (BHD) syndrome, is a novel modifier of TDP-43 cytoplasmic translocation and aggregation. *Hum Mol Genet* 25, 83–96. doi:10.1093/hmg/ddv450 [PubMed: 26516189]
- Yamashita T, Hatakeyama T, Sato K, Fukui Y, Hishikawa N, Ohta Y, Nishiyama Y, Kawai N, Tamiya T, Abe K, 2017 Flow-metabolism uncoupling in the cervical spinal cord of ALS patients. *Neurol Sci* 38, 659–665. doi:10.1007/s10072-017-2823-y [PubMed: 28120243]
- Yan J, Deng H-X, Siddique N, Fecto F, Chen W, Yang Y, Liu E, Donkervoort S, Zheng JG, Shi Y, Ahmeti KB, Brooks B, Engel WK, Siddique T, 2010 Frameshift and novel mutations in FUS in familial amyotrophic lateral sclerosis and ALS/dementia. *Neurology* 75, 807–814. doi:10.1212/WNL.0b013e3181f07e0c [PubMed: 20668259]
- Ygland E, van Westen D, Englund E, Rademakers R, Wszolek ZK, Nilsson K, Nilsson C, Landqvist Waldö M, Alafuzoff I, Hansson O, Gustafson L, Puschmann A, 2018 Slowly progressive dementia caused by MAPT R406W mutations: longitudinal report on a new kindred and systematic review. *Alzheimers Res Ther* 10, 2. doi:10.1186/s13195-017-0330-2 [PubMed: 29370822]
- Yilmaz R, Müller K, Brenner D, Volk AE, Borck G, Hermann A, Meitinger T, Strom TM, Danzer KM, Ludolph AC, Andersen PM, Weishaupt JH, Weyen U, Hermann A, Regensburger M, Winkler J, Linker R, Winner B, Hagenacker T, Koch JC, Lingor P, Göricke B, Zierz S, Jordan B, Baum P, Wolf J, Winkler A, Young P, Bogdahn U, Prudlo J, Kassubek J, 2020 SQSTM1/p62 variants in 486 patients with familial ALS from Germany and Sweden. *Neurobiol Aging* 87, 139.e9–139.e15. doi:10.1016/j.neurobiolaging.2019.10.018
- Young AL, Marinescu RV, Oxtoby NP, Bocchetta M, Yong K, Firth NC, Cash DM, Thomas DL, Dick KM, Cardoso J, van Swieten J, Borroni B, Galimberti D, Masellis M, Tartaglia MC, Rowe JB, Graff C, Tagliavini F, Frisoni GB, Laforce R, Finger E, de Mendonça A, Sorbi S, Warren JD, Crutch S, Fox NC, Ourselin S, Schott JM, Rohrer JD, Alexander DC, Andersson C, Archetti S, Arighi A, Benussi L, Binetti G, Black S, Cosseddu M, Fallström M, Ferreira C, Fenoglio C, Freedman M, Fumagalli GG, Gazzina S, Ghidoni R, Grisoli M, Jelic V, Jiskoot L, Keren R, Lombardi G, Maruta C, Meeter L, Mead S, van Minkelen R, Nacmias B, Öjjerstedt L, Padovani A, Panman J, Pievani M, Polito C, Premi E, Prioni S, Rademakers R, Redaelli V, Rogava E, Rossi G, Rossor M, Scarpini E, Tang-Wai D, Thonberg H, Tiraboschi P, Verdelho A, Weiner MW, Aisen P, Petersen R, Jack CR, Jagust W, Trojanowki JQ, Toga AW, Beckett L, Green RC, Saykin AJ, Morris J, Shaw LM, Khachaturian Z, Sorensen G, Kuller L, Raichle M, Paul S, Davies P, Fillit H, Hefti F, Holtzman D, Mesulam MM, Potter W, Snyder P, Schwartz A, Montine T, Thomas RG, Donohue M, Walter S, Gessert D, Sather T, Jimenez G, Harvey D, Bernstein M,

Thompson P, Schuff N, Borowski B, Gunter J, Senjem M, Vemuri P, Jones D, Kantarci K, Ward C, Koeppe RA, Foster N, Reiman EM, Chen K, Mathis C, Landau S, Cairns NJ, Householder E, Taylor-Reinwald L, Lee V, Korecka M, Figurski M, Crawford K, Neu S, Foroud TM, Potkin S, Shen L, Faber K, Kim S, Nho K, Thal L, Buckholtz N, Albert Marylyn, Frank R, Hsiao J, Kaye J, Quinn J, Lind B, Carter R, Dolen S, Schneider LS, Pawluczyk S, Beccera M, Teodoro L, Spann BM, Brewer J, Vanderswag H, Fleisher A, Heidebrink JL, Lord JL, Mason SS, Albers CS, Knopman D, Johnson Kris, Doody RS, Villanueva-Meyer J, Chowdhury M, Rountree S, Dang M, Stern Y, Honig LS, Bell KL, Ances B, Carroll M, Leon S, Mintun MA, Schneider S, Oliver A, Marson D, Griffith R, Clark D, Geldmacher D, Brockington J, Roberson E, Grossman H, Mitsis E, de Toledo-Morrell L, Shah RC, Duara R, Varon D, Greig MT, Roberts P, Albert Marilyn, Onyike C, D'Agostino D, Kielb S, Galvin JE, Cerbone B, Michel CA, Rusinek H, de Leon MJ, Glodzik L, De Santi S, Doraiswamy PM, Petrella JR, Wong TZ, Arnold SE, Karlawish JH, Wolk D, Smith CD, Jicha G, Hardy P, Sinha P, Oates E, Conrad G, Lopez OL, Oakley M, Simpson DM, Porsteinsson AP, Goldstein BS, Martin K, Makino KM, Ismail MS, Brand C, Mulnard RA, Thai G, Mc-Adams-Ortiz C, Womack K, Mathews D, Quiceno M, Diaz-Arrastia R, King R, Weiner M, Martin-Cook K, DeVos M, Levey AI, Lah JJ, Cellar JS, Burns JM, Anderson HS, Swerdlow RH, Apostolova L, Tingus K, Woo E, Silverman DH, Lu PH, Bartzokis G, Graff-Radford NR, Parfitt F, Kendall T, Johnson H, Farlow MR, Hake AM, Matthews BR, Herring S, Hunt C, van Dyck CH, Carson RE, MacAvoy MG, Chertkow H, Bergman H, Hosein C, Stefanovic B, Caldwell C, Hsiung G-YR, Feldman H, Mudge B, Assaly M, Kertesz A, Rogers J, Bernick C, Munic D, Kerwin D, Mesulam M-M, Lipowski K, Wu C-K, Johnson N, Sadowsky C, Martinez W, Villena T, Turner RS, Johnson Kathleen, Reynolds B, Sperling RA, Johnson KA, Marshall G, Frey M, Lane B, Rosen A, Tinklenberg J, Sabbagh MN, Belden CM, Jacobson SA, Sirrel SA, Kowall N, Killiany R, Budson AE, Norbash A, Johnson PL, Allard J, Lerner A, Ogrocki P, Hudson L, Fletcher E, The Genetic FTD Initiative (GENFI), The Alzheimer's Disease Neuroimaging Initiative (ADNI), 2018 Uncovering the heterogeneity and temporal complexity of neurodegenerative diseases with Subtype and Stage Inference. *Nat Commun* 9, 1–16. doi:10.1038/s41467-018-05892-0 [PubMed: 29317637]

- Yu C-E, Bird TD, Bekris LM, Montine TJ, Leverenz JB, Steinbart E, Galloway NM, Feldman H, Woltjer R, Miller CA, Wood EM, Grossman M, McCluskey L, Clark CM, Neumann M, Danek A, Galasko DR, Arnold SE, Chen-Plotkin A, Karydas A, Miller BL, Trojanowski JQ, Lee VM-Y, Schellenberg GD, Van Deerlin VM, 2010 The spectrum of mutations in progranulin: a collaborative study screening 545 cases of neurodegeneration. *Arch Neurol* 67, 161–170. doi:10.1001/archneurol.2009.328 [PubMed: 20142524]
- Yu H, Yu W, Luo S, Yang Y, Liu F, Zhang Y, Chen Y, Sun Y, Wu J, 2019 Association of the *TBK1* mutation p.Ile334Thr with frontotemporal dementia and literature review. *Mol Genet Genom Med* 7, e547. doi:10.1002/mgg3.547
- Zhang M, Xi Z, Zinman L, Bruni AC, Maletta RG, Curcio SAM, Rainero I, Rubino E, Pinessi L, Nacmias B, Sorbi S, Galimberti D, Lang AE, Fox S, Surace EI, Ghani M, Guo J, Sato C, Moreno D, Liang Y, Keith J, Traynor BJ, St George-Hyslop P, Rogaeva E, 2015 Mutation analysis of *CHCHD10* in different neurodegenerative diseases. *Brain* 138, e380–e380. doi:10.1093/brain/awv082 [PubMed: 25833818]
- Zhang Y, Tartaglia MC, Schuff N, Chiang GC, Ching C, Rosen HJ, Gorno-Tempini ML, Miller BL, Weiner MW, 2013 MRI signatures of brain macrostructural atrophy and microstructural degradation in frontotemporal lobar degeneration subtypes. *J Alzheimers Dis* 33, 431–444. doi:10.3233/JAD-2012-121156 [PubMed: 22976075]
- Zhou B, Wang H, Cai Y, Wen H, Wang L, Zhu M, Chen Y, Yu Y, Lu X, Zhou M, Fang P, Li X, Hong D, 2020 *FUS* P525L mutation causing amyotrophic lateral sclerosis and movement disorders. *Brain Behav* 10, e01625. doi:10.1002/brb3.1625 [PubMed: 32307925]
- Zhou J, Greicius MD, Gennatas ED, Growdon ME, Jang JY, Rabinovici GD, Kramer JH, Weiner M, Miller BL, Seeley WW, 2010 Divergent network connectivity changes in behavioural variant frontotemporal dementia and Alzheimer's disease. *Brain* 133, 1352–1367. doi:10.1093/brain/awq075 [PubMed: 20410145]

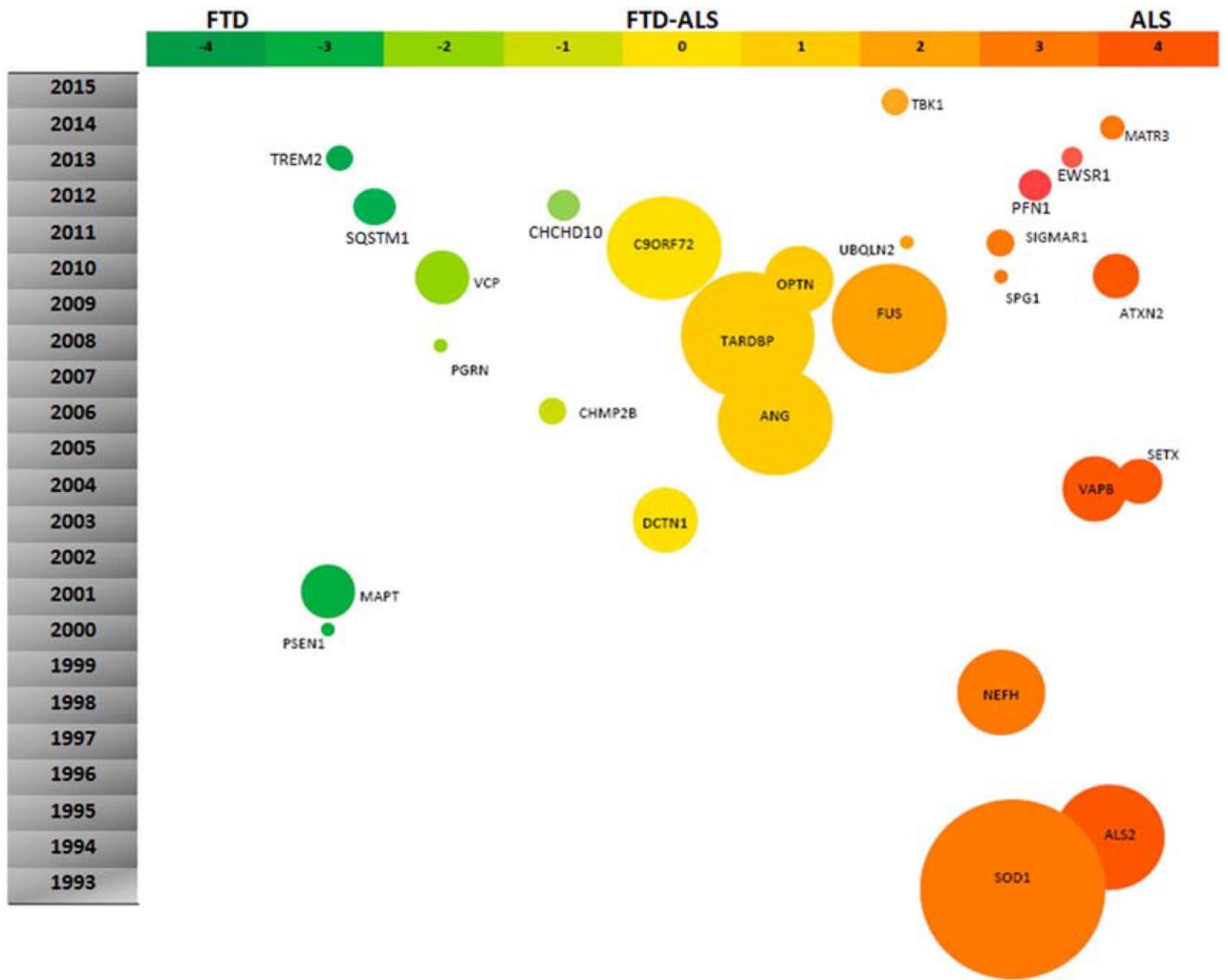


Fig. 1. Genes whose mutations are associated with FTD-ALS spectrum disorders. Reprinted from Kumar et al. (2016) with permission from Elsevier.

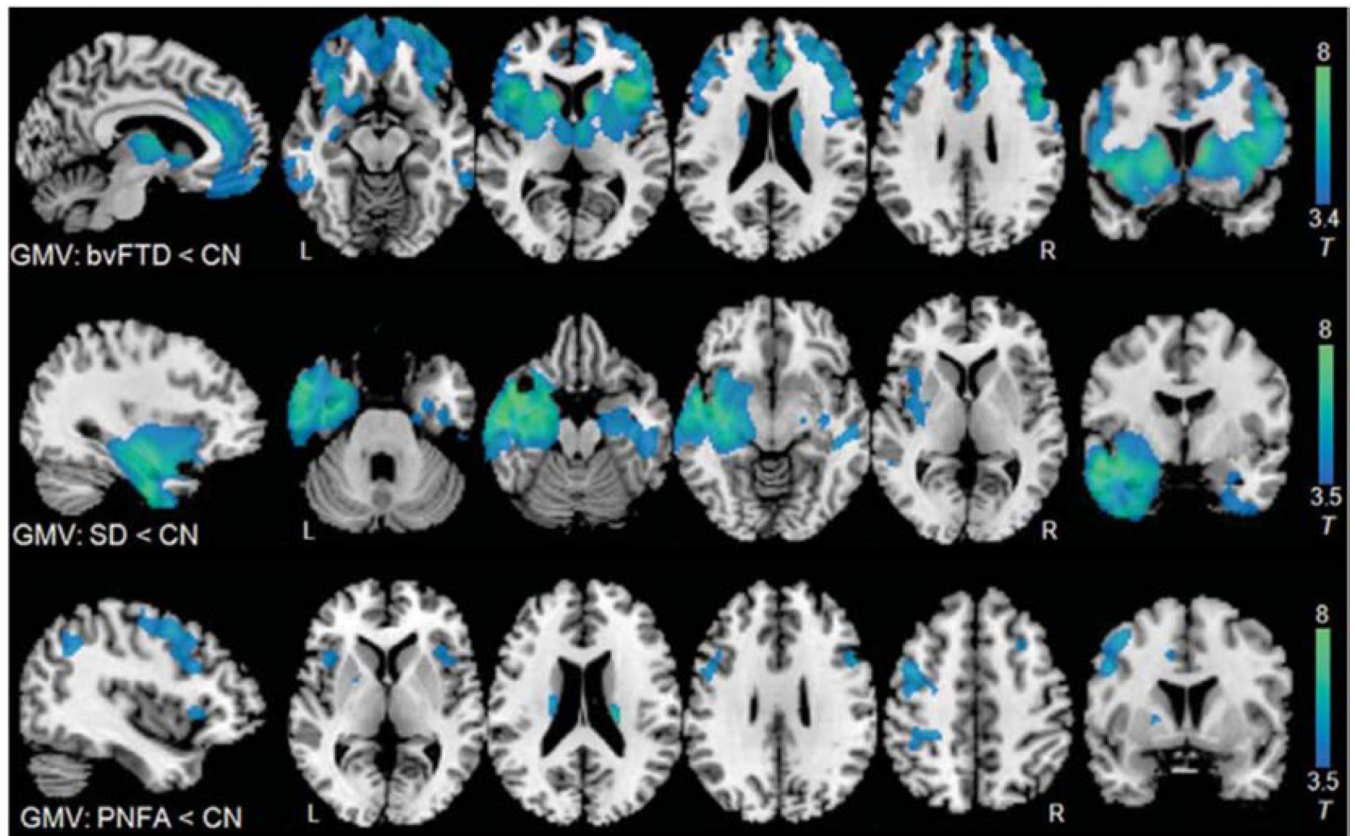


Fig. 2. Comparison of grey matter atrophy patterns in three FTD syndromes. Patients with bvFTD, svPPA, nfvPPA were compared to healthy age-matched control subjects using voxel-based morphometry. Maps are thresholded at $p < 0.001$ uncorrected and superimposed on a study-specific template. BvFTD, behavioral variant frontotemporal dementia; SD, semantic dementia, also known as semantic variant PPA; PNFA, progressive nonfluent aphasia, also known as nonfluent variant PPA; GMV, grey-matter volume. Adapted from Zhang et al. (2013).

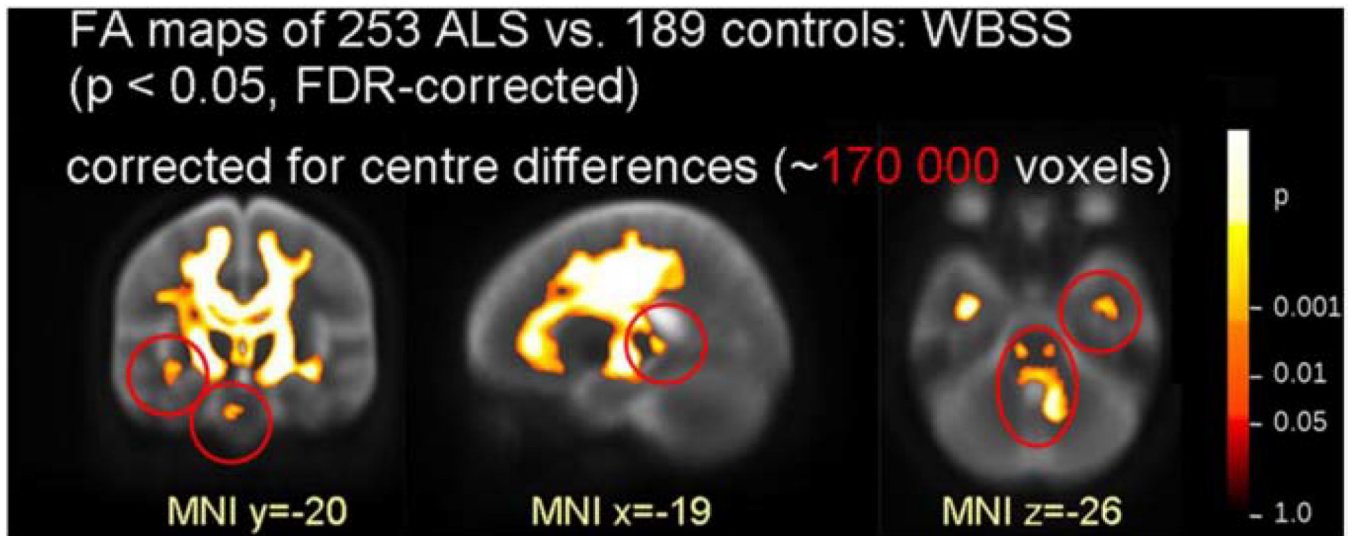


Fig. 3.

White-matter involvement in sporadic ALS revealed by a multi-site DTI study. FA decreases were found along the corticospinal tracts, frontal lobe, brainstem and hippocampi. Red circles indicate deficits only significant with correction for site differences. ALS, amyotrophic lateral sclerosis; WBSS, whole-brain-based spatial statistics; FA, fractional anisotropy; FDR, false discovery rate. Adapted from Müller et al. (2016) with permission from BMJ Publishing Group Ltd.

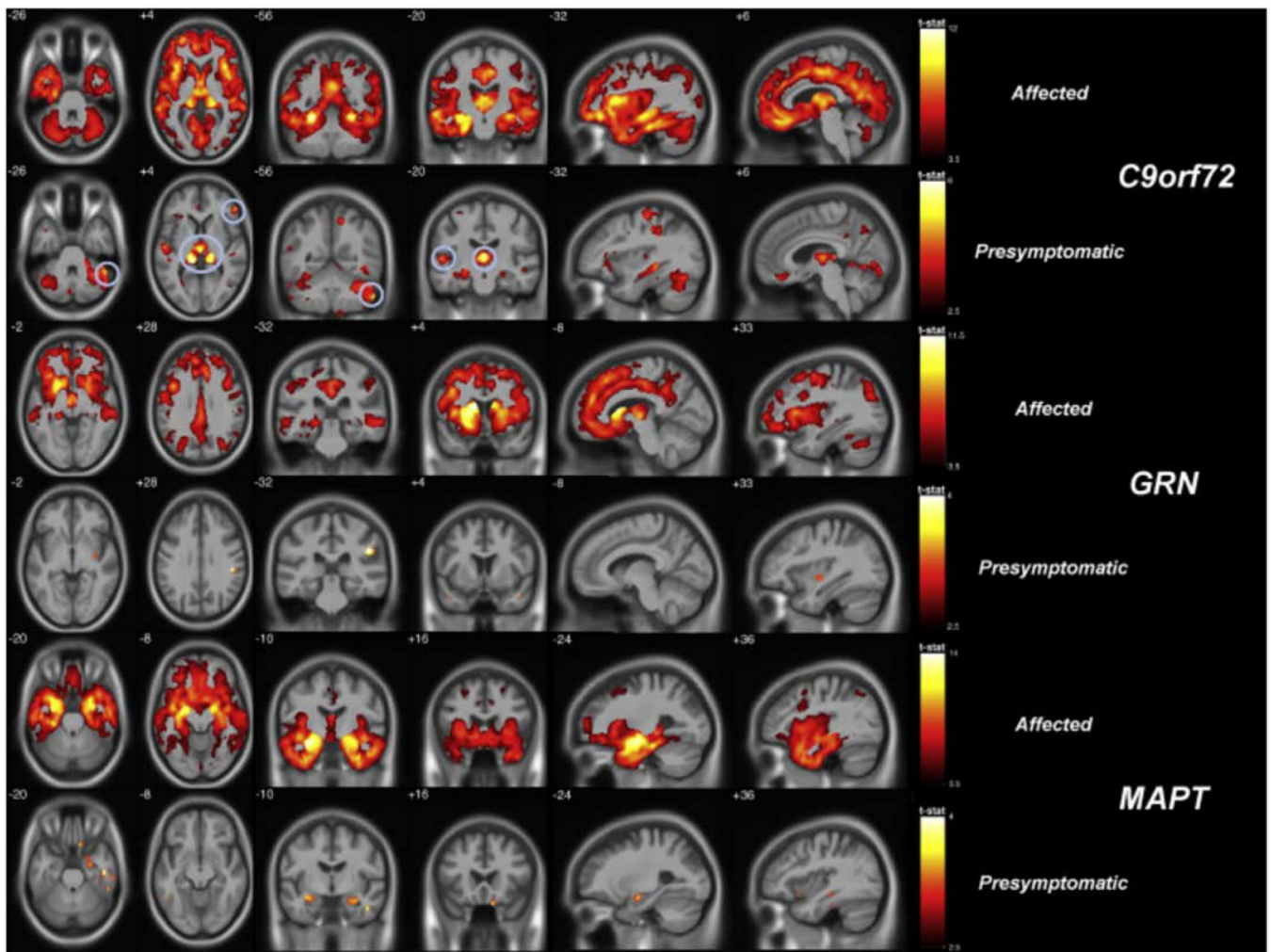


Fig. 4. Gray matter deficits in FTD mutation carriers measured by voxel-based morphometry. In both affected (symptomatic) and presymptomatic stages of disease, carriers of the *C9orf72* expansion, *MAPT* and *GRN* mutations each exhibited distinct atrophy patterns with overlap in frontotemporal cortex and insula. Both *C9orf72* and *GRN* feature parieto-occipital atrophy in addition to frontotemporal atrophy, while *MAPT* targets the mesial temporal lobe. In the presymptomatic *C9orf72* group, circles indicate significantly low gray matter volume in the thalamus. Maps illustrate brain regions with reduced grey matter probability in affected ($p < 0.05$ FWE-corrected) and presymptomatic ($p < 0.001$ uncorrected) carriers compared to noncarriers. FTD, frontotemporal dementia; FWE, familywise error rate. Reprinted from Cash et al. (2018).