

UC Riverside

UC Riverside Previously Published Works

Title

3 dimensional diagnosis unravelling prognosis of multiple impacted teeth - a case report.

Permalink

<https://escholarship.org/uc/item/0hw5x39t>

Journal

Journal of International Oral Health, 5(4)

ISSN

0976-7428

Authors

Gopinath, Adusumilli
Reddy, Naveen Admala
Rohra, Mayur G

Publication Date

2013-08-01

Peer reviewed

3 Dimensional Diagnosis Unravelling Prognosis of Multiple Impacted Teeth – A Case Report

Adusumilli Gopinath¹, Naveen Admala Reddy², Mayur G Rohra³

¹Professor, Department of Orthodontics, AME'S Dental College and Hospital, Raichur, Karnataka, India; ²Professor & Head, Department of Orthodontics, AME'S Dental College and Hospital, Raichur, Karnataka, India; ³Post Graduate Student, Department of Orthodontics, AME'S Dental College and Hospital, Raichur, Karnataka, India.

ABSTRACT

Impaction of teeth results from the interplay between nature and nurture. Radiographs play an important role in assessment of both the location and the typing of impacted teeth. In general, periapical, occlusal, and/or panoramic radiographs are sufficient for providing the information required by the clinician. Recent advances in diagnostic imaging enables to visualize, diagnose and prognose the treatment outcome of the impacted teeth. This case report discusses the value of cone beam computerized tomography (CBCT) for evaluation of the critical parameters like bone thickness, tooth position and tooth morphology of multiple impacted teeth by 3 dimensional radiography – CBCT. In this report, we present a case of 27-year-old male patient with multiple missing teeth. Radiographs revealed multiple impacted permanent teeth, though medical and family history along with physical examination was not suggestive of any syndromes.

Intraoral periapical radiograph, Orthopantomograph, Occlusal radiograph, Cone beam computed tomography were taken for the same patient to determine the exact position of multiple impacted teeth and prognose the treatment plan with the associated factors to impacted teeth. Cone beam computed tomography is an accurate modality to localize and determine the prognosing factors associated with multiple impacted teeth. Three-dimensional volumetric imaging might provide information for improved diagnosis and treatment plans, and ultimately result in more successful treatment outcomes and better care for patients.

Key Words: 3 Dimensional Radiography, Multiple Impacted Teeth, Cone Beam Computed Tomography.

How to cite this article: Gopinath A, Reddy NA, Rohra MG. 3 Dimensional Diagnosis Unravelling Prognosis of Multiple Impacted Teeth – A Case Report. *J Int Oral Health* 2013; 5(4):78-83.

Source of Support: Nil

Conflict of Interest: None Declared

Received: 24th February 2013

Reviewed: 14th March 2013

Accepted: 28th June 2013

Address for Correspondence: Dr. Mayur G Rohra. Post Graduate Student, Department of Orthodontics, AME'S Dental College and Hospital, Near Government Polytechnic College, Bijengere Road, Raichur- 584103. Karnataka, India. Phone: +91 – 7411285740. e-mail: mayurrohra86@yahoo.com

Introduction

Impaction refers to a failure of a tooth to emerge into the dental arch, usually due to either space deficiencies or the presence of an entity blocking its path of eruption. Although heredity has long been described as playing a role, many times the etiology is unknown. Impacted teeth are commonly found in the dental practice and they pose a threat for the maintenance and continuity of dental health.

Primarily because of their eruption pattern and sequence, canines are especially prone to impaction and the maxillary canines are affected 20 times more frequently than mandibular canines¹.

Sequelae of impaction

Shafer, Hine, and Levy listed seven possible sequelae which can be related to the unerupted canines : (1) labial impaction, usually vertically impacted; (2) lingual impaction, usually horizontally impacted; (3)

root resorption of impinged teeth ; (4) referred pain ; (5) infection from partial impaction resulting in pain and trismus ; (6) dentigerous cyst which can possibly become an ameloblastoma (7) self-resorption-which radiographically resembles caries and begins usually in the crown portion of the impacted tooth. On the other hand, the impacted canine may cause no untoward effects during the lifetime of the individual²

Diagnosis and localization of impacted canines

Diagnosis is usually made on the basis of both clinical and roentgenographic examinations.

1. Clinical - Any one or a combination of the following signs may be present:

(a) delayed eruption of one or more of the permanent

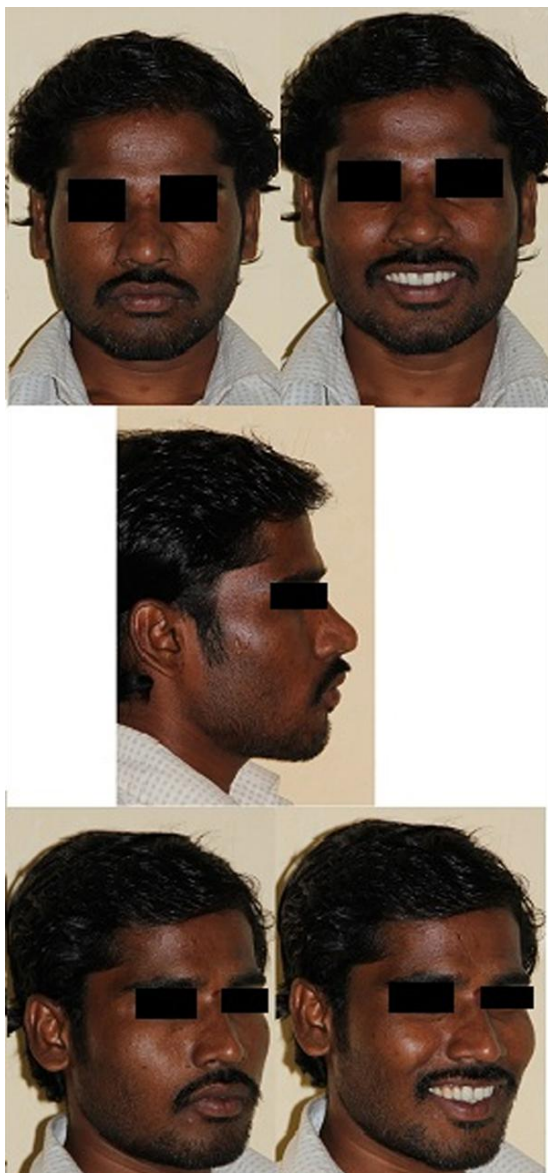

Fig. 1: Extraoral photographs

canines after 14 years of age; (b) prolonged retention of a primary canine; (c) elevation of the soft tissue of the palatal or labial mucosa (depending on canine location) ; (d) distal migration of the lateral incisors with or without a midline shift.

2. Roentgenographic. Impacted canines may be diagnosed during routine dental examination, which usually includes either a full-mouth survey or a Panorex film.

Radiographic localization - Different roentgenographic techniques have been advocated to localize the position of unerupted canines. The most common are as follows.

1. PERIAPICAL FILMS³ - (a) Tube-shift technique or Clark's rule : Two periapical films are taken of the same area, with the horizontal angulation of the cone changed when the second film is taken. If the object in question moves in the same direction as the tube head it is lingually positioned. If it moves in the opposite direction it is situated closer to the source of radiation and therefore is buccally located.

(b) **Buccal-object rule** - If the vertical angulation of the cone is changed by approximately 20 degrees in two successive periapical films, the buccal object will move in the direction opposite to the source of radiation. On the other hand, the lingual object will move in the same direction as the source of radiation. The basic principle of this technique deals with the

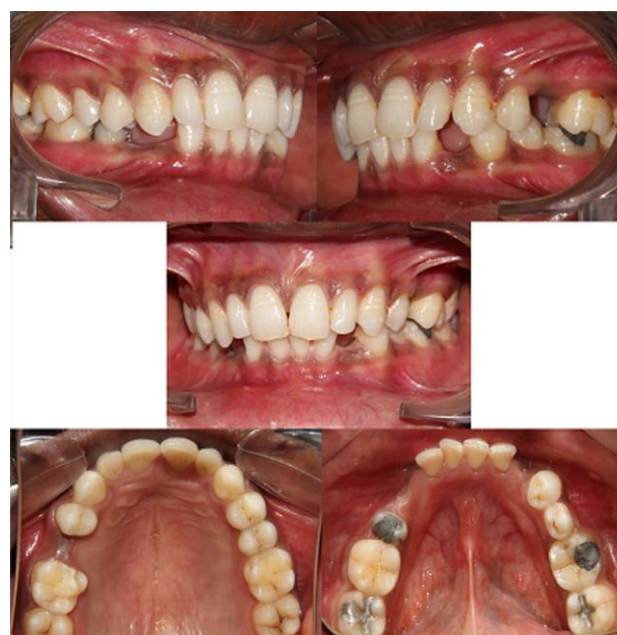

Fig. 2: Intraoral photographs

foreshortening and elongation of the images of the films. In summary, a single periapical film can give information as to the relative mesiodistal and superior-inferior positions of the object and the use of two periapical films can add the buccolingual dimension.

2. OCCLUSAL FILMS - These also help to determine the buccolingual position of the impacted canine in conjunction with periapical films, provided that the image of the impacted canine is not superimposed on the other teeth.

3. EXTRAORAL FILMS –

(a) **Frontal and lateral cephalograms** can sometimes be of aid in determining the position of impacted canines, especially in relation to other facial structures-particularly the maxillary sinus and the floor of the nose.

(b) **Panorex films** are also used to locate impacted

teeth in all three planes of space (much the same as using two periapical films in the tube-shift method or Clark's rule)-with the exception that, since the source of radiation comes from behind the patient, the movements are reversed for position; e.g., a palatal impaction will move left to right roentgenographically when the tube head moves from the patient's right to his left. A labially impacted or positioned tooth will move roentgenographically in the same direction as the tube head because it is farther from the source of radiation than the reference point⁴.

The aim of the present case report is to determine the accurate diagnostic value of 2 dimensional radiographic techniques versus 3 dimensional radiographic technique of cone beam computed tomography.

Case Report

The patient was 21 year old when he presented for

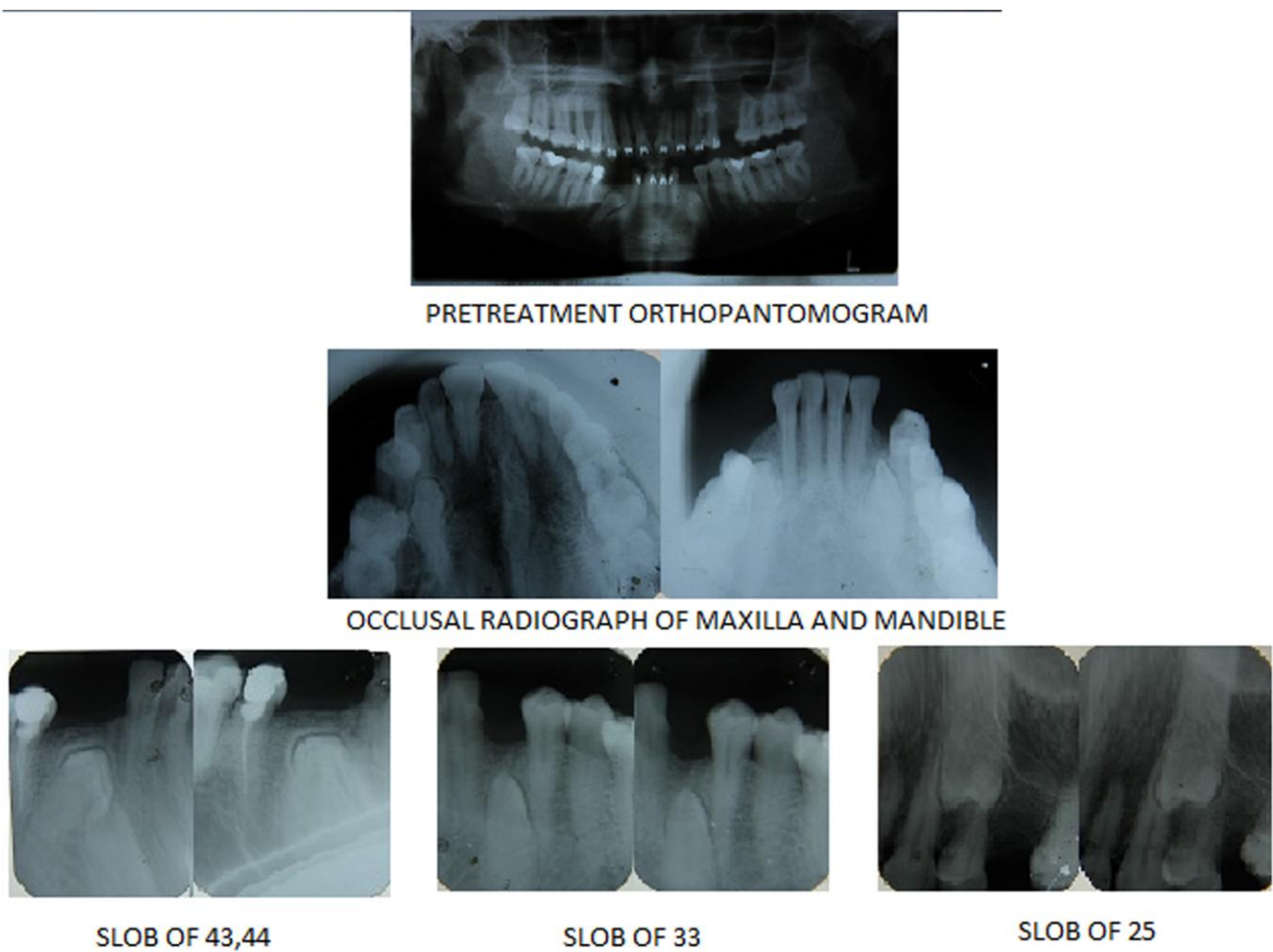


Fig. 3: Pretreatment radiographs

orthodontic consultation. Review of the medical history revealed no allergic or medical problems. He was in good health and had no contraindications to dental treatment. No signs or symptoms of temporomandibular dysfunction were noted. There was no history of trauma to the mouth, teeth, lips or jaws (Figure 1). Complete intraoral examination of the patient revealed missing mandibular permanent canines, mandibular right first premolar (44), maxillary left second premolar (25) following which a panoramic radiograph was advised to look for the permanent canines (Figure 2).

The patient was 21 year old when he presented for orthodontic consultation. Review of the medical history revealed no allergic or medical problems. He was in good health and had no contraindications to dental treatment. No signs or symptoms of temporomandibular dysfunction were noted. There was no history of trauma to the mouth, teeth, lips or jaws (Figure 1). Complete intraoral examination of

mandibular arch and arch was in there alignment except for a crowding present in mandibular anterior region (Figure 2). The orthopantomograph revealed the presence of impacted 43, 44, 33, and 25. Teeth suggested to be missing by the patient were impacted in their respective arches without any transmigration of these teeth (Figure 3). Mandibular Occlusal radiographs suggested a lingually impacted 43, 44, and 33 and maxillary occlusal suggested palatal impaction of 25 (Figure 3). Intraoral periapical view via clarks rule suggested lingual impaction with respect to 43, 44 and an upright 33 in the center of the mandibular body (Figure 3). Intraoral periapical view for 25 suggested an palatally impacted 25 (Figure 3).

To determine the accurate position of the impacted teeth patient was advised to take a cone beam computed tomographic radiograph of 43, 44, 33 (Figure 4) and 25 regions (Figure 4). Cone beam computed tomograph was taken at secundarabad diagnostic imaging center, secunderabad. CS 3D

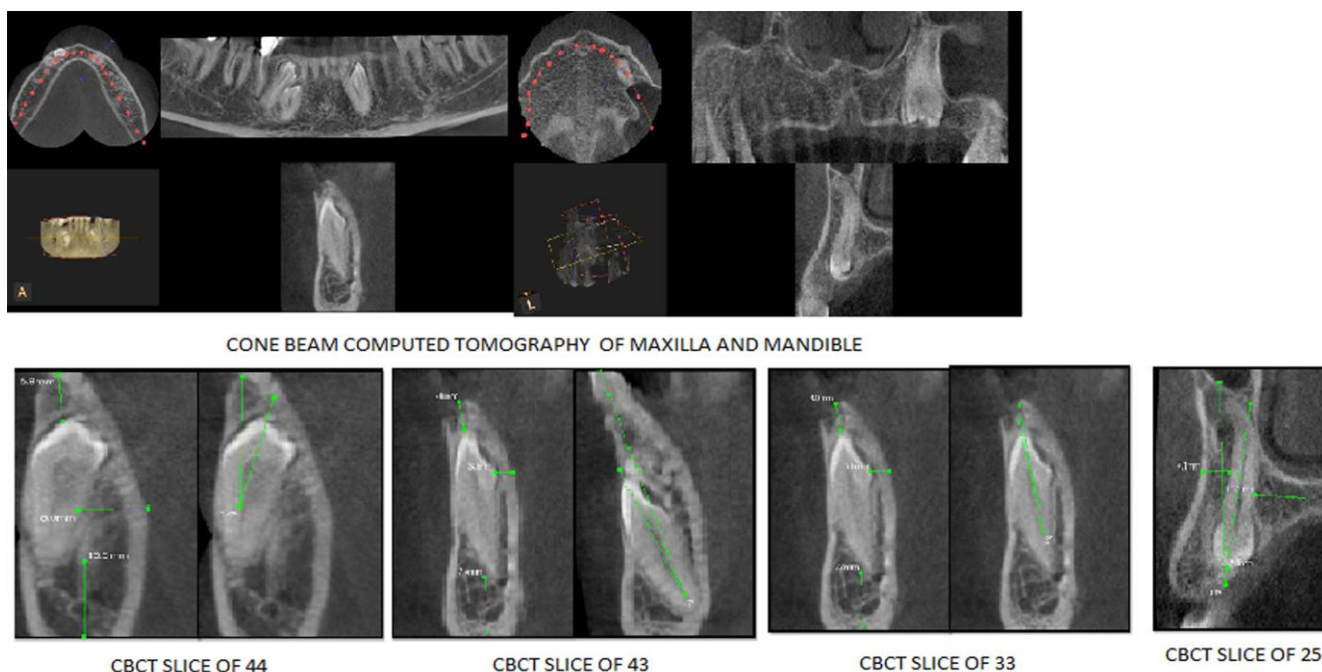


Fig. 4: Cone beam computed tomography of maxilla and mandible

the patient revealed missing mandibular permanent canines, mandibular right first premolar (44), maxillary left second premolar (25) following which a panoramic radiograph was advised to look for the permanent canines (Figure 2).

There was no crowding of the maxillary and

imaging software was used.

Cone beam computed tomography slice of 44 depicted the tooth to be labially impacted with tooth to be 8 mm away from outer border of lingual cortical plate. Tooth is localized 6.8mm away from crest of mandibular alveolar ridge and 10.5 mm away from

outer margin of inferior border of mandible. Tooth is angulated 14 degrees to the crest of mandibular alveolar ridge (Figure 4).

Cone beam computed tomography slice of 43 depicted the tooth to be labially impacted with tooth to be 3.1 mm away from outer border of lingual cortical plate. Tooth is localised 4 mm away from crest of mandibular alveolar ridge and 7 mm away from outer margin of inferior border of mandible. Tooth is angulated 7 degrees to the crest of mandibular alveolar ridge (Figure 4).

Cone beam computed tomography slice of 33 depicted the tooth to be labially impacted with tooth to be 3.1 mm away from outer border of lingual cortical plate. Tooth is localised 4 mm away from crest of mandibular alveolar ridge and 7 mm away from outer margin of inferior border of mandible. Tooth is angulated 2 degrees to the crest of mandibular alveolar ridge (Figure 4).

Cone beam computed tomography slice of 25 depicted the tooth to be palatally impacted with tooth to be 2.8 mm away from outer border of palatal vault. Tooth is localised 4.1 mm away from outer border of buccal cortical plate. Tooth is angulated 11 degrees to the crest of maxillary alveolar ridge (Figure 4).

Results

There were differences in the identified location of the impacted teeth depending on the radiographic modality. 2 dimensional radiographic assesement of the impacted teeth via occlusal radiograph suggested palatal position of impacted 25 and lingually impacted 33, 43 and 44. Intraoral radiographic assesement of impacted teeth by clark's rule suggested palatally impacted 25 that was in accordance to occlusal radiographic assesement. Assesement of impacted 33 suggested an upright position of 33 in the mandibular body that varied from the occlusal assesement. Assesement of 43, 44 suggested lingually impacted 43, 44 that was in accordance with occlusal radiographic assesement.

Cone beam computed tomographic assesement provided exact localization for the impacted teeth. Cone beam computed tomographic slice of impacted 25 suggested palatally impacted 25 that was in accordance to 2 dimensional radiographic

assesement. Cone beam computed tomographic slice of impacted 33 suggested labially positioned impacted 33 that differs from 2 dimensional radiographic assesement that suggested lingual impaction of 33 by occlusal radiographic assesement. Cone beam computed tomographic slice of impacted 43 suggested labially impacted 43 that differs from 2 dimensional radiographic assesement that suggested lingual impaction of 43 by occlusal radiographic assesement and intraoral periapical view by clarks rule. Cone beam computed tomographic slice of impacted 44 suggested labially impacted 44 that differs from 2 dimensional radiographic assesement that suggested lingual impaction of 44 by occlusal radiographic assesement and intraoral periapical view by clarks rule.

Discussion

While comparing the volumetric 3D method of CBCT and traditional 2D radiographs, we found differences between position of the impacted teeth⁵. Individual tooth variations affect the labiopalatal localization of the impacted canine.

Ericson and Kuroi⁶⁻⁸ demonstrated that 8% of impacted maxillary canines could not be accurately localized in the labiopalatal dimension with periapical radiographs.

Bjerklin and Ericson⁹ showed that evaluating the same patients 10 to 12 months later with additional information from a computed tomography scan allowed them to detect root resorption in approximately 50% more incisors with retained and ectopically positioned maxillary permanent canines, and the treatment plan was changed for almost 44% of the patients.

Kau et al¹⁰ have stated that in complex orthodontic cases such as in canine impactions and cleft lip and palate, 3-D imaging is mandatory, and CBCT is the imaging of choice

Traditionally, the position of the impacted canine has been assessed in two dimensions: mesial/distal and buccal/palatal.

In the present study we found diagnostic differences between 2 dimensional radiographic assesement and 3 dimensional radiographic assesement. The radiographic differences might be due to the over

demanding manual accuracy of the 2 dimensional radiography. In 2 dimensional radiography 3 dimensional structure is projected as 2 dimensional structure with an absent depth parameter or volume. These limitations of 2 dimensional radiography were reduced by cone beam computed tomographic technique as cbct involves the volume of the structure.

CBCT, which provides a lower dose, lower cost alternative to conventional CT, is being used with increasing frequency in the practice of orthodontics and oral and maxillofacial radiology. Ludlow et al. found the calculated doses for a 12 FOV scan in mSv were NewTom3G (Elmsford, New York, USA) (45, 59), i-CAT (Hartfield, Pennsylvania, USA) (135, 193) and CB Mercuray (477, 558). These are 4 to 42 times greater than comparable panoramic examination doses (6.3 mSv, 13.3 mSv).

Reductions in dose were seen with reductions in field size and mA and kV technique factors. Based on the diagnostic requirements the FOV, mA and kV can be altered to reduce the radiation dosage.

Conclusions

These results suggest that the use of 2D and 3D images of impacted teeth can produce different diagnoses and treatment plans for the same patient. Individual tooth variations affect the determination of the labiopalatal position of an multiple impacted teeth . Three-dimensional volumetric imaging might provide information for improved diagnosis and treatment plans, and ultimately result in more successful treatment outcomes and better care for patients. 3 dimensional imaging gives an overall volumetric analysis of the structure and assists in clinical realms to asses position and morphology of the impacted teeth and its relation to surrounding structure thus assisting in the surgical procedures , orthodontic tooth alignment and there by assisting to improve its prognosis.

Acknowledgement

We are thankful to Dr. Raghu .D, Dr. Saravanan .P, Dr. Triveni, Dr. Amit .B, Dr. Najmuddin, Dr. Venkatesh for there support and guidance throu-

ghout the research work.

References

1. Rebellato J, Schabel B. Treatment of patient with an impacted transmigrant mandibular canine & a palatally impacted maxillary canine. *Angle Orthod* 2002;73(3):328-36.
2. Shafer WG, Hine MK, Levy BM: A textbook of oral pathology. ed. 2.Philadelphia, 1963, W. B. Saunders Company, pp. 2-75.
3. Landland OE, Sippy F.: Manual of dental radiology, Ames, 1969, Tinivesrity of Towa Publications.
4. Turk MH, Katzenell J: Panoramic localization, *Oral Surg.*1970; 29(2): 212-5.
5. E Haney, SA Gansky, Lee JS, Johnson E, Maki K, AJ Miller, Huang JC. Comparative analysis of traditional radiographs and cone-beam computed tomography volumetric images in the diagnosis and treatment planning of maxillary impacted canines. *Am J Orthod Dentofacial Orthop* 2010; 137(5):590-7.
6. Ericson S, Kurol J. Radiographic assessment of maxillary canine eruption in children with clinical signs of eruption disturbance. *Eur J Orthod* 1986;8(3):133-40.
7. Ericson S, Kurol J. Longitudinal study and analysis of clinical supervision of maxillary canine eruption. *Community Dent Oral Epidemiol* 1986;14(3):172-6.
8. Ericson S, Kurol J. Incisor resorption caused by maxillary cuspids. A radiographic study. *Angle Orthod* 1987;57(4):332-46.
9. Bjerklin K, Ericson S. How a computerized tomography examination changed the treatment plans of 80 children with retained and ectopically positioned maxillary canines. *Angle Orthod* 2006; 76(1): 43-51.
10. Snehlata O. CBCT Evaluation of Impacted Canines and Root Resorption. *P C S O Bulletin Summer 2011.* www. pcsortho.org/PCSO Bulletin (Last accessed on 06/09/2012)