

# UC Davis

## UC Davis Previously Published Works

### Title

Sonographic reference values for median nerve cross-sectional area: A meta-analysis of data from healthy individuals.

### Permalink

<https://escholarship.org/uc/item/0jr036gj>

### Journal

Journal of Diagnostic Medical Sonography, 39(5)

### ISSN

8756-4793

### Authors

Roll, Shawn

Takata, Sandy

Yao, Buwen

et al.

### Publication Date

2023-09-01

### DOI

10.1177/87564793231176009

Peer reviewed



Published in final edited form as:

*J Diagn Med Sonogr.* 2023 September ; 39(5): 492–506. doi:10.1177/87564793231176009.

## Sonographic reference values for median nerve cross-sectional area: A meta-analysis of data from healthy individuals

Shawn C. Roll, PhD, OTR/L, RMSKS, FAOTA, FAIUM<sup>\*,1</sup>, Sandy C. Takata, PhD, OTD, OTR/L<sup>\*,1</sup>, Buwen Yao, PhD, MBBS<sup>1</sup>, Lynn Kysh, MLIS, MPP<sup>2</sup>, Wendy J. Mack, PhD<sup>3</sup>

<sup>1</sup>Chan Division of Occupational Science and Occupational Therapy, University of Southern California, Los Angeles, CA, USA

<sup>2</sup>Institute for Nursing and Interprofessional Research, Children's Hospital Los Angeles, Los Angeles, CA, USA

<sup>3</sup>Division of Population and Public Health, University of Southern California, Los Angeles, CA, USA

### Abstract

**Objective:** Establish median nerve CSA reference values and identify patient-level factors impacting diagnostic thresholds.

**Methods:** Studies were identified through a robust search of multiple databases, and quality assessment was conducted using a modified version of the National Institute of Health Study Quality Assessment Tool for Observational Cohort and Cross-Sectional Studies. A meta-analysis was performed to identify normative values stratified by anatomic location. A meta-regression was conducted to examine heterogeneity effects of age, sex, and laterality.

**Results:** The meta-analysis included 73 studies; 41 (56.2%) were high quality. The median nerve CSA [95% CI] was 6.46mm<sup>2</sup> [6.09–6.84], 8.68mm<sup>2</sup> [8.22–9.13], and 8.60mm<sup>2</sup> [8.23–8.97] at the proximal forearm, the carpal tunnel inlet, and the proximal carpal tunnel, respectively. Age was positively associated with CSA at the level of proximal carpal tunnel ( $\beta=0.03\text{mm}^2$ ,  $p=0.047$ ). Men (9.42mm<sup>2</sup>, [8.06–10.78]) had statistically larger proximal tunnel CSA ( $p = 0.03$ ) as compared to women (7.71mm<sup>2</sup>, [7.01–8.42]). No difference was noted in laterality.

**Conclusion:** A reference value for median nerve CSA in the carpal tunnel is 8.60mm<sup>2</sup>. Adjustments may be required in pediatrics or older adults. The diagnostic threshold of 10.0mm<sup>2</sup> for male patients should be cautiously applied as the upper limit of normative averages surpasses this threshold.

### Keywords

ultrasonography; median nerve; reference values; meta-analysis

---

**Corresponding Author:** Shawn C. Roll; sroll@usc.edu.

\*Co-primary authors

## Introduction

Sonographic imaging is becoming widely used for the examination of peripheral nerves, particularly in the diagnosis of carpal tunnel syndrome (CTS), where a growing body of literature is examining the diagnostic accuracy of sonography for CTS.<sup>1–3</sup> Research and clinical approaches primarily compare median nerve cross sectional area (CSA) to a diagnostic threshold (e.g., 10mm<sup>2</sup>) or use a within-arm comparison of the CSA in the carpal tunnel to the CSA in the forearm.<sup>4–6</sup> Sonography has been shown to demonstrate a better false-positive rate at 23% compared to the “gold standard” of nerve conduction at 43%.<sup>1</sup> Recent expert consensus suggests that combining sonography with other clinical measures<sup>7</sup> can increase diagnostic accuracy<sup>8</sup> and may be able to differentiate severity of CTS.<sup>9</sup>

Most researchers examining diagnostic accuracy or developing diagnostic thresholds for sonographic measurements enroll a unique sample of healthy individuals to serve as reference values in their individual studies. These comparator samples are often substantially small and purposefully recruited to match the patient population of the primary study. Although a few studies have been conducted to report normative values within specific populations<sup>10–12</sup> and across different demographic factors<sup>13,14</sup> these studies do not provide the substantially large, heterogeneous samples necessary to serve as stand-alone reference values for all clinical patients or research protocols.

With the proliferation of sonographic measurement of the median nerve in diagnostic studies and clinical trials, along with the increasing clinical use of sonography for screening and prevention of CTS, there is a need to establish a robust set of normative reference values for these measures across various populations, ages, and sexes. Thus, the purpose of this meta-analysis was to locate all published data on median nerve CSA measurements in healthy participants, statistically combine the data to establish reference values, and identify patient-level factors that may impact how diagnostic thresholds are considered within clinical practice and research.

## Materials and Methods

### Search Strategy

Our review was designed to meet the criteria of the Preferred Reporting of Items for Systematic Reviews and Meta-Analyses.<sup>15</sup> The study protocol was registered with the International Prospective Register of Systematic Reviews (CRD42016037286), and the detailed search and selection methodology has been previously published.<sup>16</sup> An initial bibliographic search was completed by a clinical and research librarian on March 20, 2017, and an updated search was conducted on May 31, 2019. Searches were conducted in Ovid MEDLINE, Embase, Cochrane Library, CINAHL, and SPORTDiscus using a combination of subject headings (when available) and keywords for concepts of peripheral nerves, reference values, or carpal tunnel and ultrasonography to capture articles published since the year 2000. The detailed search strategies for each database are included in Supplemental Table 1. Additional searches were conducted in [ClinicalTrials.gov](https://www.clinicaltrials.gov), the tables of contents of journals within related medical (e.g., imaging, neurology) and injury prevention fields (e.g.,

human factors and industrial engineering), and the reference lists of relevant review articles identified in the search process.

### Study Selection

A review team with varied training in sonographic imaging, rehabilitation, and medicine followed a standardized protocol to complete the study selection process.<sup>16</sup> Following removal of duplicates, all abstracts were imported into Covidence (Veritas Health Innovation Ltd; Melbourne, Australia) and independently screened by two reviewers. Full texts were obtained for any article that at least one reviewer indicated used sonography to examine the peripheral nerves of the upper extremity in healthy individuals. All full texts were independently reviewed for eligibility by two reviewers to identify studies that measured median nerve CSA in healthy participants using sonography. A registered musculoskeletal sonographer with more than 10 years of experience examined articles with discrepancies between the primary reviewers, and final inclusion was determined by consensus among the reviewers. Studies that used a transducer <10MHz, a measurement technique other than direct trace around the internal hyperechoic border of the nerve, or a primary measurement of CSA in cm<sup>2</sup> rather than mm<sup>2</sup> were excluded. When units of measurement were not reported in the methods, studies were excluded if cm<sup>2</sup> appeared in figures or whole numbers were used to report CSA. Studies that lacked a clear anatomical description or combined measures from different locations across participants (e.g., largest CSA measured across the carpal tunnel region) were also excluded.

### Data Extraction and Quality Assessment

For each study, the number, average age, and distributions of sex and handedness of participants were extracted. Central tendency and variance for each sonographic CSA measurement of the median nerve were entered into the dataset across nine anatomic locations from the axilla to the distal carpal tunnel (Table 1). To obtain missing data, the corresponding authors were contacted when articles did not report both centrality and variance of CSA for healthy participants. Because the purpose of this review was limited to measures of the median nerve in healthy participants, additional information related to overall study (e.g., design, diagnosis, intervention) were not extracted or reported.

Quality assessment was conducted using a modified version of the National Institute of Health Study Quality Assessment Tool for Observational Cohort and Cross-Sectional Studies.<sup>17</sup> Studies were scored as having fully met (1 point), partially met (0.5 points), or not met (0 points) eight quality criteria related to the imaging of healthy participants in the study.<sup>16</sup> Studies that did not report enough detail to determine if a criterion was met received no points, and studies that included only healthy participants received full points for criteria that required differentiation between groups (e.g., blinding of raters to participant status). Two reviewers individually scored each article, and a third reviewer resolved any differences. Average quality across the included studies was calculated, and individual articles were categorized into three quality levels: (1) *High Quality*: > 6.0 points; (2) *Fair Quality*: 4.5 to 6.0 points; and (3) *Poor Quality*: < 4.5 points.

## Statistical Analysis

A meta-analysis was performed to identify normative values for sonographic measurement of median nerve CSA stratified by anatomic location. Weighted averages were calculated for each anatomic location using random-effects models specifying the mean value of each study-specific median nerve CSA as an effect size. Standard errors for each study mean were obtained (in order of preference): 1) using directly reported standard errors; 2) calculated from SD and sample size; or 3) using the sample range to compute an SD. Overall measures, study-specific effect sizes, and 95% confidence intervals were displayed in forest plots by anatomic location, and the  $I^2$  test statistic was used to evaluate heterogeneity of CSA means across studies. A meta-regression was conducted to examine heterogeneity effects of age (i.e., mean study age) and sex (i.e., % male in study) at the two most clinically used anatomical locations (i.e., proximal forearm, proximal carpal tunnel). Finally, means were reported by subgroups of sex and hand dominance using studies that reported CSA values in these two locations by these subgroups or that had a homogeneous sample (e.g., all females, all dominant hands); differences in CSA means by sex and hand dominance were tested. Meta-analyses were conducted using Stata V17 (College Station, TX).

## Results

### Study Selection

The flow of records through the study selection process is presented in Figure 1. Screening was conducted for 18,592 unique records. A total of 418 full text articles were reviewed for eligibility due to abstracts indicating that sonographic measurement of the median nerve was conducted in the study. Articles were excluded that did not evaluate median nerve CSA (n=75), did not include healthy participants (n=34), or did not use an appropriate measurement technique (n=166). Additionally, 69 articles were excluded due to missing data or re-reporting of healthy participant data that had been used in previous studies already included in the review. One study was identified as an outlier and excluded; this study reported an average CSA of approximately twice the size reported by the 20 other studies within the same anatomical region.<sup>18</sup> Data from the remaining 73 articles were included in the meta-analysis.

### Study Characteristics and Quality

The proximal carpal tunnel (47/73, 64.4%), carpal tunnel inlet (35/73, 47.9%), and proximal forearm (20/73, 27.4%) were the most common anatomical locations of CSA measurement among the included studies. The meta-analytic average age of healthy participants across all articles in the sample was 43.6 years. The average quality rating across the included studies was 6.1 out of 8.0, with 41 of 73 (56.2%) studies identified as high quality, 28 of 73 (38.4%) fair quality, and 5 of 73 (6.8%) poor quality (Table 2). Quality of the image acquisition process was the criterion most often partially or not met based on the description in the articles (i.e., only 37.8% fully met this criterion). Only half of the studies indicated the qualifications of the individuals obtaining or measuring the sonographic data.

### Meta-Analysis of Healthy Median Nerve Cross-Sectional Area

The weighted averages and confidence intervals for median nerve CSA across the nine anatomic regions are presented in Table 3. The median nerve CSA was approximately 8–9mm<sup>2</sup> in the upper arm, elbow, and wrist, with a smaller CSA noted in forearm. In the most frequently measured regions, CSA was 6.46mm<sup>2</sup> (95% CI: 6.09–6.84) in the proximal forearm, 8.60mm<sup>2</sup> (95% CI: 8.23–8.97) at the level of the pisiform in the proximal carpal tunnel, and 8.68mm<sup>2</sup> (95% CI: 8.22–9.13) at inlet to the carpal tunnel (Figures 2 and 3). Most confidence intervals for the weighted means were approximately  $\pm 0.5\text{mm}^2$ ; however, these intervals were larger for measurements in the upper arm, the distal carpal tunnel, and the carpal tunnel outlet indicating either wider variability in nerve size or increased measurement error in these locations. The  $I^2$  values indicated heterogeneity across the included studies suggesting potential moderating effects within the individual study designs or samples and confirming the need for further meta-regression and moderator analyses. Forest plots for the additional anatomical regions are included in Supplemental Figures 1–6.

### Meta-Regression and Moderator Analysis of Study Factors Related to Cross-Sectional Area

Five studies were excluded from the meta-regression due to missing data for average age or sex distribution (i.e., % male). Among the remaining studies, there was no significant effect of sex distribution or age in proximal forearm CSA (sex,  $p = 0.809$ ; age,  $p = 0.418$ ) and no effect of sex distribution on proximal carpal tunnel CSA (sex,  $p = 0.112$ ). There was a statically significant effect of age on proximal carpal tunnel CSA ( $p = 0.047$ ), such that, assuming a linear trend, each year of increase or decrease from the average age of the sample (i.e., 43.6 years) would result in a subsequent increase or decrease in CSA by 0.03mm<sup>2</sup> (95% CI: 0.00 – 0.07). Thus, assuming a linear trend, the estimated range of normal CSA at the pisiform for adults aged 18 years to 65 years would be 7.83mm<sup>2</sup> to 9.24mm<sup>2</sup>.

Only three studies reported stratified data by either sex or hand dominance at the proximal forearm so further evaluation of these factors at this location was not completed. Ten studies provided proximal carpal tunnel CSA values stratified by sex (Figure 4). The weighted average CSA of these 10 studies was equal to the overall weighted average of the 47 studies measuring CSA at this location (i.e., approximately 8.60mm<sup>2</sup>); however, men (9.42mm<sup>2</sup>, [8.06–10.78]) had statistically larger weighted average CSA ( $p = 0.03$ ) as compared to women (7.71mm<sup>2</sup>, [7.01–8.42]). Eighteen studies reported CSA values at the proximal carpal tunnel stratified by hand dominance and sixteen studies reported values based on laterality of right versus left wrist (Figure 5). The weighted averages were nearly identical with no significant differences between nerves measured in a dominant wrist (8.51mm<sup>2</sup>, [7.72–9.29]) and a non-dominant wrist (8.57mm<sup>2</sup>, [7.62–9.52]) and in nerves measured in the right (7.71mm<sup>2</sup>, [7.03–8.40]) versus left wrist (7.93mm<sup>2</sup>, [7.46–8.76]). Similarly, there was no significant difference ( $p=0.81$ ) among eleven studies that reported laterality for CSA of the median nerve in the proximal formal between the right (6.92mm<sup>2</sup>, [6.30–7.54]) and left (6.87mm<sup>2</sup>, [6.49–7.26]).

## Discussion

Without accounting for age, sex, or laterality, healthy median nerve CSA values measured at the inlet to or in the proximal carpal tunnel all fall below the commonly used diagnostic threshold of  $10\text{mm}^2$  and are well below meta-analytic values reported for patients with various severities of CTS.<sup>5,19</sup> Reference values for median nerve CSA in healthy individuals change slightly as the nerve travels from proximal to distal, being of similar size in the wrist and upper arm regions and slightly smaller in the forearm. Specifically, healthy median nerve CSA should be about  $8.60\text{mm}^2$  in the proximal carpal tunnel, approximately  $2.0\text{mm}^2$  larger than in the forearm with a wrist-to-forearm ratio of approximately 1.3. Although using either a difference of  $2.0\text{mm}^2$  or a wrist-to-forearm ratio of greater than 1.4 as suggested by commonly cited literature,<sup>20,21</sup> these measures may lead to false positives and might be best considered as general ‘rules of thumb’ rather than singular diagnostic threshold. That is, when considering confidence intervals of healthy measures of the nerve between the proximal forearm and carpal tunnel, the potential difference in a healthy individual could be as large as  $2.88\text{mm}^2$  (i.e.,  $8.97\text{mm}^2 - 6.09\text{mm}^2$ ) with a corresponding wrist-to-forearm ratio of 1.5. Definitive diagnosis of CTS may require adoption of these more conservative thresholds or a combination of multiple clinical measures.<sup>9,22</sup>

When accounting for linear changes by age, the estimated range of CSA within the carpal tunnel in healthy adults (18–65) is  $7.83\text{mm}^2$  to  $9.24\text{mm}^2$ , falling well below a diagnostic threshold of  $10\text{mm}^2$ . Given a small effect of age on CSA measures, adjusting normative values is only necessary when evaluating pediatric or older adults; however, sex and laterality may require attention in clinical practice and research. Although there were no differences in median nerve CSA when considering percent male versus female across 47 studies, among 10 studies that exclusively stratified data by sex, men had significantly larger CSA than women. Given that these studies had the same weighted average as the full sample when compiling men and women together, research with mixed-sex samples could confidently use  $8.60\text{mm}^2$  as a valid reference for median nerve CSA at the level of the pisiform. Alternatively, for studies with higher representation of men or women and for individual patients, researchers or clinicians should consider using the sex-normed reference values of  $7.71\text{mm}^2$  for women and  $9.42\text{mm}^2$  for men. Importantly, caution should be used when applying the diagnostic threshold of  $10.0\text{mm}^2$  in men as the upper limit of the 95% confidence interval for male CSA surpasses this threshold in the aggregate data within this meta-analysis.

In healthy individuals, median nerve CSA in the proximal carpal tunnel is likely highly similar between dominant and non-dominant sides. Thus, studies that consider bilateral CSA as independent datapoints could have increased risk of erroneous statistical findings. Alternatively, accounting for within-subject differences between wrists as a diagnostic assessment may have significant validity. Current primary sonographic diagnostic criteria for CTS rely on an absolute threshold (i.e.,  $10.0\text{mm}^2$ ) or a within-arm comparison (e.g., wrist-to-forearm ratio). Adding a bilateral comparison criterion would mirror electrodiagnostic approaches that consider bilateral differences in conduction velocities along with an absolute threshold and a within-arm comparison to the ulnar nerve.



Methodological concerns require attention to improve rigor in the clinical or research use of median nerve CSA measurements. One previously identified issue that remains pervasive is the wide variability how anatomical locations of CSA measurements are identified and described.<sup>6</sup> Two issues arose in attempting to categorize study findings using the heterogeneous descriptions across the studies. Firstly, the same term was often used to represent different anatomical regions, such as the word “inlet” used to indicate a location immediately proximal to the carpal ligament in some studies and a location under the most proximal portion of the carpal ligament in other studies. Secondly, there was variability in how much detail was used to describe where a measure was taken and disparate use of surface landmarks versus sonographically identified anatomical landmarks to identify the measurement location. For example, the “carpal tunnel inlet” was sometimes mentioned as generally being measured from an image taken at the wrist crease, while measurements in the proximal forearm were sometimes completed at a specific distance from the elbow or wrist and other times completed at the location where the nerve emerged between the heads of the pronator teres muscle. The only consistent description noted across the studies was using the pisiform as a landmark for measuring the median nerve in the proximal carpal tunnel. Developing additional standardized nomenclature that avoids gross, external landmarks and uses clear sonographic anatomical landmarks for the acquisition and analysis of median nerve CSA will improve clarity across research studies and consistency in clinical diagnostics.

In addition to adopting standardized nomenclature, there is a significant need for studies to clearly describe how individual patients versus individual wrists are included or excluded from final data samples. It was often challenging to determine if one or both wrists were included among individual participants and even more challenging to know when or why data from some wrists were either not collected or were excluded when the number of wrists was not equal between sides or did not match the total number of participants in the sample. Importantly, if both wrists of an individual participant are included, data from this meta-analysis suggests a need to account for the dependent nature of nerves when conducting within-subject analyses. Finally, although most studies now measure CSA using a direct trace within the hyperechoic epineurium, multiple studies were eliminated due to measurement using less sensitivity or accurate techniques (e.g., ellipse).

## Limitations

The reliance on reported summary data rather than using primary data, combined with inconsistencies in reporting of methodological details across studies introduces some error in the meta-analytic means. Firstly, individual studies obtained and reported data either by individual or by wrist, and it was often unclear when data were from left or right wrists, from dominant or non-dominant sides, or averaged across a mixture of both upper extremities. Furthermore, some studies reported inconsistencies between the number of included wrists or individuals and the final sample size used in the analysis. Secondly, despite efforts to obtain missing data, many studies were excluded, and inconsistent reporting of race and ethnicity resulted in the inability to examine CSA based on these factors. Finally, definitions of ‘healthy’ varied greatly across studies or were generally undefined, which potentially resulted in inclusion of some data from individuals with



pathologies. Despite these limitations, consistency of CSA means within similar ranges across the included studies increases confidence in reporting the meta-analytic averages as normative reference values within the general population.

## Conclusions

Using data from 73 studies, normative reference values for the CSA of the median nerve in healthy individuals were identified. The reference value for the most common measurement site within the carpal tunnel at the level of the pisiform is 8.60mm<sup>2</sup>. Adjustment for age in a clinical setting or age-matching in research samples may only be necessary when examining pediatric or older adult patients. Men generally have larger CSA in the proximal carpal tunnel than women, and caution is required when applying a diagnostic threshold of 10.0mm<sup>2</sup> for male patients as the upper limit of normative averages surpasses this threshold. Finally, evidence of no difference between dominant and non-dominant wrists is important. Researchers should avoid considering bilateral CSA measures from one individual as independent data points, while within-patient differences between wrists may be useful as a clinical diagnostic assessment. In addition to normative values, this meta-analysis illuminated numerous issues in the quality of study reporting, variations in the use of anatomical landmarks, and a lack of standard nomenclature.

## Supplementary Material

Refer to Web version on PubMed Central for supplementary material.

## Acknowledgements:

We would like to acknowledge the assistance in reviewing abstracts and studies provided by Joyce Ho and Nina Wakayama.

## Funding:

This study was funded by grant number R01 OH010665 from the Centers for Disease Control and Prevention (CDC), National Institute for Occupational Safety and Health, and by grant number F31 AR074894 from the National Institutes of Health (NIH), National Institute of Arthritis and Musculoskeletal and Skin Diseases (NIAMS). The content is solely the responsibility of the authors and does not necessarily represent the official views of the CDC or the NIH.

## List of Abbreviations:

<b>CSA</b>	cross-sectional area
<b>CTS</b>	carpal tunnel syndrome
<b>MHz</b>	megahertz

## References

1. Fowler JR, Byrne K, Pan T, Goitz RJ (2019) False-positive rates for nerve conduction studies and ultrasound in patients without clinical signs and symptoms of carpal tunnel syndrome. *The Journal of Hand Surgery* 44:181–185 [PubMed: 30635201]

2. Wang WL, Buterbaugh K, Kadow TR, Goitz RJ, Fowler JR (2018) A prospective comparison of diagnostic tools for the diagnosis of carpal tunnel syndrome. *The Journal of hand surgery* 43:833–836. e832 [PubMed: 29935774]
3. Cartwright MS, Hobson-Webb LD, Boon AJ et al. (2012) Evidence-based guideline: neuromuscular ultrasound for the diagnosis of carpal tunnel syndrome. *Muscle Nerve* 46:287–293 [PubMed: 22806381]
4. Ibrahim I, Khan W, Goddard N, Smitham P (2012) Suppl 1: carpal tunnel syndrome: a review of the recent literature. *The open orthopaedics journal* 6:69 [PubMed: 22470412]
5. Fowler JR, Gaughan JP, Ilyas AM (2011) The sensitivity and specificity of ultrasound for the diagnosis of carpal tunnel syndrome: a meta-analysis. *Clin Orthop Relat Res* 469:1089–1094 [PubMed: 20963527]
6. Roll SC, Case-Smith J, Evans KD (2011) Diagnostic accuracy of ultrasonography vs. electromyography in carpal tunnel syndrome: a systematic review of literature. *Ultrasound Med Biol* 37:1539–1553 [PubMed: 21821353]
7. Pelosi L, Arányi Z, Beekman R et al. (2022) Expert consensus on the combined investigation of carpal tunnel syndrome with electrodiagnostic tests and neuromuscular ultrasound. *Clinical Neurophysiology*. 10.1016/j.clinph.2021.12.012
8. Wang WL, Hanson T, Fowler JR (2019) A Comparison of 6 Diagnostic Tests for Carpal Tunnel Syndrome Using Latent Class Analysis. *HAND*:1558944719833709
9. Roll SC, Volz KR, Fahy CM, Evans KD (2015) Carpal tunnel syndrome severity staging using sonographic and clinical measures. *Muscle Nerve* 51:838–845 [PubMed: 25287477]
10. Bathala L, Kumar P, Kumar K, Shaik AB, Visser LH (2014) Normal values of median nerve cross-sectional area obtained by ultrasound along its course in the arm with electrophysiological correlations, in 100 Asian subjects. *Muscle & Nerve* 49:284–286 [PubMed: 23703739]
11. Burg EWV, Bathala L, Visser LH (2014) Difference in normal values of median nerve cross-sectional area between Dutch and Indian subjects. *Muscle & Nerve* 50:129–132 [PubMed: 24265182]
12. Qrimli M, Ebadi H, Breiner A et al. (2016) Reference values for ultrasonography of peripheral nerves. *Muscle & Nerve* 53:538–544 [PubMed: 26316047]
13. Cartwright MS, Mayans DR, Gillson NA, Griffin LP, Walker FO (2013) Nerve cross-sectional area in extremes of age. *Muscle & Nerve* 47:890–893 [PubMed: 23670837]
14. Guillen-Astete CA, Muñoz-Martínez de Castilla A, Zurita-Prada P, García-Casado P, Urrego-Laurín C (2020) Relationship between anthropometric variables and the cross-sectional area of the median nerve by ultrasound assessment in healthy subjects. *Acta Reumatológica Portuguesa* 45
15. Moher D, Liberati A, Tetzlaff J, Altman DG (2009) Preferred reporting items for systematic reviews and meta-analyses: the PRISMA statement. *Ann Intern Med* 151:264–269, W264 [PubMed: 19622511]
16. Takata SC, Kysh L, Mack WJ, Roll SC (2019) Sonographic reference values of median nerve cross-sectional area: a protocol for a systematic review and meta-analysis. *Syst Rev* 8:2 [PubMed: 30606255]
17. National Heart Lung and Blood Institute Quality assessment tool for observational cohort and cross-sectional studies. Available via <https://www.nhlbi.nih.gov/health-topics/study-quality-assessment-tools>. Accessed January 11 2022
18. Li X, Li JW, Ho AM-H, Karmakar MK (2015) Age-related differences in the quantitative echo texture of the median nerve. *Journal of Ultrasound in Medicine* 34:797–804 [PubMed: 25911712]
19. Roomizadeh P, Eftekharsadat B, Abedini A et al. (2019) Ultrasonographic assessment of carpal tunnel syndrome severity: a systematic review and meta-analysis. *American Journal of Physical Medicine & Rehabilitation* 98:373–381
20. Klauser AS, Halpern EJ, De Zordo T et al. (2009) Carpal tunnel syndrome assessment with US: value of additional cross-sectional area measurements of the median nerve in patients versus healthy volunteers. *Radiology* 250:171–177 [PubMed: 19037017]
21. Hobson-Webb LD, Massey JM, Juel VC, Sanders DB (2008) The ultrasonographic wrist-to-forearm median nerve area ratio in carpal tunnel syndrome. *Clin Neurophysiol* 119:1353–1357 [PubMed: 18387336]

22. Wang WL, Hanson T, Fowler JR (2020) A comparison of 6 diagnostic tests for carpal tunnel syndrome using latent class analysis. *Hand* 15:776–779 [PubMed: 30854901]
23. Ajeena IM, Al-Saad RH, Al-Mudhafar A, Hadi NR, Al-Aridhy SH (2013) Ultrasonic assessment of females with carpal tunnel syndrome proved by nerve conduction study. *Neural Plast* 2013:754564 [PubMed: 23864961]
24. Ghasemi-Esfe AR, Khalilzadeh O, Mazloumi M et al. (2011) Combination of high-resolution and color Doppler ultrasound in diagnosis of carpal tunnel syndrome. *Acta Radiol* 52:191–197 [PubMed: 21498348]
25. Horng YS, Hsieh SF, Lin MC, Chang YW, Lee KC, Liang HW (2014) Ultrasonographic median nerve changes under tendon gliding exercise in patients with carpal tunnel syndrome and healthy controls. *J Hand Ther* 27:317–323; quiz 324 [PubMed: 25240682]
26. Kwon BC, Jung KI, Baek GH (2008) Comparison of sonography and electrodiagnostic testing in the diagnosis of carpal tunnel syndrome. *J Hand Surg [Am]* 33:65–71
27. Tajika T, Kobayashi T, Yamamoto A, Kaneko T, Takagishi K (2013) Diagnostic utility of sonography and correlation between sonographic and clinical findings in patients with carpal tunnel syndrome. *J Ultrasound Med* 32:1987–1993 [PubMed: 24154903]
28. Boehm J, Scheidl E, Bereczki D, Schelle T, Aranyi Z (2014) High-resolution ultrasonography of peripheral nerves: measurements on 14 nerve segments in 56 healthy subjects and reliability assessments. *Ultraschall Med* 35:459–467 [PubMed: 24764211]
29. Junck AD, Escobedo EM, Lipa BM et al. (2015) Reliability Assessment of Various Sonographic Techniques for Evaluating Carpal Tunnel Syndrome. *J Ultrasound Med* 34:2077–2088 [PubMed: 26453123]
30. Kerasnoudis A, Pitarokouli K, Behrendt V, Gold R, Yoon MS (2013) Cross sectional area reference values for sonography of peripheral nerves and brachial plexus. *Clin Neurophysiol* 124:1881–1888 [PubMed: 23583024]
31. Mansiz Kaplan B, Ya ci , Akdeniz Leblebicier M (2016) Ultrasonographic assessment of the shoulder in patients with carpal tunnel syndrome. *Marmara Medical Journal* 29:102–109
32. Rahmani M, Ghasemi Esfe AR, Vaziri-Bozorg SM, Mazloumi M, Khalilzadeh O, Kahnouji H (2011) The ultrasonographic correlates of carpal tunnel syndrome in patients with normal electrodiagnostic tests.[Erratum appears in *Radiol Med*. 2011 Apr;116(3):503 Note: Bozorg, S M [corrected to Vaziri-Bozorg, S M]]. *Radiol Med (Torino)* 116:489–496 [PubMed: 21293941]
33. Woo EHC, White P, Lai CWK (2019) Morphological changes of the median nerve within the carpal tunnel during various finger and wrist positions: an analysis of intensive and nonintensive electronic device users. *The Journal of Hand Surgery* 44:610. e611–610. e615
34. Cartwright MS, Shin HW, Passmore LV, Walker FO (2009) Ultrasonographic reference values for assessing the normal median nerve in adults. *Journal of Neuroimaging* 19:47–51 [PubMed: 18482371]
35. Cartwright MS, Baute V, Caress JB, Walker FO (2017) Ultrahigh-frequency ultrasound of fascicles in the median nerve at the wrist. *Muscle & Nerve* 56:819–822 [PubMed: 28214293]
36. Ghasemi-Esfe AR, Khalilzadeh O, Vaziri-Bozorg SM et al. (2011) Color and power Doppler US for diagnosing carpal tunnel syndrome and determining its severity: a quantitative image processing method. *Radiology* 261:499–506 [PubMed: 21900619]
37. Kang S, Yang SN, Yoon JS, Kang HJ, Won SJ (2016) Effect of carpal tunnel syndrome on the ulnar nerve at the wrist: sonographic and electrophysiologic studies. *Journal of Ultrasound in Medicine* 35:37–42 [PubMed: 26589645]
38. Kantarci F, Ustabasioglu FE, Delil S et al. (2014) Median nerve stiffness measurement by shear wave elastography: a potential sonographic method in the diagnosis of carpal tunnel syndrome. *Eur Radiol* 24:434–440 [PubMed: 24220753]
39. Kim HS, Joo SH, Han Z-A, Kim YW (2012) The nerve/tunnel index: a new diagnostic standard for carpal tunnel syndrome using sonography: a pilot study. *Journal of Ultrasound in Medicine* 31:23–29 [PubMed: 22215765]
40. Lai WKC, Chiu YT, Law WS (2014) The deformation and longitudinal excursion of median nerve during digits movement and wrist extension. *Manual Therapy* 19:608–613 [PubMed: 25024110]

41. Loh PY, Muraki S (2015) Effect of wrist angle on median nerve appearance at the proximal carpal tunnel. *PLoS One* 10:e0117930 [PubMed: 25658422]
42. Loh PY, Nakashima H, Muraki S (2015) Median nerve behavior at different wrist positions among older males. *PeerJ* 3:e928 [PubMed: 25945317]
43. Mohammadi A, Afshar A, Masoudi S, Etemadi A (2009) Comparison of high resolution ultrasonography and nerve conduction study in the diagnosis of carpal tunnel syndrome: diagnostic value of median nerve cross-sectional area. *Iran J Radiol* 6:147–152
44. Ooi CC, Wong SK, Tan AB et al. (2014) Diagnostic criteria of carpal tunnel syndrome using high-resolution ultrasonography: correlation with nerve conduction studies. *Skeletal Radiol.* 10.1007/s00256-014-1929-z
45. Roll SC, Evans KD, Li X, Freimer M, Sommerich CM (2011) Screening for carpal tunnel syndrome using sonography. *J Ultrasound Med* 30:1657–1667 [PubMed: 22124001]
46. ahin Ö, enocak E, Üzümlü H, Kıyan A, Ço algil (2010) Ultrasonographic evaluation of median nerve in tennis training athletes. *Erciyes Tıp Dergisi* 32:247–252
47. Toosi KK, Impink BG, Baker NA, Boninger ML (2011) Effects of computer keyboarding on ultrasonographic measures of the median nerve. *American Journal of Industrial Medicine* 54:826–833 [PubMed: 21739468]
48. Werner RA, Jacobson JA, Jamadar DA (2004) Influence of body mass index on median nerve function, carpal canal pressure, and cross-sectional area of the median nerve. *Muscle & Nerve* 30:481–485 [PubMed: 15372540]
49. Won SJ, Kim BJ, Park KS, Yoon JS, Choi H (2013) Reference values for nerve ultrasonography in the upper extremity. *Muscle Nerve* 47:864–871 [PubMed: 23625758]
50. Chen S-F, Lu C-H, Huang C-R et al. (2011) Ultrasonographic median nerve cross-section areas measured by 8-point” inching test” for idiopathic carpal tunnel syndrome: a correlation of nerve conduction study severity and duration of clinical symptoms. *BMC Med Imaging* 11:1–9 [PubMed: 21199574]
51. Choo HJ, Lee SJ, Park Y-M, Kim DW (2017) Distally extended muscle belly of the flexor digitorum within the carpal tunnel: is it a risk factor for carpal tunnel syndrome? *Acta Radiologica* 58:1269–1275 [PubMed: 28173726]
52. Kasius KM, Claes F, Meulstee J, Verhagen WI (2014) Bifid median nerve in carpal tunnel syndrome: Do we need to know? *Muscle Nerve* 50:835–843 [PubMed: 24599605]
53. Kaymak B, Ozcakar L, Cetin A, Candan Cetin M, Akinçi A, Hascelik Z (2008) A comparison of the benefits of sonography and electrophysiologic measurements as predictors of symptom severity and functional status in patients with carpal tunnel syndrome. *Arch Phys Med Rehabil* 89:743–748 [PubMed: 18374007]
54. Lee KM, Kim HJ (2016) Relationship between electrodiagnosis and various ultrasonographic findings for diagnosis of carpal tunnel syndrome. *Ann Rehabil Med* 40:1040–1047 [PubMed: 28119834]
55. Loh PY, Nakashima H, Muraki S (2016) Effects of grip force on median nerve deformation at different wrist angles. *PeerJ* 4:e2510 [PubMed: 27688983]
56. Loh PY, Muraki S (2014) Effect of wrist deviation on median nerve cross-sectional area at proximal carpal tunnel level. *Iranian Journal of Public Health* 43:180–185
57. Ng A, Griffith J, Lee R, Tse W, Wong C, Ho P (2018) Ultrasound carpal tunnel syndrome: additional criteria for diagnosis. *Clinical Radiology* 73:214. e211–214. e218
58. Noto YI, Garg N, Li T et al. (2018) Comparison of cross-sectional areas and distal-proximal nerve ratios in amyotrophic lateral sclerosis. *Muscle & Nerve* 58:777–783 [PubMed: 30019401]
59. Pitarokoilı K, Kerasnoudis A, Behrendt V et al. (2016) Facing the diagnostic challenge: Nerve ultrasound in diabetic patients with neuropathic symptoms. *Muscle & Nerve* 54:18–24 [PubMed: 26575030]
60. Toosi KK, Hogaboom NS, Oyster ML, Boninger ML (2015) Computer keyboarding biomechanics and acute changes in median nerve indicative of carpal tunnel syndrome. *Clinical Biomechanics* 30:546–550 [PubMed: 25933812]

61. Yang SN, Kang HJ, Yoon JS, Won SJ, Seo W-K, Koh SB (2014) Is median nerve enlargement at the wrist associated with tremor in Parkinson disease? *Journal of Ultrasound in Medicine* 33:2079–2083 [PubMed: 25425363]
62. Yurdakul OV, Mesci N, Çetinkaya Y, Külcü DG (2016) Diagnostic significance of ultrasonographic measurements and median-ulnar ratio in carpal tunnel syndrome: correlation with nerve conduction studies. *Journal of Clinical Neurology* 12:289–294 [PubMed: 27095524]
63. Atan T, Günendi Z (2018) Diagnostic utility of the sonographic median to ulnar nerve cross-sectional area ratio in carpal tunnel syndrome. *Turkish Journal of Medical Sciences* 48:110–116 [PubMed: 29479967]
64. Kang S, Kim SH, Yang SN, Yoon JS (2016) Sonographic features of peripheral nerves at multiple sites in patients with diabetic polyneuropathy. *Journal of Diabetes and its Complications* 30:518–523 [PubMed: 26782023]
65. Nodera H, Takamatsu N, Shimatani Y et al. (2014) Thinning of cervical nerve roots and peripheral nerves in ALS as measured by sonography. *Clinical Neurophysiology* 125:1906–1911 [PubMed: 24657162]
66. Su PH, Chen WS, Wang TG, Liang HW (2013) Correlation between subclinical median neuropathy and the cross-sectional area of the median nerve at the wrist. *Ultrasound Med Biol* 39:975–980 [PubMed: 23499346]
67. Borire AA, Arnold R, Pussell BA et al. (2018) Effects of hemodialysis on intraneural blood flow in end-stage kidney disease. *Muscle & Nerve* 57:287–293 [PubMed: 28556350]
68. De Kleermaeker FG, Meulstee J, Verhagen WI (2019) The controversy of the normal values of ultrasonography in carpal tunnel syndrome: diagnostic accuracy of wrist-dependent CSA revisited. *Neurological Sciences* 40:1041–1047 [PubMed: 30796623]
69. El Miedany YM, Aty SA, Ashour S (2004) Ultrasonography versus nerve conduction study in patients with carpal tunnel syndrome: substantive or complementary tests? *Rheumatology (Oxford)* 43:887–895 [PubMed: 15100417]
70. Jang JH, Cho CS, Yang K-S, Seok HY, Kim B-J (2014) Pattern analysis of nerve enlargement using ultrasonography in chronic inflammatory demyelinating polyneuropathy. *Clinical Neurophysiology* 125:1893–1899 [PubMed: 24560630]
71. Kotb MA, Bedewi MA, Aldossary NM, Mahmoud G, Naguib MF (2018) Sonographic assessment of carpal tunnel syndrome in diabetic patients with and without polyneuropathy. *Medicine* 97:e11104 [PubMed: 29901629]
72. Lee HL, Kim J-s, Kim H et al. (2019) Ultrasonography and electrophysiological study of median nerve in patients with essential tremor. *PLoS One* 14:e0215750 [PubMed: 31013299]
73. Mohamed RE, Amin MA, Aboelsafa AA, Elsayed SE (2014) Contribution of power Doppler and gray-scale ultrasound of the median nerve in evaluation of carpal tunnel syndrome. *The Egyptian Journal of Radiology and Nuclear Medicine* 45:191–201
74. Mori A, Nodera H, Takamatsu N et al. (2015) Focal nerve enlargement is not the cause for increased distal motor latency in ALS: sonographic evaluation. *Clinical Neurophysiology* 126:1632–1637 [PubMed: 25465357]
75. Mulroy E, Pelosi L, Leadbetter R et al. (2018) Peripheral nerve ultrasound in Friedreich ataxia. *Muscle & Nerve* 57:852–856 [PubMed: 29130498]
76. Wang LY, Leong CP, Huang YC, Hung JW, Cheung SM, Pong YP (2008) Best diagnostic criterion in high-resolution ultrasonography for carpal tunnel syndrome. *Chang Gung Med J* 31:469–476 [PubMed: 19097594]
77. Watanabe T, Sakakibara N, Sugimori H et al. (2012) Effect of long-term physical exercise of peripheral nerve: comparison of nerve conduction study and ultrasonography. *The Journal of Sports Medicine and Physical Fitness* 52:212–220 [PubMed: 22525659]
78. Agirman M, Yagci I, Leblebici MA, Ozturk D, Akyuz GD (2016) Is ultrasonography useful in the diagnosis of the polyneuropathy in diabetic patients? *Journal of Physical Therapy Science* 28:2620–2624 [PubMed: 27799707]
79. Borire AA, Issar T, Kwai NC et al. (2018) Correlation between markers of peripheral nerve function and structure in type 1 diabetes. *Diabetes/Metabolism Research and Reviews* 34:e3028 [PubMed: 29858541]

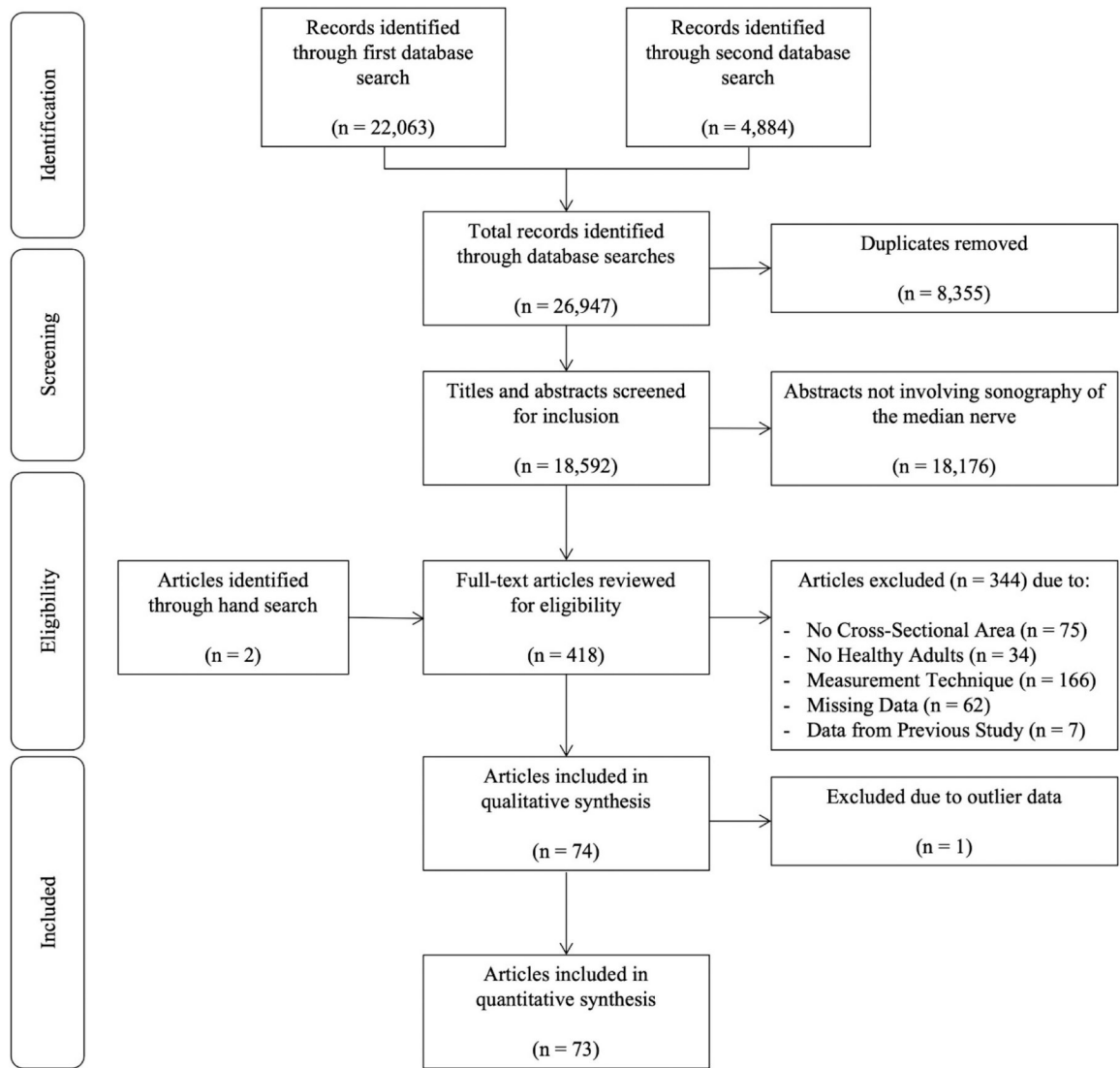
80. Cartwright MS, Walker FO, Griffin LP, Caress JB (2011) Peripheral nerve and muscle ultrasound in amyotrophic lateral sclerosis. *Muscle & Nerve* 44:346–351 [PubMed: 21815172]
81. Fujimoto K, Kanchiku T, Kido K, Imajo Y, Funaba M, Taguchi T (2015) Diagnosis of Severe Carpal Tunnel Syndrome Using Nerve Conduction Study and Ultrasonography. *Ultrasound Med Biol* 41:2575–2580 [PubMed: 26111913]
82. Lopes MM, Lawson W, Scott T, Keir PJ (2011) Tendon and nerve excursion in the carpal tunnel in healthy and CTD wrists. *Clinical Biomechanics* 26:930–936 [PubMed: 21550703]
83. Im Moon H, Kwon HK, Kim L, Lee HJ, Lee HJ (2014) Ultrasonography of palm to elbow segment of median nerve in different degrees of diabetic polyneuropathy. *Clinical Neurophysiology* 125:844–848 [PubMed: 24269093]
84. Park D (2017) Ultrasonography of the Transverse Movement and Deformation of the Median Nerve and Its Relationships With Electrophysiological Severity in the Early Stages of Carpal Tunnel Syndrome. *PM R* 9:1085–1094 [PubMed: 28433831]
85. Scheidl E, Böhm J, Simó M, Bereznaï B, Bereczki D, Arányi Z (2014) Different patterns of nerve enlargement in polyneuropathy subtypes as detected by ultrasonography. *Ultrasound in Medicine & Biology* 40:1138–1145 [PubMed: 24613217]
86. Schreiber S, Oldag A, Kornblum C et al. (2013) Sonography of the median nerve in CMT1A, CMT2A, CMTX, and HNPP. *Muscle & Nerve* 47:385–395 [PubMed: 23381770]
87. Borire AA, Arnold R, Pussell BA et al. (2017) Haemodialysis alters peripheral nerve morphology in end-stage kidney disease. *Clinical Neurophysiology* 128:281–286 [PubMed: 27743880]
88. Koyuncuoglu HR, Kutluhan S, Yesildag A, Oyar O, Guler K, Ozden A (2005) The value of ultrasonographic measurement in carpal tunnel syndrome in patients with negative electrodiagnostic tests. *Eur J Radiol* 56:365–369 [PubMed: 15994046]
89. Miwa T, Miwa H (2011) Ultrasonography of carpal tunnel syndrome: clinical significance and limitations in elderly patients. *Internal Medicine* 50:2157–2161 [PubMed: 21963734]
90. Pelosi L, Mulroy E, Leadbetter R et al. (2018) Peripheral nerves are pathologically small in cerebellar ataxia neuropathy vestibular areflexia syndrome: a controlled ultrasound study. *European Journal of Neurology* 25:659–665 [PubMed: 29316033]
91. Schreiber S, Abdulla S, Debska-Vielhaber G et al. (2015) Peripheral nerve ultrasound in amyotrophic lateral sclerosis phenotypes. *Muscle & Nerve* 51:669–675 [PubMed: 25155020]
92. Van Doesburg MH, Henderson J, Yoshii Y et al. (2012) Median nerve deformation in differential finger motions: ultrasonographic comparison of carpal tunnel syndrome patients and healthy controls. *Journal of Orthopaedic Research* 30:643–648 [PubMed: 21953849]
93. Arumugam T, Razali S, Vethakkan S, Rozalli F, Shahrizaila N (2016) Relationship between ultrasonographic nerve morphology and severity of diabetic sensorimotor polyneuropathy. *European Journal of Neurology* 23:354–360 [PubMed: 26498575]
94. Hammer HB, Hovden IA, Haavardsholm EA, Kvien TK (2006) Ultrasonography shows increased cross-sectional area of the median nerve in patients with arthritis and carpal tunnel syndrome. *Rheumatology (Oxford)* 45:584–588 [PubMed: 16332951]
95. Niu J, Cui L, Liu M (2017) Multiple sites ultrasonography of peripheral nerves in differentiating charcot–marie–tooth type 1A from chronic inflammatory demyelinating polyradiculoneuropathy. *Frontiers in neurology* 8:181 [PubMed: 28522988]



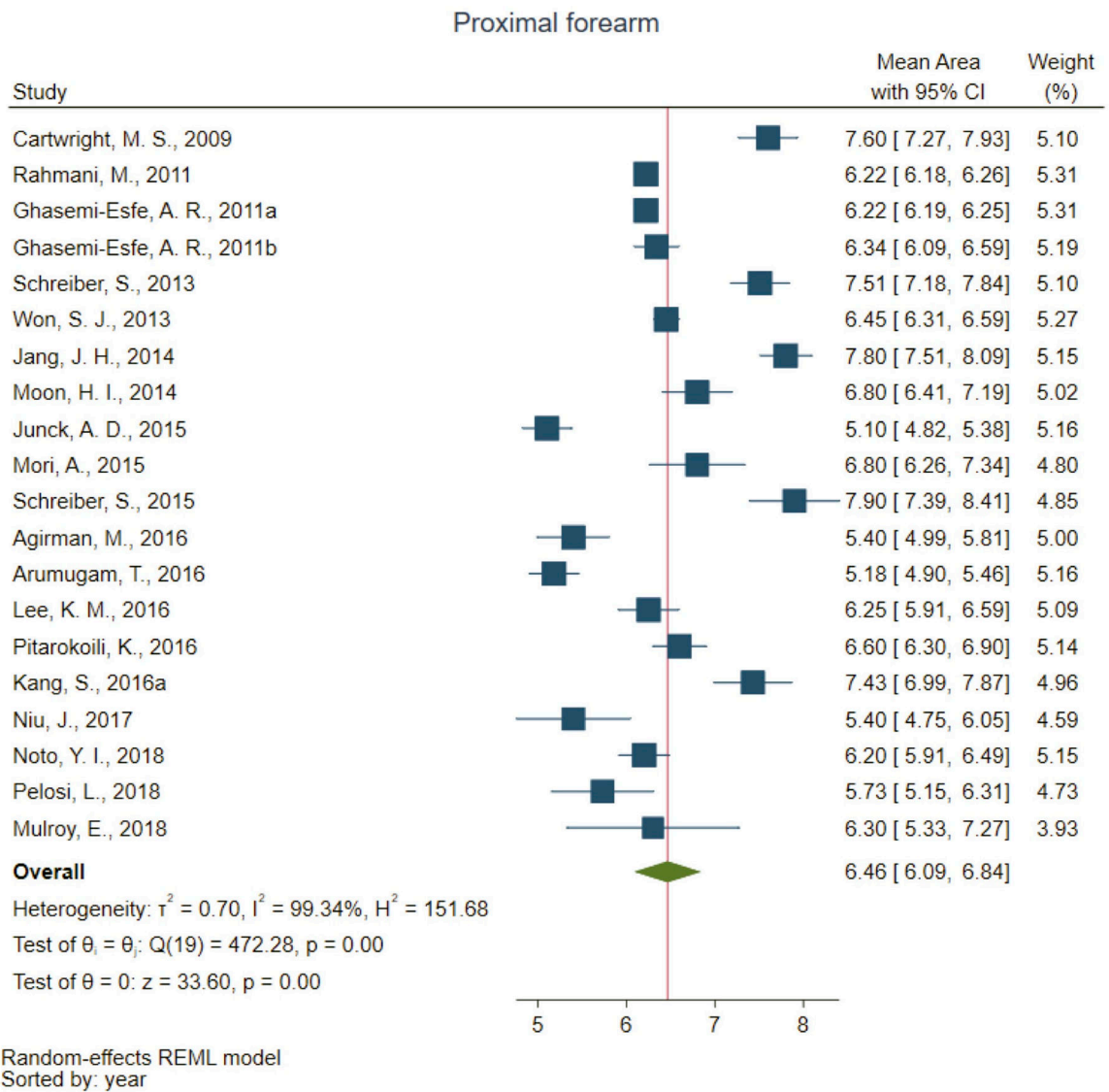
**Key Points:**

- A healthy median nerve cross-sectional area reference at the pisiform is 8.60mm<sup>2</sup>.
- Age adjustments for median nerve reference values are not indicated in adults.
- Healthy men have larger nerves that may exceed common diagnostic thresholds.
- Healthy nerves do not differ in size between wrists.
- Differences in nerve area between wrists may be a viable diagnostic indicator.





**Figure 1.** Flow chart of studies through the search, screening, eligibility, and inclusion process.



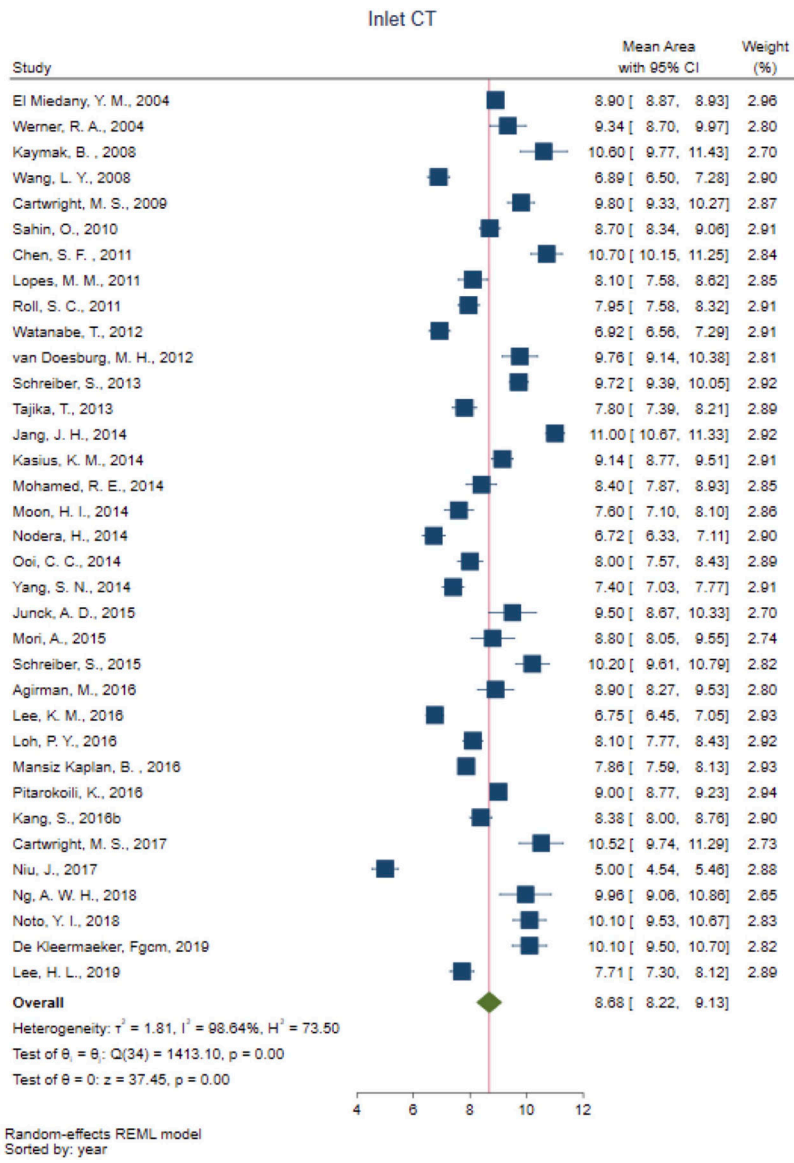
**Figure 2.** Forest plot of meta-analysis results showing the direction and magnitude of the weighted averages of median nerve cross-sectional area (CSA) in the proximal forearm 10cm or greater from the wrist across individual studies.

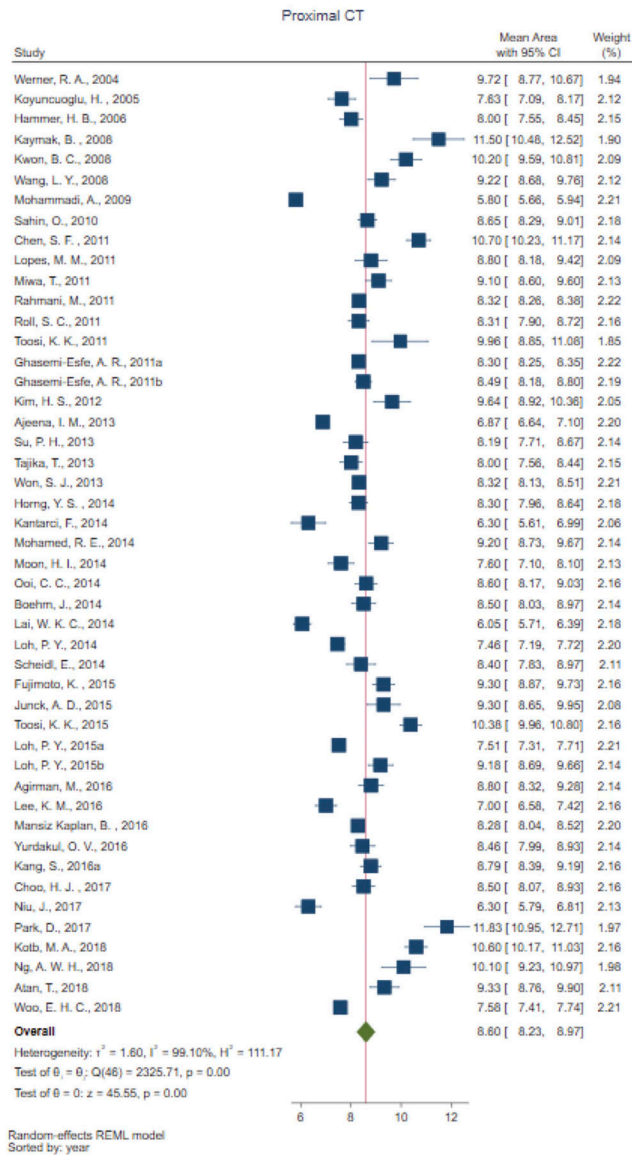
Author Manuscript

Author Manuscript

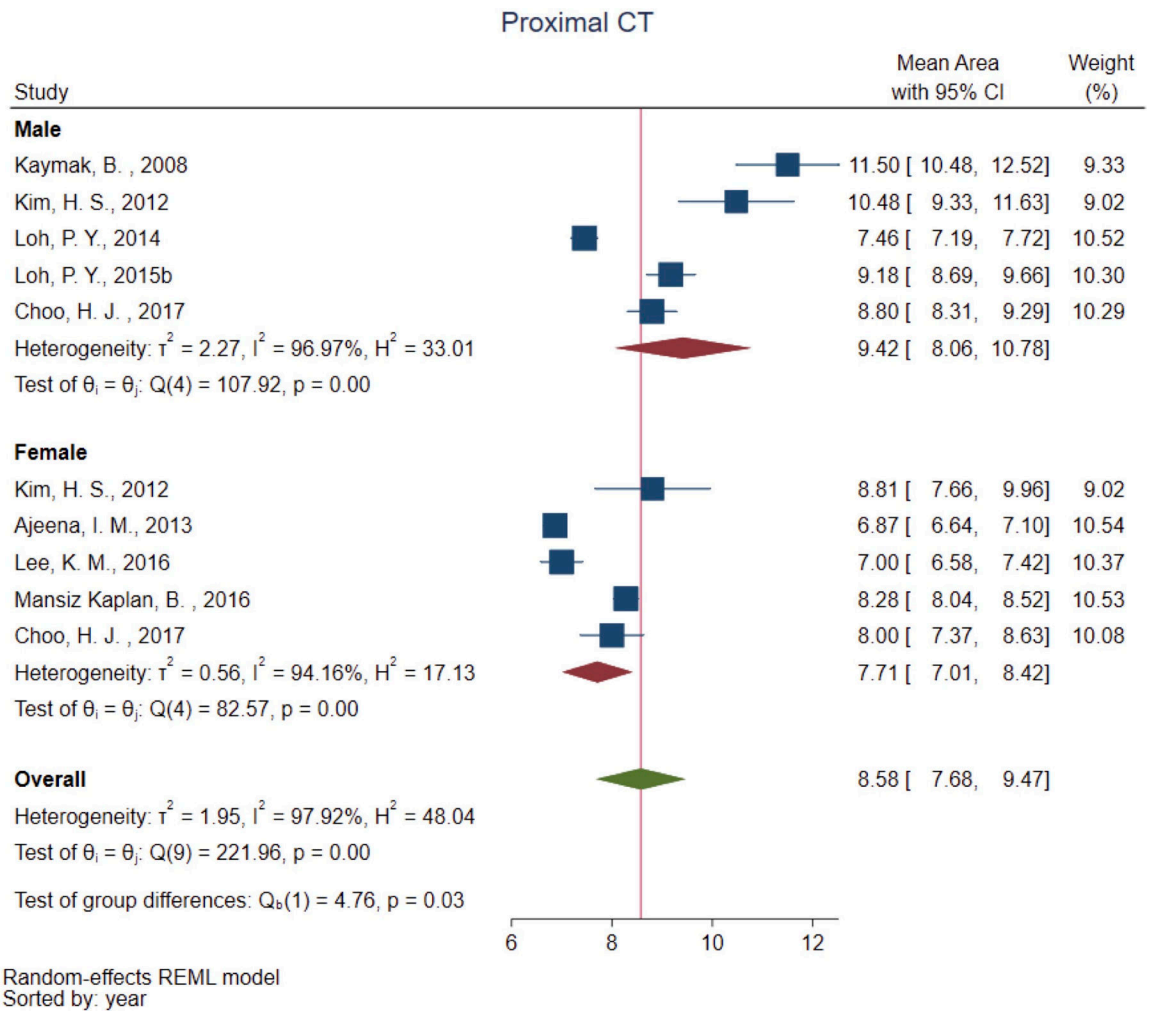
Author Manuscript

Author Manuscript

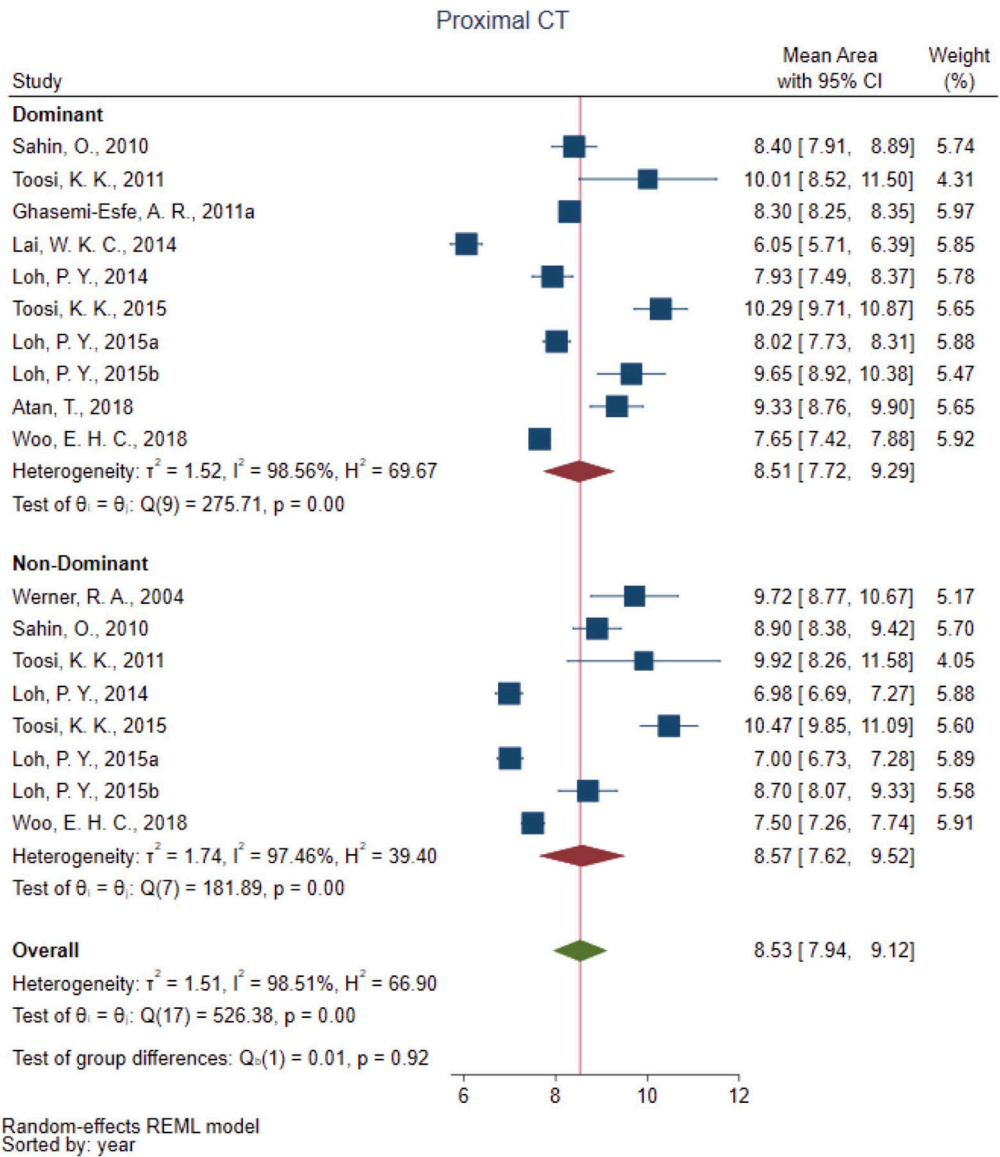




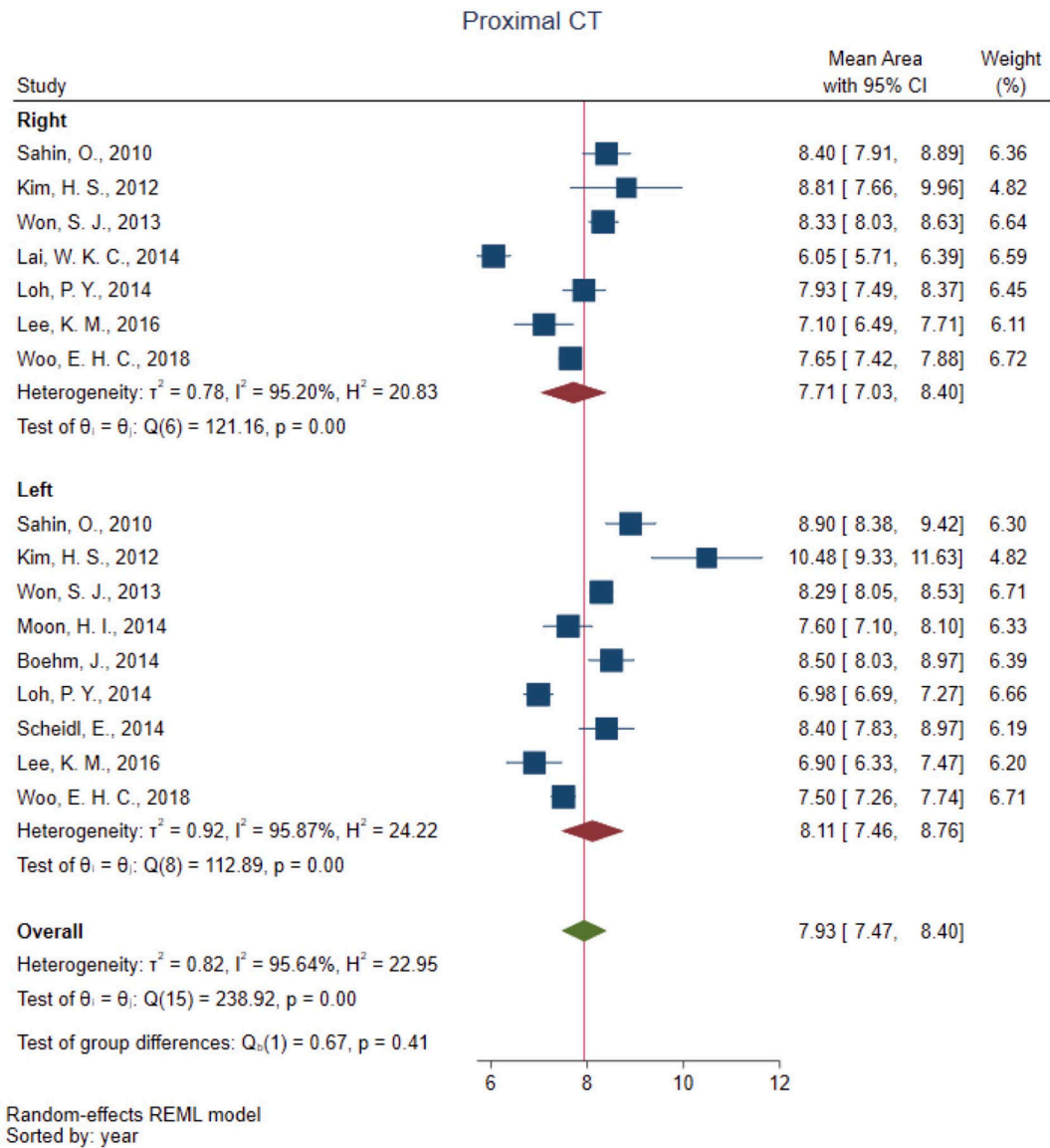
**Figure 3.** Forest plot of meta-analysis results showing the direction and magnitude of the weighted averages of median nerve cross-sectional area (CSA) at the inlet to the carpal tunnel (CT) up to 4cm proximal to the radial carpal joint (i.e., distal wrist crease; 3a) and proximal CT at the level of the pisiform (3b) across individual studies.



**Figure 4.** Forest plots showing group differences for weighted averages of median nerve cross-sectional area (CSA) in the proximal carpal tunnel (CT) among studies that provided data stratified by sex demonstrating significantly larger CSA ( $p=0.03$ ) in men ( $9.42\text{mm}^2$ ) than in women ( $8.58\text{mm}^2$ ).







**Figure 5.** Forest plots showing group differences for weighted averages of median nerve cross-sectional area (CSA) in the proximal carpal tunnel (CT) among studies that provided data stratified by hand dominance (5a) or side (5b) demonstrating no differences based on laterality ( $p=0.92$ ,  $p=0.41$ ).



**Table 1.**

Parameters used to categorize median nerve measures reported across the included studies into anatomical regions for analysis.

<b>Region</b>	<b>Descriptions of anatomical regions reported across studies</b>
Axilla	Axillary fossa
Humerus	Midpoint of the upper arm, mid humerus, or midpoint between medial epicondyle and axillary fossa
Elbow	Antecubital fossa to the pronator teres
Proximal forearm	At the pronator teres to 10 cm proximal to the distal wrist crease
Distal forearm	Between 4 cm and 10 cm proximal to distal wrist crease
Carpal tunnel inlet	Less than 4 cm proximal to or at the distal wrist crease, distal radioulnar joint, lunate, pronator quadratus, proximal scaphoid
Proximal carpal tunnel	At the pisiform, distal scaphoid, or under the flexor retinaculum
Distal carpal tunnel	At the hook of hamate or trapezium
Carpal tunnel outlet	Over the metacarpal bones or in the palm

**Table 2.**

Quality assessment of included studies, sorted by quality score.

Study	Rating	Score	Criterion							
			1	2	3	4	5	6	7	8
Ajeena et al [23]	Good	8	+	+	+	+	+	+	+	+
Ghasemi-Esfe et al [24]	Good	8	+	+	+	+	+	+	+	+
Hornig et al [25]	Good	8	+	+	+	+	+	+	+	+
Kwon et al [26]	Good	8	+	+	+	+	+	+	+	+
Tajika et al [27]	Good	8	+	+	+	+	+	+	+	+
Boehm et al [28]	Good	7.5	+	+	+	+	+	+	+	+
Junck et al [29]	Good	7.5	+	+	+	+	+	+	+	+
Kerasnoudis et al [30]	Good	7.5	+	+	+	+	+	+	+	+
Mansiz Kaplan et al [31]	Good	7.5	+	+	+	+	+	+	+	+
Rahmani et al [32]	Good	7.5	+	+	+	+	+	+	+	+
Woo et al [33]	Good	7.5	+	+	+	+	+	+	+	+
Cartwright et al [34]	Good	7	+	+	+	-	+	+	+	+
Cartwright et al [35]	Good	7	+	+	+	-	+	+	+	+
Ghasemi-Esfe et al [36]	Good	7	+	+	+	+	+	+	+	+
Kang et al [37]	Good	7	+	+	+	-	+	+	+	+
Kantarci et al [38]	Good	7	+	+	+	+	+	+	+	?
Kim et al [39]	Good	7	+	+	+	+	+	+	+	+
Lai et al [40]	Good	7	+	+	+	+	+	+	+	+
Loh et al [41]	Good	7	+	+	+	+	+	+	?	+
Loh et al [42]	Good	7	+	+	+	+	+	?	+	+
Mohammadi et al [43]	Good	7	+	+	+	+	+	+	+	?
Ooi et al [44]	Good	7	+	+	+	+	+	+	+	?
Roll et al [45]	Good	7	+	+	+	+	+	+	+	-
Sahin et al [46]	Good	7	+	+	+	+	+	?	+	+
Toosi et al [47]	Good	7	+	+	+	+	+	?	+	+
Werner et al [48]	Good	7	+	+	+	-	+	+	+	+
Won et al [49]	Good	7	+	+	+	+	+	+	?	+
Chen et al [50]	Good	6.5	+	+	+	+	+	+	?	+
Choo et al [51]	Good	6.5	+	+	+	+	+	+	?	+
Kasius et al [52]	Good	6.5	+	+	+	+	+	+	+	-
Kaymak et al [53]	Good	6.5	+	+	+	+	+	?	+	+
Lee et al [54]	Good	6.5	+	+	+	+	+	?	+	+
Loh et al [55]	Good	6.5	+	+	+	+	+	?	+	+
Loh et al [56]	Good	6.5	+	+	+	+	+	?	+	+
Ng et al [57]	Good	6.5	+	+	+	+	+	?	+	+
Noto et al [58]	Good	6.5	+	+	+	+	+	+	+	+
Pitaroköllü et al [59]	Good	6.5	+	+	+	+	+	+	?	+
Toosi et al [60]	Good	6.5	+	+	+	+	+	?	+	+
Yang et al [61]	Good	6.5	+	+	+	-	+	+	+	+
Yurdakul et al [62]	Good	6.5	+	+	+	+	+	?	+	+
Atan et al [63]	Fair	6	+	+	+	+	+	?	+	+
Kang et al [64]	Fair	6	+	+	+	+	+	?	+	+
Nodera et al [65]	Fair	6	+	+	+	-	+	?	+	+
Su et al [66]	Fair	6	+	+	+	+	+	?	+	+
Borire et al [67]	Fair	5.5	+	+	-	+	+	?	+	+

Author Manuscript

Author Manuscript

Author Manuscript

Author Manuscript

Author Manuscript

Author Manuscript

Author Manuscript

Author Manuscript

De Kleermaeker et al [68]	Fair	5.5	+	+	+	+	+	+	?	-
El Miedany et al [69]	Fair	5.5	+	+	+	+	-	+	?	+
Jang et al [70]	Fair	5.5	+	+	+	-	+	+	?	+
Kotb et al [71]	Fair	5.5	+	+	+	+	+	+	?	-
Lee et al [72]	Fair	5.5	+	+	+	-	+	+	+	-
Mohamed et al [73]	Fair	5.5	+	+	+	+	+	?	?	+
Mori et al [74]	Fair	5.5	+	+	+	-	+	?	+	+
Mulroy et al [75]	Fair	5.5	+	+	+	-	+	?	+	+
Wang et al [76]	Fair	5.5	+	+	+	+	+	?	?	+
Watanabe et al [77]	Fair	5.5	+	+	+	+	-	+	?	+
Agirman et al [78]	Fair	5	+	+	-	+	+	+	+	-
Borire et al [79]	Fair	5	+	+	-	+	+	?	+	+
Cartwright et al [80]	Fair	5	+	+	+	+	+	?	?	+
Fujimoto et al [81]	Fair	5	+	+	+	+	-	+	+	-
Lopes et al [82]	Fair	5	+	+	+	+	+	+	?	-
Moon et al [83]	Fair	5	+	+	+	+	+	?	+	-
Park et al [84]	Fair	5	+	+	-	+	+	+	?	+
Scheidl et al [85]	Fair	5	+	+	+	+	+	?	+	-
Schreiber et al [86]	Fair	5	+	+	+	-	+	?	?	+
Borire et al [87]	Fair	4.5	-	+	+	+	+	?	+	+
Koyuncuoglu et al [88]	Fair	4.5	+	+	+	+	+	?	?	?
Miwa et al [89]	Fair	4.5	+	+	-	+	+	?	+	-
Pelosi et al [90]	Fair	4.5	+	+	+	-	+	?	?	+
Schreiber et al [91]	Poor	4	-	+	+	-	+	?	?	+
van Doesburg et al [92]	Poor	4	-	+	+	+	+	?	?	?
Arumugam et al [93]	Poor	3.5	+	+	-	-	+	?	?	+
Hammer et al [94]	Poor	3.5	+	+	+	+	+	?	?	-
Niu et al [95]	Poor	2	-	+	+	-	+	?	?	-

**Note.** green plus = satisfactorily met the criterion; yellow plus = partially met the criterion; red minus = did not meet criterion; grey question mark = did not report on the criterion. Quality assessment was conducted using a modified version of the National Institute of Health Study Quality Assessment Tool for Observational Cohort and Cross-Sectional Studies [17] using the eight criteria as previously described [16].

**Table 3.**

Meta-analytic averages for cross-sectional area (CSA) of the median nerve within healthy individuals across anatomical regions of the upper extremity.

Anatomical Region	N	Weighted Mean	95% CI	I <sup>2</sup>
Axilla	1	7.90	7.53 – 8.27	-
Humerus	12	9.27	8.50 – 10.05	97.1
Elbow	6	8.32	7.69 – 8.95	88.7
Proximal Forearm	20	6.46	6.09 – 6.84	99.3
Distal Forearm	9	6.20	5.87 – 6.53	92.9
Carpal Tunnel Inlet	35	8.68	8.22 – 9.13	98.6
Proximal Carpal Tunnel	47	8.60	8.23 – 8.97	99.1
Distal Carpal Tunnel	15	8.43	7.62 – 9.25	98.6
Carpal Tunnel Outlet	2	11.12	9.77 – 12.47	86.7

Author Manuscript

Author Manuscript

Author Manuscript

Author Manuscript