

# UCSF

## UC San Francisco Previously Published Works

### Title

The Effect of Tube Location on Corneal Endothelial Cells in Patients with Ahmed Glaucoma Valve

### Permalink

<https://escholarship.org/uc/item/0kc3m8dq>

### Journal

Ophthalmology, 128(2)

### ISSN

0161-6420

### Authors

Zhang, Qi  
Liu, Yingna  
Thanapaisal, Sukhumal  
[et al.](#)

### Publication Date

2021-02-01

### DOI

10.1016/j.opthta.2020.06.050

Peer reviewed



Published in final edited form as:

*Ophthalmology*. 2021 February ; 128(2): 218–226. doi:10.1016/j.ophtha.2020.06.050.

## The Effect of Tube Location on Corneal Endothelial Cells in Patients with Ahmed Glaucoma Valve

Qi Zhang, MD, PhD<sup>1,2,\*</sup>, Yingna Liu, MD<sup>1,\*</sup>, Sukhumal Thanapaisal, MD<sup>1,3</sup>, Julius Oatts, MD<sup>1</sup>, Yetao Luo, MAS<sup>4</sup>, Gui-Shuang Ying, PhD<sup>5</sup>, Junming Wang, MD, PhD<sup>6</sup>, Stephen D. McLeod, MD<sup>1</sup>, Steven J. Gedde, MD<sup>7</sup>, Ying Han, MD, PhD<sup>1</sup>

<sup>1</sup>Department of Ophthalmology, University of California San Francisco, San Francisco, CA <sup>2</sup>The First Affiliated Hospital of Chongqing Medical University, Chongqing Key Laboratory of Ophthalmology and Chongqing Eye Institute, Chongqing, China <sup>3</sup>Department of Ophthalmology, Khon Kaen University, Khon Kaen, Thailand <sup>4</sup>Department of Clinical Epidemiology and Biostatistics, Children's Hospital of Chongqing Medical University, Chongqing, China <sup>5</sup>Center for Preventive Ophthalmology and Biostatistics, University of Pennsylvania, Perelman School of Medicine, Philadelphia, PA <sup>6</sup>Department of Ophthalmology, Tongji Hospital, Tongji Medical College, Huazhong University of Science and Technology, Wuhan, China <sup>7</sup>Bascom Palmer Eye Institute, University of Miami Miller School of Medicine, Miami, FL

### Abstract

**Objective**—To compare the effects of Ahmed glaucoma valve (AGV) with sulcus versus anterior chamber (AC) tube placement on the corneal endothelial density and morphology over time.

**Design**—Non-randomized interventional study

**Participants**—This study included 106 eyes from 101 pseudophakic patients who had AGV tube placed in the AC (acAGV) and 105 eyes from 94 pseudophakic patients who had AGV tube insertion into the ciliary sulcus (sAGV).

**Methods**—All patients underwent preoperative specular microscopy, which was repeated postoperatively in 2019. The patients demographic information, glaucoma diagnoses, and basic ocular information were obtained on chart review. Anterior segment optical coherence tomography was conducted for sAGV patients to evaluate sulcus tube position. Gonioscopy was performed to document peripheral anterior synechiae (PAS). Linear mixed-effects models were used to compare

---

Corresponding author: Ying Han, MD PhD, University of California, San Francisco, San Francisco, California, Glaucoma Service, 10 Koret Way, San Francisco, CA 94131, Ying.Han@ucsf.edu.

\*These authors contributed equally

Conflict of interest: No conflicting relationship exists for any author.

This article contains additional online-only material. The following should appear online only: Supplemental Table 1, Supplemental Table 2.

**Publisher's Disclaimer:** This is a PDF file of an unedited manuscript that has been accepted for publication. As a service to our customers we are providing this early version of the manuscript. The manuscript will undergo copyediting, typesetting, and review of the resulting proof before it is published in its final form. Please note that during the production process errors may be discovered which could affect the content, and all legal disclaimers that apply to the journal pertain.

the different ocular and endothelial measurements between the two groups and to identify risk factors for endothelial cell density (ECD) loss over time.

**Main outcome measures**—Monthly change in corneal endothelial measurements, including ECD and coefficient of variation (CV), calculated as the difference between preoperative and postoperative measurements divided by the number of months from the time of surgery to postoperative specular microscopy.

**Results**—AcAGV and sAGV groups were comparable in all baseline characteristics except that acAGV group had longer follow up (37.6 vs. 20.1 months, respectively,  $P < 0.001$ ). Mean monthly loss in central ECD was significantly more in the acAGV (mean  $\pm$  standard deviation:  $29.3 \pm 29.7$  cells/mm<sup>2</sup>) than the sAGV group ( $15.3 \pm 20.7$  cells/mm<sup>2</sup>,  $P < 0.001$ ). Mean monthly change in CV was similar between the 2 groups ( $P = 0.28$ ). Multivariate analyses revealed that younger age and tube location in the AC were associated with faster central ECD loss ( $P = 0.02$ ,  $P < 0.0001$ , respectively). For patients with sAGV, while PAS was associated with faster central ECD loss ( $P = 0.002$ ), a more forward tube position tenting the iris was not ( $P > 0.05$ ).

**Conclusions**—Compared to anterior segment placement, ciliary sulcus tube implantation may be a preferred surgery approach to reduce endothelial cell loss in pseudophakic patients.

## Précis

Ahmed glaucoma valve implantation with sulcus tube demonstrated a slower rate of endothelial cell density loss compared to anterior chamber tube placement.

---

## Introduction

Glaucoma drainage device (GDD) surgery is being performed with increasing frequency as an alternative to trabeculectomy.<sup>1–3</sup> However, one of the major long-term complications of the GDD is progressive corneal endothelial cell loss leading to corneal decompensation.<sup>4–7</sup> The mechanism of endothelial damage is not clear, but has been proposed to involve mechanical damage from the tube's proximity to the corneal endothelium, high fluid flow through the tube producing damage to the endothelium proximal to tube entry, and/or postoperative inflammation leading to corneal endothelial damage.<sup>7,8</sup>

Surgical techniques have been modified to avoid corneal endothelial damage by positioning the tube in the anterior chamber parallel to the iris plane and away from the cornea, or by avoiding anterior chamber tube placement altogether. Pars plana tube placement has been advocated for patients with pre-existing corneal disease and when the traditional anterior chamber tube insertion is not possible. This approach has been shown to be an effective way to protect against significant corneal endothelial cell loss and improve corneal graft survival.<sup>9–14</sup> However, pars plana tube insertion requires a concurrent or antecedent vitrectomy procedure and is associated with potential posterior segment complications such as retinal tear or detachment or tube obstruction by the vitreous. As a result, this is not a commonly performed technique.

The ciliary sulcus is the space between the posterior iris face and a posterior chamber intraocular lens. After cataract extraction with posterior chamber intraocular lens implantation, sulcus placement of a tube offers the advantage of increased distance between

the cornea and the tube with the iris acting as a barrier between them, thereby potentially minimizing mechanical damage and excessive fluid conductance force. Ciliary sulcus tube placement does not require vitrectomy, thereby avoiding additional surgery and its associated complications. While previous studies have shown that sulcus tube placement is as effective as anterior chamber placement in lowering intraocular pressure (IOP),<sup>15–19</sup> this technique's effect on the corneal endothelium has not yet been well described in the literature. We hypothesized that GDD with sulcus tube placement is associated with a slower rate of corneal endothelial cell loss compared to the traditional anterior chamber tube location insertion. The aim of this study is to evaluate the effect of tube location on corneal endothelial cell density after Ahmed glaucoma valve (AGV) implantation.

## Methods

This is a non-randomized interventional study, conducted with approval from the University of California San Francisco (UCSF) Institutional Review Board, and in accordance with the tenets of the Declaration of Helsinki.

### Study population

The study included consecutive patients who underwent AGV implantation in the superotemporal quadrant either in the anterior chamber or in the ciliary sulcus within the UCSF Glaucoma Service from 2013 to 2018, as long as none of the exclusion criteria were present. Exclusion criteria included preexisting corneal disease, previous corneal transplant, more than one tube shunt in the same eye, phakic status except if the patient were to undergo a combined phacoemulsification with AGV implantation, and inability to complete tests relevant for this investigation.

Patient demographics and ocular characteristics were extracted from the medical record, including the patients' age, sex, glaucoma diagnosis, IOP and best-corrected visual acuity (BCVA) preoperatively, at the postoperative 1 year visit, and at the time of the study.

### Surgical techniques

All surgeries were performed by a single surgeon (YH). The primary surgeon's standard practice from 2013 to 2015 was to place the tube in the anterior chamber, and this practice was gradually changed to sulcus placement in 2016. Surgical techniques for AGV implantation have been previously described.<sup>20</sup> A fornix-based conjunctival flap was created in the superotemporal quadrant. After being primed, the AGV plate was anchored to the sclera between the superior rectus and lateral rectus muscles. For sulcus tube implantation, a bent 20g MVR was used to enter into the ciliary sulcus 3.5 mm from the limbus, followed by Provisc injection along the same path. After being trimmed to the appropriate length, the Ahmed tube was inserted along the created path, with the bevel facing away from the iris. For tube implantation in the anterior chamber, a bent 20g MVR was used to tunnel forward and enter into the anterior chamber 3 mm from the limbus, followed by Provisc injection. After trimming to the appropriate length, the drainage tube was inserted into the anterior chamber parallel to the iris plane, with the bevel facing away

from the iris. The tube was covered by an autologous scleral flap. The conjunctiva and Tenon's capsule were then secured at the limbus.

### Evaluation of the anterior segment

All eligible patients were identified by reviewing their medical records. As a part of the preoperative evaluation prior to AGV implantation in the surgeon's practice, all patients had previously undergone ultrasound pachymetry (DGH Pachette 4; DGH Technology Inc, Exton, PA) to measure central corneal thickness (CCT) and non-contact specular microscopy (CellChek Konan Specular Microscope X; Konan Medical Inc, Hyogo, Japan) for corneal endothelial evaluation within one month prior to AGV surgery. During their follow-up visit in 2019, these corneal measurements were repeated. Endothelial cell density (ECD) and coefficient of variation (CV) were obtained on 3 pre-specified corneal locations, including the central cornea, superotemporal (ST) and inferonasal (IN) quadrants. During the follow-up in 2019, anterior segment OCT (Visante OCT Anterior Segment Imaging, Carl Zeiss Medical Inc, Dublin, CA, USA) was also performed to evaluate the location, position and length of the tube. The presence or absence of peripheral anterior synechiae (PAS) was evaluated by standard gonioscopic examination using a 4-minor Zeiss gonioscopy (Volk Optical Inc, Mentor, Ohio).

### Statistical analysis

Scatterplot was performed to evaluate the relationship between ECD change (calculated by subtracting preoperative ECD from postoperative ECD) and time lapse since surgery (calculated as the number of months from AGV surgery to postoperative repeat ECD measurements) for acAGV and sAGV patients separately. To compensate for the difference in follow-up time between the two AGV groups, we calculated the mean monthly change, i.e. difference between pre- and postoperative endothelial measurements divided by the number of months since surgery, and compared these monthly changes between the two groups. As some subjects had both eyes eligible for the study, linear mixed-effects models were used to compare the different ocular and endothelial measurements between the two AGV groups while accounting for inter-eye correlation between two eyes of the same subject. Randomized block design analysis of variance was used to compare endothelial measurements in central, ST and IN locations of the same eye.

Univariate and multivariate linear mixed-effects models were used to assess risk factors for more monthly ECD loss. Factors with  $P < 0.2$  from univariate analyses were included in the multivariate regression analysis. A backward stepwise selection algorithm was employed until covariates had a  $P < 0.05$ . All statistical analyses were performed using SAS 9.4 software (Copyright © 2016 SAS Institute Inc. Cary, NC, USA). Because multiple comparisons were used to compare different specular microscopic parameters (ECD monthly change, percentage of ECD change, and CV) and different corneal locations (superotemporal, central and inferonasal) between the two groups, Bonferroni correction was performed to adjust for multiple comparisons. Adjusted P values were indicated in associated tables.

## Results

### Patient demographics and ocular characteristics

A total of 256 patients underwent AGV implantation with tube implanted superotemporally in the anterior chamber or sulcus by a single surgeon (YH) from 2013 to 2018. The inclusion/exclusion criteria were met by 195 patients, including 106 eyes from 101 patients who had acAGV, and 105 eyes from 94 patients who underwent sAGV. Amongst these patients, eight underwent combined phacoemulsification with acAGV, and 27 patients underwent combined phacoemulsification with sAGV.

With regards to preoperative characteristics, acAGV and sAGV patients had comparable age, gender distribution, diagnoses, preoperative BCVA, IOP, and baseline corneal characteristics including CCT, ECD, and CV ( $P>0.05$  for all, Table 1). Because the surgeon shifted surgical technique from default tube placement in the anterior chamber to placement in the sulcus in 2016, the mean months of follow up from AGV surgery to the time when postoperative specular microscopy was conducted (mean $\pm$ SD) was 37.6 $\pm$ 20.1 months for the acAGV group, significantly longer than that for the sAGV group (20.1 $\pm$ 17.2 months,  $P<0.001$ , Table 1).

With regards to the ocular characteristics postoperatively, 1 year after AGV implantation, acAGV group had a mean IOP (mean $\pm$ SD) of 12.5 $\pm$ 3.7 mmHg, similar to the sAGV group (11.6 $\pm$ 3.3,  $P=0.12$ ). At the time when postoperative specular microscopy was performed in 2019, the acAGV and sAGV groups also had similar postoperative mean IOP (12.3 $\pm$ 3.7 and 11.6 $\pm$ 3.4 mmHg, respectively,  $P=0.16$ ). The acAGV group had significantly worse postoperative LogMAR BCVA compared to the sAGV group 1 year after surgery (LogMAR 0.41 $\pm$ 0.57 vs. 0.23 $\pm$ 0.37,  $P=0.01$ ), and at the time of specular microscopy (LogMAR 0.39 $\pm$ 0.55 vs. 0.23 $\pm$ 0.36,  $P=0.01$ ). In addition, the mean postoperative CCT at the time of specular microscopy in the acAGV group was thicker than that in the sAGV (546 $\pm$ 56 vs. 536 $\pm$ 35  $\mu$ m), but these differences did not reach statistical significance ( $P=0.13$ ). Tube length was measured on the AS-OCT images for AC tubes only, and mean AC tube length was 2.85 $\pm$ 0.74 mm. Five eyes in the acAGV group and 4 eyes in the sAGV group developed tube-related postoperative complications, including tube occlusion, persistent inflammation longer than 3 months postoperatively and tube-related exposure/infection ( $P=0.74$ ).

### Comparison of postoperative corneal endothelial characteristics between the acAGV and sAGV groups

To adjust for the effect of different time lapse since surgery on corneal endothelial cells, we calculated and compared mean monthly changes. The assumption of a linear relationship between ECD changes and time lapse since surgery was based on the observation of a linear change in of ECD loss over time in both groups within the study period (Figure 1). Corneal endothelial measurements were compared between the two AGV groups for ECD and CV in the central, superotemporal, and inferonasal corneal locations. The mean monthly reduction in central ECD (mean $\pm$ SD) was 29.3 $\pm$ 29.7 cells/mm<sup>2</sup> in the acAGV group, which was significantly more loss than that of the sAGV group (15.3 $\pm$ 20.7 cells/mm<sup>2</sup>,  $P<0.0001$ , Table 2). The percentage central ECD loss (mean $\pm$ SD), which was obtained by monthly central

ECD change divided by preoperative ECD, was  $1.37 \pm 1.43\%$  per month in the acAGV group, and it was significantly higher than monthly loss seen in the sAGV group ( $0.72 \pm 0.91\%$  ECD loss per month,  $P < 0.0001$ , Table 2). The mean monthly change on central CV was not significantly different between the 2 groups in the central cornea ( $P = 0.28$ ). Similar trends of corneal endothelial changes including ECD and CV described above were also observed in the ST and IN locations of the cornea (Supplemental Table 1).

We then examined risk factors associated with worse corneal endothelial damage for all AGV patients. In univariate analyses, younger age ( $P = 0.01$ ) and tube location in the anterior chamber as compared to sulcus location ( $P < 0.0001$ ) were significantly associated with more monthly ECD decline in the central cornea (Table 3). In multivariate analyses, younger age ( $P = 0.02$ ) and tube location in the anterior chamber ( $P < 0.0001$ ) remained significant risk factors for more monthly ECD loss in the central cornea (Table 3). Tube location in the anterior chamber was also significantly associated with more monthly ECD loss in the ST and IN corneal locations, but age was not associated with ECD loss in these two non-central corneal locations (Supplemental Table 2). In addition, we examined whether age was a risk factor for worse percentage monthly ECD loss, and found that younger age was not associated with worse percentage ECD loss in central ( $P = 0.34$ ), ST ( $P = 0.48$ ) or IN cornea ( $P = 0.67$ ).

We also evaluated whether the length of AC tube was a significant risk factor for worse endothelial damage in the acAGV group. AC tube length was not significantly associated with more monthly ECD loss in central ( $P = 0.73$ , Table 3), ST ( $P = 0.12$ ) and IN cornea ( $P = 0.38$ , Supplemental Table 2).

### Postoperative corneal endothelial characteristics in patients with sulcus tube

We studied the effects of sulcus tube position on postoperative corneal endothelium in patients with sAGV. We first compared corneal endothelial parameters in 3 corneal locations in the sAGV group. The mean monthly decrease in central ECD (mean  $\pm$  SD) was  $15.3 \pm 20.7$  cells/ $\text{mm}^2$ , significantly lower than decrease in the ST location ( $20.1 \pm 24.6$ ,  $P = 0.005$ ) but not significantly different from ECD decrease in the IN location ( $17.9 \pm 20.2$ ,  $P = 0.12$ , Table 4). The mean monthly changes of CV showed no significant difference whether it was measured in the central, ST or IN cornea (overall  $P > 0.05$  for all, Table 4).

Every sAGV patient underwent AS-OCT in addition to routine slit lamp examination to evaluate the position of the sulcus tube. An example of a sulcus tube in the ideal location is shown in Figure 2A. In the sAGV group, 38 patients were found to have local shallowing of the anterior chamber on AS-OCT caused by the sulcus tube pushing the iris towards the corneal endothelium (an example is shown in Figure 2B). However, when comparing the corneas of patients with sAGV patients without tenting of the iris, these endothelial measurements were not significantly different, including corneal ECD, CV in central, ST and IN cornea (Table 5).

Finally, we explored whether PAS affected sulcus tube position and the corneal endothelium in patients with sAGV. There were 10 eyes that were found to have PAS in more than 3 clock hours on gonioscopic examination. Amongst them, 6 eyes had uveitic glaucoma, 2

eyes from the same patient had primary angle closure glaucoma, 1 eye had neovascular glaucoma, and 1 eye had traumatic glaucoma (an example of PAS on AS-OCT is shown in Figure 2C). When comparing these patients with sAGV patients who did not have PAS, the presence of PAS was significantly associated with more monthly ECD reduction in the central ( $P=0.002$ ) and IN cornea ( $P=0.0002$ ), but did not reach statistical significance in the ST cornea ( $P=0.04$ ). The presence or absence of PAS did not seem to have any effect on the mean monthly change of CV (Table 6).

## Discussion

This study aims to directly compare postoperative corneal endothelial changes between the sulcus and anterior chamber tube locations after AGV, and to examine risk factors for corneal endothelial cell loss after the tube shunt surgery.

We found that sulcus AGV patients experienced significantly slower rate of ECD loss in the central, ST and IN cornea compared to the acAGV patients. This supports the hypothesis that sulcus tube placement is protective against corneal endothelial cell loss over time. There is very limited data describing the pattern of ECD loss after sAGV to compare with the results of the current study. On the other hand, a previous study that investigated ECD loss after phacoemulsification in patients with primary open angle glaucoma reported a monthly ECD loss of about 10 cells/mm<sup>2</sup> (extrapolated from published data)<sup>21</sup>, which is more comparable with the monthly ECD loss observed in the sAGV group (15.3 cells/mm<sup>2</sup>) as opposed to that in the acAGV group (29.3 cells/mm<sup>2</sup>). Future investigations are needed to directly compare the pattern of ECD loss after sAGV with cataract surgery. However, the results in the current investigation suggest that with regards to cornea endothelium preservation, sulcus placement might be the preferred approach for AGV implantation compared to anterior chamber placement in patients with moderate to severe glaucoma.

In the acAGV group, we found that mean central ECD decreased by  $35.5\pm 23.4\%$  over the course of an average of 37.6 months. Kim et al. reported a 10.5% decrease in central ECD 12 months after acAGV implantation;<sup>8</sup> Lee et al. reported corneal ECD loss rates after acAGV surgery of 15.3% and 18.6% at 12 and 24 months, respectively.<sup>22</sup> The yearly ECD loss is largely consistent with Kim's and Lee's reports. The observational period in our study was substantially longer compared to the other two studies, and this may explain the different results. An AGV tube in the anterior chamber presents a constant source of endothelial trauma; the longer time the tube is present in the AC, the more endothelial change it might cause.

Previously, a biexponential decay of ECD loss over time was observed after cataract surgery and penetrating keratoplasty.<sup>23</sup> However, ECD loss pattern after tube shunt surgery is not well understood. In our study, within the follow up periods in each group, we observed a grossly linear relationship of ECD loss over time in both acAGV and sAGV patients (Figure 1). Unlike cataract surgery and penetrating keratoplasty, damage to the endothelium during AGV surgery is limited because there is usually minimal surgical manipulation in the anterior chamber; therefore, we observed that there was no dramatic ECD loss immediately after surgery as shown in the biexponential decay model. Even though there is less



immediate postoperative corneal changes, after GDD implantation, the aqueous humor protein concentration have been observed to increase tenfold,<sup>24</sup> including some proteins that are known to play a role in oxidative stress, apoptosis, and inflammation.<sup>25</sup> These more chronic and persistent changes are likely responsible for ongoing corneal endothelial damage in the long term. Hence, we observed a steady decline in ECD over time after surgery in both groups, and in order to compensate for the different follow-up durations between the two groups, we used monthly ECD loss to assess the rate of ECD change over time and to directly compare the two AGV groups.

Younger age and tube location in the AC were both significant risk factors for more monthly central ECD loss on the multivariate mixed linear regression analyses. Age has not been previously reported to be a significant risk factor for ECD loss after GDD implantation. It is reported that ECD declines by about 0.6% per year in normal adults subjects, while the annual percentage ECD decline in pediatric patients younger than 18 years old was higher<sup>27</sup>. Indeed, when we examined whether age was a risk factor for percentage monthly ECD loss, we found that age was not associated with more or less percentage monthly ECD loss. This supports our hypothesis that the effect of age on monthly ECD loss in our patient population was a reflection of natural age-related differential in ECD loss rate over time. Younger patients had more cells to lose, but were not more likely to lose a higher proportion compared to older patients.

In the sAGV group, the monthly ECD loss was significantly higher in the ST corneal location, compared to the central and IN cornea. This regional difference correlates with the superotemporal location of the inserted sulcus tube in this study, and hence the area of insult and stress to the endothelial cells. This is consistent with the pattern of ECD loss in previous reports of AGV with anterior chamber tube placement.<sup>8,22</sup> This suggests that even though a sulcus tube may be associated with less trauma to the central corneal endothelial cells, it still induces corneal endothelial loss and corneal changes in the region closest to the tube. However, the clinical significance of preferential ECD loss at the superotemporal location on corneal clarity and vision outcome remains to be elucidated.

When the tube is placed in the sulcus, it is not uncommon for the tube to tent the iris depending on the trajectory of the inserted tube. Our study found that the tube position, whether being flat and away from the iris, or pushing the iris toward the cornea, did not seem to significantly affect the rate of ECD loss: ECD change in all 3 corneal areas and their respective endothelial morphology did not differ significantly. It appears that as long as the tube is located in the ciliary sulcus, the iris acts as an effective barrier to reduce ECD loss from tube-cornea proximity.

The presence of PAS in sAGV patients was associated with significantly more ECD loss in central and IN corneal regions in our study. A similar finding was previously reported in a cross-sectional study that found PAS to be a significant risk factor for lower corneal ECD in AC tube patients.<sup>5</sup> PAS may directly harm the corneal endothelium by long-term mechanical iridocorneal contact, but its effects on the central endothelium suggests a more global impact on the corneal endothelium, likely related to chronic intraocular inflammation which may have contributed to PAS formation in the first place.<sup>28</sup>

Our study has several limitations. First of all, the follow-up time was significantly longer for the acAGV compared with the sAGV group. AcAGV patients underwent postoperative specular microscopy on average over 17 months later than sAGV patients. We have reported the rate of ECD loss (i.e. mean cell loss per month) to address the differences in follow-up time, based on the linear pattern of ECD loss over time observed in both groups within the follow-up period. However, beyond the current follow-up time-frame, the ECD loss pattern is not known. Future studies with long term longitudinal follow up and repeated postoperative specular microscopy at pre-specified time points should be conducted to more accurately examine the rate and pattern of ECD decline after AGV. Secondly, the study groups were not concurrent but consecutive, raising the possibility that reduced endothelial trauma in the more recently performed sulcus cases were due to greater surgeon experience and skill. However, there was substantial time overlap in the two groups, and the primary surgeon (YH) was highly experienced with 10 years of practice at the beginning of the study. Moreover, a change in practice to sulcus placement might generate a new learning curve, thereby, adversely affecting the outcomes. Yet sulcus placement demonstrated a more favorable outcome. Thirdly, some patients underwent combined phacoemulsification and AGV implantation that could lead to worse ECD loss at the time of combined procedures, and result in an overestimate of the degree of ECD loss compared to AGV surgery alone. Specifically, there were more combined cases in the sAGV group than the acAGV group. Even with a possible bias favoring the acAGV group, our results still demonstrated that sAGV as a group had significantly slower ECD loss. Furthermore, all patients in the study underwent AGV implantation, and the results may not be directly applicable to other implant types. However, similar rates of corneal endothelial cell loss have been reported with the AGV and Molteno implants after 24 months of follow up, <sup>29</sup> and all modern implants have a tube made of medical grade silicone with the same external and internal diameters. Lastly, all AGV procedures were performed by a single surgeon at one academic medical center, and this may affect the generalizability of results.

In summary, AGV implantation with sulcus tube placement was associated with a slower rate of ECD loss compared to tube placement in the anterior chamber. Younger age, in addition to tube location in the anterior chamber, was a significant risk factor for faster central ECD loss. For patients with sulcus tubes, the presence of PAS was also a significant risk factor for faster endothelial cell loss, but a more forward tube position tenting the iris was not. Ciliary sulcus tube implantation may be a preferred surgery approach in pseudophakic eyes to prevent corneal endothelial cell loss while maintaining adequate IOP control. In the future, a randomized clinical trial comparing GDD with tube placement in different locations is warranted to more definitively determine the preferred surgical approach.

## Supplementary Material

Refer to Web version on PubMed Central for supplementary material.

## Acknowledgments

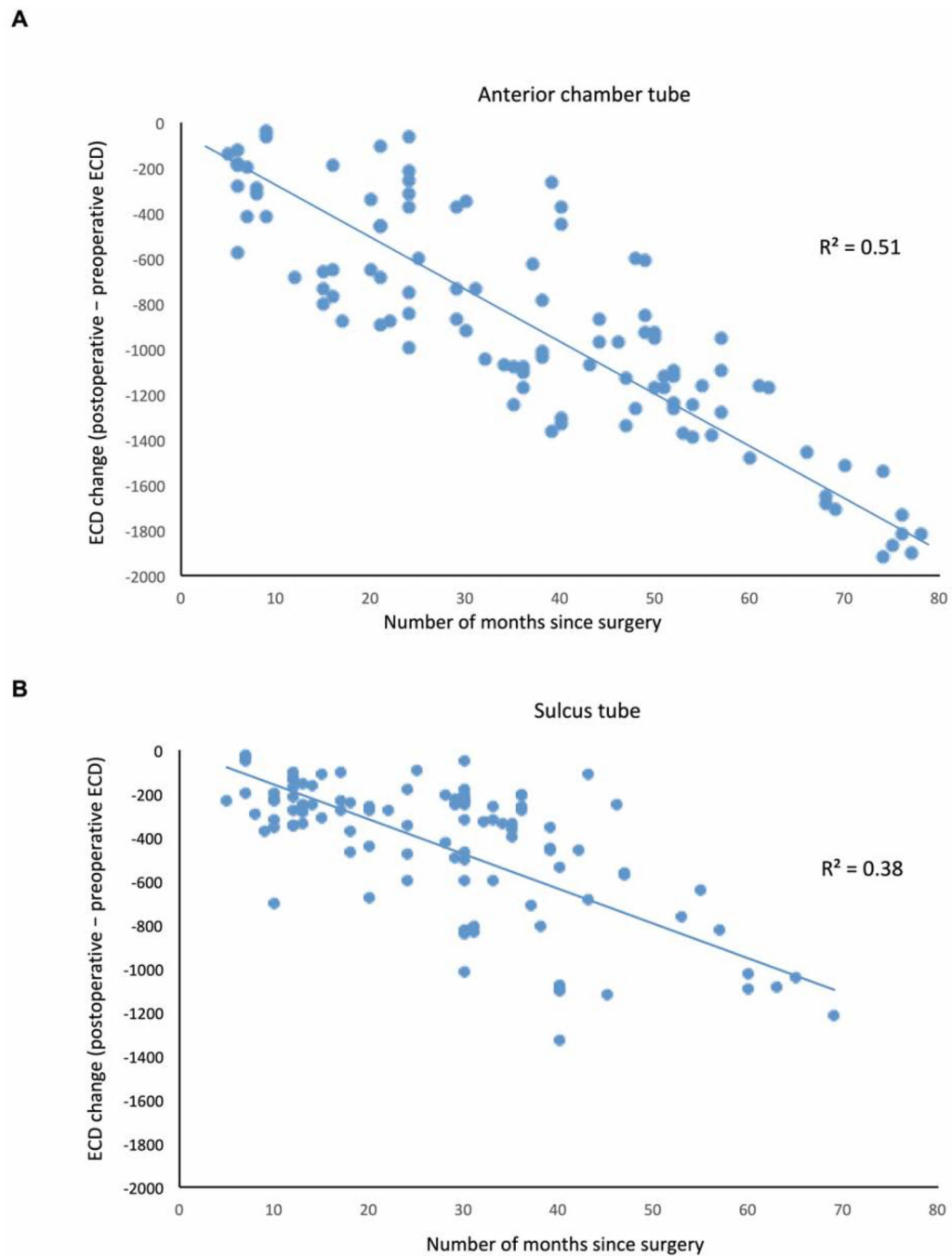
Financial support: National Eye Institute (NEIEY028747-01) funding to Ying Han. Supported by an unrestricted grant from Research to Prevent Blindness, New York, NY The study was supported by the National Key Clinical

Specialties Construction Program of China, the Natural Science Foundation Project of Chongqing (cstc2019jcyj-msxmX0398), the Joint Medical Research Project of Chongqing Health Commission and Science and Technology Bureau (2019MSXM003).

## References

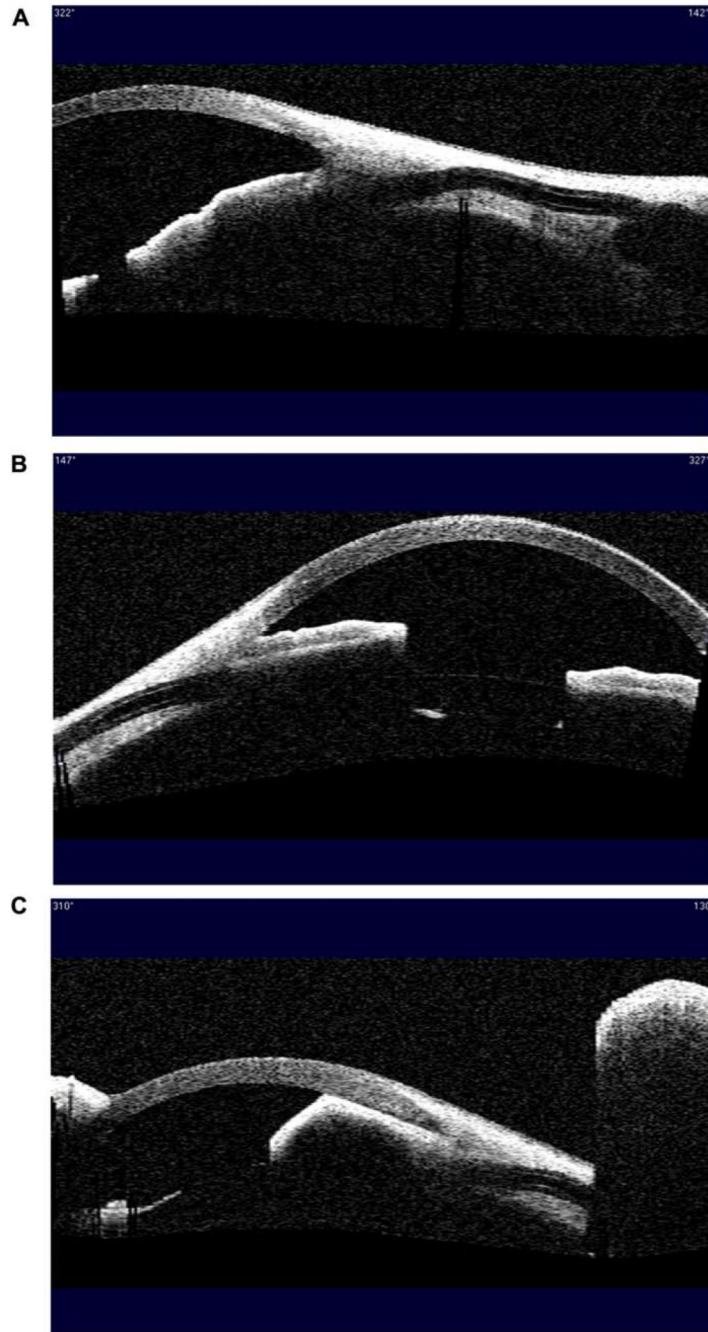
1. Arora KS, Robin AL, Corcoran KJ, Corcoran SL, Ramulu PY. Use of Various Glaucoma Surgeries and Procedures in Medicare Beneficiaries from 1994 to 2012. *Ophthalmology*. 2015;122(8):1615–1624. [PubMed: 26092196]
2. Gedde SJ, Schiffman JC, Feuer WJ, et al. Treatment outcomes in the Tube Versus Trabeculectomy (TVT) study after five years of follow-up. *Am J Ophthalmol*. 2012;153(5):789–803. e2. [PubMed: 22245458]
3. Vinod K, Gedde SJ, Feuer WJ, et al. Practice Preferences for Glaucoma Surgery: A Survey of the American Glaucoma Society. *J Glaucoma*. 2017;26(8):687–693. [PubMed: 28692597]
4. Minckler DS, Francis BA, Hodapp EA, et al. Aqueous shunts in glaucoma: a report by the American Academy of Ophthalmology. *Ophthalmology*. 2008;115(6):1089–1098. [PubMed: 18519069]
5. Hau S, Scott A, Bunce C, Barton K. Corneal endothelial morphology in eyes implanted with anterior chamber aqueous shunts. *Cornea*. 2011;30(1):50–55. [PubMed: 20861725]
6. Koo EB, Hou J, Han Y, Keenan JD, Stamper RL, Jeng BH. Effect of glaucoma tube shunt parameters on cornea endothelial cells in patients with Ahmed valve implants. *Cornea*. 2015;34(1):37–41. [PubMed: 25393097]
7. Koo EB, Hou J, Keenan JD, Stamper RL, Jeng BH, Han Y. Effects of Glaucoma Tube Surgery on Corneal Endothelial Cells: A Review. *Eye Contact Lens*. 2016;42(4):221–224. [PubMed: 26222096]
8. Kim CS, Yim JH, Lee EK, Lee NH. Changes in corneal endothelial cell density and morphology after Ahmed glaucoma valve implantation during the first year of follow up. *Clin Experiment Ophthalmol*. 2008;36(2):142–147. [PubMed: 18352870]
9. Arroyave CP, Scott IU, Fantes FE, Feuer WJ, Murray TG. Corneal graft survival and intraocular pressure control after penetrating keratoplasty and glaucoma drainage device implantation. *Ophthalmology*. 2001;108(11):1978–1985. [PubMed: 11713065]
10. Sidoti PA, Mosny AY, Ritterband DC, Seedor JA. Pars plana tube insertion of glaucoma drainage implants and penetrating keratoplasty in patients with coexisting glaucoma and corneal disease. *Ophthalmology*. 2001;108(6):1050–1058. [PubMed: 11382628]
11. Seo JW, Lee JY, Nam DH, Lee DY. Comparison of the changes in corneal endothelial cells after pars plana and anterior chamber ahmed valve implant. *J Ophthalmol*. 2015;2015:486832. [PubMed: 25694824]
12. Chihara E, Umemoto M, Tanito M. Preservation of corneal endothelium after pars plana tube insertion of the Ahmed glaucoma valve. *Jpn J Ophthalmol*. 2012;56(2):119–127. [PubMed: 22203463]
13. Qin VL, Kaleem M, Conti FF, et al. Long-term Clinical Outcomes of Pars Plana Versus Anterior Chamber Placement of Glaucoma Implant Tubes. *J Glaucoma*. 2018;27(5):440–444. [PubMed: 29521717]
14. Siedner MJ, Ng CK, Bassett IV, Katz IT, Bangsberg DR, Tsai AC. Trends in CD4 count at presentation to care and treatment initiation in sub-Saharan Africa, 2002–2013: a meta-analysis. *Clin Infect Dis Off Publ Infect Dis Soc Am*. 2015;60(7):1120–1127.
15. Tello C, Espana EM, Mora R, Dorairaj S, Liebmann JM, Ritch R. Baerveldt glaucoma implant insertion in the posterior chamber sulcus. *Br J Ophthalmol*. 2007;91(6):739–742. [PubMed: 17301121]
16. Weiner A, Cohn AD, Balasubramaniam M, Weiner AJ. Glaucoma tube shunt implantation through the ciliary sulcus in pseudophakic eyes with high risk of corneal decompensation. *J Glaucoma*. 2010;19(6):405–411. [PubMed: 19907341]
17. Prata TS, Mehta A, De Moraes CGV, Tello C, Liebmann J, Ritch R. Baerveldt glaucoma implant in the ciliary sulcus: midterm follow-up. *J Glaucoma*. 2010;19(1):15–18. [PubMed: 19373099]

18. Eslami Y, Mohammadi M, Fakhraie G, Zarei R, Moghimi S. Ahmed glaucoma valve implantation with tube insertion through the ciliary sulcus in pseudophakic/aphakic eyes. *J Glaucoma*. 2014;23(2):115–118. [PubMed: 22828010]
19. Bayer A, Önol M. Clinical outcomes of Ahmed glaucoma valve in anterior chamber versus ciliary sulcus. *Eye Lond Engl*. 2017;31(4):608–614.
20. Cui QN, Hsia YC, Lin SC, et al. Effect of mitomycin c and 5-fluorouracil adjuvant therapy on the outcomes of Ahmed glaucoma valve implantation. *Clin Experiment Ophthalmol*. 2017;45(2):128–134. [PubMed: 27490793]
21. Ianchulev T, Lane S, Masis M, et al. Corneal Endothelial Cell Density and Morphology After Phacoemulsification in Patients With Primary Open-Angle Glaucoma and Cataracts: 2-Year Results of a Randomized Multicenter Trial. *Cornea*. 2019;38(3):325–331. [PubMed: 30614901]
22. Lee E-K, Yun Y-J, Lee J-E, Yim J-H, Kim C-S. Changes in corneal endothelial cells after Ahmed glaucoma valve implantation: 2-year follow-up. *Am J Ophthalmol*. 2009;148(3):361–367. [PubMed: 19505676]
23. Armitage WJ, Dick AD, Bourne WM. Predicting endothelial cell loss and long-term corneal graft survival. *Invest Ophthalmol Vis Sci*. 2003;44(8):3326–3331. [PubMed: 12882777]
24. Rosenfeld C, Price MO, Lai X, Witzmann FA, Price FW. Distinctive and pervasive alterations in aqueous humor protein composition following different types of glaucoma surgery. *Mol Vis*. 2015;21:911–918. [PubMed: 26321865]
25. Anshu A, Price MO, Richardson MR, et al. Alterations in the aqueous humor proteome in patients with a glaucoma shunt device. *Mol Vis*. 2011;17:1891–1900. [PubMed: 21850163]
26. Kim KN, Lee SB, Lee YH, Lee JJ, Lim HB, Kim C. Changes in corneal endothelial cell density and the cumulative risk of corneal decompensation after Ahmed glaucoma valve implantation. *Br J Ophthalmol*. 2016;100(7):933–938. [PubMed: 26508781]
27. Bourne WM, Nelson LR, Hodge DO. Central corneal endothelial cell changes over a ten-year period. *Invest Ophthalmol Vis Sci*. 1997;38(3):779–782. [PubMed: 9071233]
28. Bigar F, Witmer R. Corneal endothelial changes in primary acute angle-closure glaucoma. *Ophthalmology*. 1982;89(6):596–599. [PubMed: 7122040]
29. Nassiri N, Nassiri N, Majdi-N M, et al. Corneal endothelial cell changes after Ahmed valve and Molteno glaucoma implants. *Ophthalmic Surg Lasers Imaging Off J Int Soc Imaging Eye*. 2011;42(5):394–399.



**Figure 1.**

Scatter-plot of endothelial cell density (ECD) loss over time after Ahmed glaucoma valve (AGV) with tube placement in the anterior chamber (A) versus sulcus (B). The horizontal axis shows the time elapse from AGV surgery to postoperative repeat ECD measurement (months). The vertical axis shows ECD change calculated by subtracting preoperative from postoperative ECD, i.e. postoperative ECD - preoperative ECD (cells/cm<sup>2</sup>). The line of best fit describes a linear relationship between ECD loss and time interval in both AGV groups, with  $r^2$  describing how well it fits the data.



**Figure 2.** Evaluation of tube position and peripheral anterior synechiae (PAS) using anterior segment optical coherence tomography. A. An example of a well positioned sulcus tube. B. An example of sulcus tube pushing the iris forward toward the cornea. C. An example of significant peripheral anterior synechiae in a patient with traumatic glaucoma.

Table 1.

## Baseline patient characteristics

	acAGV (N=106 eyes 101 patients)	sAGV (N=105 eyes, 94 patients)	P value
Age in years, mean (SD)	64.5 (15.4)	66.4 (15.4)	0.37
Male, N (%)	46 (45.5%)	42 (44.7%)	0.62
Months since surgery (SD) <sup>a</sup>	37.6 (20.1)	20.1 (17.2)	<0.001
<b>Glaucoma diagnoses</b>			
POAG, N (%)	77 (72.6%)	66 (62.9%)	0.21
Uveitic glaucoma, N (%)	17 (16.0%)	17 (16.2%)	
PACG, N (%)	3 (2.8%)	9 (8.6%)	
Other, N (%) <sup>b</sup>	9 (8.5%)	13 (12.4%)	
<b>Preoperative ocular characteristics</b>			
Preoperative IOP, mmHg (SD)	23.4 (7.49)	23.3 (7.98)	0.96
Preoperative BCVA in LogMAR (SD)	0.37 (0.49)	0.31 (0.38)	0.36
Preoperative CCT, pm (SD)	540.7 (46.6)	539.1 (36.8)	0.10
Preoperative ECD, cells/mm <sup>2</sup> (SD)	2190 (508)	2251 (570)	0.59
Preoperative CV (SD)	28.5 (7.13)	27.0 (5.88)	0.05

acAGV = Ahmed glaucoma valve implant with tube placed in the anterior chamber; BCVA = best corrected visual acuity; CCT = central corneal thickness; CV = coefficient of variation; ECD = endothelial cell density; IOP = intraocular pressure; PACG = primary angle closure glaucoma; POAG = primary open angle glaucoma; sAGV = Ahmed glaucoma valve implant with tube placed in the sulcus; SD = standard deviation.

<sup>a</sup>Months since surgery indicate the number of months from the time of AGV surgery to repeat postoperative specular microscopy

<sup>b</sup>Other glaucoma diagnoses included steroid induced glaucoma, neovascular glaucoma, mixed-mechanism glaucoma, pigmentary glaucoma, aphakic glaucoma, pseudoexfoliative glaucoma and normal tension glaucoma.

Comparison of monthly change in each of the central corneal endothelial measurements between treatment groups

**Table 2.**

Measurements	Mean monthly change (SD)		P value <sup>b</sup>
	acAGV (N=106 eyes)	sAGV (N=105 eyes)	
ECD, cells/mm <sup>2</sup>	-29.3 (29.7)	-15.3 (20.7)	<0.0001
%ECD change <sup>a</sup>	-1.37 (1.43)	-0.72 (0.91)	<0.0001
CV	0.08 (0.58)	0.36 (1.63)	0.28

acAGV = Ahmed glaucoma valve implant with tube placed in the anterior chamber; CV = coefficient of variation; ECD = endothelial cell density; sAGV = Ahmed glaucoma valve implant with tube placed in the sulcus; SD = standard deviation

<sup>a</sup>%ECD change was calculated by monthly ECD change (postoperative – preoperative ECD) divided by preoperative ECD.

<sup>b</sup>Bonferroni correction was applied to adjust for multiple comparisons. P<0.017 is considered statistically significant.



Univariate analysis and multivariate analysis of risk factors for more monthly central endothelial cell density change<sup>a</sup> after AGV (N=211 eyes, 195 patients)

**Table 3.**

	Univariate analysis			Multivariate analysis		
	Estimate	Standard error	P value	Estimate	Standard error	P value
Age (per year increase)	0.30	0.12	0.01	0.27	0.12	0.02
Female	0.80	3.60	0.82			
Preoperative central ECD	-0.006	0.003	0.08			
Postoperative IOP	0.61	0.52	0.24			
Presence of PI	-2.59	3.63	0.48			
AC tube length <sup>b</sup>	1.48	4.25	0.73			
Sulcus tube location (vs. AC)	14.9	3.28	<0.0001	14.3	3.27	<0.0001

AC = anterior chamber; AGV = Ahmed glaucoma valve; ECD = endothelial cell density; PI = peripheral iridotomy.

<sup>a</sup> monthly endothelial cell density (ECD) change = (postoperative – preoperative ECD)/months since surgery

<sup>b</sup> Univariate analysis conducted only for acAGV group

**Table 4.** Comparison of corneal endothelial measurements at different corneal locations in the sulcus group (N=105)

Measurements	Mean monthly change (SD)				P values		
	Central	ST	IN	Overall	Central vs. ST *	Central vs. IN *	ST vs. IN *
ECD, cells/mm <sup>2</sup>	-15.3 (20.7)	-20.1 (24.6)	-17.9 (20.2)	0.02	0.005	0.12	0.20
CV	0.36 (1.63)	0.10 (1.79)	0.41 (1.50)	0.35	0.25	0.85	0.18

AVE = average cell area; CV = coefficient of variation; ECD = endothelial cell density; IN = inferonasal; SD = standard deviation; ST = superotemporal.

\* Pairwise comparisons obtained with Bonferroni correction. P<0.025 is considered statistically significant.

Comparison of mean monthly change in corneal endothelial measurements in sAGV based on sulcus tube and iris relationship

**Table 5.**

Measurements	Mean monthly change (SD)		P value <sup>a</sup>
	Sulcus tube flat or away from iris (n = 67)	Sulcus tube pushing iris toward cornea (n = 38)	
<b>Central cornea</b>			
ECD, cells/mm <sup>2</sup>	-17.7 (23.8)	-10.9 (12.9)	0.33
CV	0.46 (1.98)	0.19 (0.68)	0.74
<b>ST cornea</b>			
ECD, cells/mm <sup>2</sup>	-21.4 (26.3)	-17.7 (21.2)	0.88
CV	0.07 (2.02)	0.16 (1.32)	0.96
<b>IN cornea</b>			
ECD, cells/mm <sup>2</sup>	-21.0 (22.2)	-12.4(14.9)	0.17
CV	0.45 (1.70)	0.33 (1.05)	0.37

CV = coefficient of variation; ECD = endothelial cell density; sAGV = Ahmed glaucoma valve with sulcus tube; SD = standard deviation

<sup>a</sup> Bonferroni correction was applied to adjust for multiple comparisons. P<0.0083 is considered statistically significant.

Comparison of mean monthly change in corneal endothelial measurements between eyes with versus without peripheral anterior synechiae in sAVG

**Table 6.**

Measurements	Mean monthly change (SD)		P value <sup>a</sup>
	No PAS (N = 95)	PAS (N = 10)	
<b>Central cornea</b>			
ECD, cells/mm <sup>2</sup>	-13.3 (18.9)	-33.8 (28.5)	0.002
CV	0.39 (1.71)	0.09 (0.47)	0.82
<b>ST cornea</b>			
ECD, cells/mm <sup>2</sup>	-18.3 (22.7)	-36.7 (35.1)	0.04
CV	0.07 (1.87)	0.38 (0.82)	0.47
<b>IN cornea</b>			
ECD, cells/mm <sup>2</sup>	-15.7 (17.6)	-38.5 (31.0)	0.0002
CV	0.43 (1.55)	0.20 (0.83)	0.82

CV = coefficient of variation; ECD = endothelial cell density; PAS = peripheral anterior synechiae; sAVG = Ahmed glaucoma valve with sulcus tube; SD = standard deviation

<sup>a</sup> Bonferroni correction was applied to adjust for multiple comparisons. P < 0.0083 is considered statistically significant.