

UC Davis

UC Davis Previously Published Works

Title

Initial clinical use of a novel mechanical thrombectomy device, XCOIL™, in hemodialysis graft and fistula de clot procedures.

Permalink

<https://escholarship.org/uc/item/0kh1h69q>

Journal

Diagnostic and Interventional Radiology, 22(3)

Authors

Monsky, Wayne
Latchaw, Richard

Publication Date

2016

DOI

10.5152/dir.2015.15158

Peer reviewed

Initial clinical use of a novel mechanical thrombectomy device, XCOIL™, in hemodialysis graft and fistula de clot procedures

Wayne L. Monsky
Richard E. Latchaw

PURPOSE

We aimed to evaluate the safety and effectiveness of a novel catheter-based mechanical thrombectomy device, XCOIL™, as a first line therapy to restore patency of thrombosed dialysis grafts and fistulae.

METHODS

In 2010, 18 consecutive/sequential patients (11 male, 7 female; median age, 52 years; age range, 32–69 years) with occluded arteriovenous grafts (n=15) or fistulae (n=3) were treated with XCOIL™ (NexGen Medical Systems Inc.) without adjunctive thrombolytic drugs. XCOIL™ was advanced distal to the thrombus within the outflow vein as well as distal to the arterial inflow platelet thrombin plug, using a 4F angiographic catheter. The percentage of thrombus cleared, primary patency, procedure time, and XCOIL™ performance were documented.

RESULTS

Thrombosis occurred 1–30 days prior to the procedure. Thrombosed segments of graft/fistula measured 10–50 cm. Pre- and postprocedure angiography demonstrated that in 15 of 18 cases (83%) XCOIL™ removed 80%–100% of the venous outflow thrombus. In 11 of 14 cases (79%), the platelet thrombin plug was also removed. Thrombectomy procedure time averaged 8 min, with one to three passes with the XCOIL™ required. No evidence of distal embolization or graft/vessel injury was found on angiography following clot removal. In four cases in whom patency was not restored with XCOIL™, subsequent use of other clot removal devices also failed to restore patency. In one case with severe venous stenosis, the device failed to deploy and the thrombus was not captured. No intraprocedural complications related to XCOIL™ use occurred.

CONCLUSION

XCOIL™ is an effective and safe first-line therapy option for the treatment of thrombosed hemodialysis grafts/fistulae. Rapid removal of intact thrombus and platelet thrombin plug can be achieved without adjunctive thrombolytics.

With over 18 000 patients undergoing intermittent hemodialysis treatment in more than 350 dialysis centers, Turkey today has the fifth largest chronic hemodialysis patient population among European countries (1). In the United States, there are approximately 370 000 hemodialysis patients (2). Frequent thrombosis is well described in both dialysis arteriovenous (AV) grafts and fistulae (2). One and two-year patency rates for dialysis grafts have been reported to be 60%–80% and 50%–70%, respectively (2). This represents a major source of hospital admissions, increasing hospital costs and patient morbidity in most countries.

Thrombosed fistulae and grafts can be declotted using pharmacomechanical techniques combining thrombolysis and thrombectomy, or by mechanical thrombectomy alone (3, 4). The medical literature suggests that technical success rates for thrombolysis of thrombosed fistulae ranges from 76%–96% (5–7). However, all declotting procedures carry a risk of distal arterial embolization and hemorrhagic complications (4). Large randomized controlled clinical trials evaluating thrombolysis and thrombectomy procedures for thrombosed dialysis grafts show a 3%–18% occurrence rate of adverse events (8–10).

XCOIL™ (NexGen Medical Systems Inc.) is a new FDA-approved, catheter-based mechanical thrombectomy device (11) (Fig. 1). Preclinical animal studies have shown that XCOIL™ enables safe and effective percutaneous thrombectomy of soft acute and firm chronic thrombus in arteries and veins without the use of thrombolytics (11).

From the Department of Radiology (W.L.M. ✉ wmonsky@u.washington.edu), University of Washington Medical Center, Seattle, WA, USA; the Department of Radiology (W.L.M., R.E.L.), University of California Davis Medical Center, Sacramento, CA, USA.

Received 5 June 2015; revision requested 3 July 2015; last revision received 17 October 2015; accepted 20 October 2015.

Published online 24 March 2016.
DOI 10.5152/dir.2015.15158

The aim of this clinical study was to preliminarily evaluate the safety and effectiveness of XCOIL™ mechanical thrombectomy for the endovascular treatment of thrombosed AV grafts and fistulae.

Methods

Patients

This prospective study involved consecutive subject enrollment and was performed with informed consent and following guidelines for experimental investigation in human subjects required by the Institutional Review Board (IRB)/Ethics Committee at The University of California Davis Medical Center. All data were collected in accordance with HIPAA regulations. The study population consisted of 18 consecutive patients (11 men and 7 women; median age, 52 years; age range, 32–69 years) with three AV fistulae (two radiocephalic, one brachiocephalic), and 15 grafts (nine brachiocephalic, six brachiocephalic) occlusions, referred to Interventional Radiology at The University of California Davis Medical Center for de clot procedures. During the time of the study, sequential patients referred for de clot procedures were considered for inclusion in the study. To be included in the study the patient had to agree to not receive usual tissue plasminogen activator (tPA) (Altoplase, Genentech Inc.). Our institution's usual clinical inclusion and exclusion criteria for de clot procedures were followed. Exclusion criteria included patients with histories suggesting occlusions >30 days, potassium >6 mEq/L, creation of the graft or fistula within one month of the referral, immature or never used fistula, most recent de clot procedure within two weeks of the referral, coagulopathy/anticoagulation, infection, and clinically significant cardiopulmonary compromise such as pulmonary hypertension.

Main points

- The XCOIL™ system readily cleared thrombus from both the venous and the arterial sides of the dialysis graft/fistula, including soft thrombus and the firm platelet fibrin plug, without the addition of thrombolytics.
- The system is designed to remove clot, not compress it against the vessel wall nor create a channel within it.
- This thrombectomy approach aims to decrease the incidence of embolization of clot to the lungs or adjacent artery during dialysis graft/fistula de clot procedures.

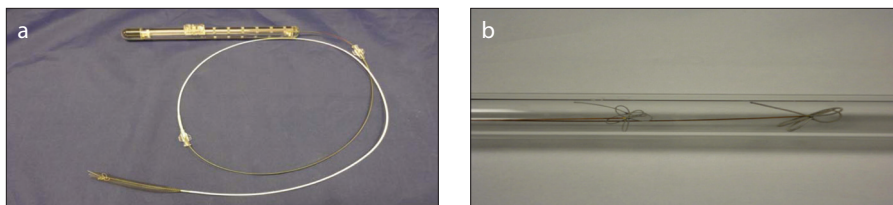


Figure 1. a, b. Photograph (a) of fully assembled XCOIL™ mechanical thrombectomy device, including actuated loops, within the intravascular basket (Encapsulator™, NexGen Medical Systems Inc.). Bench-top demonstration of two different sized XCOIL™ loops deployed within transparent tubing (b). The smaller (11 mm) loops shown on the left side have been developed for clot removal from popliteal-femoral veins, whereas the larger ones (16 mm) shown on the right side can be used for large clot retraction from central veins such as the subclavian, brachiocephalic, or iliofemoral veins.

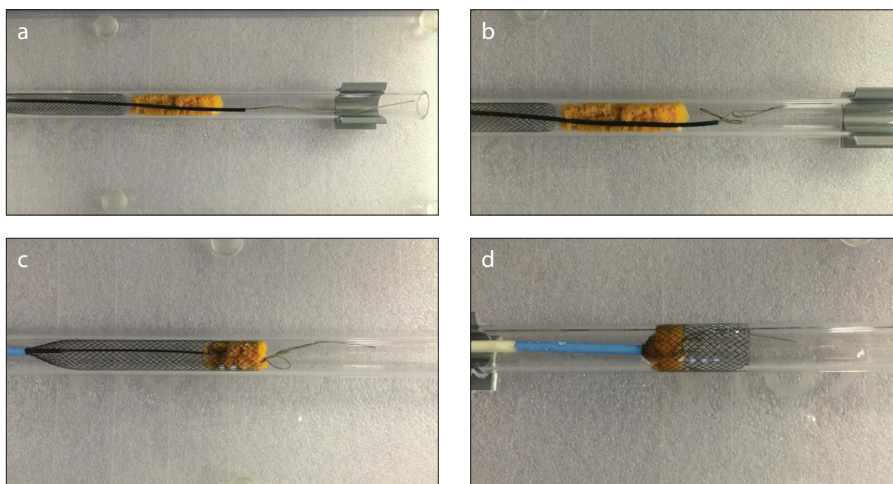


Figure 2. a–d. Bench top demonstration of XCOIL™ removal of clot model. Panel (a) shows 4F catheter advanced over the wire distal to clot. The XCOIL™ is inserted into a 4F angiographic catheter positioned distal to the clot, using conventional over-the-wire coaxial angiographic technique. In panel (b), the XCOIL™ loops are formed distal to the clot. In panel (c), loops are sequentially released from the catheter around and through the mid-portion of the clot and then the proximal portion of the clot. The catheter is progressively pulled back to unsheath and actuate more loops. The core wire is retracted to tighten the loop structure around the clot model. In panel (d), the now fully encapsulated clot is pulled to the intravascular basket (Encapsulator) or sheath and removed through the sheath.

Procedures

All procedures were performed by an interventional radiologist with eight years of experience. Patients underwent XCOIL™ thrombectomy without additional thrombolytics. Intravenous heparin was administered to keep activated clotting time (ACT) above 100. Crossing 7F short sheaths (Cook Medical) were placed and directed toward the arterial inflow and venous outflow. Initial ultrasonography (IU22, Philips) and pull back angiogram (Artis, Siemens Medical) with Visipaque (Iodixanol, Amersham Health) from the patent central veins to the thrombus within the outflow vein was performed to estimate the length of thrombus occupying the graft/fistula, outflow vein, and central veins, as well as the anatomy of the fistula/graft and anastomoses. A 4F angiographic catheter (NexGen Medical Systems Inc.) was advanced over a 0.35-inch guidewire (Bentson, Boston Scientific)

along the venous outflow to a patent venous segment distal to the thrombus, as confirmed with contrast injection. XCOIL™ was advanced through the catheter and unsheathed in the patent outflow vein distal to the clot, with additional loops placed around the body of the clot and proximal to it. Retracting the XCOIL™ pull-wire tightened the loops around the clot. The clot was then withdrawn using the XCOIL™ and pulled out of the sheath, as described in previous preclinical studies (11) (Fig. 2). The platelet-thrombin plug was removed with the XCOIL™ in similar fashion via the 4F catheter advanced into the adjacent inflow artery just distal to the platelet thrombin plug. Following clot removal, the inflow artery and its branches, fistula/graft, and central veins were evaluated angiographically (Fig. 3). Patency of the fistula/graft was evaluated using reference standards/index tests in accordance with the reporting standards

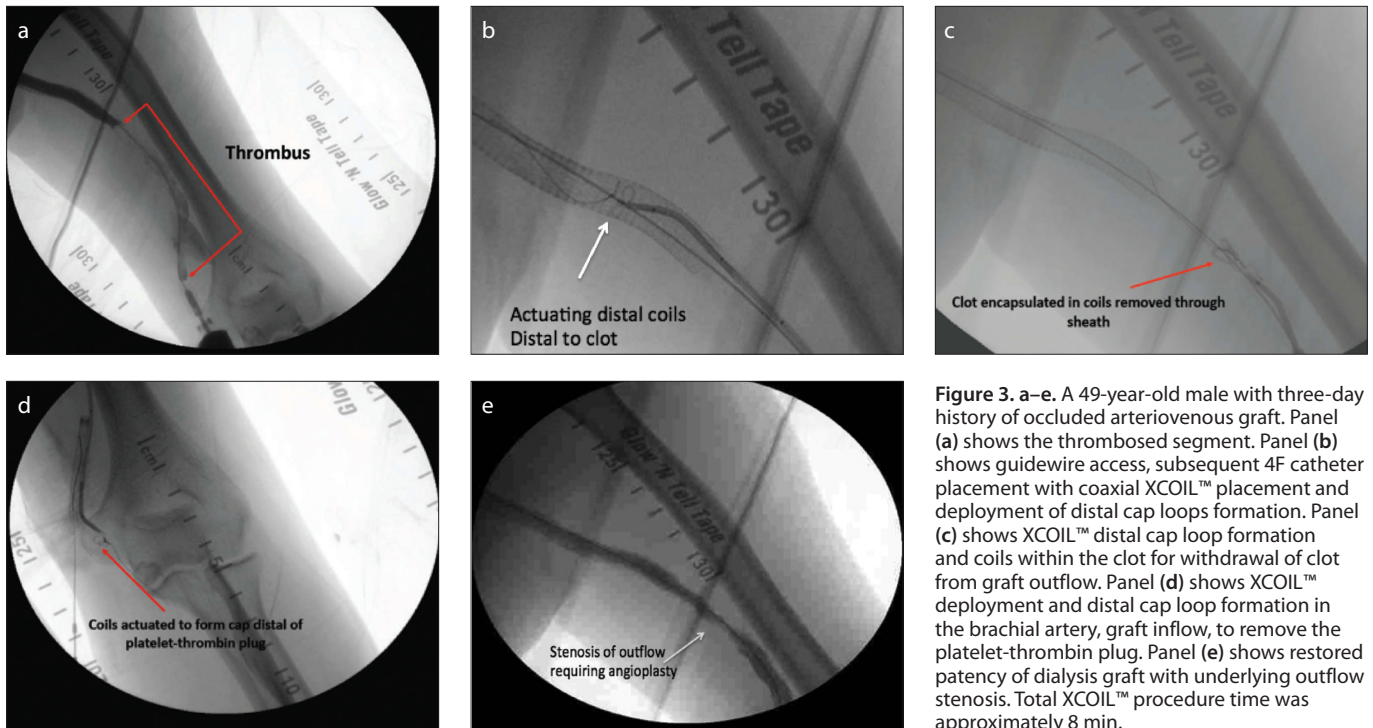


Figure 3. a–e. A 49-year-old male with three-day history of occluded arteriovenous graft. Panel (a) shows the thrombosed segment. Panel (b) shows guidewire access, subsequent 4F catheter placement with coaxial XCOIL™ placement and deployment of distal cap loops formation. Panel (c) shows XCOIL™ distal cap loop formation and coils within the clot for withdrawal of clot from graft outflow. Panel (d) shows XCOIL™ deployment and distal cap loop formation in the brachial artery, graft inflow, to remove the platelet-thrombin plug. Panel (e) shows restored patency of dialysis graft with underlying outflow stenosis. Total XCOIL™ procedure time was approximately 8 min.

of the Society of Interventional Radiology (SIR) (12).

Data analysis

All data were prospectively collected by the operator (WLM) and a research coordinator. This operator also interpreted the data. To determine the percentage of thrombus removed, the initial length of thrombosed clot-containing vessel was estimated on ultrasonography based on the location of the patent outflow vessel. Following each sweep with the device, angiography was performed to determine the length of thrombus remaining within the vessel.

Details of the XCOIL™ procedure, including adjunctive procedures and procedure time, were documented. Evaluation of the ease of use, navigability, completeness of loop deployment, ease of clot engagement/retraction/removal, and XCOIL™ device integrity were related to a 3-point Likert scale and SIR reporting standards (12) with scores corresponding to “did not meet, met, or exceeded expectations.” The technical success of thrombectomy was defined by restoration of a palpable thrill. Clinical success was defined as subsequent resumption of at least one successful hemodialysis session. Complications were categorized as major and minor per published SIR guidelines (12). Major complications were those resulting in hospital admission, unplanned

increase in the level of care, prolonged hospitalization, permanent adverse sequelae, or death. Minor complications were defined as those resulting in no sequelae, nominal therapy, or short hospital stay for observation.

Results

Fistulae and grafts were occluded for 1–30 days prior to the declot procedure with XCOIL™ (Table 1). Based on initial angiography and ultrasonography, the thrombosed vessels had a median length of 20 cm (10–50 cm) and a mean diameter of 7.3 ± 2.7 mm. Thrombus extended from the arterial anastomosis, where there was a platelet-thrombin plug, well into the venous outflow. In one case, thrombus extended through the left brachiocephalic vein into the superior vena cava. Eight patients had moderate-to-severe stenosis at and/or adjacent to the arterial anastomosis. Ten patients had moderate-to-severe venous outflow stenoses, which in six cases included stenoses within previously placed venous outflow stents. One patient had a moderate subclavian/brachiocephalic venous stenosis.

XCOIL™ cleared clot and restored vessel patency in 1–3 sweeps with a mean total thrombectomy time of 8 min (range, 5–18 min). In 15 of 18 cases (83%), XCOIL™ removed 80%–100% of the venous outflow thrombus. The firm platelet-thrombin plug

was removed from the AV graft anastomosis in 11 of the 14 cases (79%) in which XCOIL™ was used to attempt to sweep the arterial graft anastomosis. In one case, in which a large amount of thrombus extended from the left subclavian, axillary, and brachiocephalic veins into the superior vena cava, 80% of the clot was cleared with XCOIL™. There were four cases in which clot could not be removed with XCOIL™, and subsequent use of the AngioJet (AngioJet AVX, Boston Scientific) also failed to clear the thrombus. In one case, the Trerotola device (Teleflex) was used to clear additional thrombus between the two sheaths. Angioplasty (Conquest, Bard) of stenoses was performed in all cases, and in one case stenting was required for refractory stenosis. All patients who were restored had a palpable thrill at the end of the procedure and underwent successful dialysis. Following XCOIL™ thrombectomy, the median primary patency rate was 15 months (1–24 months). In 14 cases, XCOIL™ alone was used to restore venous outflow and arterial inflow, clearing the arteriovenous anastomotic platelet thrombin plug. The overall technical success rate of XCOIL™ was 72% (13 of 18 cases).

During clot removal, thrombus was typically observed to be adherent within the XCOIL™ and the vascular access sheath. Clot was purged from the sheath by removing the sheath over a wire, flushing it outside the patient, and then advancing the sheath

Table. XCOIL™ data in individual patients

Patient no.	Clinical history	XCOIL sweeps	Device time	Percent clot removed
1	Forearm loop graft 7-day-old clot	1 venous 1 arterial	5 min	100% venous 60% arterial
2	Forearm loop graft 3-day-old clot	2 venous	10 min	40% venous
3	Forearm loop graft 3-day-old clot	2 venous	10 min	90% venous
4	Forearm straight graft 7-day-old clot	2 venous 1 arterial	10 min	100% venous 100% arterial
5	Forearm straight graft 3-day-old clot	3 venous 1 arterial	10 min	80% venous 100% arterial
6	Forearm loop graft 30-day-old clot	2 venous 1 arterial	6 min	100% venous 100% arterial
7	Forearm loop graft 3-day-old clot	3 venous 2 arterial	9 min	70% venous 100% arterial
8	Brachial loop graft 3-day-old clot	3 venous	10 min	80% venous
9	Forearm straight graft 2-day-old clot	3 venous 2 arterial	10 min	100% venous 100% arterial
10	Brachio-brachial fistula 3-day-old clot	3 venous 1 arterial	18 min	90% venous 60% arterial
11	Forearm loop graft 3-day-old clot	3 venous 1 arterial	10 min	90% venous 60% arterial
12	Brachio-brachial graft 4-day-old clot	2 venous 2 arterial	10 min	90% venous 60% arterial
13	Brachiobasilic graft 2-day-old clot	2 venous 2 arterial	10 min	80% venous 80% arterial
14	Brachiobasilic graft 3-day-old clot	2 venous 1 arterial	20 min	100% venous 100% arterial
15	Brachio-brachial straight graft 3-day-old clot	2 venous 2 arterial	9 min	80% venous 100% arterial
16	Brachiobasilic fistula 3-day-old clot	3 venous 2 arterial	11 min	80% venous 100% arterial
17	Upper arm graft 4-day-old clot	2 venous 1 arterial	6 min	60% venous 80% arterial
18	Radiocephalic fistula 3-day-old clot	2 venous	6 min	80% venous

with its dilator over the wire back into the patient. Subsequent angiography showed no evidence of distal embolization or vascular/valvular injury. In one case, which was complicated by severe vessel stenosis and tortuosity, the XCOIL™ failed to deploy fully and the thrombus was not completely captured. In this patient, further attempts at clot removal using the AngioJet device combined with angioplasty were also not successful. In all XCOIL™ cases, postprocedure angiography showed no evidence of graft/fistula or valvular damage or any other intraprocedural complications. In one case, prior to XCOIL™ use, when the initial guidewire and 4F angiographic catheter was advanced beyond the arterial anasto-

mosis into the adjacent artery, subsequent angiography demonstrated emboli within the adjacent brachial artery at the origin of the ulnar artery. This clot was cleared with AngioJet pulse spray using tissue plasminogen activator (tPA) (Altoplase, Genentech Inc.) without further sequelae. In this patient, the XCOIL™ was used to complete the declot procedure. Otherwise, all post-thrombectomy angiography showed no evidence of distal embolization within the adjacent arterial vasculature, the venous outflow, and the central vasculature.

In all but two cases, with minimal training, XCOIL™ met or exceeded operator expectations with regard to navigability of the device within the vessel and ability to ad-

vance through the delivery catheter, even in acutely angled vessels and kinked stents. The deployment performance of XCOIL™, in reliably converting from its unactuated to its actuated state, also met or exceeded operator expectations.

XCOIL™ readily and easily engaged venous thrombus, but in two cases the clot could not be retracted through a severe venous stenosis and a kinked stent. Angioplasty combined with AngioJet thrombectomy was not successful in restoring patency in these same two cases. In four out of a total of 62 passes with XCOIL™ in 18 patients, the pull-wire component fractured. In all four cases, the XCOIL™ could be removed intact through the sheath without clinical or angiographic evidence of any complications, including vascular injury on subsequent post-thrombectomy imaging.

Discussion

XCOIL™ successfully removed thrombus from the occluded outflow vein and grafts as well as firm platelet thrombin plug from the arteriovenous anastomosis restoring patency without evidence of vascular injury on angiography following the declot procedure.

Current declot strategies often employ a pharmacomechanical approach comprised of initial thrombolysis coupled with mechanical thrombectomy and/or balloon angioplasty (3, 4). Thrombolysis can be a lengthy and costly procedure, particularly if infusion thrombolysis is used. The common “lyse and wait” approach is less expensive and associated with lower risk. However, this approach is rarely technically successful without additional thrombectomy and/or balloon maceration of any underlying vascular stenosis.

In view of well-known limitations of current pharmacomechanical approaches, a new mechanical thrombectomy device that reliably removes clot and restores vessel patency, without thrombolytic agents, has obvious potential utility as a first-line treatment. In the present study, promising initial clinical data were obtained with XCOIL™ without adjunctive thrombolytic agents. A high rate of complete recanalization of occluded vessels was demonstrated. The XCOIL™ thrombectomy procedure time was short, averaging 8 min (range, 5–18 min), without extensive preparation time. Furthermore, because a thrombolytic agent was not required, no time was spent during “lyse and wait” or other thrombolytic infusion. This reduction in preparation time and associated

costs and risks may prove to be a significant benefit of XCOIL™ compared with other mechanical thrombectomy devices that require adjunctive thrombolytic drugs.

The XCOIL™ was designed to fully enmesh and retract hard organized fibrin-laden thrombus (11). Safe and effective removal of chronic clot has always been problematic. In two study cases, seven-day-old thrombus was removed and in one case, 30-day-old clot was removed. While only evaluated in three cases in this study, the preliminary results suggest that chronic thrombus can be removed with XCOIL™. Additional experience with subacute and chronic occlusions would be required to further substantiate efficacy in this setting. It is clear that firm clot such as the platelet thrombin plug is removed with the XCOIL™. Several mechanical thrombectomy devices, including the AngioJet rheolytic catheter (AngioJet AVX, Boston Scientific) and the Arrow-Terrotola percutaneous thrombectomy device (Teleflex), have been used for treatment of thrombosed prosthetic AV grafts and fistulae. The AngioJet device is reported to have a 6% to 10% rate of hemorrhagic complications, distal embolization, and vessel dissection during arterial interventions (13). An 11% occurrence of adverse events has been reported with use of hydrodynamic thrombectomy devices during dialysis graft de clot procedures (14). Current arterial thrombectomy devices have a 2%–18% rate of distal embolization (13, 15–19), including an 11% incidence of distal embolization for the Trellis device (Bacchus Vascular) (17).

The design of the XCOIL™ appears to minimize distal embolization during clot removal, which was confirmed by angiographic visualization in the present study. XCOIL™ uses a series of loops that are placed around the thrombus to “cocoon” the clot, and the loops are then retracted to keep the thrombus from fragmenting during withdrawal (11, 20). Studies of the XCOIL™ using a pulsatile flow model, similar to that described by Müller-Hülsbeck et al. (14), have demonstrated no significant fragmentation or distal embolization (unpublished communication). Distal embolization into the adjacent artery occurred in one case (5.5%). However, this was not associated with use of the XCOIL™ since it occurred when the usual 0.035-inch guidewire and 4F catheter was advanced beyond the platelet thrombin plug, into the adjacent brachial artery at the origin of the ulnar artery, at which time the patient complained of arm pain and an-

giography demonstrated emboli in the adjacent artery. Recently, a flared intravascular basket (Encapsulator™, NexGen Medical Systems Inc.), which enables clot capture and removal from the sheath, has been added to the XCOIL™ to allow easier removal of clot from the sheath without shearing, or the need to purge the sheath of thrombus following each sweep (21). This intravascular basket (Encapsulator™, NexGen Medical Systems Inc.) was not used in the current study reported here, as we sought to initially demonstrate technical success using only the XCOIL™ loop component.

Vascular trauma, including hemorrhage in 6%–10% cases, dissection in 6%–8% cases, and vessel perforation in 4% cases, has been associated with a number of current mechanical thrombectomy devices in the setting of arterial thrombectomy (13). By comparison, vascular injury was not observed with the XCOIL™ in this study, likely because this device uses soft and atraumatic loops to mechanically retract blood clots. XCOIL™ loops have been described as having viscoelastic properties that match the obstructing thrombus, a design feature which is intended to facilitate control of gripping forces on the thrombus while reducing circumferential contact of the device with the blood vessel endoluminal surfaces (11). This XCOIL™ mechanism facilitates retraction of thrombus without pushing clot into the pulmonary circulation, which is highly desirable, particularly in dialysis patients with large clot burden and borderline cardiopulmonary function.

The occurrence of hemolysis during clot removal, with resultant adenosine release and possible bradycardia, has been reported in 6%–14% cases in which rheolytic thrombectomy devices were used (13). Ultrasound-assisted thrombolytic approaches also have associated hemolysis, although less so than with the AngioJet device (16). By comparison, hemolysis is unlikely with the XCOIL™ because no maceration of blood constituents occurs during thrombectomy.

XCOIL™ device failure was only encountered in the present study as a result of unraveling of the loop complex during first-pass retrieval of thrombus through severely stenotic vessels or severe stenosis within a previously placed stent. In four devices, the pull-wire which actuates the loop complex snapped while withdrawing from a valved vascular sheath, but was otherwise removed intact. This could likely be avoided by using a valveless sheath.

It is important to note that for any de clot procedure, the complete procedure necessary for technical success requires removal of the thrombus, percutaneous trans-luminal angioplasty (PTA) of any stenosis and sweeping of the platelet thrombin plug most commonly with a Fogarty balloon. It is the angioplasty and/or stenting of the culprit stenosis, not the thrombectomy, which affects subsequent patency. Therefore, nearly all de clot procedures require PTA as an adjunctive procedure.

A limitation of the study is that only two of the de clot procedures were performed on occluded radiocephalic fistulae. Technical and clinical success, without complications, has been demonstrated. However, this is a small number of cases. Furthermore, the majority of the procedures were performed in dialysis grafts and our patient population may not reflect that of all centers.

In conclusion, this study preliminarily demonstrates that the XCOIL™ mechanical thrombectomy device can safely and effectively remove intact clot and platelet thrombin plug from dialysis grafts/fistulae. The data obtained in the present investigation can be used for power analysis to construct a larger prospective randomized study. Clinical trials investigating use of XCOIL™ for deep venous thrombosis are now underway.

Conflict of interest disclosure

W.L. Monsky serves on the NexGen Medical Systems Inc. Medical Advisory Board and has stock options.

R.E. Latchaw is Co-Founder of NexGen Medical Systems Inc., serves on the Medical Advisory Board and has stock options.

References

1. Ereğ E, Suleymanlar G, Serdengeçti K. Nephrology, dialysis and transplantation in Turkey. *Nephrol Dial Transplant* 2002; 17:2087–2093. [CrossRef]
2. Turmel-Rodrigues L, Pengloan J, Bourquelot P. Interventional radiology in hemodialysis fistulae and grafts: a multidisciplinary approach. *Cardiovasc Intervent Radiol* 2002; 25: 3–16. [CrossRef]
3. Bush RL, Lin PH, Lumsden AB. Management of thrombosed dialysis access: Thrombectomy versus thrombolysis. *Semin Vasc Surg* 2004; 17:32–39. [CrossRef]
4. Valji K. Transcatheter treatment of thrombosed hemodialysis access grafts. *AJR Am J Roentgenol* 1995; 164:823–829. [CrossRef]
5. Jain G, Maya ID, Allon M. Outcomes of percutaneous mechanical thrombectomy of arteriovenous fistulas in hemodialysis patients. *Semin Dial* 2008; 21:581–583. [CrossRef]
6. Shatsky JB, Berns JS, Clark TW, et al. Single-center experience with the Arrow-Terrotola Percutaneous Thrombectomy Device in the management of thrombosed native dialysis fistulas. *J Vasc Interv Radiol* 2005; 16:1605–1611. [CrossRef]

7. Ng YY, Wu SC, Hung YN, Ko PJ. Effect of demographic characteristics and timing of vascular access maturation on patency in Chinese incident haemodialysis patients. *Nephrol Dial Transplant* 2009; 24:3447–3453. [\[CrossRef\]](#)
8. Surlan M, Popovic P. The role of interventional radiology in management of patients with end-stage renal disease. *Eur J Radiol* 2003; 46:96–114. [\[CrossRef\]](#)
9. Dolmatch BL, Casteneda F, McNamara TO, Zemel G, Lieber M, Cragg AH. Synthetic dialysis shunts: thrombolysis with the Cragg thrombolytic brush catheter. *Radiology* 1999; 213:180–184. [\[CrossRef\]](#)
10. Beathard GA. Mechanical versus pharmacomechanical thrombolysis for the treatment of thrombosed dialysis access grafts. *Kidney Int* 1994; 45:1401–1406. [\[CrossRef\]](#)
11. Monsky WL, Finitis S, De Cicco D, Brock JM, Kucharczyk J, Latchaw RE. A novel thrombectomy device for retrieval of intravascular thrombus. *Cardiovasc Intervent Radiol* 2011; 34:383–390. [\[CrossRef\]](#)
12. Gray RJ, Sacks D, Martin LG, Trerotola SO; Society of Interventional Radiology Technology Assessment Committee. Reporting standards for percutaneous interventions in dialysis access. *J Vasc Interv Radiol* 2003; 14:S433–442. [\[CrossRef\]](#)
13. Kasirajan K, Haskal Z, Ouriel K. The use of mechanical thrombectomy devices in the management of acute peripheral arterial occlusive disease. *J Vasc Interv Radiol* 2001; 12:405–411. [\[CrossRef\]](#)
14. Barth KH, Gosnell MR, Palestrant AM, et al. Hydrodynamic thrombectomy system versus pulse-spray thrombolysis for thrombosed hemodialysis grafts: a multicenter prospective randomized comparison. *Radiology* 2000; 217:678–684. [\[CrossRef\]](#)
15. Müller-Hülsbeck S, Grimm J, Leidt J, Jahnke T, Heller M. Comparison of in vitro effectiveness of mechanical thrombectomy devices. *J Vasc Interv Radiol* 2001; 12:1185–1191. [\[CrossRef\]](#)
16. Lang EV, Kulis AM, Villani M, Barnhart W, Balano R, Cohen R. Hemolysis comparison between the OmniSonics OmniWave Endovascular System and the Possis AngioJet in a porcine model. *J Vasc Interv Radiol* 2008; 19:1215–1221. [\[CrossRef\]](#)
17. Sarac TP, Hilleman D, Arko FR, Zarins CK, Ouriel K. Clinical and economic evaluation of the trellis thrombectomy device for arterial occlusions: preliminary analysis. *J Vasc Surg* 2004; 39:556–559. [\[CrossRef\]](#)
18. Liebig T, Reinartz J, Hannes R, Miloslavski E, Henkes H. Comparative in vitro study of five mechanical embolectomy systems: effectiveness of clot removal and risk of distal embolization. *Neuroradiology* 2008; 50:43–52. [\[CrossRef\]](#)
19. Kasirajan K, Marek JM, Langsfeld M. Mechanical thrombectomy as a first-line treatment for arterial occlusion. *Semin Vasc Surg* 2001; 14:123–131. [\[CrossRef\]](#)
20. Finitis S. Thrombus removal system and process. United States Patent No. 7,955,344. Issued June 7, 2011.
21. Pokorney J, Finitis S, Kucharczyk J. Thrombus removal system and process. United States Patent No. 8,603,122 B2. Issued December 10, 2013.