

# UC Irvine

## UC Irvine Previously Published Works

### Title

Not All That Wheezes Is Bronchial Asthma

### Permalink

<https://escholarship.org/uc/item/0kq4t7nx>

### Journal

New England Journal of Medicine, 363(1)

### ISSN

0028-4793

### Authors

Randhawa, Inderpal  
Nussbaum, Eliezer

### Publication Date

2010-07-01

### DOI

10.1056/nejmicm0906105

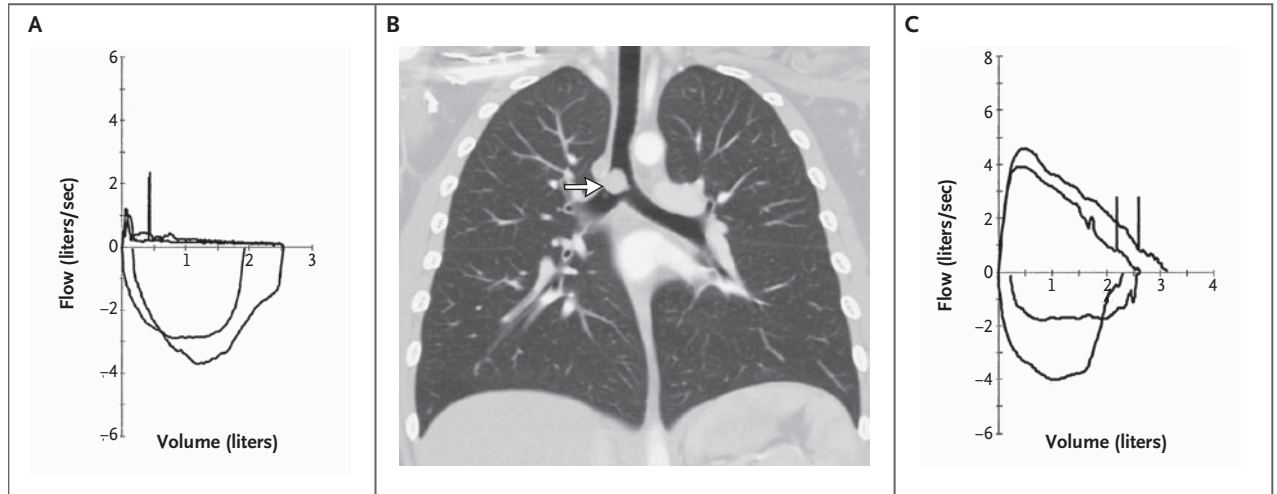
### Copyright Information

This work is made available under the terms of a Creative Commons Attribution License, available at <https://creativecommons.org/licenses/by/4.0/>

Peer reviewed

## IMAGES IN CLINICAL MEDICINE

## Not All That Wheezes Is Bronchial Asthma



A 10-YEAR-OLD PREVIOUSLY HEALTHY GIRL PRESENTED WITH EPISODIC wheezing, dyspnea, and progressive exercise intolerance, which had developed during the preceding 9 months. On physical examination, the patient had moderate bilateral expiratory wheezing. She was treated for presumed asthma with multiple courses of inhaled bronchodilators, inhaled corticosteroids, montelukast, and oral corticosteroids. Though the patient reported that her condition had improved somewhat, there was no demonstrable objective improvement. Further evaluation by spirometry revealed severe expiratory obstruction (Panel A). The patient underwent flexible fiberoptic bronchoscopy, which revealed nearly complete (>90%) occlusion of the distal trachea by a vascular mass. Computed tomographic angiography showed that the mass did not extend beyond the trachea (Panel B, arrow). The mass was ablated endoscopically with the use of a potassium titanyl phosphate laser. Pathological analysis revealed an inflammatory pseudotumor, a benign tumor composed of a proliferation of inflammatory cells. Rarely invasive, this type of tumor is usually cured by local excision. One month after surgery, the patient was free of symptoms and had normal results on spirometry (Panel C). Pulmonary pseudotumors are rarely the cause of wheezing. However, a lack of response to first-line therapies warrants further investigation, including spirometric analysis.

Copyright © 2010 Massachusetts Medical Society.

Inderpal Randhawa, M.D.  
Eliezer Nussbaum, M.D.

Miller Children's Hospital  
Long Beach, CA  
docrandhawa@verizon.net