

UCSF

UC San Francisco Previously Published Works

Title

Comparative Analysis of Clinical and Patient-Reported Outcomes of a New Enhanced Monofocal IOL and a Conventional Monofocal IOL.

Permalink

<https://escholarship.org/uc/item/0m22x8q5>

Authors

Dell, Steven

Hannan, Stephen

Venter, Jan

et al.

Publication Date

2024

DOI

10.2147/OPHTH.S456332

Peer reviewed

Comparative Analysis of Clinical and Patient-Reported Outcomes of a New Enhanced Monofocal IOL and a Conventional Monofocal IOL

Steven J Dell¹, Stephen J Hannan², Jan A Venter², David Teenan², Noelle C Hannan², Dasi Raju², Colin W Berry², Huba J Kiss², Julie M Schallhorn^{3,4}

¹Dell Laser Consultants, Austin, TX, USA; ²Optical Express, Glasgow, UK; ³University of California, San Francisco, Department of Ophthalmology, San Francisco, CA, USA; ⁴F.I. Proctor Foundation, University of California, San Francisco, CA, USA

Correspondence: Steven J Dell, Dell Laser Consultants, 901 Mopac Expressway South, Barton Oaks Plaza IV, Suite 350, Austin, TX, 78746, USA, Email steven@dellmd.com

Purpose: To compare the outcomes of the Tecnis Eyhance ICB00 IOL, designed to enhance intermediate vision, to a conventional Tecnis Monofocal ZCB00 IOL.

Methods: This retrospective analysis compared two cohorts of patients undergoing lens replacement surgery with bilateral implantation of the Tecnis ICB00 or the Tecnis ZCB00 IOL (383 patients in each group). Monocular and binocular uncorrected distance (UDVA), intermediate (UIVA; 66cm), and near (UNVA; 40cm) visual acuities, refractive predictability, and patient-reported outcomes were compared. A sub-analysis of patients with the Eyhance IOL was performed to compare patients who achieved bilateral emmetropia to those with mini-monovision. One-month postoperative outcomes were analyzed.

Results: Both groups had comparable UDVA outcomes. On average, both monocular and binocular UIVAs were approximately one Snellen line better in patients implanted with Eyhance IOL (monocular UIVA: ICB00 0.23 ± 0.18 logMAR, ZCB00 0.33 ± 0.19 logMAR; binocular UIVA: ICB00 0.18 ± 0.18 logMAR, ZCB00 0.26 ± 0.20 logMAR, $p < 0.01$). Likewise, the mean UNVA was also one Snellen line better with the ICB00 model (monocular UNVA: ICB00 0.51 ± 0.20 logMAR, ZCB00 0.61 ± 0.18 logMAR; binocular UNVA: ICB00 0.42 ± 0.19 logMAR, ZCB00 0.51 ± 0.22 logMAR, $p < 0.01$). There was no difference between the two groups in overall satisfaction or visual phenomena. A subgroup of patients who achieved mini-monovision with Eyhance IOL had, on average, one Snellen line better UIVA and UNVA compared to patients with bilateral emmetropia.

Conclusion: Patients receiving the enhanced monofocal IOL had better intermediate and near vision compared to those receiving the conventional monofocal IOL, with similar levels of patient-reported photic phenomena in both groups.

Keywords: enhanced monofocal IOL, Eyhance, patient-reported outcomes

Introduction

Achieving increased depth of focus is important for patients undergoing intraocular lens procedures since a variety of daily activities require good intermediate vision (eg, computer work, tablets, cooking, various hobbies, etc.). The increasing use of smartphones and tablet devices has made intermediate vision a greater priority for many patients undergoing cataract or refractive lens exchange surgery. In the United Kingdom, patients aged between 55 and 64 have seen the biggest increase in smartphone internet usage over the past decade, going from 9% in 2012 to 87% in 2020. This is followed by the over-65 age group, going from just 3% in 2012 to 65% in 2020.¹

These demands have been heard by lens manufacturers, and there are now available several presbyopia-correcting diffractive and refractive multifocal IOL models specifically designed to improve intermediate vision, such as trifocal IOLs.²⁻⁴ Although these lenses are an excellent option, their use in some patients is limited by a reduction in contrast sensitivity or coexisting ocular disease.^{4,5}

In recent years, a few monofocal IOL designs emerged with optical properties aiming to slightly extend the depth of focus while maintaining a similar clarity of distance vision and visual phenomena incidence as conventional monofocal IOLs.⁶ One of these is the Tecnis Eyhance ICB00 IOL (Johnson & Johnson Vision, Inc, Irvine, CA).^{7–33} This IOL has similar features as the Tecnis ZCB00 monofocal aspheric IOL of the same manufacturer (Johnson & Johnson Vision, Inc, Irvine, CA). Compared to the ZCB00 model, the ICB00 has a refractive optical design with a higher-order aspheric anterior surface that creates continuous power progressions from the periphery to the center.^{9,11,17} Such optic profile is intended to improve intermediate vision, and these lens models are often referred to as monofocal plus or enhanced monofocal IOLs.⁶

To date, there are a number of studies that compare the ICB00 model to its parent IOL model (ZCB00 or its preloaded versions DCB00 and PCB00; Johnson & Johnson Vision, Inc, Irvine, CA),^{7–21} most of which are based on a smaller sample size comparison and often report differing extent of improvement of intermediate and near vision with the enhanced monofocal IOL. The refractive outcomes of the studies also vary, and very few studies report on the tolerance to monovision.^{15,33}

Hence, the aim of the current study was to validate the findings of previous studies in a large cohort of patients, comparing visual, refractive, and patient-reported outcomes between the ICB00 and ZCB00 models. Additionally, the tolerance to the monovision approach in patients implanted with bilateral Tecnis Eyhance ICB00 IOL was assessed.

Patients and Methods

The study was a retrospective analysis of patients who underwent lens replacement surgery in the presence or absence of a cataract, comparing two types of implanted IOLs: a monofocal IOL with an enhanced depth of focus, Tecnis Eyhance ICB00, to a conventional aspheric monofocal IOL, Tecnis ZCB00 (both IOLs manufactured by Johnson & Johnson Vision, Inc, Irvine, CA). This study was deemed exempt from review by the Institutional Review Board at the University of California, San Francisco, because it used only retrospective, de-identified patient data. All patients signed an informed consent to undergo the surgical procedure and agreed to use their de-identified data for statistical analysis and research purposes. The study adhered to the tenets of the Declaration of Helsinki.

Patient data were extracted from the electronic medical records of Optical Express, Glasgow, United Kingdom, with the following criteria: treatment between November 2019 and July 2023, bilateral implantation of Tecnis Eyhance ICB00, corneal astigmatism of 1.50 D or less in each eye, corrected distance visual acuity (CDVA) 20/40 or better in each eye, attended one-month postoperative visit, and completed a vision and eye health patient experience questionnaire. Patients with significant ocular co-morbidities that could limit visual function were excluded. A sample of patients matched on preoperative CDVA and age with bilateral implantation of the Tecnis Monofocal ZCB00 IOL was selected from a large dataset of patients treated during the same time period by the same treating ophthalmic surgeons, applying the same preoperative inclusion/exclusion criteria.

At baseline, the patients underwent a full ophthalmic examination, including visual acuity measurement, ocular dominance testing, anterior eye slit-lamp examination, and dilated fundus examination. Diagnostic scans included autorefractometry and tonometry (Tonoref II, Nidek Co. Ltd., Gamagory, Japan), corneal tomography (Pentacam, Oculus Optikgeräte GmbH, Wetzlar, Germany), wavefront aberration measurement (iDesign Advanced WaveScan System, Johnson & Johnson Vision, Inc, Irvine, CA), endothelial cell count (SP 2000P specular microscope, Topcon Corp, Tokyo, Japan), biometry (IOLMaster, Carl Zeiss Meditec AG, Jena, Germany), and retinal optical coherence tomography (Cirrus 4000/500 OCT, Carl Zeiss Meditec AG, Jena, Germany).

Visual acuity measurements included monocular corrected distance visual acuity (CDVA), monocular and binocular uncorrected distance (UDVA), intermediate (UIVA), and near (UNVA) visual acuity. Corrected and uncorrected distance visual acuity was measured at 4 meters with a logarithmic acuity chart. Near visual acuity was measured at 40 cm with an early treatment diabetic retinopathy study (ETDRS) near vision chart normalized for a 40 cm distance. Intermediate visual acuity was tested at 66 cm using the same ETDRS chart as for UNVA, with the visual acuity adjusted for the modified viewing distance. All visual acuities were recorded in Snellen equivalents on the electronic medical record and converted to the logarithm of the minimum angle of resolution (logMAR) for statistical analysis.

Postoperatively, patients were required to complete a vision and eye health patient experience questionnaire, where they rated their overall satisfaction with vision (on a scale from 1 – very satisfied to 5 – very dissatisfied) as well as the difficulty with visual side effects (glare, halo, starburst, ghosting/double vision) on a discrete scale from 1 (no difficulty)

to 7 (severe difficulty). The methodology for obtaining the questionnaire has been previously described.³⁴ One-month postoperative patient-reported outcomes, visual acuity, and refractions were used for analysis in the current study.

Intraocular Lenses

Tecnis ZCB00 IOL is a monofocal hydrophobic acrylic one-piece IOL with a spherical posterior surface and an anterior aspheric surface that provides a negative spherical aberration of $-0.27 \mu\text{m}$. The optic diameter is 6 mm, with the overall length of the IOL of 13 mm. The lens is available in dioptric powers from +5.0 D to +34.0 D in 0.5 D increments with an A-constant of 119.3.

Tecnis Eyhance ICB00 IOL is made of the same hydrophobic acrylic material and has the same geometric characteristics, A-constant, and available dioptric range as the ZCB00 model. Compared to the ZCB00 model, the ICB00 model has a modified higher-order aspheric anterior surface. This profile is designed to continuously increase the power of the enhanced monofocal IOL from the periphery to the center of the IOL, resulting in improved intermediate vision.

Surgical Technique

The surgeries were performed either by a standard phacoemulsification technique, or with the assistance of a femtosecond laser (Catalys Precision Laser System, Johnson & Johnson Vision, Inc, Irvine, CA). Both IOL models were implanted through a 2.75 mm clear corneal incision under topical anesthesia (proparacaine hydrochloride 0.5%). The surgical procedures were conducted by 20 experienced ophthalmic surgeons in 17 surgical centers across the United Kingdom and Ireland. Surgical equipment, diagnostic equipment, postoperative regimens, and biometry settings were standardized across all clinics. The standard postoperative drop regimen included topical antibiotic drops for 2 weeks and topical steroid drops for four weeks.

Statistical Analysis

Preoperative and one-month postoperative variables were compared between Tecnis Eyhance ICB00 IOL ("Group 1") and Tecnis Monofocal ZCB00 IOL ("Group 2"). All continuous variables were compared using an independent *t*-test or Mann–Whitney test, depending on the normality assumption. The chi-square test was used to compare percentages.

Standard graphs for reporting outcomes of intraocular lens-based refractive surgery³⁵ were used to present outcomes, with the addition of cumulative UIVA and UNVA histograms. To account for the interrelatedness of the two eyes of a patient, all monocular visual acuity outcomes (monocular UDVA, UIVA, UNVA, and CDVA) and refractive outcomes analysis (refractive predictability, the distribution of postoperative manifest spherical equivalent, and refractive astigmatism outcomes) were analyzed using one eye of each patient, the dominant eye. Another reason for dominant eye analysis was a frequent aim for monovision or mini-monovision in the non-dominant eye among patients with monofocal IOLs. Using a dominant eye ensured only eyes targeted for emmetropia were used in monocular visual acuity and refractive outcomes analysis. However, a brief description of non-dominant eyes outcomes (mean manifest spherical equivalent and the percentage of eyes with postoperative myopia) was included to compare the two groups as the refractive aim of the non-dominant eye can influence binocular visual acuity and patient-reported outcomes. All patient-reported outcomes (satisfaction with vision and visual phenomena) were analyzed on a per-patient basis.

In the group of patients implanted with Tecnis Eyhance ICB00 IOL, an additional analysis was performed to compare the outcomes of patients who achieved bilateral emmetropia to those with mini-monovision. A *p*-value of less than 0.05 was considered significant in all analyses.

Results

There were 383 patients (766 eyes) in each group. Table 1 shows the comparison of preoperative demographics, visual acuity, and refraction of the two study groups. The groups were matched on preoperative age and CDVA, but all of the other preoperative characteristics also appeared to be comparable. Most eyes (97.5% or 1494 of 1532) had standard phacoemulsification, while only 2.5% (38/1532) had femtosecond laser-assisted phacoemulsification.

There was no statistically significant difference in the mean power of the implanted IOL (Group 1: 22.81 ± 4.32 D, range from 5.00 D to 34.00 D; Group 2: 22.89 ± 4.95 D, range from 5.00 D to 34.00 D, *p* = 0.74), implying preoperative

Table 1 Preoperative Characteristics of the Two Study Groups

	TECNIS Eyhance ICB00 (Group 1)	TECNIS Monofocal ZCB00 (Group 2)	P value
Number of patients (eyes)	383 (766)	383 (766)	
Age [years] Mean \pm SD [Range]	60.07 \pm 8.37 [40, 85]	60.16 \pm 8.17 [42, 83]	0.87
Male/Female [%]	52.2/47.8	54.3/45.7	0.56
Sphere [D] Mean \pm SD [Range]	+1.41 \pm 3.01 [-13.5, +9.75]	+1.43 \pm 3.49 [-13.75, +9.25]	0.92
Cylinder [D] Mean \pm SD [Range]	-0.63 \pm 0.43 [-3.00, 0.00]	-0.63 \pm 0.44 [-3.50, 0.00]	0.87
MSE [D] Mean \pm SD [Range]	+1.10 \pm 3.03 [-14.00, +8.75]	+1.12 \pm 3.50 [-14.38, +8.63]	0.93
Monocular CDVA [logMAR] Mean \pm SD [Range]	-0.01 \pm 0.10 [-0.18, 0.30]	-0.01 \pm 0.10 [-0.18, 0.30]	0.50
Power of implanted IOL [D] Mean \pm SD [Range]	22.81 \pm 4.32 [5.00, 34.00]	22.89 \pm 4.95 [5.00, 34.00]	0.74

Abbreviations: D, diopter; SD, standard deviation; MSE, manifest spherical equivalent; logMAR, logarithm of minimum angle of resolution; CDVA, corrected distance visual acuity; IOL, intraocular lens.

biometric measurements were also likely comparable between the two groups. One-month postoperative outcomes are summarized in [Table 2](#).

Uncorrected Visual Acuity

[Figure 1](#) depicts one-month postoperative monocular (A) and binocular (B) UDVA. There was no statistically significant difference between groups in the percentages for any of the presented levels of visual acuity (VA) in [Figure 1A](#) (p-values

Table 2 One-Month Postoperative Comparison

	TECNIS Eyhance ICB00 (Group 1)	TECNIS Monofocal ZCB00 (Group 2)	P value
Number of patients (eyes)	383 (383)	383 (383)	
Sphere (dominant eye) [D] Mean \pm SD [Range]	+0.22 \pm 0.44 [-1.75, +2.00]	+0.23 \pm 0.45 [-1.75, +1.75]	0.76
Cylinder (dominant eye) [D] Mean \pm SD [Range]	-0.48 \pm 0.37 [-2.00, 0.00]	-0.47 \pm 0.38 [-2.50, 0.00]	0.94
MSE (dominant eye) [D] Mean \pm SD [Range]	-0.02 \pm 0.40 [-1.88, +1.75]	-0.01 \pm 0.43 [-2.00, +1.50]	0.72
MSE (non-dominant eye) [D] Mean \pm SD [Range]	-0.17 \pm 0.46 [-1.50, +1.50]	-0.23 \pm 0.71 [-2.25, +1.25]	0.17
Monocular UDVA [logMAR] (dominant eye) Mean \pm SD [Range]	0.02 \pm 0.12 [-0.18, 0.60]	0.01 \pm 0.13 [-0.18, 0.70]	0.51
Binocular UDVA [logMAR] Mean \pm SD [Range]	-0.03 \pm 0.10 [-0.18, 0.52]	-0.04 \pm 0.09 [-0.18, 0.60]	0.23
Monocular UIVA [logMAR] (dominant eye) Mean \pm SD [Range]	0.23 \pm 0.18 [-0.08, 0.78]	0.33 \pm 0.19 [-0.08, 0.88]	<0.01
Binocular UIVA [logMAR] Mean \pm SD [Range]	0.18 \pm 0.18 [-0.08, 0.78]	0.26 \pm 0.20 [-0.08, 0.88]	<0.01
Monocular UNVA [logMAR] (dominant eye) Mean \pm SD [Range]	0.51 \pm 0.20 [0.00, 1.3]	0.61 \pm 0.18 [0.10, 1.10]	<0.01
Binocular UNVA [logMAR] Mean \pm SD [Range]	0.42 \pm 0.19 [0.00, 1.30]	0.51 \pm 0.22 [0.00, 1.00]	<0.01
Monocular CDVA [logMAR] (dominant eye) Mean \pm SD [Range]	-0.05 \pm 0.07 [-0.18, 0.40]	-0.05 \pm 0.09 [-0.18, 1.00]	0.40

Abbreviations: D, diopter; SD, standard deviation; MSE, manifest spherical equivalent; logMAR, logarithm of minimum angle of resolution; UDVA, uncorrected distance visual acuity; UIVA, uncorrected intermediate visual acuity; UNVA, uncorrected near visual acuity; CDVA, corrected distance visual acuity.

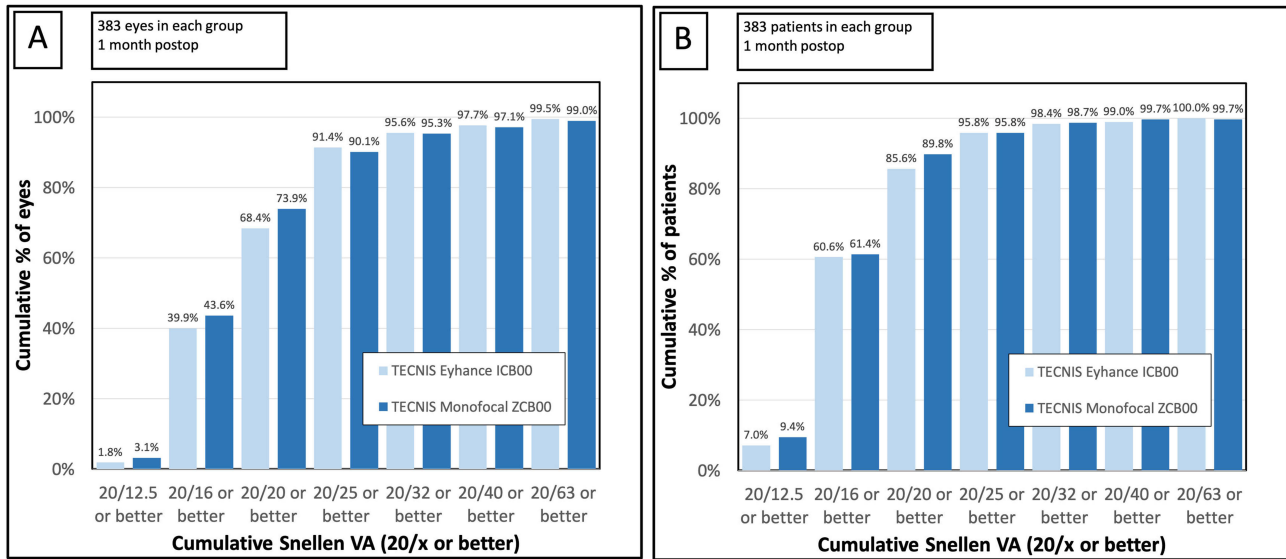


Figure 1 Cumulative postoperative monocular (A) and binocular (B) uncorrected distance visual acuity. Monocular visual acuity outcomes are based on the dominant eye of each patient.

between 0.09 and 0.86) or **Figure 1B** (p-values between 0.08 and 1.00). Comparing the mean logMAR UDVA, there was no statistically significant difference in the mean monocular UDVA (Group 1: 0.02 ± 0.12 logMAR or $\approx 20/20^{-1}$; Group 2: 0.01 ± 0.13 logMAR or $\approx 20/20^{-0.5}$; $p = 0.51$) or binocular UDVA (Group 1: -0.03 ± 0.10 logMAR or $\approx 20/20^{+1.5}$; Group 2: -0.04 ± 0.09 logMAR or $\approx 20/20^{+2}$; $p = 0.23$).

Cumulative uncorrected intermediate visual acuity is depicted in **Figures 2A** (monocular) and **2B** (binocular). For monocular UIVA, the difference in percentages was statistically significant between the two groups for every level of presented visual acuity in **Figure 2A**, except for 20/20 or better ($p = 0.11$) and 20/80 or better ($p = 0.23$), where the difference did not reach significance. For binocular UIVA, the difference in percentages between the groups was statistically significant for every level of VA in **Figure 2B** except for 20/80 or better ($p = 0.29$). On average, both monocular and binocular logMAR UIVAs were approximately one Snellen line better in Group 1 compared to Group 2.

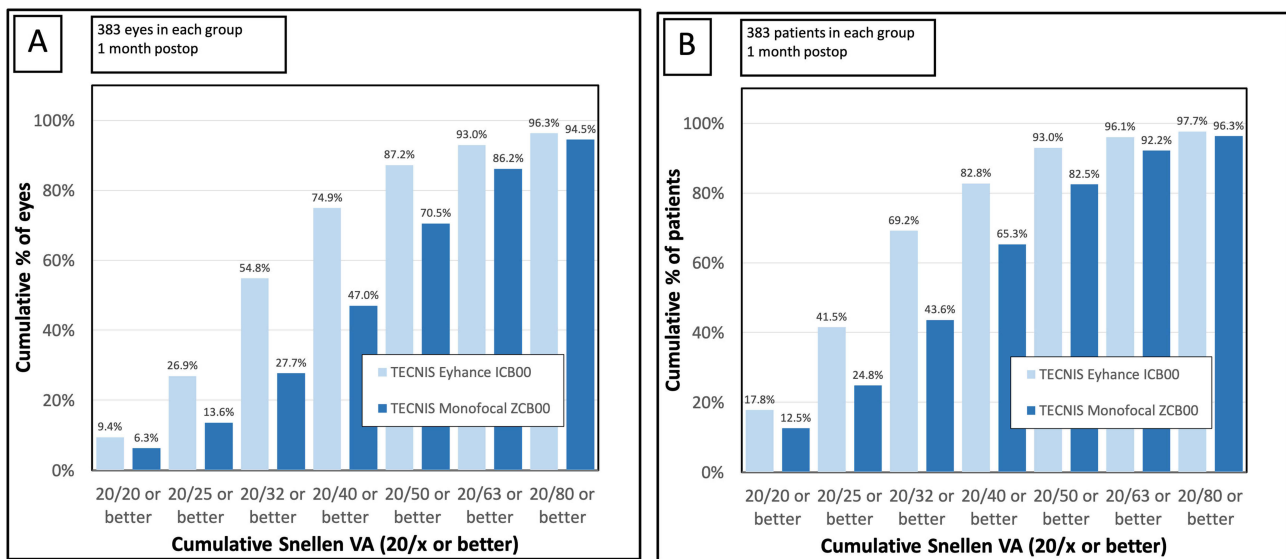


Figure 2 Cumulative postoperative monocular (A) and binocular (B) uncorrected intermediate visual acuity (66 cm). Monocular visual acuity outcomes are based on the dominant eye of each patient.

The mean monocular UIVA was 0.23 ± 0.18 logMAR ($\approx 20/32^{-1.5}$) in Group 1 and 0.33 ± 0.19 logMAR ($\approx 20/40^{-1.5}$) in Group 2 ($p < 0.01$). The mean binocular UIVA was 0.18 ± 0.18 logMAR ($\approx 20/32^{+1}$) in Group 1 and 0.26 ± 0.20 logMAR ($\approx 20/40^{+2}$) in Group 2 ($p < 0.01$).

Monocular UNVA (Figure 3A) was significantly better in favor of Group 1 for all percentages and visual acuity levels ($p < 0.04$). Binocular UNVA (Figure 3B) was significantly better for all visual acuity levels, except for 20/32 or better, where the outcome was on the borderline of statistical significance ($p = 0.06$). Corresponding with the UIVA outcomes, both monocular and binocular mean logMAR UNVAs were approximately one Snellen line better in Group 1. The mean monocular UNVA was 0.51 ± 0.20 logMAR ($\approx 20/63^{-0.5}$) in Group 1 and 0.61 ± 0.18 logMAR ($\approx 20/80^{-0.5}$) in Group 2 ($p < 0.01$). The mean binocular UNVA was 0.42 ± 0.19 logMAR ($\approx 20/50^{-1}$) in Group 1 and 0.51 ± 0.22 logMAR ($\approx 20/63^{-0.5}$) in Group 2 ($p < 0.01$).

Corrected Distance Visual Acuity

Figure 4 shows the difference between preoperative and postoperative CDVA. Both groups had comparable CDVA at baseline (Table 1). The majority of eyes had good preoperative CDVA. Of all dominant eyes, 82.8% (317 out of 383) in Group 1 and 80.7% (309 out of 383) in Group 2 had preoperative CDVA 20/20 or better ($p = 0.45$), while 93.2% (357/383) and 93.5% (358/383) of eyes had preoperative CDVA 20/25 or better in Groups 1 and 2, respectively ($p = 0.88$).

At the one-month visit, there was no statistically significant difference in the mean logMAR CDVA between the two groups (Group 1: -0.05 ± 0.07 logMAR or 20/20^{+2.5}; Group 2: -0.05 ± 0.09 logMAR 20/20^{+2.5}; $p = 0.40$), although the histogram in Figure 4 is suggestive of a slightly higher gain of CDVA in Group 2.

Refractive Outcomes

Figures 5A and B depict the scattergram of refractive predictability for the two groups. Both IOLs demonstrated a predictable correction of manifest spherical equivalent (MSE) with no apparent over or undercorrection of the outcomes in the dominant eye. The mean postoperative MSE in the dominant eye was -0.02 ± 0.40 D in Group 1 and -0.01 ± 0.43 D in Group 2 ($p = 0.72$).

Figure 6 shows the distribution of postoperative manifest spherical equivalent in all dominant eyes. The percentage of eyes with postoperative MSE within ± 0.50 D of emmetropia was 89.0% (341 eyes out of 383) in Group 1 and 86.4% (331 eyes out of 383) in Group 2 ($p = 0.27$). Of all dominant eyes, 97.9% (375/383) in Group 1 and 96.3% (369/383) in Group 2 were within ± 1.00 D of emmetropia ($p = 0.19$).

Non-dominant eyes had a slightly myopic mean postoperative MSE (Group 1: -0.17 ± 0.46 D; Group 2: -0.23 ± 0.71 D; $p = 0.17$). Approximately a quarter of all non-dominant eyes in both groups had postoperative myopic MSE of -0.50 D or less

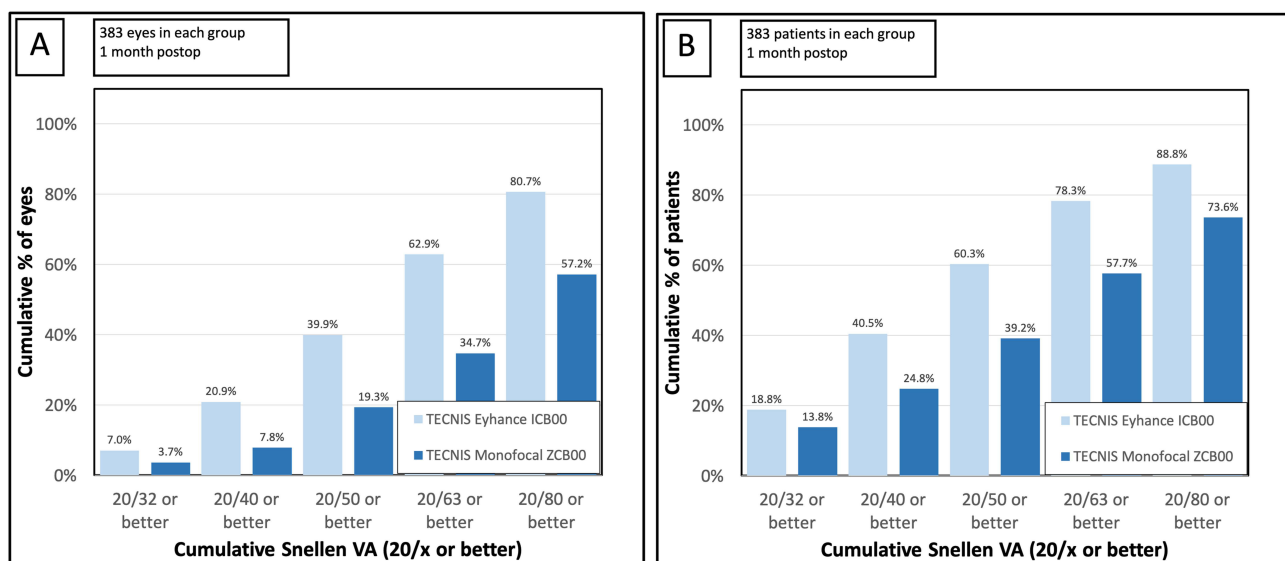


Figure 3 Cumulative postoperative monocular (A) and binocular (B) uncorrected near visual acuity (40 cm). Monocular visual acuity outcomes are based on the dominant eye of each patient.

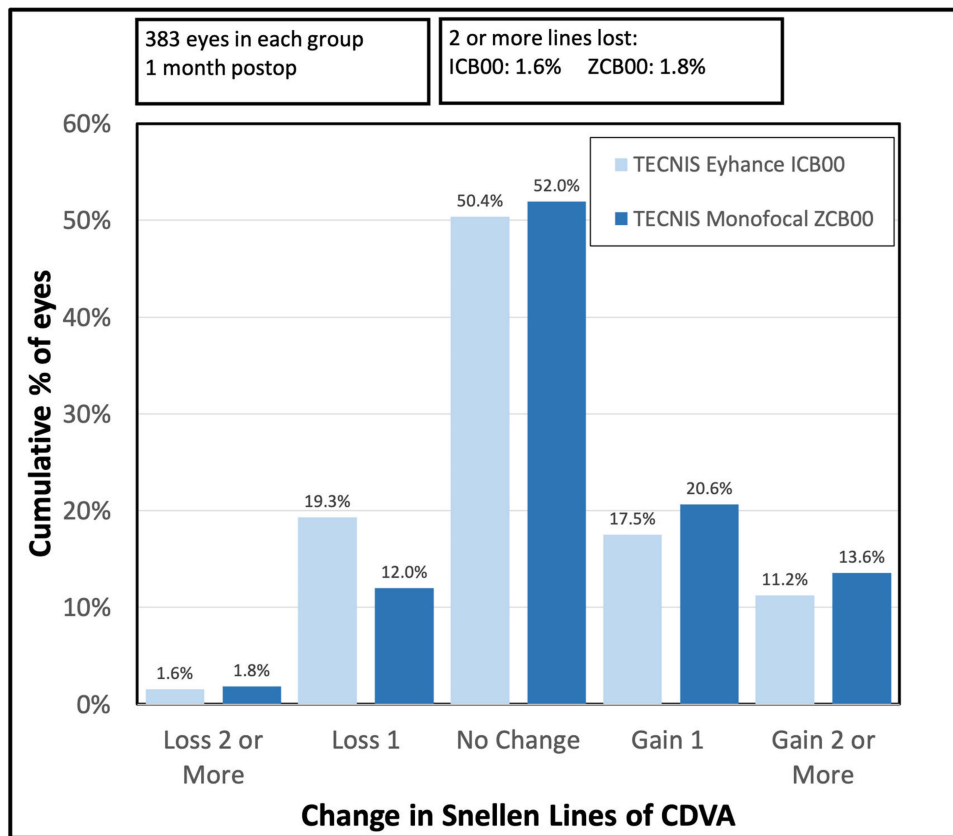


Figure 4 The difference between preoperative and postoperative corrected distance visual acuity (dominant eyes).

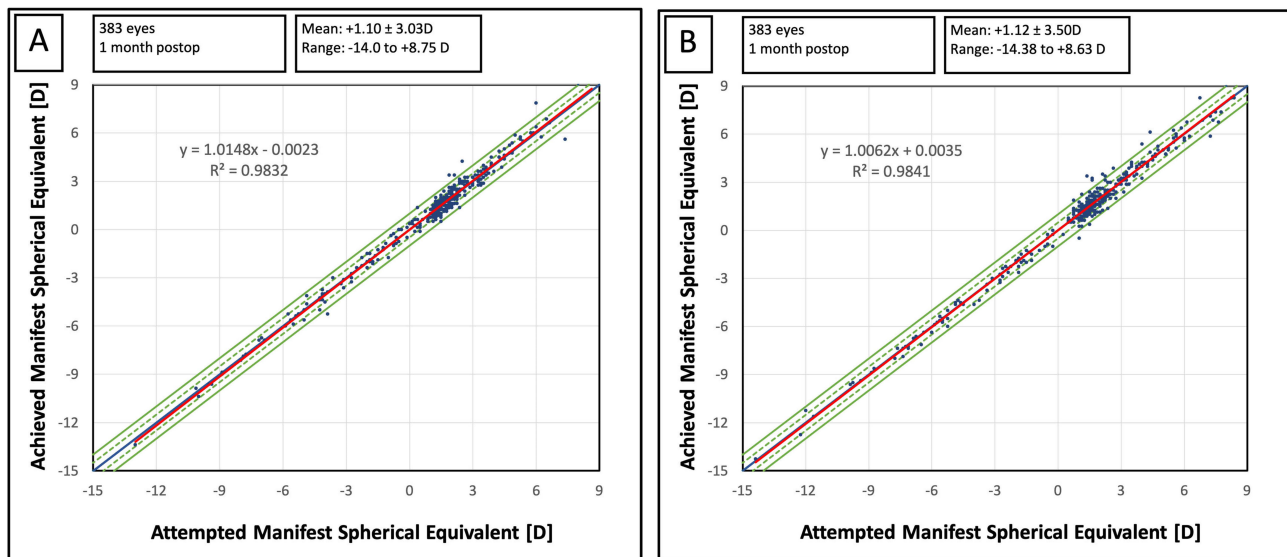


Figure 5 The scattergram of attempted vs achieved manifest spherical equivalent (dominant eyes): (A) Tecnis ICB00 IOL, (B) Tecnis ZCB00 IOL.

(Group 1: 26.1% or 100 out of 383 eyes; Group 2: 25.3% or 97 out of 383 eyes; $p = 0.80$), but the percentage of eyes having myopia of -1.0 D or less in the dominant eye was significantly higher in Group 2 (Group 1: 6.0% or 23 out of 383 eyes; Group 2: 16.4% or 63 out of 383 eyes; $p < 0.01$).

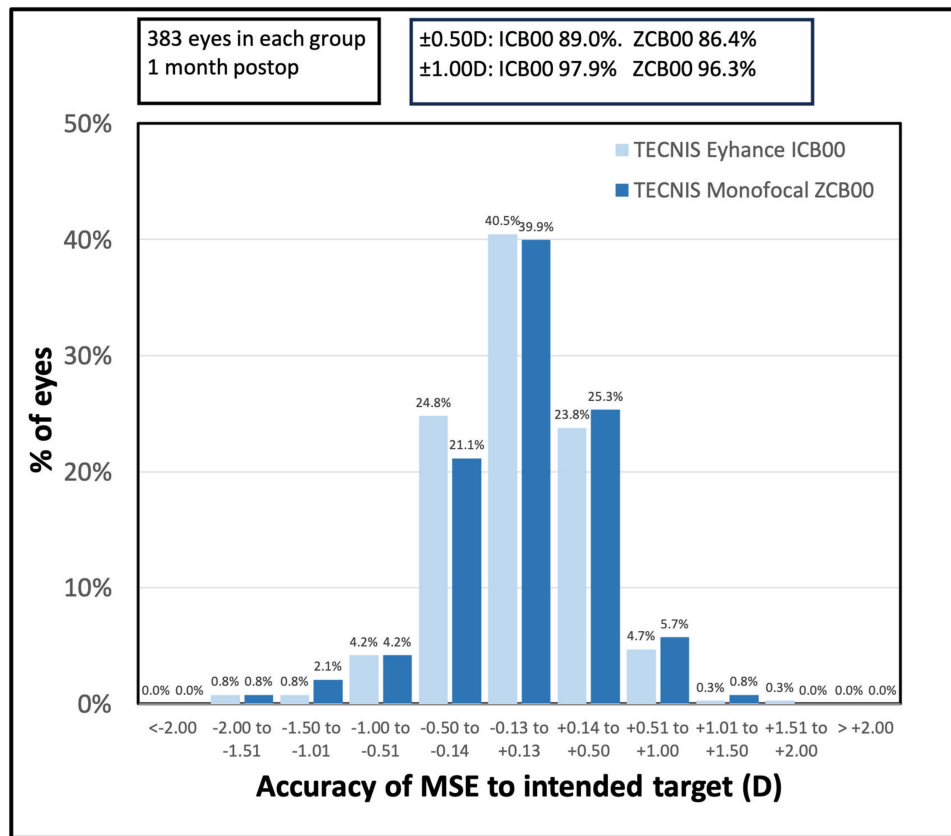


Figure 6 The distribution of postoperative manifest spherical equivalent (MSE) in the dominant eyes.

Figure 7 depicts the distribution of postoperative refractive astigmatism in the dominant eye. There was no statistically significant difference in the mean postoperative refractive cylinder between the two groups (Table 2). Likewise, there was no difference in the percentages of eyes with residual refractive cylinder (absolute value) ≤ 0.50 D (Group 1: 69.5% or 266 eyes out of 383; Group 2: 71.5% or 274 out of 383; $p = 0.53$) or ≤ 1.00 D (Group 1: 94.8% or 363 eyes out of 383; Group 2: 93.2% or 357 out of 383; $p = 0.36$).

Patient Reported Outcomes

The percentage of patients satisfied or very satisfied with postoperative vision was 90.6% (347 out of 383) in Group 1 and 92.7% (355/383) in Group 2 ($p = 0.30$). Of all patients, 93.2% (357/383) in Group 1 and 95.8% (367/383) in Group 2 would recommend the procedure to their friends and family ($p = 0.11$). The differences between the two groups were not statistically significant.

Table 3 shows the comparison of visual phenomena between the two groups. The mean visual phenomena score (calculated as the mean of 1 – no difficulty to 7 – severe difficulty) was comparable between the two groups for all four evaluated side effects (glare, halo, starburst, ghosting/double vision). Likewise, there was no statistically significant difference in the percentage of patients experiencing no or little, moderate, or significant difficulty with visual phenomena (Table 3). The percentage of patients having significant difficulty with any of the presented side effects ranged between 0.8% and 1.8% (3 to 7 patients of 383) in Group 1 and between 0.5% and 1.6% in Group 2 (2 to 6 patients of 383).

Tecnis Eyhance ICB00 IOL and Refractive Aim

A sub-analysis of patients was performed to compare the outcomes of patients who achieved bilateral emmetropia to those who achieved mini-monovision. Bilateral emmetropia was defined as postoperative MSE within ± 0.25 D in each eye with no more than 0.75 D or residual refractive cylinder. Mini-monovision was defined as postoperative emmetropia in one eye and myopic MSE (≤ -0.50 D) in the other eye.

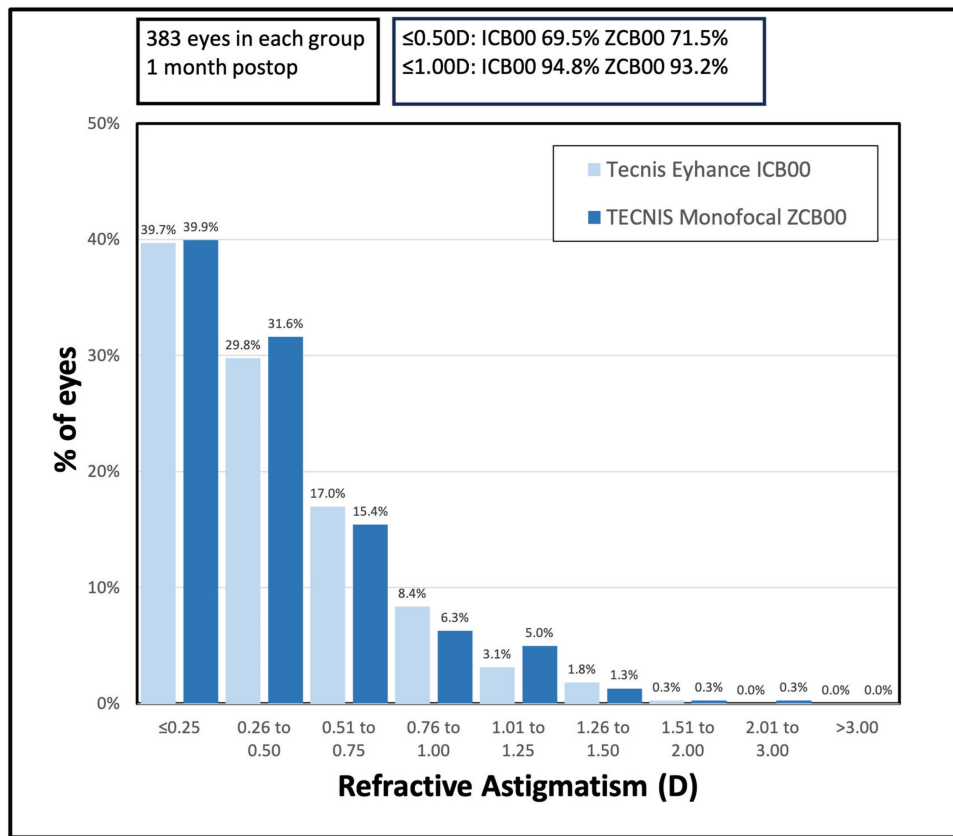


Figure 7 The distribution of postoperative refractive astigmatism (absolute value) in the dominant eyes.

There were 118 patients (236 eyes) who achieved bilateral emmetropia, and 58 patients (116 eyes) achieved monovision. The amount of myopia (MSE) in the monovision eye ranged between -0.50 D and -1.25 D (mean -0.69 ± 0.22 D), with the median value of -0.625 D. The comparison of one-month postoperative outcomes of the two groups is presented in

Table 3 One-Month Postoperative Visual Phenomena

	TECNIS Eyhance ICB00 (383 Patients)	TECNIS Monofocal ZCB00 (383 Patients)	P value
Mean Visual Phenomena Score (\pm Standard deviation)			
Glare	1.61 \pm 1.15	1.67 \pm 1.17	0.53
Halo	1.42 \pm 1.06	1.41 \pm 0.94	0.91
Starburst	1.42 \pm 0.98	1.54 \pm 1.13	0.12
Ghosting/Double vision	1.24 \pm 0.78	1.31 \pm 0.89	0.24
Visual phenomena: No or little difficulty/Moderate difficulty, Significant difficulty (%)			
Glare	84.1%/14.4%/1.6%	82.2%/16.2%/1.6%	0.78
Halo	90.6%/7.6%/1.8%	89.3%/10.2%/0.5%	0.12
Starburst	88.8%/10.4%/0.8%	86.4%/12%/1.6%	0.46
Ghosting/Double vision	94.8%/4.4%/0.8%	92.4%/6.3%/1.3%	0.40

Notes: Visual phenomena were rated on a discrete scale from 1 to 7. No or little difficulty – combined score 1 and 2; Moderate difficulty – combined score 2,3,4; Significant difficulty – combined score 6 and 7.

Table 4 Tecnis Eyhance ICB00 IOL: Comparison of Patients with Postoperative Bilateral Emmetropia to Those with Monovision

	Bilateral Emmetropia	Monovision	P value
Number of patients (eyes)	118 (236)	58 (116)	
Binocular UDVA [logMAR] Mean \pm SD [Range]	-0.08 \pm 0.05 [-0.18, 0.1]	-0.03 \pm 0.08 [-0.18, 0.22]	<0.01
Binocular UIVA [logMAR] Mean \pm SD [Range]	0.18 \pm 0.16 [-0.08, 0.78]	0.09 \pm 0.12 [-0.08, 0.48]	<0.01
Binocular UNVA [logMAR] Mean \pm SD [Range]	0.43 \pm 0.18 [0, 1]	0.32 \pm 0.15 [0, 0.8]	<0.01
Very Satisfied/Satisfied with postoperative vision [% of patients]	90.7%	89.7%	0.83
Would recommend the procedure to friends/family [% of patients]	94.1%	96.6%	0.48
Visual phenomena: No or little difficulty/Moderate difficulty, Significant difficulty (%)			
Glare	81.4%/16.1%/2.5%	84.5%/15.5%/0.0%	0.47
Halo	90.7%/7.6%/1.7%	91.4%/6.9%/1.7%	0.98
Starburst	89.0%/11.0%/0.0%	87.9%/12.1%/0.0%	0.84
Ghosting/Double vision	94.9%/3.4%/1.7%	94.8%/5.2%/0.0%	0.52

Notes: Bilateral emmetropia was defined as manifest spherical equivalent (MSE) within ± 0.25 D in each eye with no more than 0.75 D of refractive astigmatism. Monovision was defined as emmetropia in one eye (MSE within ± 0.25 D with no more than 0.75 D of refractive astigmatism) and myopic MSE (≤ -0.50 D) in the other eye. Visual phenomena were rated on a discrete scale from 1 to 7. No or little difficulty – combined score 1 and 2; Moderate difficulty – combined score 2,3,4; Significant difficulty – combined score 6 and 7.

Abbreviations: UDVA, uncorrected distance visual acuity; UIVA, uncorrected intermediate visual acuity; UNVA, uncorrected near visual acuity; SD, standard deviation; logMAR, logarithm of minimum angle of resolution; CDVA, corrected distance visual acuity.

Table 4. Patients with mini-monovision had, on average, half of the Snellen line worse binocular UDVA ($p < 0.01$), but one Snellen line better binocular UIVA and UNVA ($p < 0.01$). The overall satisfaction was, however, comparable between the two groups.

There was no difference in postoperative visual phenomena between the two groups, indicating that a slight amount of myopia was well tolerated in patients with Eyhance IOL.

Discussion

The current study presents the largest available sample comparison of the two IOLs well matched on preoperative characteristics, with the number of eyes exceeding the sample included in the two currently available meta-analyses of ICB00 vs ZCB00 (or other conventional IOLs) outcomes.^{36,37} Although the actual logMAR values of the achieved UIVA considerably vary in the literature (depending on the methodology, testing distance, and refractive aim), the studies report approximately half a Snellen line to more than two Snellen lines improvement in intermediate vision between ICB00 and ZCB00 models.^{7–21} We found approximately one Snellen line difference in both monocular and binocular UIVA. If we look at the percentage of eyes with 20/32 or better monocular uncorrected acuity at intermediate, the ICB00 achieves this in 54.8% of eyes, compared to 27.7% with the ZCB00.

The meta-analysis of Wan et al³⁶ comparing Eyhance IOL to conventional monofocal IOLs found a mean difference in monocular UIVA -0.11 logMAR (approx. one Snellen line) and a mean difference in binocular UIVA of -0.17 logMAR (almost two Snellen lines). The larger difference in binocular UIVA could be attributed to a more myopic residual manifest spherical equivalent reported in most of the available comparative studies,^{7,9,10,14,18,21} which was, on average, higher than the residual myopia in the non-dominant eye in the current study. On the other hand, a meta-analysis of Redruello-Guerrero et al³⁷ focused on distance-corrected intermediate vision (DCIVA) comparison and found -0.21 logMAR difference between ZCB00 and ICB00 models in binocular DCIVA 2 weeks to 1 month postoperatively, and -0.11 logMAR difference six months postoperatively.

Compared to conventional monofocal IOL, we also found one Snellen line improvement in both monocular and binocular uncorrected near visual acuity with the enhanced monofocal IOL. The mean logMAR UNVA for Eyhance IOL was 0.51 ± 0.20 logMAR ($\approx 20/63^{-0.5}$) monocularly and 0.42 ± 0.19 logMAR ($\approx 20/50^{-1}$) binocularly. At 20/50, 39.9% of eyes implanted with Eyhance met this acuity standard, while in comparison, 19.3% of the conventional ZCB00 monofocal eyes achieved this level of monocular uncorrected near acuity. The currently available meta-analyses do not report on Eyhance near vision outcomes due to the lack of UNVA data in the studies. However, in the few available studies with near vision outcomes,^{10,11,13,17,20,21} monocular UNVA for Eyhance IOL ranged from 0.20 ± 0.14 logMAR for a study with slightly myopic residual MSE (-0.47 ± 0.29 D)¹⁰ to 0.62 ± 0.15 logMAR for a study with the mean MSE close to emmetropia (-0.02 ± 0.84 D).¹⁷ Nevertheless, as anticipated for a monofocal IOL, the UNVA outcomes of Eyhance were always worse in direct comparison to lenses with a true multifocal design.^{11,24,27,30}

In our sub-analysis, mini-monovision with Tecnis Eyhance IOL resulted in slightly worse binocular UDVA but approx. one Snellen line better average UIVA and UNVA compared to patients with Tecnis Eyhance who achieved bilateral emmetropia. The satisfaction and visual phenomena were, however, comparable between bilateral emmetropes and those with mini-monovision. There are two studies that discuss mini-monovision aim with Tecnis Eyhance IOL,^{15,33} one of them has a similar design comparing bilateral emmetropes to mini-monovision patients of the study IOL.³³ In a comparison of 25 patients in each group, the authors found minimal and non-significant differences in bilateral UDVA and UIVA (0.03 logMAR difference), but almost 2 Snellen lines better UNVA with the mini-monovision approach.³³ This is different from our findings, likely because patients in the previous study had a more myopic spherical equivalent, even in the bilateral emmetropia group (mean MSE: bilateral emmetropia group: -0.18 ± 0.21 D vs mini-monovision group: dominant eye -0.19 ± 0.18 D, non-dominant eye: -0.95 ± 0.19 D),²¹ while MSE was closer to plano in eyes targeted for emmetropia in our study. However, their patient-reported findings agree with our conclusions that there was no difference in visual phenomena and overall patient satisfaction between bilateral emmetropes and those with mini-monovision.

Although there might be some variation in the level of improved intermediate or near vision comparing Tecnis ICB00 and ZCB00 model between available studies, whenever intermediate vision was evaluated with patient-reported outcomes (satisfaction or spectacle independence), Tecnis Eyhance was always superior.^{7,8,10–12,14,18,20,28} Most importantly, the published studies strongly agree that there is no difference between the two lenses in the perception of visual phenomena or satisfaction with distance vision.^{7–12,17,20,21} Our study corroborated these findings in a larger population patients, finding no difference in overall satisfaction with vision or difficulties with optical side effects. On the other hand, in direct comparison to multifocal lenses (mainly the extended depth of focus multifocal IOL of the same manufacturer, Tecnis Symphony), the Tecnis Eyhance IOL was found to have a lower incidence of visual phenomena and better optical quality.^{11,27,30}

Our study has some limitations, the most notable being the retrospective design and a relatively short follow-up. Since the new monofocal IOL is intended to improve intermediate vision range, evaluation of the defocus curve would be beneficial, but it was not possible in the current study. Nonetheless, this topic has already been addressed in several smaller comparative studies.^{7,8,10–14,16,17,20,21} Other objective variables evaluating the quality of vision (such as contrast sensitivity or higher-order aberrations) would be valuable, but unfortunately, we were not able to obtain them as the study was retrospective, and these variables were not routinely recorded on our electronic medical record. Even though the equipment, postoperative regimens, and biometry settings are standardized across our clinics, the multi-center and multi-surgeon approach could be perceived as a limitation of the study, as there could be slight variations in the surgical technique among surgeons. The population of patients in this study was younger, and their preoperative corrected visual acuity was better compared to a typical population of patients undergoing cataract surgery with a monofocal IOL. Thus, the findings might not be applicable to patients who undergo cataract surgery in the presence of various ocular comorbidities. However, some preliminary studies^{38,39} showed promising outcomes in patients with ocular pathology other than cataracts, and this topic definitely deserves further attention.

Conclusion

In a large sample analysis, the current study corroborated the findings of the previous studies that Tecnis Eyhance offers better intermediate vision compared to its predecessor while maintaining the same distance vision and a similar incidence

of visual phenomena. A mini-monovision approach can potentially further increase intermediate and near visual acuity in patients implanted with Eyhance IOL without a negative effect on visual phenomena or patient satisfaction.

Disclosure

Steven J Dell is a consultant to Johnson and Johnson Vision, Bausch + Lomb, Allergan, LENZ Therapeutics, Atia Vision, and is a member of the medical advisory board of Optical Express. Stephen J Hannan, Jan A Venter, David Teenan, Noelle C Hannan, Dasi Raju, Colin W Berry, and Huba J Kiss are employees of Optical Express. Julie M Schallhorn received personal fees from Carl Zeiss Meditec, Allergan, and Forsight V6, ViaLase and has a financial interest in Journey 1, Neurotrigger, and Novus Vision.

References

- Hiley C. UK mobile phones statistics. Uswitch statistics from 1st February 2023; 2023. Available from: <https://www.uswitch.com/mobiles/studies/mobile-statistics>. Accessed October 18, 2023.
- Alio JL, Plaza-Puche AB, Fernandez-Buenaga R, Pikkel J, Maldonado M. Multifocal intraocular lenses: an overview. *Survey of Ophthalmology*. 2017;62(5):611–634. doi:10.1016/j.survophthal.2017.03.005
- Salerno LC, Tiveron MC, Alio JL. Multifocal intraocular lenses: types, outcomes, complications and how to solve them. *Taiwan J Ophthalmol*. 2017;7(4):179–184. doi:10.4103/tjo.tjo_19_17
- Schallhorn JM, Pantanelli SM, Lin CC, et al. Multifocal and accommodating intraocular lenses for the treatment of presbyopia: a report by the American Academy of ophthalmology. *Ophthalmology*. 2021;128:1469–1482. doi:10.1016/j.ophtha.2021.03.013
- Braga-Mele R, Chang D, Dewey S, et al. Multifocal intraocular lenses: relative indications and contraindications for implantation. *J Cataract Refract Surg*. 2014;40(2):313–322. doi:10.1016/j.jcrs.2013.12.011
- Fernandez J, Rocha-de-lossada C, Zamorano-Martin F, Rodriguez-Calvo-de-Mora M, Rodriguez-Vallejo M. Positioning of enhanced monofocal intraocular lenses between conventional monofocal and extended depth of focus lenses: a scoping review. *BMC Ophthalmol*. 2023;23(1):101. doi:10.1186/s12886-023-02844-1
- Huh J, Eom Y, Yang SK, Choi Y, Kim HM, Song JS. A comparison of clinical outcomes and optical performance between monofocal and new monofocal with enhanced intermediate function intraocular lenses: a case-control study. *BMC Ophthalmol*. 2021;21(1):365. doi:10.1186/s12886-021-02124-w
- Steinmuller LN, Greve D, Rua Amaro D, Bertelmann E, von Sonnleithner C. Analysis of higher-order aberrations in relation to the clinical outcome of an enhanced monofocal IOL. *Eur J Ophthalmol*. 2022;11206721221134171. doi:10.1177/11206721221134171
- Auffarth GU, Gerl M, Tsai L, et al. Clinical evaluation of a new monofocal IOL with enhanced intermediate function in patients with cataract. *J Cataract Refract Surg*. 2021;47(2):184–191. doi:10.1097/j.jcrs.0000000000000399
- Choi WK, Han HJ, Son HS, Khoramnia R, Auffarth GU, Choi CY. Clinical outcomes of bilateral implantation of new generation monofocal IOL enhanced for intermediate distance and conventional monofocal IOL in a Korean population. *BMC Ophthalmol*. 2023;23(1):157. doi:10.1186/s12886-023-02897-2
- Corbelli E, Iuliano L, Bandello F, Fasce F. Comparative analysis of visual outcome with 3 intraocular lenses: monofocal, enhanced monofocal, and extended depth of focus. *J Cataract Refract Surg*. 2022;48(1):67–74. doi:10.1097/j.jcrs.0000000000000706
- Lopes D, Loureiro T, Carreira R, et al. Comparative evaluation of visual outcomes after bilateral implantation of an advanced or conventional monofocal intraocular lens. *Eur J Ophthalmol*. 2022;32(1):229–234. doi:10.1177/1120672121995343
- Yangzes S, Kamble N, Grewal S, Grewal SPS. Comparison of an aspheric monofocal intraocular lens with the new generation monofocal lens using defocus curve. *Indian J Ophthalmol*. 2020;68(12):3025–3029. doi:10.4103/ijo.IJO_985_20
- Unsal U, Sabur H. Comparison of new monofocal innovative and standard monofocal intraocular lens after phacoemulsification. *Int Ophthalmol*. 2021;41(1):273–282. doi:10.1007/s10792-020-01579-y
- Beltraminelli T, Rizzato A, Toniolo K, Galli A, Menghini M. Comparison of visual performances of enhanced monofocal versus standard monofocal IOLs in a mini-monovision approach. *BMC Ophthalmol*. 2023;23(1):170. doi:10.1186/s12886-023-02920-6
- de Luis Eguileor B, Martinez-Indart L, Martinez Alday N, Sacristan Eguen C, Cuadros Sanchez C. [Differences in intermediate vision: monofocal intraocular lenses vs. monofocal extended depth of focus intraocular lenses]. *Diferencias en la vision intermedia: lente intraocular monofocal vs lente intraocular monofocal de rango extendido*. *Arch Soc Esp Oftalmol*. 2020;95(11):523–527. Spanish. doi:10.1016/j.oftal.2020.06.009
- Donoso R, Torres A, Klagges J, et al. Enhanced vs conventional monofocal intraocular lens clinical results in patients with cataract: randomized clinical trial. *J Cataract Refract Surg*. 2023;49(8):818–825. doi:10.1097/j.jcrs.0000000000001224
- Gigon E, Bouthour W, Panos GD, Pajic B, Massa H. Real world outcomes of the new Tecnis Eyhance IOL. *Eur J Ophthalmol*. 2023;33(3):1390–1397. doi:10.1177/11206721221146675
- Rocha KM, Costa ED, Dodhia M, Waring GO. Tolerance to induced astigmatism with a monofocal intraocular lens designed to extend the depth of focus. *J Refract Surg*. 2023;39(4):222–228. doi:10.3928/1081597X-20230126-02
- Mencucci R, Cennamo M, Venturi D, Vignapiano R, Favuzza E. Visual outcome, optical quality, and patient satisfaction with a new monofocal IOL, enhanced for intermediate vision: preliminary results. *J Cataract Refract Surg*. 2020;46(3):378–387. doi:10.1097/j.jcrs.0000000000000061
- Kang KH, Song MY, Kim KY, Hwang KY, Kwon YA, Koh K. Visual Performance and Optical Quality after Implantation of a New Generation Monofocal Intraocular Lens. *Korean J Ophthalmol*. 2021;35(2):112–119. doi:10.3341/kjo.2020.1115
- Mencucci R, Morelli A, Cennamo M, Roszkowska AM, Favuzza E. Enhanced monofocal intraocular lenses: a retrospective, comparative study between three different models. *J Clin Med*. 2023;12(10):3588. doi:10.3390/jcm12103588
- Alio JL, D’Oria F, Toto F, et al. Retinal image quality with multifocal, EDoF, and accommodative intraocular lenses as studied by pyramidal aberrometry. *Eye Vis (Lond)*. 2021;8(1):37. doi:10.1186/s40662-021-00258-y

24. Karuppiah P, Varman NVA, Varman A, Balakumar D. Comparison of clinical outcomes of trifocal intraocular lens (AT LISA, Eyecryl SERT trifocal) versus extended depth of focus intraocular lens (Eyhance, Eyecryl SERT EDOF). *Indian J Ophthalmol.* 2022;70(8):2867–2871. doi:10.4103/ijo.IJO_2921_21
25. Goslings O, Veraart H, van de Laar-Muskens J, Pinero DP. Clinical outcomes with an aspheric monofocal and a new enhanced monofocal intraocular lens with modified optical profile. *Graefes Arch Clin Exp Ophthalmol.* 2023;261(8):2315–2326. doi:10.1007/s00417-023-06128-8
26. Abd Elghaffar Shehata M, Hosny MH, Tolba DA, Attya M. Evaluation of postoperative total ocular aberrations after bilateral implantation of monofocal IOL with extended depth of focus in phacoemulsification. *Clin Ophthalmol.* 2022;16:4257–4261. doi:10.2147/OPTH.S391355
27. Jeon YJ, Yoon Y, Kim TI, Koh K. Comparison between an intraocular lens with extended depth of focus (Tecnis Symphony ZXR00) and a new monofocal intraocular lens with enhanced intermediate vision (Tecnis Eyhance ICB00). *Asia Pac J Ophthalmol.* 2021;10(6):542–547. doi:10.1097/APO.0000000000000439
28. Blancafort Alias S, Del Campo Carrasco Z, Salvador-Miras I, et al. Exploring vision-related quality of life: a qualitative study comparing patients' experience of cataract surgery with a standard monofocal IOL and an enhanced monofocal IOL. *Clin Ophthalmol.* 2022;16:1641–1652. doi:10.2147/OPTH.S358386
29. Corbelli E, Iuliano L, Codenotti M, Fasce F, Bandello F. Comparative analysis of visual outcomes with 2 enhanced monofocal intraocular lenses. *J Cataract Refract Surg.* 2023;49(9):929–935. doi:10.1097/j.jcrs.0000000000001239
30. Lee JH, Moon SY, Chung HS, et al. Clinical outcomes of a monofocal intraocular lens with enhanced intermediate function compared with an extended depth-of-focus intraocular lens. *J Cataract Refract Surg.* 2022;48(1):61–66. doi:10.1097/j.jcrs.0000000000000710
31. Sabur H, Unsal U. Visual outcomes of non-diffractive extended-depth-of-focus and enhanced monofocal intraocular lenses: a case-control study. *Eur J Ophthalmol.* 2023;33(1):262–268. doi:10.1177/11206721221125004
32. Cinar E, Bolu H, Erbakan G, et al. Vision outcomes with a new monofocal IOL. *Int Ophthalmol.* 2021;41(2):491–498. doi:10.1007/s10792-020-01599-8
33. Park ES, Ahn H, Han SU, et al. Visual outcomes, spectacle Independence, and patient satisfaction of pseudophakic mini-monovision using a new monofocal intraocular lens. *Sci Rep.* 2022;12(1):21716. doi:10.1038/s41598-022-26315-7
34. Schallhorn SC, Teenan D, Venter JA, et al. Monovision LASIK versus presbyopia-correcting IOLs: comparison of clinical and patient-reported outcomes. *J Refract Surg.* 2017;33(11):749–758. doi:10.3928/1081597x-20170721-03
35. Reinstein DZ, Archer TJ, Srinivasan S, et al. Standard for reporting refractive outcomes of intraocular lens-based refractive surgery. *J Cataract Refract Surg.* 2017;43(4):435–439. doi:10.1016/j.jcrs.2017.04.005
36. Wan KH, Au AC, Kua WN, et al. Enhanced monofocal versus conventional monofocal intraocular lens in cataract surgery: a meta-analysis. *J Refract Surg.* 2022;38(8):538–546. doi:10.3928/1081597X-20220707-01
37. Redruello-Guerrero P, Rivera-Izquierdo M, Jimenez-Gutierrez C, Lainez-Ramos-Bossini AJ, Yela R, Lopez-Marin I. Improvement of intermediate vision with new monofocal intraocular lenses: a systematic review and meta-analysis. *Eur J Ophthalmol.* 2023;33(3):1308–1319. doi:10.1177/11206721221127075
38. Giansanti F, Dragotto F, Nicolosi C, et al. Enhancing intermediate vision in patients affected by epiretinal membrane treated by phaco-vitreotomy. *J Clin Med.* 2023;12(15):5016. doi:10.3390/jcm12155016
39. Choi SH, Lee HS, Chang IB, et al. Evaluation of a new monofocal intraocular lens in patients undergoing cataract and vitrectomy surgery for idiopathic macular hole. *Curr Eye Res.* 2023;48(10):904–910. doi:10.1080/02713683.2023.2229542

Clinical Ophthalmology

Dovepress

Publish your work in this journal

Clinical Ophthalmology is an international, peer-reviewed journal covering all subspecialties within ophthalmology. Key topics include: Optometry; Visual science; Pharmacology and drug therapy in eye diseases; Basic Sciences; Primary and Secondary eye care; Patient Safety and Quality of Care Improvements. This journal is indexed on PubMed Central and CAS, and is the official journal of The Society of Clinical Ophthalmology (SCO). The manuscript management system is completely online and includes a very quick and fair peer-review system, which is all easy to use. Visit <http://www.dovepress.com/testimonials.php> to read real quotes from published authors.

Submit your manuscript here: <https://www.dovepress.com/clinical-ophthalmology-journal>