

# UC Davis

## Dermatology Online Journal

### Title

Acral Persistent Papular Mucinosis: is it an under-diagnosed disease?

### Permalink

<https://escholarship.org/uc/item/0n04458v>

### Journal

Dermatology Online Journal, 20(3)

### Authors

Alvarez-Garrido, Helena  
Najera, Laura  
Garrido-Rios, Anastasia Alejandra  
et al.

### Publication Date

2014

### License

<https://creativecommons.org/licenses/by-nc-nd/4.0/> 4.0

Peer reviewed

## Photo Vignette

### Acral Persistent Papular Mucinosis: is it an under-diagnosed disease?

Helena Alvarez-Garrido, Laura Najera, Anastasia Alejandra Garrido-Ríos, Susana Córdoba-Guijarro, María Huerta-Brogeras, Marta Aguado-Lobo, Jesus Borbujo

Dermatology Online Journal 20 (3): 10

Hospital Universitario de Fuenlabrada, Department of Dermatology, Spain

#### Correspondence:

Helena Alvarez-Garrido  
Hospital Universitario de Fuenlabrada  
helenaalvarezgarrido@hotmail.com

## Abstract

Acral persistent papular mucinosis is a subtype of localized lichen myxedematosus. It presents as acrally located papules with a benign, but persistent course. It is a scarcely reported disease. We present a female with both the clinical and histopathological described criteria

## Introduction

Acral persistent papular mucinosis (APPM) is a type of papular mucinosis. Also known as lichen myxedematosus or scleromyxedema, this is a group of diseases is characterized by mucin deposits in skin. We can classify these diseases into clinicopathological types. The first type is a generalized/sclerodermoid form, also called scleromyxedema, with systemic manifestations. The second is a localized form without systemic involvement. There are five subtypes: discrete papular, nodular, self-healing papular mucinosis, papular mucinosis of infancy, and acral persistent papular mucinosis. Finally, the cases that don't fit any of the groups are considered as atypical forms.

APPM was first described by Rongioletti *et al* in 1986 as a new condition, [1]. Later, in 2001, it was classified as a subtype of localized lichen mixedematosus [2]. It is characterized by acrally located mucinous papules, a benign but persistent course, and an absence of systemic abnormalities [2].

To date, there are 34 reported cases in the literature which fit with the diagnostic criteria (Table 1) [1,3,4,5,6,7]. Another 6 cases have been described, but they do not meet the established criteria for APPM.

## Case synopsis

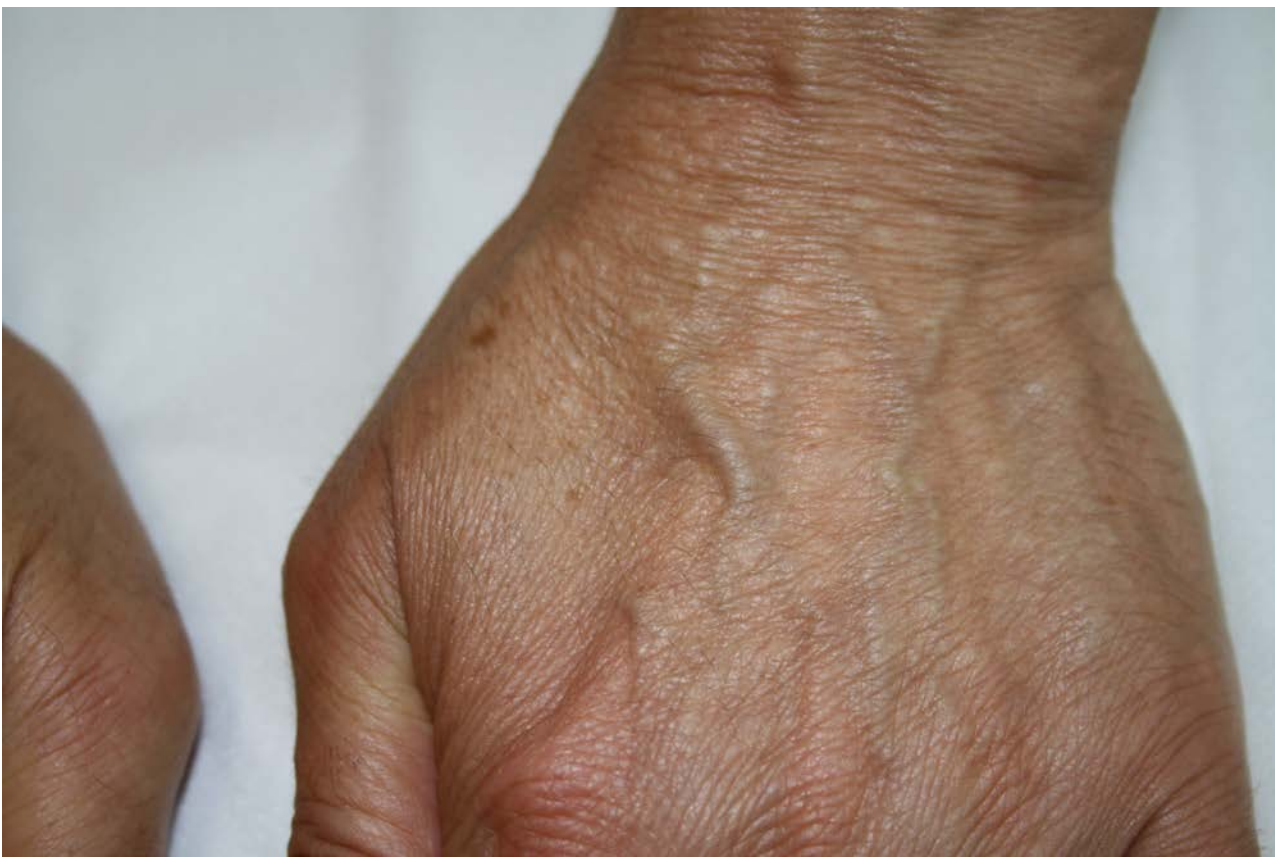A 53-year old woman presented with a one-year history of a progressive eruption of asymptomatic papules on the back of her hands, wrists, and distal forearms. Physical examination revealed multiple 2-5 mm flesh-colored to translucent papules, which were round and firm with a smooth surface (Figure 1). The skin between lesions appeared to be normal. There were no other similar lesions on the rest of the body.

Routine laboratory tests revealed no abnormalities. Thyroid studies (T3, T4, thyroid-stimulating hormone, anti-thyroid antibodies), serum protein electrophoresis, IgM, IgA, and Ig G serum levels were all normal.

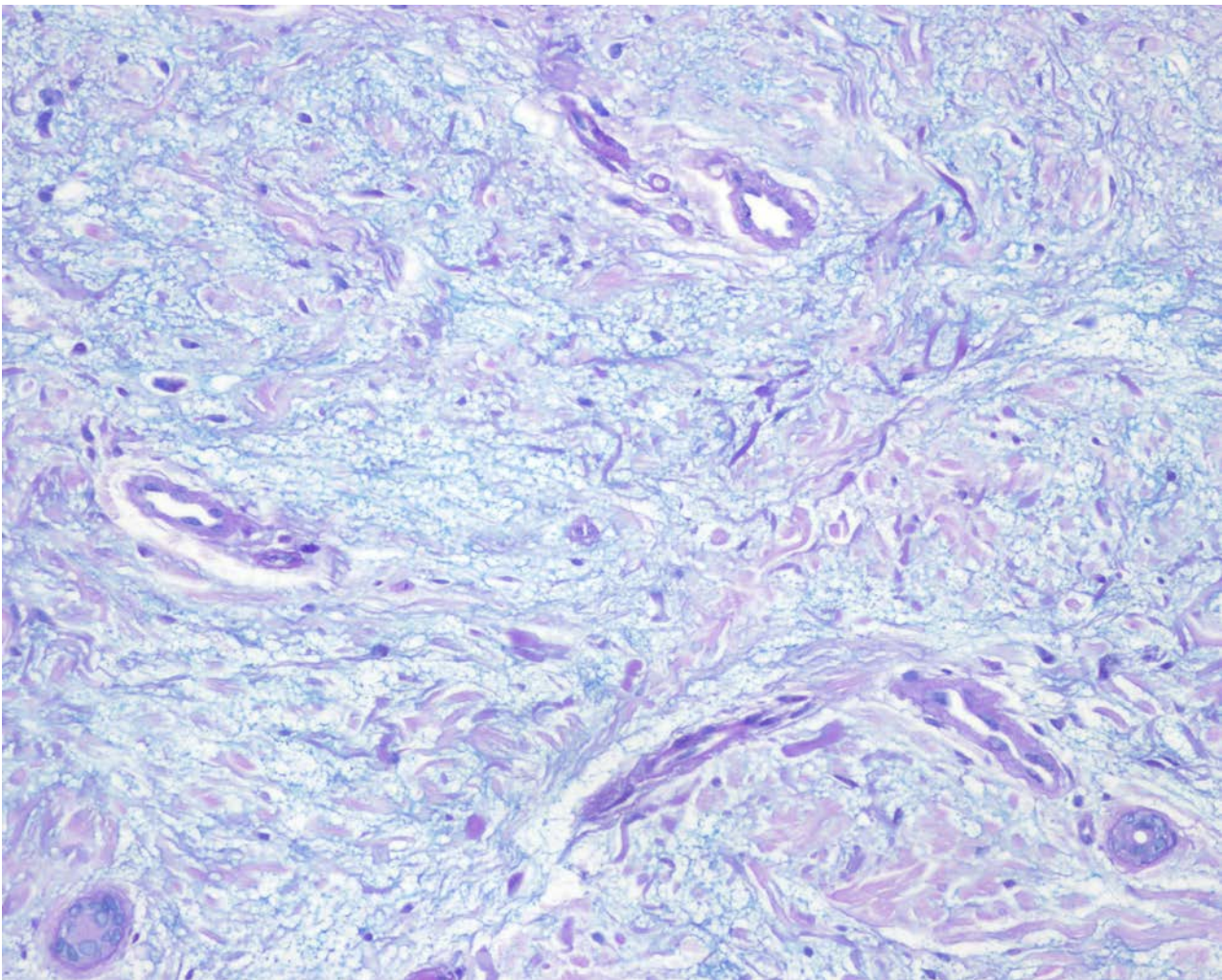
The histologic examination of one of the lesions showed a normal epidermis with a localized deposit of nodular mucin in the papillary and upper reticular dermis, sparing the deep dermis. There was increased spacing between collagen bundles, but the number of fibroblasts was not increased (Figure 2).

Our patient satisfied the diagnostic criteria of APPM (Table 1).

Because the lesions were asymptomatic and not very apparent no treatment was proposed.



**Figure 1.** Flesh-colored to translucent papules, round and firm, on the back of both hands



**Figure 2.** 40x Alcian blue. Normal epidermis with a localized deposit of nodular mucin in papillary and upper reticular dermis, sparing the deep dermis.

**Table 1: Clinical and histologic criteria of APPM [5]**

Clinical criteria	Histologic criteria
2-5 mm, few to multiple, ivory to flesh-colored papules	Focal, well-circumscribed mucin
	Mucin in papillary and mid dermis, never confined to deep reticular dermis
Persists without spontaneous resolution, may increase in number	Spared Grenz zone
Predominately female patients	Variable fibroblast proliferation, usually absent
No systemic disease overlap	
No associated gammopathy	

## Discussion

The etiology of lichen mixedematous remains unknown [3]. An over stimulation of fibroblasts has been implicated in patients with human immunodeficiency virus infection, but not in other cases [4]. In the localized form, the lesions are confined to only a few sites and mainly affects middle-aged women. It is not associated sclerotic features, paraproteinemia, systemic involvement, or thyroid disease [2]. Typically, lesions are asymptomatic, persist, and gradually increase in number [5].

It is important to distinguish APPM from the papular form of lichen myxedematosus. The latter is characterized by the presence of flesh colored translucent papules localized on the extremities and on the trunk; it is usually self-limited [2].

Histologically, it is characterized by well-circumscribed nodular mucin deposits between the collagen bundles, particularly in the superficial dermis, but also in the mid reticular dermis. Only occasionally is there an increased number of fibroblasts present. A Grenz zone is a characteristic finding. The overlying epidermis is normal [5].

Treatment is not required; it is generally a cosmetic concern. Destructive therapies such as liquid nitrogen, carbon dioxide laser, or electrodesiccation [6] are not recommended because they can leave scars [3]. Topical corticosteroids, tacrolimus [7], and pimecrolimus have been used with some success [3,8], although more studies are required to show the benefit of various treatments [5].

### Learning points

1. APPM is a localized form of lichen myxedematosus (also called papular mucinosis).
2. It is generally underdiagnosed
3. No association with systemic disease or gammopathy is present.
4. Histologically, it is characterized by the presence of mucin in the papillary and mid dermis and by variable fibroblast proliferation.
5. It is persistent and asymptomatic.
6. Treatment is not required.

## References

1. Rongioletti F, Rebora A, Crovato F. Acral persistent papular mucinosis: a new entity. *Arch Dermatol* 1986; 122: 1237-9. [PMID:3777968]
2. Rongioletti F, Rebora A. Updated classification of papular mucinosis, lichen myxedematosus, and scleromyxedema. *J Am Acad Dermatol* 2001; 44: 273-81. [PMID: 11174386]
3. Luo D, Wu L, Liu J, Zhang H. Acral persistent papular mucinosis: a case report and literature review. *J Dtsch Dermatol Ges* 2011 9(5): 354-9. [PMID: 21122068]
4. Callaly E, Mulligan N, Powell F. Multiple painless papules on the wrists. *Arch Dermatol* 2007; 143: 791,6. [PMID:17576949]
5. Harris JE, Purcell SM, Griffin TD. Acral persistent papular mucinosis. *J Am Acad Dermatol* 2004; 51: 982-8. [PMID:15583597]
6. André Jorge F, Mimura Cortez T, Guadalini Mendes F, Esther Alencar Marques M, Amante Miot H. Treatment of acral persistent papular mucinosis with electrocoagulation. *J Cutan Med Surg* 2011; 15(4): 227-9. [PMID:21781629]
7. Rongioletti F, Zaccaria E, Cozzani E, Parodi A. Treatment of localized lichen myxedematosus of discrete type with tacrolimus ointment. *J Am Acad Dermatol* 2008; 58: 530-2. [PMID:18280368]

8. Rongioletti F. Lichen myxedematosus (papular mucinosis): new concepts and perspectives for an old disease. *Semin Cutan Med Surg* 2006; 25: 100-4. [PMID:16908401]