

# UC Davis

## UC Davis Previously Published Works

### Title

Preliminary report of postoperative complications of phacoemulsification in Pugs: A multicenter retrospective study of 32 cases

### Permalink

<https://escholarship.org/uc/item/0nj3p3f0>

### Journal

Veterinary Ophthalmology, 23(3)

### ISSN

1463-5216

### Authors

Boss, Christine  
La Croix, Noelle  
Moore, Phillip A  
et al.

### Publication Date

2020-05-01







### DOI

10.1111/vop.12739

Peer reviewed

## ORIGINAL ARTICLE

# Preliminary report of postoperative complications of phacoemulsification in Pugs: A multicenter retrospective study of 32 cases

Christine Boss<sup>1</sup>  | Noelle La Croix<sup>1</sup> | Phillip A. Moore<sup>2</sup> | David A. Wilkie<sup>3</sup>  | Federica Maggio<sup>4</sup>  | Kenneth Tomo Wiggins<sup>5</sup> | David J. Maggs<sup>5</sup>  | Kevin Kaiser<sup>6</sup> | John S. Sapienza<sup>7</sup>  | Kay Kim<sup>7</sup> | Rachel Strauss<sup>7</sup> | Alexandra van der Woerd<sup>8</sup>  | Gretchen Schmidt<sup>9</sup>

<sup>1</sup>The Veterinary Medical Center of Long Island, West Islip, NY, USA

<sup>2</sup>Auburn University, Auburn, AL, USA

<sup>3</sup>The Ohio State University, Columbus, OH, USA

<sup>4</sup>Tufts V.E.T.S., Walpole, MA, USA

<sup>5</sup>School of Veterinary Medicine, University of California-Davis, Davis, CA, USA

<sup>6</sup>Animal Eye Clinic of Spokane, Spokane, WA, USA

<sup>7</sup>Long Island Veterinary Specialists, Plainview, NY, USA

<sup>8</sup>Animal Medical Center, New York City, NY, USA

<sup>9</sup>Animal Eye Clinic, Denmark, WI, USA

## Correspondence

Christine Boss, College of Veterinary Medicine, Small Animal Hospital, University of Florida, 2089 SW 16<sup>th</sup> Ave, Gainesville, FL 32608, USA.  
Email: c.boss@ufl.edu

## Abstract

**Objective:** To compare complication rates and visual outcomes following phacoemulsification in Pugs versus dogs of other breeds.

**Animals studied:** Thirty-two pure-bred Pugs (55 eyes) and 32 dogs of other breeds (56 eyes) undergoing phacoemulsification.

**Procedures:** Multi-institutional retrospective medical record review of perioperative factors, postoperative complications, and visual outcomes. The reference population of dogs of varying breeds included surgical cases following each Pug case at the same institutions. Perioperative risk factors and postoperative complication rates were compared between the two populations.

**Results:** Pigmentary keratitis and diabetes mellitus were the most common preoperative comorbidities, found in 75% ( $P < .001$ ) and 72% ( $P = .12$ ) of Pugs, respectively. No perioperative factors were significantly associated with postoperative complications in Pugs. Postoperative complication rates were similar between groups; however, the most common complication in Pugs was corneal ulceration (15% of operated eyes), whereas glaucoma was most common in the reference population (13% of operated eyes). Three months postoperatively, vision was preserved in 91% of eyes of Pugs (50/55) and 95% of the reference population (53/56). One year postoperatively, 80% (32/40) of Pug eyes and 82% (28/34) of eyes in the reference population remained sighted.

**Conclusions:** Comorbidities and complications of cataract surgery in Pugs of this study demonstrate a predisposition for corneal disease. This highlights the importance of preoperative evaluation of factors associated with PK and corneal clarity, and postoperative monitoring for corneal ulceration in this breed.

## KEYWORDS

canine, cataract, corneal ulceration, glaucoma, pigmentary keratitis

## 1 | INTRODUCTION

Complications of cataract removal by means of phacoemulsification in the dog include, but are not limited to, corneal endothelial cell damage, corneal ulceration, endophthalmitis, glaucoma, incision dehiscence, lens capsule opacification, lens fiber regrowth, postoperative ocular hypertension (POH), pre-iridal fibrovascular membranes, prosthetic intraocular lens (IOL) malpositioning, retinal detachment, and uveitis.<sup>1-7</sup> Numerous studies have demonstrated a relationship between dog breed and postoperative complications of phacoemulsification, with glaucoma, retinal detachment, and corneal ulceration commonly reported.<sup>4,6,8-16</sup> Clinical and histologic studies of canine eyes that have undergone phacoemulsification suggest an increased risk of postoperative glaucoma in breeds such as Boston Terriers, Cocker Spaniels, Shih Tzus, Labrador Retrievers, Poodles, Bichon Frise, Rhodesian Ridgebacks, Australian Cattle Dogs, Jack Russell Terriers, and Parson Russell Terriers.<sup>6,8-11,15,16</sup> There is conflicting evidence as to whether the Bichon Frise is predisposed to postoperative retinal detachment.<sup>6,10,12-14,17</sup> Causes for these breed-associated postoperative complications are likely multifactorial. However, some authors suggest inflammation as being one of the main general factors that can lead to postoperative glaucoma,<sup>6,10,16</sup> though the preoperative presence of goniodysgenesis has also been suggested as a factor in Cocker Spaniels.<sup>10</sup>

Postoperative corneal ulceration is of particular concern in brachycephalic breeds due to facial conformation, decreased corneal sensitivity, and predisposition to keratoconjunctivitis sicca (KCS).<sup>10,18-20</sup> Pugs are a popular brachycephalic breed and are predisposed to corneal diseases such as pigmentary keratitis (PK), KCS, and corneal ulceration.<sup>20-24</sup>

The objective of this study was to investigate the incidence of common postoperative complications, the association between preoperative findings and postoperative complications, and the postoperative visual success rate of phacoemulsification in Pugs, relative to a cohort of dogs of breeds other than Pugs. To the authors' knowledge, this is the first study reviewing complications following phacoemulsification in this breed. This information was intended to support patient selection, preoperative treatment recommendations, and postoperative monitoring considerations, and to establish the overall prognosis following phacoemulsification in Pugs.

## 2 | MATERIALS AND METHODS

Medical records were reviewed at nine academic and privately owned veterinary hospitals, including The Veterinary Medical Center of Long Island, West Islip, New York; Auburn University College of Veterinary Medicine, Auburn, Alabama; The Ohio State University College

of Veterinary Medicine, Columbus, Ohio; Tufts VETS, Walpole, Massachusetts; The University of California, Davis School of Veterinary Medicine, Davis, California; Animal Eye Clinic of Spokane, Spokane, Washington; Long Island Veterinary Specialists, Plainview, New York; The Animal Medical Center, New York, New York; and Animal Eye Clinic, Denmark, Wisconsin. Pugs undergoing phacoemulsification between 2005 and 2016 at these institutions were included in this study. A reference population was then formed by inclusion of the next dog, of a breed other than the Pug, undergoing phacoemulsification at the same institution. All dogs within the study and reference populations had undergone routine phacoemulsification in one or both eyes using a one- or two-handed technique and had been examined for at least three months postoperatively. All dogs had an initial examination, preoperative diagnostic testing, phacoemulsification, and follow-up care performed by, or under the supervision of, a Diplomate of the American College of Veterinary Ophthalmologists (ACVO).

For both populations, information collected from the medical record at initial presentation included age, sex, breed, diabetic status, duration of cataract, stage of cataract [incipient (I), immature (IM), mature (M), or hypermature (HM)], percentage of corneal surface with pigment (0%, 1%-10%, 11%-25%, or 26%-50%), and grade of aqueous flare (0 (absent), 0.5 (trace), 1, 2, or 3). In addition, Schirmer tear test-1 (STT-1) values, corneal fluorescein staining, and intraocular pressure (IOP) obtained via rebound or applanation tonometry, as well as whether a prosthetic IOL was implanted at the time of surgery, were also recorded.

Throughout the postoperative period, the following findings were recorded for both populations: (a) STT-1  $\leq 10$  mm/min noted at least 24 hours following surgery, (b) corneal ulceration acquired at least 24 hours following surgery, (c) IOP  $> 25$  mm Hg persisting at least 24 hours postoperatively, (d) retinal detachment (as diagnosed by fundoscopic examination or ocular ultrasonography), and (e) vision at final re-examination as well as likely causes and timing of vision loss, if applicable. Duration of postoperative follow-up was recorded for all dogs.

For both populations, commercial software was used to perform descriptive (SPSS<sup>®</sup>, Version 25, IBM Corp.) and inferential (SAS<sup>®</sup>, Version 9.4, SAS Institute Inc) statistical analyses. In patients undergoing bilateral cataract surgery, individual eyes were treated as dependent samples. Statistical methods were selected contingent upon independent or dependent sampling of specific findings. During analysis, independently sampled quantitative preoperative findings were compared between Pugs and the reference population using a two-sample independent *t* test. Independently sampled categorical preoperative findings were compared in the two populations using a Fisher's exact test. Dependently sampled perioperative findings in each population were compared,

using a generalized linear mixed model (GLMM) for categorical findings, and linear mixed effects model for quantitative values. Logistic regression, a generalized linear mixed model, and likelihood ratios were used to investigate relationships

between preoperative findings and postoperative complications in Pugs. Logistic regression and likelihood ratios were performed for right and left eyes independently, and results were compared.

**TABLE 1** Preoperative findings in 32 Pugs and 32 dogs of a reference population comprised of alternate breeds

Preoperative findings		Number (%) of cases		P-value
		Pugs	Reference Population	
Diabetes mellitus	Diabetic	23 (72)	16 (50)	.12 <sup>a</sup>
	Nondiabetic	9 (28)	16 (50)	
Age (y)	<5	2 (6)	4 (13)	.2 <sup>a</sup>
	5-10	22 (69)	15 (47)	
	>10	8 (25)	13 (41)	
Sex (MC, M, FS)	Castrated male	18 (56)	12 (38)	.21 <sup>a</sup>
	Intact male	2 (6)	1 (3)	
	Spayed female	12 (38)	19 (59)	
Number (%) of operated eyes				
Cataract duration (mo)	<1	12 (22)	15 (27)	.39 <sup>c</sup>
	1-5	18 (33)	15 (27)	
	6-12	6 (11)	4 (7)	
	>12	9 (16)	6 (11)	
	Unknown	10 (18)	16 (29)	
Pigmentary keratopathy (% corneal surface area)	0	14 (25)	54 (96)	<b>&lt;.01<sup>b</sup></b>
	1-10	8 (15)	0	
	11-25	23 (42)	2 (4)	
	26-50	8 (15)	0	
	Unknown	2 (4)	0	
Schirmer tear test result (mm/min)	≤10	1 (2)	3 (5)	.57 <sup>b</sup>
	>10	54 (98)	53 (95)	
Corneal fluorescein retention	Positive	2 (4)	1 (2)	.84 <sup>b</sup>
	Negative	53 (96)	55 (98)	
Intraocular pressure (mm Hg)	<10	21 (38)	23 (41)	.42 <sup>c</sup>
	10-14	25 (46)	22 (39)	
	15-25	8 (15)	7 (13)	
	Unknown	1 (2)	4 (7)	
Aqueous flare (grade)	Absent	49 (89)	47 (84)	.54 <sup>b</sup>
	Trace	0	3 (5)	
	1+	3 (6)	3 (5)	
	2+	1 (2)	1 (2)	
	3+	2 (4)	2 (4)	
Cataract maturity (stage)	Immature	9 (16)	20 (36)	.57 <sup>b</sup>
	Mature	35 (64)	29 (52)	
	Hyper mature	11 (20)	7 (13)	
IOL placement	Implanted	53 (96)	51 (91)	.42 <sup>b</sup>
	Aphakic	2 (4)	5 (9)	

Note: All dogs underwent phacoemulsification in at least one eye.

P-value was obtained by Fisher's exact test (a), generalized linear mixed model (b), or linear mixed effects models (c).

Statistically significant ( $P < .05$ ) associations are shown in bold.

**TABLE 2** Results of statistical testing (*P*-values) assessing associations between preoperative risk factors and postoperative complications in Pugs

Preoperative findings/risk factors	Postoperative complications				
	Low STT	Corneal Ulcer	Glaucoma	Retinal Detachment	Vision Loss
Diabetes mellitus (Y, N)	0.31 <sup>a</sup>	0.13 <sup>a</sup>	<b>&lt;0.01<sup>a</sup></b>	0.2074 <sup>a</sup>	0.08 <sup>a</sup>
Age (y)	0.34 <sup>a</sup>	0.3 <sup>a</sup>	0.18 <sup>a</sup>	0.5994 <sup>a</sup>	<b>0.04<sup>a</sup></b>
Sex (MC = 1, M = 2, FS = 3)	0.71 <sup>a</sup>	0.43 <sup>a</sup>	0.58 <sup>b</sup> 0.6 <sup>c</sup>	0.7067 <sup>a</sup>	0.35 <sup>a</sup>
Cataract duration (mo)	0.1 <sup>a</sup>	0.59 <sup>a</sup>	0.15 <sup>a</sup>	0.4744 <sup>a</sup>	0.45 <sup>a</sup>
Pigmentary keratopathy (Y, N)	0.4 <sup>a</sup>	0.92 <sup>a</sup>	0.08 <sup>a</sup>	0.21 <sup>a</sup>	0.79 <sup>a</sup>
Low STT result (≤10 mm/min)	0.58 <sup>b</sup> NC <sup>c</sup>	0.36 <sup>b</sup> 0.59 <sup>c</sup>	0.42 <sup>b</sup> 0.57 <sup>c</sup>	0.52 <sup>b</sup> 0.71 <sup>c</sup>	0.3 <sup>b</sup> 0.47 <sup>c</sup>
Corneal fluorescein retention (Y, N)	0.7 <sup>b</sup> NC <sup>c</sup>	0.45 <sup>a</sup>	0.37 <sup>b</sup> 0.53 <sup>c</sup>	0.51 <sup>b</sup> 0.68 <sup>c</sup>	0.27 <sup>b</sup> 0.46 <sup>c</sup>
IOP (mmHg)	0.92 <sup>a</sup>	0.3719 <sup>a</sup>	0.41 <sup>a</sup>	0.79 <sup>a</sup>	0.33 <sup>a</sup>
Aqueous flare (0, 0.5, 1, 2, 3)	0.28 <sup>b</sup> 0.32 <sup>c</sup>	0.27 <sup>a</sup>	0.15 <sup>b</sup> 0.12 <sup>c</sup>	0.22 <sup>b</sup> 0.29 <sup>c</sup>	0.42 <sup>a</sup>
Cataract maturity (I = 1, IM = 2, M = 3, HM = 4)	0.54 <sup>a</sup>	<b>0.04<sup>a</sup></b>	0.12 <sup>a</sup>	0.98 <sup>a</sup>	0.31 <sup>a</sup>
IOL placement (Y, N)	0.36 <sup>a</sup>	0.34 <sup>a</sup>	0.76 <sup>a</sup>	0.31 <sup>b</sup> 0.46 <sup>c</sup>	0.92 <sup>b</sup> 0.89 <sup>c</sup>

Note: Statistically significant ( $P < .05$ ) associations are shown in bold.

Abbreviations: FS, spayed female; HM, hypermature; IM, immature; M, intact male; M, mature; MC, castrated male; NC, noncalculable; N, No; Y, Yes.

Due to the dependent sampling of some data, eyes were tested independently using the following statistical models: a generalized linear mixed model including both right and left eyes (a), logistic regression and likelihood ratios for one eye per dog including unilateral cases and the left eyes of bilateral cases (b), or logistic regression and likelihood ratios for one eye per dog, including unilateral cases and the right eyes of bilateral cases (c).

### 3 | RESULTS

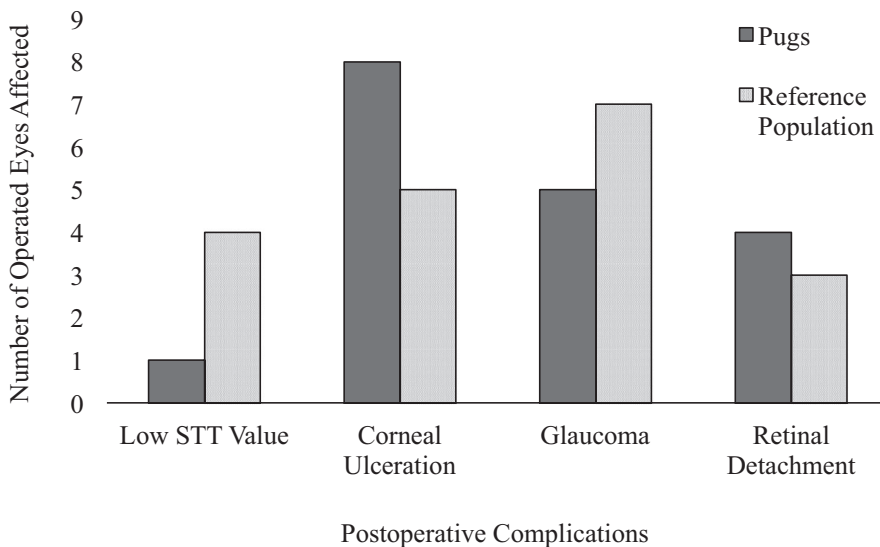
A total of 64 dogs were included in this study, including 32 pure-bred Pugs (64 eyes) and 32 dogs (63 eyes) of alternate breeds. Breeds represented in the reference population included mixed-breed dogs (6 dogs), Maltese and Maltese crosses (5), Poodle and Poodle crosses (3), Australian Shepherd and Australian Shepherd crosses (2) Yorkshire Terrier (2), and one each of Bichon Frise, Border Collie cross, Boston Terrier, Cocker Spaniel, German Shepherd cross, Irish Setter, Italian Greyhound, Miniature Pinscher, Miniature Schnauzer, Pomeranian, Portuguese Water Dog, Shih Tzu, Toy Fox Terrier, and West Highland White Terrier. Pugs had a median (range) age of 8.4 years (4–12.7 years) at presentation, and dogs in the reference population had a median (range) age of 10 years (2.2–14.3 years). There was no significant difference in this parameter between the two groups ( $P = .2$ ). The Pugs included 18 castrated males, 2 intact males, and 12 spayed females, while the reference population consisted of 12 castrated males, 1 intact male, and 19 spayed females ( $P = .21$ ). The prevalence of diabetes mellitus was similar among Pugs in 72% (23/32) and the reference population in 50% (16/32) ( $P = .12$ ).

Nine Pugs underwent unilateral phacoemulsification due to one of these findings in the nonoperated eye: retinal

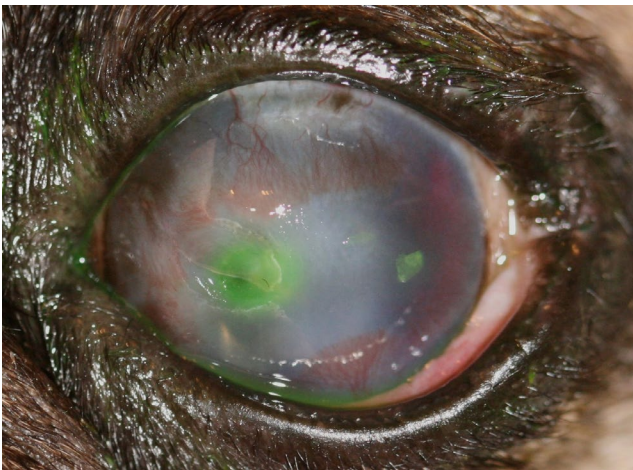
detachment ( $n = 2$ ), complete corneal pigmentation ( $n = 1$ ), normal lens ( $n = 1$ ), incipient cataract ( $n = 1$ ), lens luxation requiring extracapsular lens extraction ( $n = 1$ ), lens subluxation ( $n = 1$ ), phacoclastic uveitis with secondary glaucoma ( $n = 1$ ), or for a reason not listed ( $n = 1$ ). In the reference population, seven eyes did not undergo phacoemulsification due to intraocular/orbital neoplasia ( $n = 2$ ), normal lens ( $n = 2$ ), incipient cataract ( $n = 1$ ), glaucoma ( $n = 1$ ), or retinal detachment ( $n = 1$ ). Thus, there were 55 operated Pug eyes and 56 operated eyes in the reference population.

The predominant ophthalmic comorbidity in operated eyes of Pugs was PK, which occurred in a significantly greater proportion of Pug eyes (41/55) than eyes in the reference population (2/56) ( $P < .01$ ). The percentage of the corneal surface affected by PK in operated Pug eyes was 1%–10% in 15% (8/55) eyes, 11%–25% in 42% (23/55) eyes, and 26%–50% in 18% (10/55) eyes; PK was absent in 25% (14/55) of operated eyes. Other preoperative findings were similar between groups and are summarized in Table 1. In the Pug population, no perioperative finding (including PK) was associated with increased rate of any postoperative complication analyzed (Table 2).

During the 3-month postoperative period, specific postoperative complication rates in Pugs were as follows: corneal



**FIGURE 1** Prevalence of complications within 3 mo immediately following phacoemulsification in 32 Pugs (55 eyes) and a reference population comprising 32 dogs of alternate breeds (56 eyes). No significant differences were detected between the two populations for any complication. STT = Schirmer tear test-1



**FIGURE 2** Photograph of a Pug 3 y after phacoemulsification surgery. Fluorescein stain has been applied. A paraxial deep stromal corneal ulcer is present along with 360° perilimbal corneal vascularization, diffuse corneal edema, and corneal pigmentation involving <25% of the nasal aspect of the corneal limbus, and the superior limbus adjacent to a fibrotic corneal incision

ulceration 15% (8/55), glaucoma 9% (5/55), retinal detachment 7% (4/55), and low STT-1 values 2% (1/55). Postoperative complications and their frequency in the reference population included glaucoma 13% (7/56), corneal ulceration 9% (5/56), low STT-1 values 7% (4/56), and retinal detachment 5% (3/56). The prevalence of complications in Pugs and the reference population are shown in Figure 1. There were no significant differences between Pugs and the reference population in postoperative frequency of low STT-1 values ( $P = .16$ ), corneal ulceration ( $P = .46$ ), glaucoma ( $P = .54$ ), retinal detachment ( $P = .67$ ), or vision loss ( $P = .46$ ).

Although duration of follow-up varied for each dog, median (range) duration of follow-up after phacoemulsification for Pugs of 18 months (3-60 months) was not significantly

different ( $P = .27$ ) than that for the reference population in 15 months (3-48 months). Long-term follow-up information was not available for all subjects of this retrospective study, given that some animals failed to return for re-examinations. The frequency of re-evaluations (ie, the time between one re-evaluation and the next) varied widely between centers. However, all dogs were examined 3 months following phacoemulsification, at which time 91% (50/55) of operated Pug eyes and 95% (53/56) of eyes in the reference population were sighted ( $P = .49$ ). One year following phacoemulsification, 80% (32/40) of operated Pug eyes available for follow-up and 82% (28/34) operated eyes available for follow-up in the reference population were sighted ( $P = 1$ ). At their final postoperative examination, 76% (42/55) of operated eyes in Pugs and 84% (47/56) of operated eyes in the reference population were sighted ( $P = .46$ ). Loss of vision in Pug eyes postoperatively was due to at least one or more of the following causes: complicated corneal ulceration (5), retinal detachment (5), glaucoma (4), exacerbation of PK (2), and/or hyphema (1). Figure 2 shows a dog with postoperative PK and a deep stromal ulcer. In the reference population, loss of vision was a result of at least one or more of the following causes: glaucoma (5), retinal detachment (3), and/or infected corneal ulceration (3).

## 4 | DISCUSSION

Providing a prognosis for long-term vision restoration following cataract surgery in the dog is dependent on multiple preoperative factors including breed.<sup>6,10-14,25</sup> The popularity of brachycephalic breeds is increasing,<sup>22,26,27</sup> which has simulated a widespread discussion of breed-related health priorities and animal welfare issues throughout several European countries.<sup>27,28</sup> Selective breeding of Pugs for prominent eyes has resulted in a combination of anatomical abnormalities



including shallow orbits, laxity of lateral canthal structures, macroblepharon, and lagophthalmos.<sup>20,29,30</sup> Secondary corneal diseases found in this breed include exposure keratitis, corneal ulceration, KCS, and PK.<sup>20-22</sup> Each of these anatomic features and diseases could reasonably be expected to place Pugs at increased risk of certain complications following phacoemulsification.

Although results of the present study suggest that Pugs were not at statistically increased risk of postoperative complications when compared to the reference population, the predominant postoperative complication in Pugs and the reference population differed. The commonest and most serious postoperative complication in the reference population of the present study was glaucoma, and it was the most important cause of vision loss this group of dogs. Similar results have been reported previously in other studies with mixed populations of dogs.<sup>3,6</sup> By contrast, the commonest postoperative complication in Pugs was corneal ulceration. This was a leading cause of vision loss in this group, where complicated ulceration accounted for an important percentage of the cases with blindness. This is not surprising as brachycephalic dogs, generally, and Pugs, specifically, are at increased risk of corneal ulcerative disease.<sup>27</sup> Taken together, findings from the present and previous studies demonstrate the need for close perioperative monitoring of corneal health and postoperative measures in this breed.

In the present study, significantly more eyes of Pugs than eyes of dogs in the reference population were affected by PK. The overall prevalence of PK in operated Pug eyes in the present study (75%) was consistent with previously reported rates of 70%-82% in the breed.<sup>21,22</sup> Concurrent keratitis, progression of corneal pigmentation, and concurrent treatments for PK were not consistently reported in medical records for dogs in the present study; therefore, this information was not assessed. However, one Pug lost vision due to progression of corneal pigmentation in both eyes. Further research is warranted to assess changes in corneal pigmentation following ocular surgery. The degree of preoperative corneal pigmentation also determines whether phacoemulsification is possible. In the population of Pugs described here, the majority of operated eyes had either clear corneas or corneal pigmentation occupying less than 25% of the corneal surface. This, along with the low prevalence of preoperative KCS and corneal ulceration, likely represents a selection bias by surgeons. Therefore, our findings may not be representative of Pugs with pre-existing conditions such as excessive corneal pigmentation or KCS.

Pugs are also reported to be predisposed to the development of diabetes mellitus.<sup>23</sup> Given the association of this endocrinopathy with cataract development, it is therefore not surprising that a large proportion of Pugs in the present study were also affected by diabetes. Reduced

corneal sensitivity, secondary KCS, corneal ulceration, and delayed corneal healing are also recognized in diabetic patients.<sup>31-34</sup> However, no preoperative findings in the present study, including diabetes mellitus, were associated with increased risk of postoperative complications in Pugs.

This study has the flaws inherent to a retrospective study design and other multicentre studies. Intraoperative factors previously documented to contribute to surgical outcome include prosthetic IOL placement and variable proficiencies and techniques of surgeons.<sup>4</sup> Although prosthetic IOLs were placed in the majority of dogs in this study, there were limited data available in the medical records regarding other potentially important intraoperative factors. Detailed information about the phacoemulsification equipment used, overall surgical time, size, fit and type of IOLs, intraoperative complications, surgical experience, and perioperative IOP monitoring and treatments were not available or were varied between centers and/or surgeons. Moreover, variability of surgical skills between surgeons and centers in this study was a confounding feature. Data were produced by a large number of surgeons with varied surgical experience. Also, training centers probably involved multiple surgeons in different steps of a single surgery even if not clearly indicated in the medical record. However, the authors feel the multicenter nature of our data could serve to reflect overall surgical outcomes in the United States.

Reported success rates for routine canine phacoemulsification in the United States, and the means of calculating these, have varied widely over the last 25 years.<sup>6,35,36</sup> Sigle et al<sup>6</sup> reported a success rate of 95.5%, 6 to 12 months following cataract surgery, and Klein et al<sup>35</sup> reported a 94% success rate 6 months postoperatively. Surveyed clients in another study reported satisfaction with the surgical outcomes in approximately 81% of dogs at a median follow-up time of 12 months following phacoemulsification.<sup>37</sup> Earlier studies report lower success rates (82 to 84%).<sup>38,39</sup> In a recent publication by the Western College of Veterinary Medicine, overall success rate was 79% with a mean follow-up time of 2.3 years.<sup>1</sup> In the populations presented in the current study, success rates at the 3-month and 1-year follow-ups were similar to those recently reported in the United States through a variety of studies.<sup>1,6,35-37</sup> Although the success rates at the previously mentioned time-points in Pugs were not significantly different than those for the reference population, the success rate for vision in Pugs on last re-examination was lower than the reference population and previously reported rates for the general US population.<sup>1,6,35-37</sup> To know whether the success rate after cataract surgery in Pugs drops at the same rate as in the general, mixed, canine population, a prospective study with large groups of animals that have the same follow-up time and low number of variables is needed.

## 5 | CONCLUSIONS

Significant differences in complication rates following cataract surgery in Pugs and the reference population were not noted in the present study. However, the most prevalent complications and cause of vision loss in operated Pug eyes in this study (ie, corneal ulceration) did differ from that for the reference population (ie, glaucoma). Well-established breed predilections for corneal disease in Pugs, as well as the results of this study, demonstrate the importance of preoperative selection of Pugs with adequate corneal health and close postoperative monitoring for corneal disease following phacoemulsification.

### ACKNOWLEDGMENTS

Funding for this study was graciously provided by The Veterinary Medical Center of Long Island and Auburn University College of Veterinary Medicine. We gratefully acknowledge consulting statistician, Deborah Keys, PhD, for detailed analysis of our data. We also thank Jay Wayne, PhD, for his critical commentary and editorial revisions.

### ORCID

Christine Boss  <https://orcid.org/0000-0003-0554-3365>

David A. Wilkie  <https://orcid.org/0000-0002-4237-0371>

Federica Maggio  <https://orcid.org/0000-0001-5516-4166>

David J. Maggs  <https://orcid.org/0000-0001-6537-4335>

John S. Sapienza  <https://orcid.org/0000-0003-3377-1015>

Alexandra van der Woerd  <https://orcid.org/0000-0002-0608-4503>

### REFERENCES

- Lim C, Bakker SC, Waldner CL, et al. Cataracts in 44 dogs (77 eyes): A comparison of outcomes for no treatment, topical medical management, or phacoemulsification with intraocular lens implantation. *Can Vet J*. 2011;52:283-288.
- Davidson M, Nasisse MP, Jamieson VE, et al. Phacoemulsification and intraocular lens implantation: a study of surgical results in 182 dogs. *Progr Vet Comp Ophthalmol*. 1991;1:233-238.
- Moore D, McLellan GJ, Dubielzig RR. A study of the morphology of canine eyes enucleated or eviscerated due to complications following phacoemulsification. *Vet Ophthalmol*. 2003;6:219-226.
- Biros D, Gelatt KN, Brooks DE, et al. Development of glaucoma after cataract surgery in dogs: 220 cases (1987–1998). *J Am Vet Med Assoc*. 2000;216:1780-1786.
- Chahory S, Clerc B, Guez J, et al. Intraocular pressure development after cataract surgery: a prospective study in 50 dogs (1998–2000). *Vet Ophthalmol*. 2003;6:105-117.
- Sigle K, Nasisse MP. Long-term complications after phacoemulsification for cataract removal in dogs: 172 cases (1995–2002). *J Am Vet Med Assoc*. 2006;228:74-79.
- Smith P, Brooks DE, Lazarus JA, et al. Ocular hypertension following cataract surgery in dogs: 139 cases (1992–1993). *J Am Med Assoc*. 1996;209:105-111.
- Foote B, Peders SL, Welihozkiy A, et al. Retinal detachment and glaucoma in the Boston Terrier and Shih Tzu following phacoemulsification (135 patients): 2000–2014. *Vet Ophthalmol*. 2017;1–9.
- Newbold G, Kelch WJ, Chen T, et al. Phacoemulsification outcomes in Boston terriers as compared to non-Boston terriers: a retrospective study (2002–2015). *Vet Ophthalmol*. 2018;21(4):353–361.
- Scott E, Esson DW, Fritz KJ, et al. Major breed distribution of canine patients enucleated or eviscerated due to glaucoma following routine cataract surgery as well as common histopathologic findings within enucleated globes. *Vet Ophthalmol*. 2013;16:64-72.
- Moeller E, Blocker T, Esson D, et al. Postoperative glaucoma in the Labrador Retriever: incidence, risk factors, and visual outcome following routine phacoemulsification. *Vet Ophthalmol*. 2011;14:385-394.
- Gelatt K, Wallace MR, Andrew SE, et al. Cataracts in the Bichon Frise. *Vet Ophthalmol*. 2003;6:3-9.
- Braus B, Rhodes M, Featherstone HJ, et al. Cataracts are not associated with retinal detachment in the Bichon Frise in the UK—a retrospective study of preoperative findings and outcomes in 40 eyes. *Vet Ophthalmol*. 2012;15:98-101.
- Schmidt G, Vainisi SJ. Retrospective study of prophylactic random transscleral retinopexy in the Bichon Frise with cataract. *Vet Ophthalmol*. 2004;7:307-310.
- Lannek E, Miller PE. Development of glaucoma after phacoemulsification for removal of cataract in dogs: 22 cases (1987–1997). *J Am Vet Med Assoc*. 2001;218:70-76.
- Johnsen D, Maggs DJ. Evaluation of risk factors for development of secondary glaucoma in dogs: 156 cases (1999–2004). *J Am Vet Med Assoc*. 2006;229:1270-1274.
- Pryor S, Bentley E, McLellan GJ, et al. Retinal detachment post-phacoemulsification in Bichon Frises: a retrospective study of 54 dogs. *Vet Ophthalmol*. 2016;19:373-378.
- Kafarnik C, Fritsche J, Reese S. Corneal innervation in mesocephalic and brachycephalic dogs and cats: assessment using in vivo confocal microscopy. *Vet Ophthalmol*. 2008;11:363-367.
- Sanchez R, Innocent G, Mould J, et al. Canine keratoconjunctivitis sicca: disease trends in a review of 229 cases. *J Small Anim Pract*. 2006;48:1-9.
- Packer R, Hendricks A, Burn CC. Impact of facial conformation on canine health: corneal ulceration. *PLoS One*. 2015;10:1-13.
- Krecny M, Tichy A, Rushton J, et al. A retrospective survey of ocular abnormalities in pugs: 130 cases. *J Small Anim Pract*. 2015;56:96-102.
- Labelle A, Dresser CB, Hamor RE, et al. Characteristics of, prevalence of, and risk factors for corneal pigmentation (pigmentary keratopathy) in Pugs. *J Am Vet Med Assoc*. 2013;243:667-674.
- Hess R, Kass PH, Ward CR. Breed distribution of dogs with diabetes mellitus admitted to a tertiary care facility. *J Am Vet Med Assoc*. 2000;216:1414-1421.
- Vallone L, Enders AM, Mohammed HO, et al. In vivo confocal microscopy of brachycephalic dogs with and without superficial corneal pigment. *Vet Ophthalmol*. 2017;4:294-303.
- van der Woerd A, Nasisse MP, Davidson MG, et al. Lens-induced uveitis in dogs: 151 cases (1985–1990). *J Am Vet Med Assoc*. 1992;201:921-926.
- AKC. AKC Registration Statistics 2017 [Available from: <http://www.akc.org/content/news/articles/most-popular-dog-breeds-full-ranking-list/>]. Accessed April 1, 2016.
- O'Neill D, Darwent EC, Church DB, et al. Demography and health of Pugs under primary veterinary care in England. *Canine Genet Epidemiol*. 2016;3:1-12.



28. Fenn J, Sanchez RF, ter Haar G. Brachycephaly Ethics, Soft Tissue (neurology, ophthalmology and ear-nose-throat diseases). Continuing Education Day, 27th Annual ECVS Scientific Meeting; July 5–7. Athens, Greece; 2018.
29. Genetics Committee of the ACVO. The Pug Ocular disorders presumed to be inherited in purebred dogs. 2013.
30. AKC.Pug Breed Standard; 2008 [Available from: [http://www.akc.org/breeds/pug/breed\\_standard.cfm](http://www.akc.org/breeds/pug/breed_standard.cfm)]. Accessed April 1, 2016.
31. Barrera R, Cinta MM, Rodriguez JF, et al. Keratoconjunctivitis sicca and diabetes mellitus in a dog. *J Am Vet Med Assoc.* 1992;200:1967-1968.
32. Good K, Maggs DJ, Hollingsworth SR, et al. Corneal sensitivity in dogs with diabetes mellitus. *Am J Vet Res.* 2003;64:7-11.
33. Cullen C. Keratoconjunctival effects of diabetes mellitus in dogs. *Vet Ophthalmol.* 2005;8:215-224.
34. Gemensky-Metzler A, Sheahan JE, Rajala-Schultz PJ, et al. Retrospective study of the prevalence of keratoconjunctivitis sicca in diabetic and nondiabetic dogs after phacoemulsification. *Vet Ophthalmol.* 2015;18:472-480.
35. Klein H, Krohne SG, Moore GE, et al. Postoperative complications and visual outcomes of phacoemulsification in 103 dogs (179 eyes): 2006–2008. *Vet Ophthalmol.* 2011;14:114-120.
36. Bagley L, Lavach JD. Comparison of postoperative phacoemulsification results in dogs with and without diabetes mellitus: 153 cases (1991–1992). *J Am Vet Med Assoc.* 1994;205:1165-1169.
37. Appel S, Maggs DJ, Hollingsworth SR, et al. Evaluation of client perceptions concerning outcome of cataract surgery in dogs. *J Am Vet Med Assoc.* 2006;228:870-875.
38. Nasisse M, Davidson MG, Jamieson VE, et al. Phacoemulsification and intraocular lens implantation: a study of technique in 182 dogs. *Prog Vet Comp Ophthalmol.* 1991;1:225-232.
39. Miller T, Whitley RD, Meek LA, et al. Phacofragmentation and aspiration for cataract extraction in dogs: 56 cases (1980–1984). *J Am Vet Med Assoc.* 1987;190:1577-1580.

**How to cite this article:** Boss C, La Croix N, Moore PA, et al. Preliminary report of postoperative complications of phacoemulsification in Pugs: A multicenter retrospective study of 32 cases. *Vet Ophthalmol.* 2020;23:442–449. <https://doi.org/10.1111/vop.12739>