

Adenoid cystic carcinoma located on the lower lip

Ralfi Singer¹ MD, Berk Gürpınar² MD, Özben Yalçın³ MD

Affiliations: ¹Department of Dermatology, Cemil Tascioglu City Hospital, Istanbul, Turkey, ²Department of Otorhinolaryngology, Cemil Tascioglu City Hospital, Istanbul, Turkey, ³Department of Pathology, Cemil Tascioglu City Hospital, Istanbul, Turkey.

Corresponding Author: Ralfi Singer MD, Department of Dermatology, Cemil Taşcıoğlu City Hospital, Darülaceze Caddesi, No:25, 34384, Şişli/Istanbul, Turkey, Tel: 90-212-3145555, Email: ralfisinger@yahoo.com

Abstract

Adenoid cystic carcinoma is a relatively rare epithelial tumor of the major and minor salivary glands that makes up less than 1% of head and neck neoplasms. The typical clinical and pathological findings of this neoplasm include slow growth, perineural invasion, multiple local recurrences, and distant metastasis. Herein, we report a patient with adenoid cystic carcinoma located to the lower lip which is quite uncommon.

Keywords: adenoid cystic carcinoma, lip, salivary gland tumor

Introduction

Adenoid cystic carcinoma (ACC) is a malignant salivary gland tumor which makes up less than 1% of head and neck neoplasms. Approximately 50% of cases are located to the intraoral region, most commonly to the palate. Other less common sites are the floor of the mouth, buccal mucosa, retromolar-tonsillary region, and the lips [1]. Herein, we present a patient with ACC occurring on the lower lip.

Case Synopsis

A 60-year-old man complaining of a nodule located on the inner surface of the right lower lip presented to the dermatology clinic. The lesion first appeared two years prior and was growing slowly. He was a smoker for 30 years (30 packs annually). Physical examination revealed a 1.5cm, firm nodule with a slight depression in the center (**Figure 1**); regional lymph nodes were not palpable. Clinical preliminary diagnoses included squamous cell carcinoma and

minor salivary gland tumor. Punch biopsy was obtained, but since tissue was insufficient no interpretation could be made and the patient was referred to the otorhinolaryngology department where he received a wide wedge resection of the lesion and Abbe flap reconstruction of the lower lip.

Histopathological examination showed well-differentiated tumor tissue growing in large solid sheets together with patchy cribriform areas (**Figure 2**). Perineural invasion was present. Immunohistochemical examination showed positive staining with CK7, CKHMW (high molecular weight cytokeratin), CKLMW (low molecular weight cytokeratin), P63, vimentin, CD117, p40. EMA was focally positive; p53 showed 70-75% positivity and Ki67 was 25-30%. Computed tomography

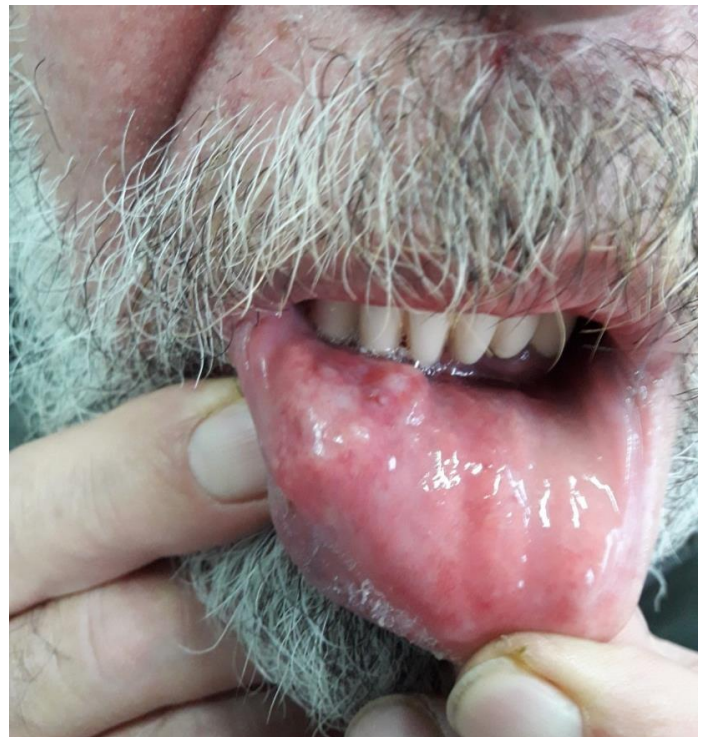

Figure 1. A 1.5 cm firm nodule located on the lower lip.

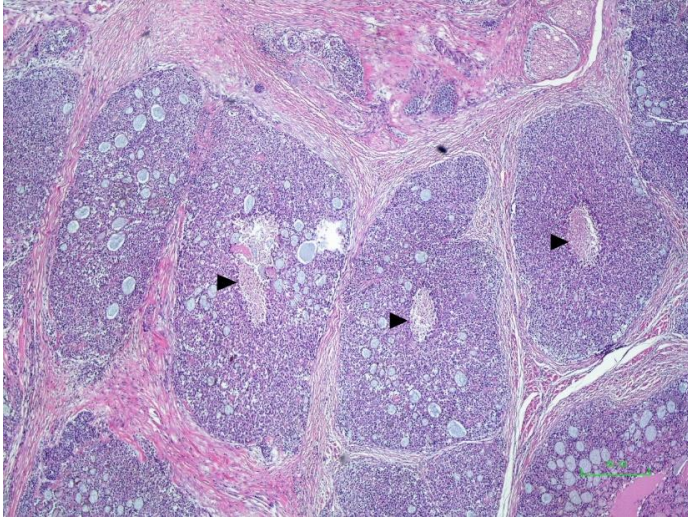


Figure 2. Histological analysis revealed solid and cribriform pattern in the same area. Note the tumor necrosis. (arrowheads). H&E, 40x.

demonstrated heterogeneous changes in the density of the soft tissues located to the anterior part of the right mandible. Positron emission tomography was neither conclusive nor diagnostic; ^{18}F fluoro-2-deoxy-glucose (FDG) uptake was normal. The final diagnosis was ACC and the patient received radiotherapy. The patient has been followed for four years without any recurrences.

Case Discussion

Adenoid cystic carcinoma comprises 10-12% of the salivary gland neoplasms and is characterized by slow growth, perineural invasion, local recurrences, and distant metastasis [2]. Peak incidence occurs in the fourth and sixth decades with a 3:2 prevalence for females [1].

Adenoid cystic carcinoma occurrence on the lips is very exceptional. To the best of our knowledge, only a few case reports could be found in the literature [3-5]. In all these cases, the neoplasms were located on the upper lip. In a study of 59 cases with upper lip neoplasms, ACC was found in one [6]. Waldron et al. [7] reported 426 cases of intraoral minor salivary gland neoplasms and identified two cases of ACC on the upper lip, whereas Yih et al. [8] identified one ACC case out of 213 cases with intraoral minor salivary gland tumors. Wang et al. [9] reported six

ACC cases out of 397, a relatively higher ratio than previously reported.

Histopathologically, ACC has three subtypes, cribriform, tubular, and solid (**Figure 3**). All three patterns are composed of both ductal and myoepithelial cells. The cribriform subtype has been defined as “Swiss cheese-like” and consists of pseudocystic spaces [1]. Solid pattern has the worst prognosis with regard to distant metastasis and overall survival and the cribriform variant shows poor prognosis with respect to local recurrence rates [2]. More than one histopathologic pattern can be observed in a neoplasm [10]. Our case had both solid and cribriform patterns.

Several features indicate poor prognosis, including the clinical stage, tumor location, presence of metastatic nodules, recurrence following treatment, histological subtype, perineural invasion, presence of a tumor arising from minor salivary glands, and/or positive surgical margins [1,5]. Perineural invasion is an important feature of ACC, which partly explains its tendency to spread. It occurs in approximately 22-46% of cases [3]. Hematogenous spread occurs late in the course of the disease in 40-60 % of cases [10].

The most common salivary gland tumor of the lower lip is pleomorphic adenoma and the differential diagnosis consists of myoepithelioma and basal cell adenoma. Mucoepidermoid carcinoma is the most common malignant salivary gland tumor located on the lower lip. Nevertheless, squamous cell

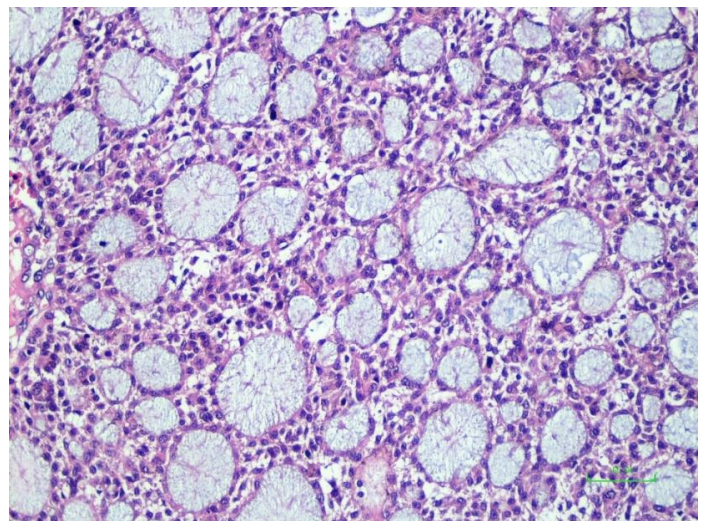


Figure 3. Cribriform areas with myxoid globules. H&E, 200x.

carcinoma, a non-salivary gland tumor, must always be kept in mind for the differential diagnosis [11].

Surgery is the treatment of choice for ACC by wide local excision combined with postoperative radiotherapy [2,10]. A minimum of one centimeter margin to achieve tumor-free excision is advised. It is considered that conservative surgical treatment leads to increased failure rates and more aggressive surgical approach is supported [2,3]. Chemotherapy has shown a limited role in the management of ACC [1].

References

1. Pinakapani R, Nallan C, Reddy L, Srujana Y et al. Adenoid cystic carcinoma of the head and neck - literature review. *Qual Prim Care*. 2015; 23:309-314. [PMID: 25943783].
2. Jaiswara C, Dhiman NK, Singh AK et al. Adenoid cystic carcinoma of the floor of the mouth - A rare presentation. *J Oral Biol Craniofac Res*. 2015; 6 (Suppl 1): S65-S69. [PMID: 27900255].
3. Dogra BB, Batra G, Wahegaonkar C, et al. Adenoid cystic carcinoma of the upper lip: A case report and review of literature. *Int J Oral Health Sci*. 2016; 6: 40-43.
4. Appel BN, El Attar AM, Paladino TR et al. Multifocal adenoid cystic carcinoma of the lip. *Oral Surg, Oral Med, and Oral Pathol*. 1976; 41:764-771. [PMID: 179038].
5. Sanchez-Sanchez M, Infante-Cossio P, Lozano-Rosado R, et al. Resection of upper lip adenoid cystic carcinoma and reconstruction with reverse Yu flap: Report of three cases and a literature review. *Molecular and Clinical Oncology*. 2017; 6: 444-450. [PMID: 28451431].
6. Luna-Ortiz K, Güemes-Meza A, Villavicencio-Valencia V et al. Upper lip malignant neoplasms. A study of 59 cases. *Med Oral Patol Oral Cir Bucal*. 2012; 17: e371-376. [PMID: 22143714].
7. Waldron CA, El-Mofty SK, Gnepp DR. Tumors of the intraoral minor salivary glands: a demographic and histologic study of 426 cases. *Oral Surg Oral Med Oral Pathol*. 1988; 66: 323-333. [PMID: 2845326].
8. Yih WY, Kratochvil FJ, Stewart JC. Intraoral minor salivary gland neoplasms: review of 213 cases. *J Oral Maxillofac Surg*. 2005; 63:805-810. [PMID: 15944978].
9. Wang D, Li Y, He H, et al. Intraoral minor salivary gland tumors in a chinese population: A retrospective study on 737 cases. *Oral Surg Oral Med Oral Pathol Oral Radiol Endod*. 2007; 104: 94-100. [PMID: 17577550].
10. Giannini PJ, Shetty KV, Horan SL et al. Adenoid cystic carcinoma of the buccal vestibule: a case report and review of the literature. *Oral Oncol*. 2006; 42: 1029-1032. [PMID: 16996786].
11. Sengul I, Sengul D. Pleomorphic adenoma of the lower lip: A review. *N Am J Med Sci* 2011; 3: 536-539.
12. [PMID: 22363073].

Conclusion

Adenoid cystic carcinoma should be included in the differential diagnosis of atypical tumors located on the lip or oral mucosa. Although they are slowly growing tumors, patients should be followed long term to assess for local recurrences or distant metastasis.

Potential conflicts of interest

The authors declare no conflicts of interest.