

Photo Vignette

Childhood sarcoidosis: diagnostic issues

Fouad El Sayed MD, Gretta Torbey MD, Hussein Youssef MD, Myrna Chababi MD

Dermatology Online Journal 19 (10): 16

Lebanese University, Baabda, Mount Lebanon, Lebanon

Correspondence:

Gretta Torbey
Lebanese University
Baabda, Mount Lebanon, Lebanon

Abstract

Childhood sarcoidosis is a rare granulomatous disorder that affects several systems including the lungs, skin, eyes, and bones. On histopathology, non-caseating granuloma is the classic feature. We present a case of late childhood sarcoidosis of the skin, lungs, and bones demonstrating granulomas with fibrinoid necrosis, making distinction from tuberculosis difficult.

Introduction

Sarcoidosis is a multisystem disease affecting most commonly the lungs [1], reticuloendothelial system, bones, and skin. Childhood involvement is divided into early-onset sarcoidosis and late childhood sarcoidosis, which has a similar presentation to the adult form. Diagnosis typically relies on the clinical picture, presence of non-caseating granulomas on histopathology, and elimination of other granulomatous diseases; in 6-12% of adult cases, necrotizing granulomas are observed instead [2]. Owing to its rarity in the pediatric population, sarcoidosis is not readily suspected in children [3].

The patient we present highlights the diagnostic challenges in an adolescent with lung, bone, and skin sarcoidosis combined with fibrinoid necrosis, a condition rarely reported previously in children [4].

Case-report

A 13 year-old girl presented with necrotic and eroded nodules as well as violaceous plaques over the lower limbs (Figure 1). A careful physical examination at that point revealed sausage-shaped fingers (Figure 2). She reported a 6-month history of fever, weight loss of 6kg, splenomegaly, and diffuse lymphadenopathy treated with an anti-tubercular drug for 3 weeks at another institution.

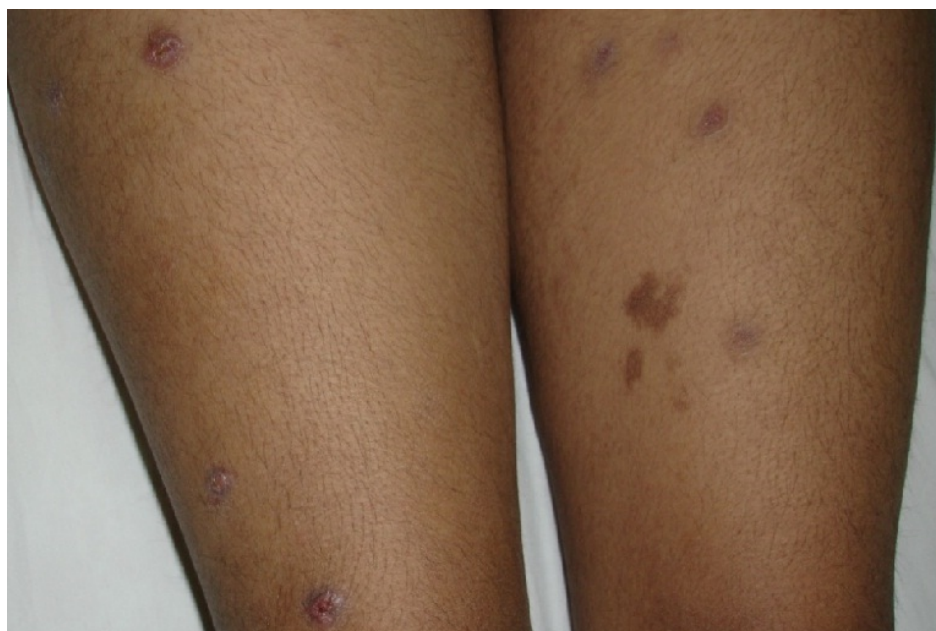

Figure1. Violaceous cutaneous nodules with erosion

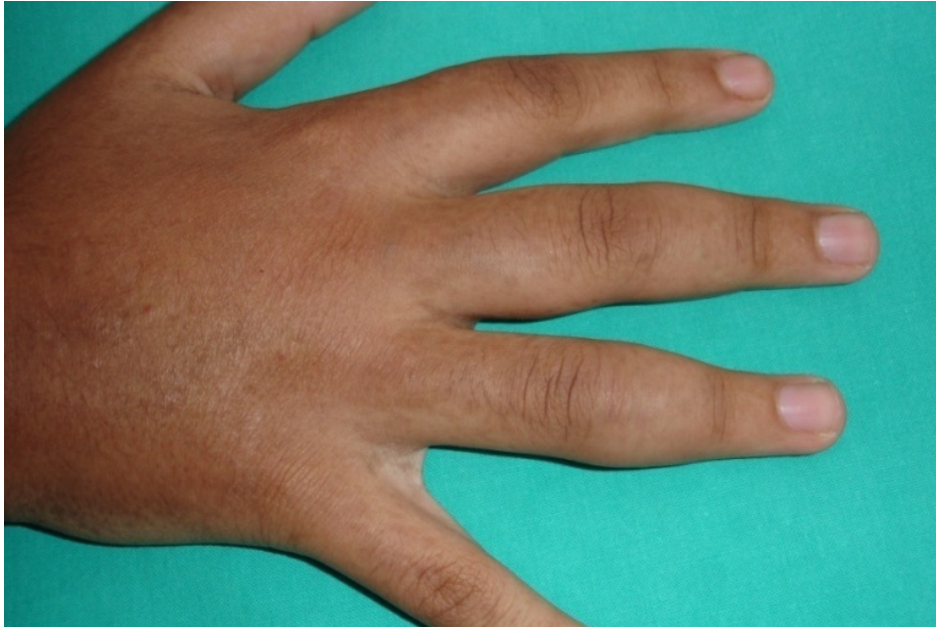

Figure2. Dactylitis with sausage-shaped fingers

Laboratory evaluation revealed only a non-specific rise in acute phase reactants. c-ANCA and p-ANCA were negative. Chest X-ray showed bilateral hilar lymphadenopathies, later confirmed by chest computed tomography. PPD (protein purified derivative) was negative. X-rays of the hands showed cortical erosions with periosteal reaction and trabecular aspect of metacarpal heads (Figure 3).

Skin biopsy showed a granuloma with eosinophilic fibrinoid necrosis (Figure 4) without obvious mycobacteria. There were no Schauman or asteroid bodies.

PCR (polymerase chain reaction) for *Mycobacterium tuberculosis* as well as the highly sensitive *hsp65* (heat shock protein 65) PCR were negative. ACE (angiotensin converting enzyme) level was three times the normal.

Based on clinical and histological findings, the diagnosis of childhood sarcoidosis was established. Treatment with prednisone 1mg/kg/day for 6 weeks was very effective in promoting complete healing of the cutaneous lesions, dactylitis, and adenopathies. Corticosteroid tapering was done over a period of 3 months without recurrence at 6-month follow-up.

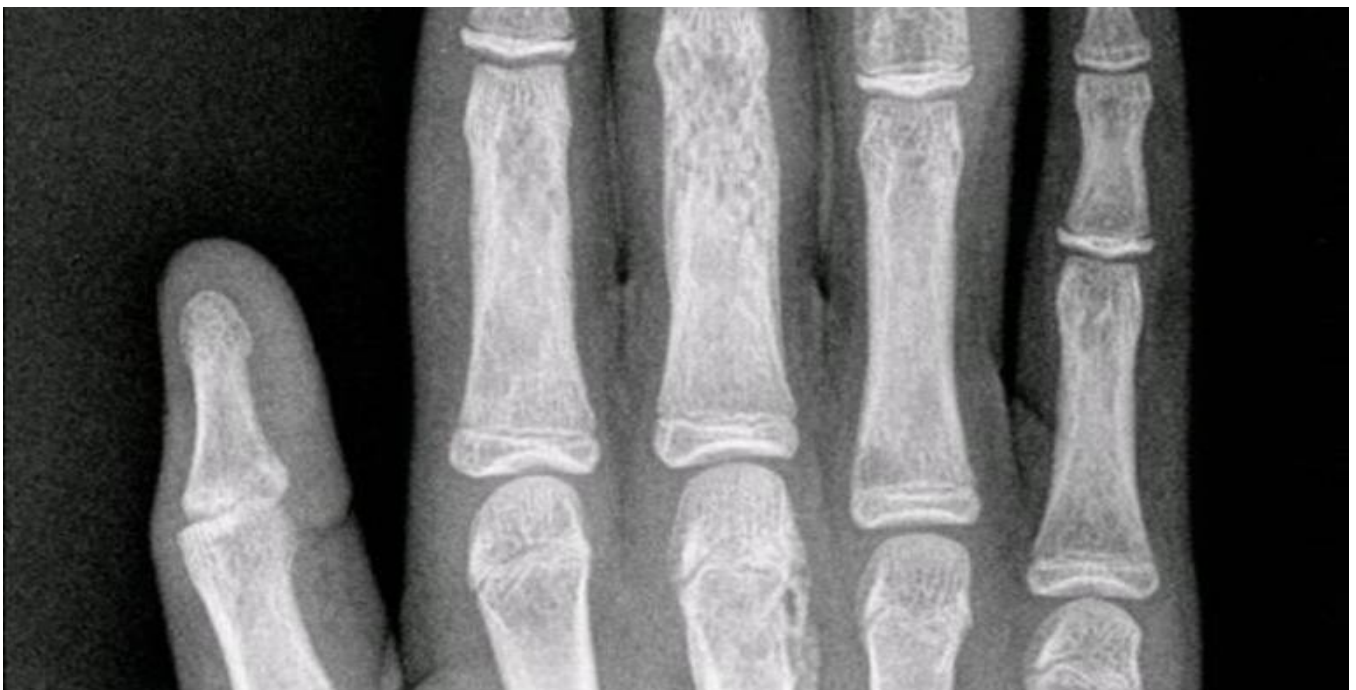

Figure3. Trabecular aspect of 3rd and 4th metacarpophalangeal joints and cortical erosions of 3rd and 4th proximal interphalangeal joints.

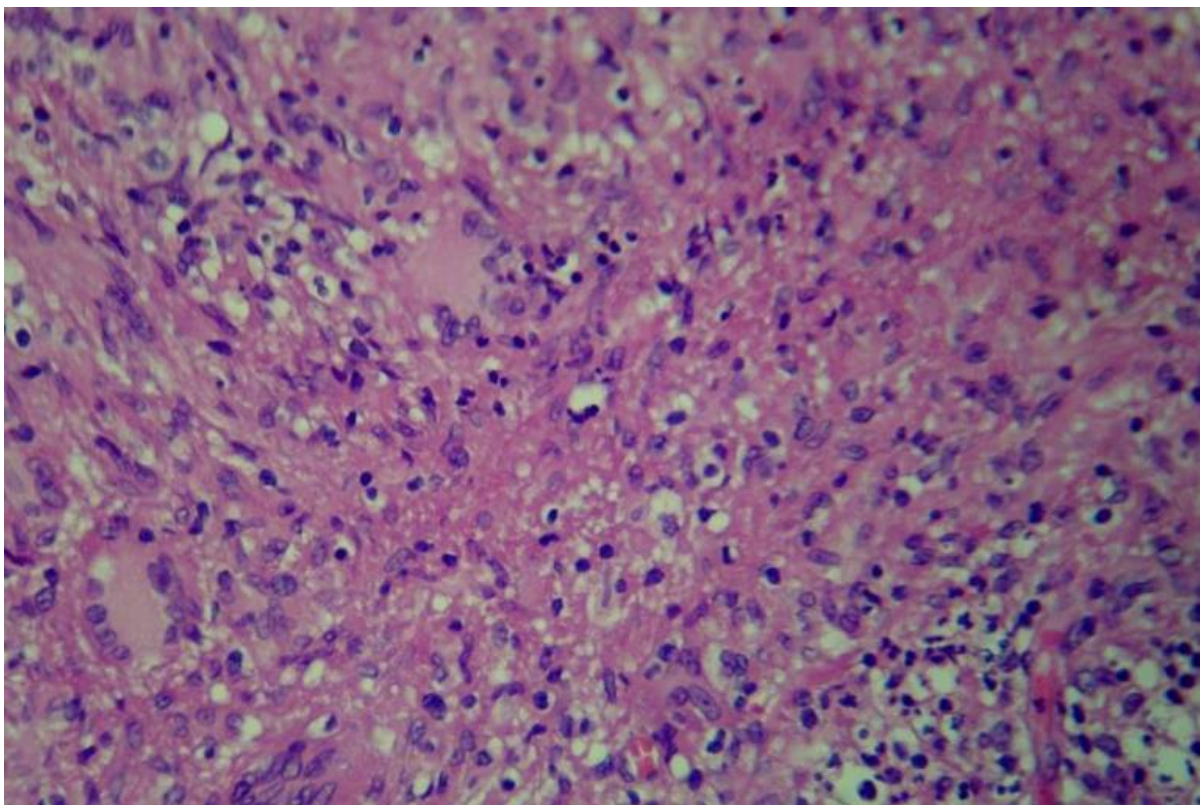


Figure 4. Skin biopsy (hematoxylin-eosin) showing granuloma with fibrinoid necrosis and giant cells.

Discussion

Childhood sarcoidosis is a rare multisystem granulomatous disorder that can be a diagnostic challenge. It is rarely encountered in the pediatric population and its incidence is uncertain (estimated to be 0.22–0.27/100,000 children per year in one study in Denmark) [3]. The early-onset form begins in the first 5 years of life and manifests with arthritis, uveitis, and skin disease rather than pulmonary symptoms. The late-onset form occurs between 10 and 15 years and resembles that of adulthood (lung primarily, skin, reticuloendothelial).

Specific lesions containing granulomas manifest as plaques, papules, nodules, scars, ulcers, hypopigmented macules, erythroderma, lupus pernio, and alopecia [5]. Non-specific manifestations are less frequent and present as erythema nodosum [6], erythema multiforme, prurigo, calcifications, and nail clubbing. Plaques and annular lesions are more likely to be associated with systemic manifestations [6], which is consistent with our patient.

Bone involvement affects around 5% (1-13%) of sarcoidosis patients [7]. When present, it indicates a more severe disease and is usually associated with other localizations. Sites of predilection are the proximal and middle phalanges, but lesions of the vertebrae, skull, ribs, nasal bones, and maxillae have been reported [9, 10, 11, 12]. Associated dactylitis, as in our patient, was only present in 45% of patients with bone alteration on X-ray [8]. Bone lesions can be either lytic or sclerotic. Sclerotic lesions are rare and usually target axial rather than peripheral bones [13]. They have only been described in black people [14]. Lytic lesions are either cystic, permeative (tunnelling and remodelling of the cortical bone), or destructive [8]. The case presented had typical lytic lesions of the middle phalanges.

No laboratory data confirms the diagnosis of sarcoidosis. Our patient had elevated serum ACE level. ACE is increased in more than half of late-childhood sarcoidosis but this test lacks specificity [15] and is more useful for follow-up. Exhaled 8-isopropane, a marker of lipid peroxidation, has been used as a prognostic factor and to follow treatment response [16]. Chitotriosidase is a new serum marker that correlates with disease activity [17].

Non-caseating granulomas remain the key diagnostic element. Nonetheless, the absence of such granulomas does not rule out sarcoidosis because limited amounts of fibrinoid necrosis are reported in 6-12% of adult cases [18]. Moreover, necrotizing sarcoid granulomatosis is a condition considered as a variant of sarcoidosis in which fibrinoid necrosis is abundant and associated granulomatous vasculitis is present [19]. The histopathological distinction between caseous and fibrinoid necrosis is subtle. Therefore, ruling out other causes of granulomatous diseases (tuberculosis in our case) is crucial.

Spontaneous remission can frequently occur over the following 6 months [20]. Therefore, indications for starting treatment are still controversial. Glucocorticoids are the mainstay of treatment in sarcoidosis [21]. Methotrexate [22] and cyclophosphamide [23] are second-line treatments. Azathioprine and chlorambucil are more used as steroid-sparing agents [24]. Chloroquine is particularly useful in cutaneous sarcoidosis [25]. Pentoxifylline is used for both pulmonary and extrapulmonary disease [26]. Limited experience exists with the use of cyclosporine [27] and thalidomide [28]. The newer anti-TNF α monoclonal antibodies

have been introduced. Infliximab is efficient in extrapulmonary sarcoidosis but equal to placebo in pulmonary sarcoidosis according to 2 randomized controlled trials. Etanercept has no indications in pulmonary and ocular sarcoidosis [29]. Adalimumab was also used in sarcoidosis refractory to steroids, but with doubtful clinical significance [30]. Paradoxical cases of sarcoidosis induced by monoclonal antibodies to TNF-alpha were reported [29]. A subset of sarcoidosis that is CD4+ lymphopenic and steroid and methotrexate resistant is particularly responsive to monoclonal antibodies [31].

This case of childhood sarcoidosis with the rare combination of mediastinal sarcoidosis, skin involvement, and dactylitis stresses the importance of keeping sarcoidosis on the differential diagnosis of granulomatous diseases in children in the presence of necrotizing granulomas.

References

1. Lynch JP 3rd, Ma YL, Koss MN, White ES. Pulmonary sarcoidosis. *Semin Respir Crit Care Med*. 2007 Feb;28(1): 53-74. [PMID:17330192]
2. Cardoso JC, Cravo M, Reis JP, Tellechae O. Cutaneous sarcoidosis: a histopathological study. *J Eur Acad Dermatol Venerol*. 2009 Jun;23(6): 678-82. [PMID:19298487]
3. Hoffman AL, Milman N, Byg KE. Childhood sarcoidosis in Denmark 1979–1994: incidence, clinical features and laboratory results at presentation in 48 children. *Acta Paediatr*. 2004 Jan;93: 30–36. [PMID:14989436]
4. K. Boussetta, N.Aloui, M.Kharfi et al. La sarcoïdose chez l'enfant : A propos d'une observation, *Journal de pédiatrie et de puériculture*. 2003;16: 374–377
5. Yanardag H, Pamuk ON, Karayel T. Cutaneous involvement in sarcoidosis: analysis of the features in 170 patients. *Respir Med*. 2003 Aug;97(8): 978-82. [PMID:12924527]
6. Kang MJ, Kim HS, Kim HO, Park YM. Cutaneous Sarcoidosis Presenting as Multiple Erythematous Macules and Patches. *Ann Dermatol*. 2009 May;21(2): 168–170. [PMID:20523778]
7. James DG, Neville E, Carstairs LS. Bone and joint sarcoidosis. *Semin Arthritis Rheum* 1976 Aug;6(1): 53-81. [PMID:785605]
8. Neville E; Carstairs LS; James DG; Sarcoidosis of bone. *Q J Med* 1977 Apr;46(182): 215-27. [PMID:866575]
9. Berk RN, Brower TD. Vertebral sarcoidosis. *Radiology* 1964 Apr;82: 660-3. [PMID:114131671]
10. Young DA, Laman ML. Radiodense skeletal lesions in Boeck's sarcoid. *Am J Roentgenol Radium Ther Nucl Med* 1972 Mar;114: 553-8. [PMID:5011402]
11. Rubin MM, Sanfilippo RJ, Pliskin A. Maxillary alveolar bone loss in a patient with sarcoidosis. *J Oral Maxillofac Surg* 1991 Dec;49: 1351-3. [PMID:1955928]
12. Curtis GT. Sarcoidosis of the nasal bones. *Br J Radiol* 1964 Jan;37: 68-70. [PMID:14111625]
13. De Bandt M, Grossin M, Smadja M, Kahn MF. Vertebral osteosclerotic sarcoidosis. *AJR Am J Roentgenol* 1991 Dec; 157:1356-7. [PMID:1950891]
14. Vinnicombe S, Heron C, Wansbrough-Jones M. Dense bones. *Br J Radiol* 1992 Nov; 65:1049-50. [PMID:1450825]
15. Studdy PR, Bird R. Serum angiotensin converting enzyme in sarcoidosis-its value in present clinical practice. *Ann Clin Biochem* 1989 Jan;26(Pt 1): 13-8. [PMID:2544134]
16. Piotrowski WJ, Kurmanowska Z, Antczak A et al. Exhaled 8-isoprostane as a prognostic marker in sarcoidosis. A short term follow-up. *BMC Pulm Med* 2010 Apr 27;10:23. [PMID:20420721]
17. Bargagli E, Bennett D, Maggiorelli C, Di Sipio P, Margollicci M, Bianchi N, Rottoli P. Human Chitotriosidase: a Sensitive Biomarker of Sarcoidosis. *J Clin Immunol*. 2012 Aug 10. [Epub ahead of print] [PMID:22878841]
18. Mortensen J, Lange P, Storm HK, Viskum K. Childhood tuberculosis in a developed country. *Eur Respir J*. 1989 Nov;2(10):985-7. [PMID: 2606201]
19. Sadoun D, Kambouchner M, Tazi A, Lattaignant JC, Margent P, Arondelle C, Carvaillo D, Groussard O, Battesti JP. Necrotizing sarcoid granulomatosis. *Ann Med Interne*. 1994;145(4):230-3. [PMID:8092646]
20. Newman LS, Rose CS, Maier LA. Sarcoidosis. *N Engl J Med* 1997 Apr; 336:1224-34. [PMID:9110911]
21. Du Bois RM. Corticosteroids in sarcoidosis: Friend or foe? *Eur Respir J* 1994 Jul; 7:1203-9. [PMID :7925895]
22. Lower EE; Baughman RP. The use of low dose methotrexate in refractory sarcoidosis. *Am J Med Sci* 1990 Mar;299(3):153-7. [PMID:2316559]
23. Demeter SL. Myocardial sarcoidosis unresponsive to steroids. Treatment with cyclophosphamide. *Chest* 1988 Jul;94(1):202-3. [PMID:3383636]
24. Agbogu BN, Stern BJ, Sewell C, Yang G. Therapeutic considerations in patients with refractory neurosarcoidosis. *Neurol* 1995 Sep;52(9):875-9. [PMID:7661724]
25. Johns CJ; Zachary JB; MacGregor MI, Curtis JL, Scott PP, Terry PB. The longitudinal study of chronic sarcoidosis. *Trans Am Clin Climatol Assoc* 1982;94:173-81. [PMID:7186230]
26. Zabel P, Entzian P, Dalhoff K, Schlaak M. Pentoxifylline in treatment of sarcoidosis. *Am J Respir Crit Care Med* 1997 May;155(5):1665-9. [PMID:9154873]
27. York EL, Kovithavongs T, Man SF, Rebuck AS, Sproule BJ. Cyclosporine and chronic sarcoidosis. *Chest* 1990 Oct;98(4):1026-9. [PMID:2209112]
28. Yasui K, Yahsiro M, Tsuge M, Manki A, Takemoto K, Yamamoto M, Morishima T. Thalidomide dramatically improves the symptoms of early-onset sarcoidosis/Blau syndrome: its possible action and mechanism. *Arthritis Rheum*. 2010 Jan;62(1):250-7. [PMID:20039400]

29. Toussirot E, Pertuiset E. TNFalpha blocking agents and sarcoidosis: An update. *Rev Med Interne* 2010 Dec;31(12):828-37. [PMID:20510487]
30. Milman N, Graudal N, Loft A, Mortensen J, Larsen J, Baslund B. Effect of the TNF- α inhibitor adalimumab in patients with recalcitrant sarcoidosis: a prospective observational study using FDG-PET. *Clin Respir J*. 2011 Nov 30. [Epub ahead of print] [PMID:22128762]
31. Crouser ED, Lozanski G, Fox CC, Hauswirth DW, Raveendran R, Julian MW. The CD4+ lymphopenic sarcoidosis phenotype is highly responsive to anti-tumor necrosis factor- α therapy. *Chest* 2010 Jun;137(6):1432-5. [PMID:20525654]