

# UCSF

## UC San Francisco Previously Published Works

### Title

Angiographic features help predict outcome after stereotactic radiosurgery for the treatment of pediatric arteriovenous malformations.

### Permalink

<https://escholarship.org/uc/item/0p9281gp>

### Journal

Child's nervous system : ChNS : official journal of the International Society for Pediatric Neurosurgery, 30(2)

### ISSN

0256-7040

### Authors

Sheth, Sunil A  
Potts, Matthew B  
Sneed, Penny K  
et al.

### Publication Date

2014-02-01

### DOI

10.1007/s00381-013-2231-4

Peer reviewed

# Angiographic features help predict outcome after stereotactic radiosurgery for the treatment of pediatric arteriovenous malformations

Sunil A. Sheth · Matthew B. Potts · Penny K. Sneed · William L. Young · Daniel L. Cooke · Nalin Gupta · Steven W. Hetts

Received: 25 June 2013 / Accepted: 8 July 2013 / Published online: 27 July 2013  
© Springer-Verlag Berlin Heidelberg 2013

## Abstract

**Purpose** Arteriovenous malformations (AVMs) are a frequent cause of hemorrhagic stroke in children. Stereotactic radiosurgery (SRS) is an established treatment for these lesions, particularly those that are surgically inaccessible. Because only complete AVM obliteration is believed to protect against the future risk of hemorrhage, identifying lesion characteristics that predict response to therapy is an important objective. The goal of this study is to evaluate the influence of angiographic features of AVMs on the rate of obliteration following treatment with SRS.

**Methods** This is a retrospective cohort study of pediatric patients (age  $\leq 18$  years) treated with Gamma Knife SRS for

cerebral AVMs between 2000 and 2012. Detailed angiographic data at the time of initial angiographic evaluation were prospectively recorded by experienced neurointerventional radiologists. The primary outcome was the rate of obliteration on a 3-year follow-up angiogram.

**Results** We identified 42 pediatric patients treated with SRS for cerebral AVMs. Twenty-seven patients completed 3-year angiographic follow-ups. Complete obliteration was seen in 30 %, partial response in 67 %, and no response in 4 %. Higher SRS dose was associated with complete obliteration. Larger AVM diameter, presence of multiple draining veins, and presence of multiple draining veins reaching a sinus were associated with partial response. In this small cohort, diffuse AVM borders, presence of aneurysm, and pre-SRS embolization were not associated with obliteration.

**Conclusions** Our study identifies AVMs in the pediatric population with a nidus diameter of  $< 2.5$  cm and a solitary draining vein as the most likely to undergo complete obliteration after SRS treatment.

---

S. A. Sheth  
Department of Neurology, University of California,  
San Francisco, San Francisco, CA, USA

M. B. Potts · N. Gupta  
Department of Neurological Surgery, University of California,  
San Francisco, San Francisco, CA, USA

P. K. Sneed  
Department of Radiation Oncology, University of California,  
San Francisco, San Francisco, CA, USA

W. L. Young  
Department of Anesthesia and Perioperative Care and Center for  
Cerebrovascular Research, University of California,  
San Francisco, San Francisco, CA, USA

D. L. Cooke · S. W. Hetts (✉)  
Division of Interventional Neuroradiology, Department of  
Radiology and Biomedical Imaging, University of California,  
San Francisco, San Francisco, CA, USA  
e-mail: steven.hetts@ucsf.edu

**Keywords** Intracranial arteriovenous malformations · Stereotactic radiosurgery · Cerebral angiography · Intracranial hemorrhages · Pediatrics

## Introduction

Arteriovenous malformations (AVMs) account for as many as half of all hemorrhagic strokes in the pediatric population. Up to 18 % of all AVMs present in this age group and compared to adults, hemorrhagic presentation is disproportionately more common in children [1–3]. Because of the long-life expectancy in a child, there is a high cumulative risk of hemorrhage, even for lesions that have not bled at the

time that they are identified. This future risk of hemorrhage and its associated morbidity justifies treatment of these lesions whenever safely possible.

The treatment options for pediatric AVMs include microsurgical resection, radiosurgery, and adjunctive or curative embolization. For lesions in surgically inaccessible areas or with high operative risk, stereotactic radiosurgery (SRS) has been shown to be an effective treatment, and prior studies report obliteration rates ranging from 35 to 90 % with a single radiosurgical treatment [1–8]. A clear correlation between higher total radiation dose and rate of obliteration has been established [4, 6, 8, 9]. Increased doses and larger treated volumes, however, are also associated with increased side effects and risk of neurological injury [10–13]. Prior reports have all been conducted in adults and have identified AVM maximal diameter, number of draining veins, presence of nidus aneurysms, and diffuse AVM shape as predictive of poor response [10, 14]. Because only complete obliteration of the AVM nidus protects from further hemorrhage, it is important to determine which specific lesion characteristics predict therapeutic response to SRS. In this study, we evaluated how specific angiographic features affected the rate of AVM obliteration in a cohort of children treated by SRS. A more comprehensive understanding of the prognostic value of angiographic features may help guide the use of and manage expectations for SRS in the treatment of pediatric AVMs.

## Patients and methods

### Patients

All patients with AVMs were discussed at one or more multidisciplinary conferences for management recommendations, with a preference for SRS over microsurgery for larger, less surgically-accessible AVMs.

This study is a retrospective cohort study from a single academic center, approved by the Institutional Review Board of the University of California, San Francisco, and has been conducted in compliance with Health Insurance Portability and Accountability Act regulations. The registries of the UCSF Brain Arteriovenous Malformation Study Project and Department of Radiation Oncology were searched to identify pediatric patients (age  $\leq 18$  years) with cerebral AVMs who were treated with SRS between January 2000 and January 2012. These databases as well as medical records, pre- and postSRS imaging studies, and clinical follow-up evaluations were reviewed. Detailed angiographic data at the time of initial angiographic evaluation were recorded by experienced neurointerventionalists and included variables describing the AVM size, location, arterial feeding vessels, presence and location of aneurysms, presence of diffuse

nidus morphology, and venous outflow characteristics. SRS treatment parameters were also recorded at the time of SRS and included target volume, treated volume, prescription dose, prescription isodose contour, and number of treatment stages. Spetzler–Martin scores were calculated based on pre-SRS angiographic data [15]. Pollock scores were calculated based on initial SRS treatment [16].

### Stereotactic radiosurgery and angiographic technique

Stereotactic radiosurgery during this study period was performed using the model B, C, 4C, or Perfexion Leksell Gamma Knife (Elekta Instruments, Atlanta, GA). General anesthesia or conscious sedation was administered by a pediatric anesthesiologist based on patient age and weight. After administration of local anesthesia, a Leksell head frame was placed and patients underwent pre-SRS imaging, which included a stereotactic catheter angiogram and gadolinium-enhanced magnetic resonance imaging. The results of these studies were superimposed to aid in target delineation, which was performed by the attending radiation oncologist, interventional neuroradiologist, and neurosurgeon. The treatment plan was created by a physicist using GammaPlan treatment planning software (Elekta, Stockholm, Sweden) and approved by the attending radiation oncologist and neurosurgeon. Volume-staged SRS was considered if the treatment volume exceeded 8–10 ml, treating approximately 8–10 ml per treatment stage spaced 3–6 months apart. After SRS, patients were discharged home once they recovered from anesthesia.

### Outcome measurements

The primary outcome of this study was the rate of obliteration of AVM at 3-year angiographic follow-up. Treatment outcomes were recorded as no response, partial response, and complete obliteration. All postSRS angiograms were reviewed by a single attending interventional neuroradiologist (SWH).

### Statistical analysis

Univariate statistics were performed using Graphpad Prism 5.0a (Graphpad Software, Inc., La Jolla, CA). Comparisons between continuous variables (AVM size, age, Pollock Score) were made using unpaired two-sided *t* test, ordinal variables (number of draining veins, number of draining veins reaching a sinus) with Mann–Whitney test, and categorical variables (diffuse borders, presence of aneurysm, treatment with embolization, gender) with Fisher's exact test. *P* values  $< 0.05$  were considered significant.

## Results

### Patient and AVM characteristics

Between 2000 and 2012, 44 pediatric patients underwent SRS for AVM treatment at our institution. Two patients have had no further follow-up after SRS and were excluded from the study. Of the remaining 42 patients, 27 have to date completed the 3-year angiographic follow-up at our institution. The remainder of the patients elected to continue their care at their local hospital (four) or still awaiting their 3-year study (ten). One patient suffered a re-hemorrhage soon after SRS and died. Table 1 lists the baseline characteristics of the entire cohort as well as the subset of patients with angiographic follow-up. Overall, mean age of initial presentation was  $12\pm 4$  years with a slight male predominance (57 %). Hemorrhage was the most common presenting symptom (62 %), followed by seizures (21 %), and headache (10 %). Vascular malformations in the remainder of patients were discovered during evaluations for developmental delay, focal

neurological deficits, and syncope. The most common location for AVMs in this series was cortical or subcortical lobar (57 %). There were, however, a significant number of lesions involving the deep nuclei (38 %).

Spetzler–Martin grades were II in 10 %, III in 48 %, IV in 38 %, and V in 7 %. Most AVMs were in eloquent locations (95 %) and had deep venous drainage (86 %). Diffuse morphology of the AVM nidus as seen on angiography was present in 29 % of the lesions. Aneurysms associated with AVM were visualized on 19 % of malformations (three feeding artery aneurysms and five intra-nidal aneurysms). Average Pollock score was  $1.5\pm 1.0$ .

### AVM treatment characteristics

Stereotactic radiosurgery at our institution was the first treatment modality for the majority of patients (74 %) as shown in Table 2. The remainder of patients was treated first with embolization (22 %) or surgery (5 %). For the majority of patients, SRS alone was the sole treatment modality (67 %), though some patients received a combination of treatments. These combinations included embolization followed by SRS (5 %), surgery followed by SRS (5 %), SRS followed by surgery (7 %), embolization followed by SRS then surgery (5 %), and embolization followed by surgery then SRS (12 %). The median target volume for single-session SRS was 1.9 ml (range, 0.1–11 ml), with a median prescription dose of 18 Gy (range, 15–20 Gy). Fifteen AVMs underwent staged SRS, with a median total target volume of 16.9 ml (range, 8–37 ml), median SRS dose of 17 Gy (range, 12–18 Gy), and median treated volume of 7.5 ml per stage (range, 4–15 ml), given over two (eight) or three (seven)

**Table 1** Patient demographics and presentation of characteristics

	All patients	Patients with 3-year angiographic follow-up
Number	42	27
Age (years)	12.0 $\pm$ 4.0	11.9 $\pm$ 3.9
Female	18 (43 %)	10 (37 %)
Presenting symptoms (%)		
Hemorrhage	26 (62 %)	16 (59 %)
Seizure	9 (21 %)	5 (19 %)
Headache	4 (10 %)	4 (15 %)
Developmental delay	1 (2 %)	1 (4 %)
Progressive focal deficit	1 (2 %)	1 (4 %)
Syncope	1 (2 %)	0
Location		
Lobar	24 (57 %)	13 (48 %)
Deep nuclei	16 (38 %)	12 (44 %)
Brainstem	2 (5 %)	2 (7 %)
Spetzler–Martin scores		
I	0	0
II	4 (10 %)	3 (11 %)
III	20 (48 %)	11 (41 %)
IV	15 (38 %)	11 (41 %)
V	3 (7 %)	2 (7 %)
Deep drainage present	36 (86 %)	25 (93 %)
Diffuse-type AVM	12 (29 %)	8 (30 %)
Presence of aneurysm	8 (19 %)	4 (15 %)
Feeding artery aneurysm	3 (7 %)	1 (4 %)
Nidal aneurysm	5 (12 %)	4 (15 %)
Pollock score	1.5 $\pm$ 1.0	1.5 $\pm$ 1.0

**Table 2** Treatment characteristics

	All patients	Patients with 3-year angiographic follow-up
Number	42	27
First treatment modality		
Gamma Knife	31 (74 %)	21 (78 %)
Embolization	9 (21 %)	6 (22 %)
Surgery	2 (5 %)	0
Total treatments		
GK only	28 (67 %)	19 (70 %)
GK + embolization	2 (5 %)	1 (4 %)
GK + surgery	5 (12 %)	2 (7 %)
GK + embolization + surgery	7 (17 %)	5 (19 %)
Total number embolization	9 (21 %)	6 (22 %)
Median target volume (ml)	4.6 [0.1–37]	4.3 [0.1–37]
Median prescription dose (Gy)	17 [12–20]	17.5 [15–20]

stages. Median interval between treatments was 3 months (range, 3–5 months).

#### AVM treatment outcomes

Three-year angiographic outcome measurements were available in 27 of the 42 patients. Complete obliteration of the AVM as seen on a 3-year angiography was achieved in eight patients (30 %). The remaining patients had partial (18) or no (1) response. Three of the patients with partial response were retreated with SRS (two) or surgery (one) and obtained complete response. All patients who achieved complete obliteration had undergone a single-session SRS. None of the eight patients who underwent staged SRS demonstrated complete obliteration on angiographic follow-up.

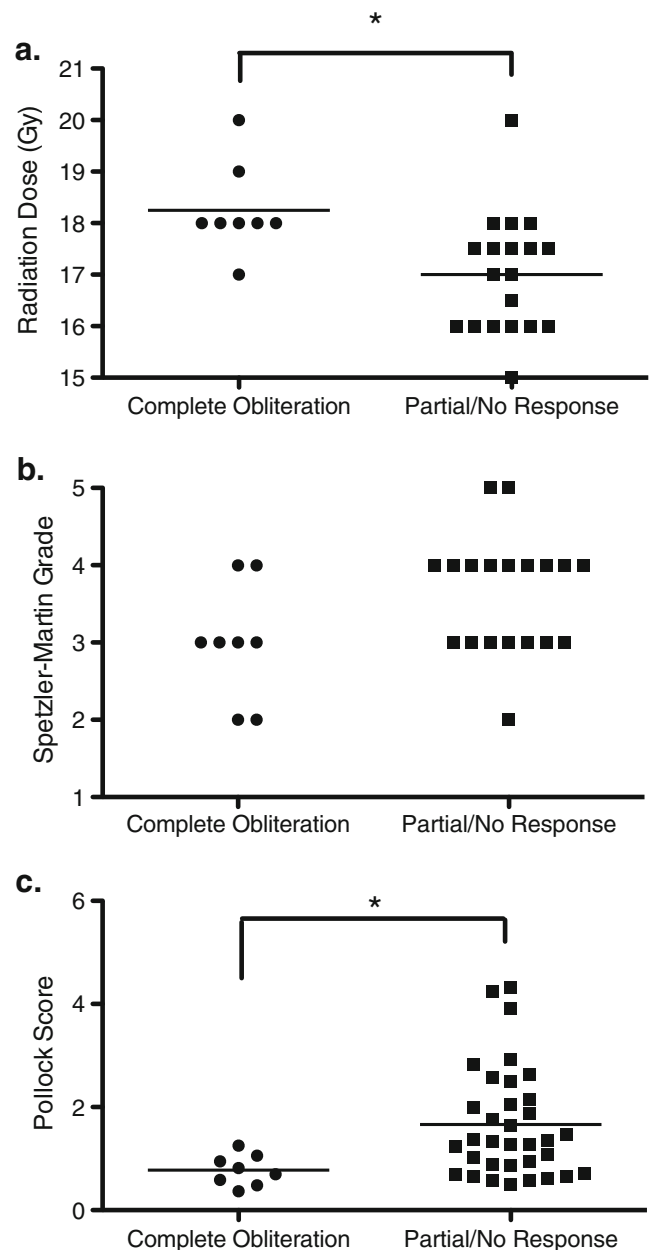
We found that patients who had complete AVM obliteration received higher SRS dose as compared to patients who had partial or no response, as shown in Fig. 1a (Mann–Whitney test,  $p < 0.01$ ). In this small series, there was no statistically significant association between pretreatment Spetzler–Martin grade and angiographic outcome (Mann–Whitney test,  $p = 0.07$ ), though there was a trend towards complete response in the lower grade lesions (Fig. 1b). Lower Pollock score was associated with complete obliteration (two-sided  $t$  test,  $p < 0.05$ ) (Fig. 1c).

Seven patients (17 %) suffered hemorrhage after SRS, ranging from 1 to 12 years after treatment, two of which resulted in death. There were no AVM hemorrhages prior to completion of staged SRS. Of these seven patients, five had a 3-year angiographic follow-up, which showed partial response in all. Other complications included new onset seizure in seven patients (17 %), significant nausea in one patient, and headache in 15 patients (37 %).

#### Angiographic features associated with treatment outcome

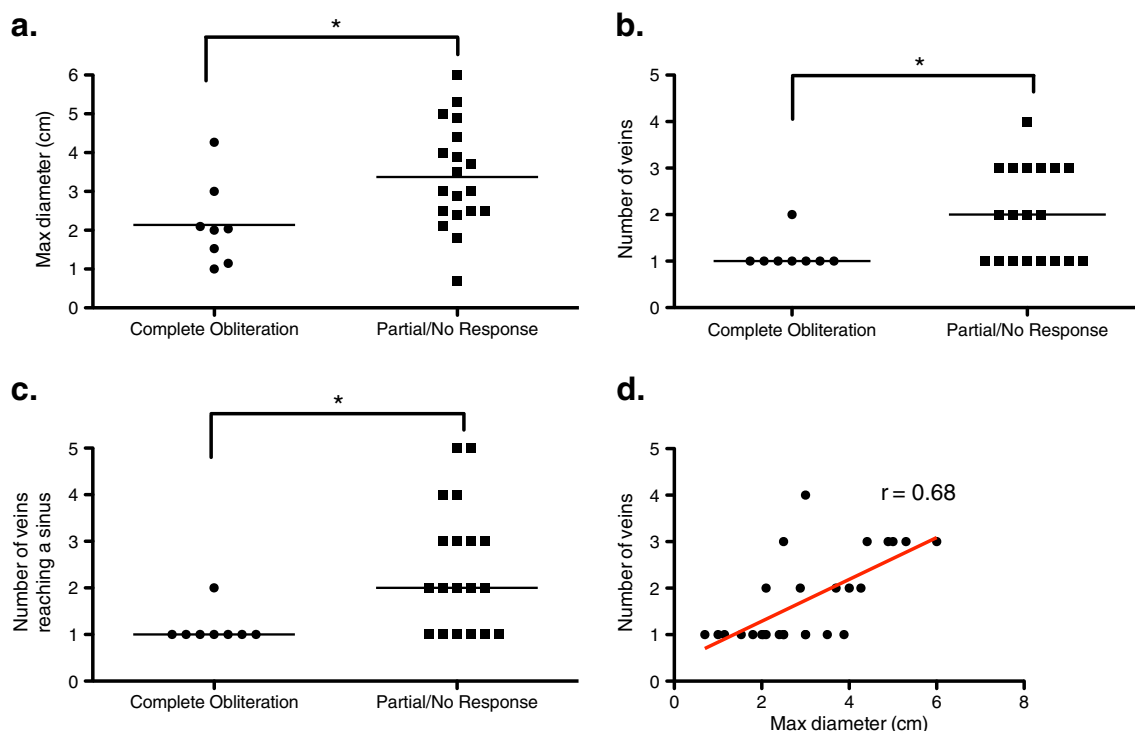
In univariate analysis, we identified several angiographic features, scored on pretreatment angiograms, as associated with treatment outcome after SRS. As shown in Fig. 2a, maximal diameter of AVM nidus was associated with obliteration rate, with complete obliteration more common in smaller AVMs and partial response more common in larger AVMs (two-sided  $t$  test,  $p < 0.05$ ). Using a cutoff size of 2.5 cm, AVMs with maximal diameter less than 2.5 cm were more likely to undergo complete obliteration after treatment (60 %) as compared to AVMs with maximal diameter greater than or equal to 2.5 cm (12 %) (Fisher's exact test,  $p < 0.05$ ).

In addition, several features of venous drainage were associated with treatment outcome. Complete obliteration, as compared to partial or no response, was seen more commonly in malformations with fewer draining veins (Mann–Whitney test,  $p < 0.05$ ), as seen in Fig. 2b. Indeed, lesions with more than one draining vein were less likely to undergo complete



**Fig. 1** Clinical characteristics and treatment outcome. Scatter plots depicting relationship of median prescription dose (a), Spetzler–Martin grade (b), and Pollock score (c) on treatment outcome. In all plots,  $*p < 0.05$  by two-sided  $t$  test or Mann–Whitney test comparing patients with complete obliteration against those with partial response. Horizontal line represents mean value

obliteration (7 %) compared to AVMs with only one draining vein (54 %; Fisher's exact test,  $p < 0.05$ ). Similarly, the number of draining veins reaching a sinus was associated with rate of obliteration, with complete obliteration observed more commonly in AVMs with fewer veins reaching a sinus (Mann–Whitney test,  $p < 0.05$ ), as seen in Fig. 2c. Malformations with more than one vein reaching a sinus were less likely to respond completely to therapy (7 %) compared to those with one vein reaching a sinus (54 %; Fisher's exact test,  $p < 0.05$ ).



**Fig. 2** Angiographic features and treatment outcome. Scatter plots demonstrating relationships of AVM size (a), total number of draining veins (b) and number of veins reaching a sinus (c) with treatment outcome. In all plots, horizontal line represents mean value. d Correlation plot of

AVM maximal diameter and number of draining veins. Red line represents linear correlation with  $r=0.68$  by Spearman's correlation.  $*p<0.05$  by two-sided Mann–Whitney test comparing patients with complete obliteration against those with partial or no response

There was a linear correlation between AVM size and number of draining veins (Spearman's correlation,  $r=0.68$ ,  $p<0.01$ ) (Fig. 2d).

Angiographic factors that were not associated with probability of complete obliteration in this small study included diffuse borders of the AVM, presence of aneurysm on the feeding arteries or inside the nidus, and treatment with embolization prior to SRS. In addition, there was no relationship between outcome and gender or age. Two patients were noted to have fistulous components to their AVMs. Both patients had not only partial response to SRS but also had large maximal AVM diameters (5 and 4.4 cm).

Several angiographic features were associated with hemorrhagic presentation. Patients who presented with hemorrhage were more like to have smaller AVMs compared to those who presented without hemorrhage ( $2.75\pm0.51$  vs  $4.37\pm0.50$  cm; two-sided  $t$  test,  $p<0.01$ ). In addition, of the eight patients found to have aneurysms on their pretreatment angiogram, seven presented with hemorrhage. This proportion is notably higher than the 18 out of 33 patients without aneurysms who presented with hemorrhage, although this relationship did not achieve statistical significance (Fisher's exact test,  $p=0.12$ ). All three patients with feeding artery aneurysms presented with hemorrhage, whereas four out of the five patients with intra-nidal aneurysms presented with

hemorrhage. Presence of venous stenosis was not associated with hemorrhagic presentation in this cohort.

### Discussion

Stereotactic radiosurgery is an established modality in the treatment of pediatric AVMs, either alone or in conjunction with surgical resection and/or embolization. When relatively safe, surgical resection is preferred over SRS, but SRS or SRS followed by microsurgical resection after partial response may be preferable for higher Spetzler–Martin grade AVMs [17]. A better understanding of complete obliteration rates and associated parameters may help guide decision-making. In this study, we examined whether certain angiographic features are associated with complete obliteration. We found that smaller AVM diameter, higher SRS dose, lower Pollock score, and fewer draining veins and fewer draining veins reaching a sinus were associated with increased rates of obliteration.

Recent studies in pediatric patients have reported rates of obliteration at 3 years that vary from 35 to 95 % [3, 4, 18–23]. Our rate of 30 % obliteration falls on the lower end of this distribution, and one possible explanation may be our relatively lower median prescription dosage. Compared to



other studies, our median dosages of 17 Gy (staged) and 18 Gy (single-session) were less than other studies with higher rates of obliteration, which report dosages of 18–25 Gy [1, 3]. As in our study, an association between higher obliteration rate and higher margin dose has been clearly seen [4, 6, 8]. In addition, the AVMs in our group were larger and higher grade. Studies reporting higher obliteration rates generally treated AVMs with smaller median target volumes, ranging from 2.5–4.2 ml and included 27–68 % Spetzler–Martin grade I and II lesions, compared to 11 % in this cohort [3, 4, 18, 19]. Two of the three of the Spetzler–Martin grade II lesions (67 %) were completely obliterated, as were 6 of the 16 grade III–V lesions (38 %), in rates which are comparable to other studies [4, 18, 19].

We found that maximal diameter of AVM as measured on angiography was significantly associated with obliteration after SRS. In keeping with findings in the adult population, larger AVMs in our series were less likely to respond completely to treatment [10, 12, 13]. Specifically, lesions with a diameter of <2.5 cm were more likely to respond (60 %) than those  $\geq 2.5$  cm (12 %). Unfortunately, larger SRS volumes need to be treated to lower prescription dose in order to maintain an acceptable complication rate. We perform volume-staged SRS for AVMs >8–10 ml as a strategy to reduce risk of giving  $\geq 17$  Gy to large AVMs.

Characteristics of the venous drainage system were also significantly associated with treatment outcome. An increased number of total draining veins and a number of veins reaching a sinus were associated with only partial response to SRS. While this observation has been seen in other series of adult patients, it remains unclear why this may be the case [2, 10, 24]. In our series, we found a close correlation between AVM diameter and number of draining veins, in that the larger AVMs had an increased number of draining veins. It is possible that the association between these venous features and response to SRS may in fact be due to AVM size. Pollock score, which we also found to be significantly associated with complete obliteration, includes target volume in its calculation.

Almost 30 % of the AVMs studied in this cohort were described as having diffuse borders. These diffuse-type AVMs are less common than those with a compact nidus and are sometimes considered to be relatively low-flow lesions with normal cerebral tissue between the abnormal vessels [4, 6, 8, 25]. Prior studies have found that these types of lesions are less likely to respond to treatment, by either radiosurgery or microsurgery [8, 10, 11, 26, 27]. In our study, we did not find an association between diffuse AVM borders and resistance to treatment with SRS.

Approximately 20 % of our cohort underwent embolization prior to SRS. We found that this adjunctive therapy did not have an influence on the eventual rate of obliteration afforded by SRS. Prior studies have shown similar ambivalence over the benefits of embolization with regard to ultimate obliteration

rates following SRS, though some studies have found a detrimental effect [3, 4, 18, 23]. At our institution, we most commonly perform embolization in patients with AVMs as a preoperative adjuvant. For patients with unresectable ruptured AVMs who will undergo SRS, we typically target embolization at high-risk features for rebleeding (including feeding artery aneurysms and nidus aneurysms) as opposed to trying to reduce the nidus volume prior to SRS.

We also evaluated for angiographic features associated with hemorrhagic presentation and found that smaller AVMs were more likely to present with hemorrhage than larger ones. This finding is in accordance with our understanding of these lesions, as smaller AVMs have been shown to contain higher feeding artery pressures and present more commonly with hemorrhage [28, 29]. In addition, although the finding did not achieve statistical significance, we found a trend towards an increase in hemorrhagic presentations in AVMs found to contain aneurysms on arterial feeders or inside the nidus on pretreatment angiogram. This finding has been noted before and an argument made for early aggressive therapy for these aneurysms as they may denote high risk for future hemorrhage [19–23, 30].

## Conclusion

Owing to their high rate of hemorrhage, both on presentation and over the long lifespan of a child, AVMs in the pediatric population often merit therapeutic intervention. Stereotactic radiosurgery has advantages over traditional microsurgical resection in that it is a noninvasive technique that can be applied in cases not amenable to safe surgical resection. The treatment modality, however, is limited by its complication risks, particularly at the higher doses that are known to be the most effective and for large AVMs not amenable to resection, as well as by the latency interval between the rendering of the treatment and the obliteration of the AVM, which can last up to 2 to 5 years. Using angiography to help predict which lesions will respond completely to therapy may help guide decision-making as well as manage expectations.

In our study, we identify smaller AVM diameter as measured on angiogram as associated with improved rate of obliteration, with 60 vs 12 % obliteration rate for AVMs <2.5 vs  $\geq 2.5$  cm, respectively. We also found that AVMs with more than one draining vein or more than one draining vein reaching a sinus were less likely to achieve complete obliteration by SRS. This effect may be confounded by AVM size; however, as larger AVMs were noted to have increased number of draining veins. These findings are consistent with prior findings in adult cohorts. However, unlike in the adult population, we found no effect in our small cohort on the rate of obliteration for AVMs with diffuse borders, prior embolization, or nidus aneurysms.

**Conflict of interests** There are no competing interests regarding the contents of this manuscript for any of the authors.

## References

- Smyth MD, Sneed PK, Circillo SF, Edwards MS, Wara WM, Larson DA, Lawton MT, Gutin PH, McDermott MW (2002) Stereotactic radiosurgery for pediatric intracranial arteriovenous malformations: the University of California at San Francisco experience. *J Neurosurg* 97:48–55. doi:10.3171/jns.2002.97.1.0048
- Ogilvy CS, Stieg PE, Awad I, Brown RD, Kondziolka D, Rosenwasser R, Young WL, Hademos G (2001) Recommendations for the management of intracranial arteriovenous malformations : a statement for healthcare professionals from a special writing group of the stroke council. *Am Stroke Assoc* 103:2644–2657. doi:10.1161/01.CIR.103.21.2644
- Buis DR, Dirven CMF, Lagerwaard FJ, Mandl ES, Lycklama á Nijeholt GJ, Eshghi DS, Berg R, Baayen JC, Meijer OWM, Sotman BJ, Vandertop WP (2008) Radiosurgery of brain arteriovenous malformations in children. *J Neurol* 255:551–560. doi:10.1007/s00415-008-0739-4
- Kano H, Kondziolka D, Flickinger JC, Yang H-C, Flannery TJ, Awan NR, Niranjan A, Novotny J, Lunsford LD (2012) Stereotactic radiosurgery for arteriovenous malformations, part 2: management of pediatric patients. *J Neurosurg Pediatr* 9:1–10. doi:10.3171/2011.9.PEDS10458
- Kondziolka D, Kano H, Yang H-C, Flickinger JC, Lunsford L (2010) Radiosurgical management of pediatric arteriovenous malformations. *Childs Nerv Syst* 26:1359–1366. doi:10.1007/s00381-010-1207-x
- Flickinger JC, Kondziolka D, Maitz AH, Lunsford LD (2002) An analysis of the dose–response for arteriovenous malformation radiosurgery and other factors affecting obliteration. *Radiother Oncol* 63:347–354
- Wara W, Bauman G, Gutin P, Circillo S, Larson D, McDermott M, Sneed P, Verhey L, Smith V, Petti P (1995) Stereotactic radiosurgery in children. *Stereotact Funct Neurosurg* 64(Suppl 1):118–125
- Yeon JY, Shin HJ, Kim J-S, Hong S-C, Lee J-I (2011) Clinico-radiological outcomes following gamma knife radiosurgery for pediatric arteriovenous malformations. *Childs Nerv Syst* 27:1109–1119. doi:10.1007/s00381-011-1401-5
- Karlsson B, Lindquist C, Steiner L (1997) Prediction of obliteration after gamma knife surgery for cerebral arteriovenous malformations. *Neurosurgery* 40:425–430, discussion 430–1
- Chang JH, Chang JW, Park YG, Chung SS (2000) Factors related to complete occlusion of arteriovenous malformations after gamma knife radiosurgery. *J Neurosurg* 93(Suppl 3):96–101. doi:10.3171/jns.2000.93.supplement.3.0096
- Lawrence YR, Li XA, el Naqa I, Hahn CA, Marks LB, Merchant TE, Dicker AP (2010) Radiation dose–volume effects in the brain. *Int J Radiat Oncol Biol Phys* 76:20–27. doi:10.1016/j.ijrobp.2009.02.091
- Pan DH, Guo WY, Chung WY, Shiao CY, Chang YC, Wang LW (2000) Gamma knife radiosurgery as a single treatment modality for large cerebral arteriovenous malformations. *J Neurosurg* 93(Suppl 3):113–119. doi:10.3171/jns.2000.93.supplement
- Pan DH-C, Kuo Y-H, Guo W-Y, Chung W-Y, Wu H-M, Liu K-D, Change Y-C, Wang L-W Wong T-T (2008) Gamma Knife surgery for cerebral arteriovenous malformations in children: a 13-year experience. *J Neurosurg Pediatr* 1:296–304. doi:10.3171/PED/2008/1/4/296
- Kwon Y, Jeon SR, Kim JH, Lee JK, Ra DS, Lee DJ, Kwun BD (2000) Analysis of the causes of treatment failure in gamma knife radiosurgery for intracranial arteriovenous malformations. *J Neurosurg* 93(Suppl 3):104–106. doi:10.3171/jns.2000.93.supplement.3.0104
- Spetzler RF, Martin NA (1986) A proposed grading system for arteriovenous malformations. *J Neurosurg* 65:476–483. doi:10.3171/jns.1986.65.4.0476
- Pollock BE, Flickinger JC (2008) Modification of the radiosurgery-based arteriovenous malformation grading system. *Neurosurgery* 63:239–243. doi:10.1227/01.NEU.0000315861.24920.92
- Sanchez-Mejia RO, McDermott MW, Tan J, Kim H, Young WL, Lawton MT (2009) Radiosurgery facilitates resection of brain arteriovenous malformations and reduces surgical morbidity. *Neurosurgery* 64:231–240. doi:10.1227/01.NEU.0000338068.44060.EA
- Yen CP, Monteith SJ, Nguyen JH, Rainey J, Schlesinger DJ, Sheehan JP (2010) Gamma Knife surgery for arteriovenous malformations in children. *J Neurosurg Pediatr* 6:426–434. doi:10.3171/2010.8.PEDS10138
- Zabel-du Bois A, Milker-Zabel S, Huber P, Schlegel W, Debus J (2006) Pediatric cerebral arteriovenous malformations: the role of stereotactic linac-based radiosurgery. *Int J Radiat Oncol Biol Phys* 65:1206–1211. doi:10.1016/j.ijrobp.2006.01.041
- Shin M, Kawamoto S, Kurita H, Tago M, Sasaki T, Morita A, Ueki K, Kirino T (2002) Retrospective analysis of a 10-year experience of stereotactic radio surgery for arteriovenous malformations in children and adolescents. *J Neurosurg* 97:779–784. doi:10.3171/jns.2002.97.4.0779
- Cohen-Gadol AA, Pollock BE (2006) Radiosurgery for arteriovenous malformations in children. *J Neurosurg* 104:388–391. doi:10.3171/ped.2006.104.6.388
- Maity A, Shu H-KG, Tan JE, Ruffer J, Sutton LN, Tochner Z, Lustig R (2004) Treatment of pediatric intracranial arteriovenous malformations with linear-accelerator-based stereotactic radiosurgery: the University of Pennsylvania experience. *Pediatr Neurosurg* 40:207–214. doi:10.1159/000082293
- Reyns N, Blond S, Gauvrit J-Y, Touzet G, Coche B, Pruvo J-P, Dhellemmes P (2007) Role of radiosurgery in the management of cerebral arteriovenous malformations in the pediatric age group: data from a 100-patient series. *Neurosurgery* 60:268–276. doi:10.1227/01.NEU.0000249277.72063.BD, discussion 276
- Pollock BE, Flickinger JC, Lunsford LD, Maitz A, Kondziolka D (1998) Factors associated with successful arteriovenous malformation radiosurgery. *Neurosurgery* 42:1239–1244, discussion 1244–7
- Chin LS, Raffel C, Gonzalez-Gomez I, Giannotta SL, McComb JG (1992) Diffuse arteriovenous malformations: a clinical, radiological, and pathological description. *Neurosurgery* 31:863–868, discussion 868–9
- Klimo P Jr, Rao G, Brockmeyer D (2006) Pediatric arteriovenous malformations: a 15-year experience with an emphasis on residual and recurrent lesions. *Childs Nerv Syst* 23:31–37. doi:10.1007/s00381-006-0245-x
- Zipfel GJ, Bradshaw P, Bova FJ, Friedman WA (2004) Do the morphological characteristics of arteriovenous malformations affect the results of radiosurgery? *J Neurosurg* 101:393–401. doi:10.3171/jns.2004.101.3.0393
- Spetzler RF, Hargraves RW, McCormick PW, Zabramski JM, Flom RA, Zimmerman RS (1992) Relationship of perfusion pressure and size to risk of hemorrhage from arteriovenous malformations. *J Neurosurg* 76:918–923. doi:10.3171/jns.1992.76.6.0918
- Kader A, Young WL, Pile-Spellman J, Mast H, Sciacca RR, Mohr JP, Stein BM (1994) The influence of hemodynamic and anatomic factors on hemorrhage from cerebral arteriovenous malformations. *Neurosurgery* 34:801–807, discussion 807–8
- Anderson RCE, McDowell MM, Kellner CP, Appelboom G, Bruce SS, Kotchetkov IS, Haque R, Feldstein NA, Connolly ES, Solomon RA (2012) Arteriovenous malformation-associated aneurysms in the pediatric population. *J Neurosurg Pediatr* 9:11–16. doi:10.3171/2011.10.PEDS11181