

UC Davis

Dermatology Online Journal

Title

Liquefactive subcutaneous fat necrosis of the newborn

Permalink

<https://escholarship.org/uc/item/0qj5d2h2>

Journal

Dermatology Online Journal, 30(6)

Authors

Esfandiari, Negar

Porter, Hannah J

Morley, Keith

Publication Date

2024

DOI

10.5070/D330664694

Copyright Information

Copyright 2024 by the author(s). This work is made available under the terms of a Creative Commons Attribution-NonCommercial-NoDerivatives License, available at

<https://creativecommons.org/licenses/by-nc-nd/4.0/>

Peer reviewed

Liquefactive subcutaneous fat necrosis of the newborn

Negar Esfandiari¹ MD, Hannah J Porter² MD MBA MS, Keith Morley^{1,2} MD

Affiliations: ¹Larner College of Medicine, The University of Vermont, Burlington, Vermont, USA, ²Division of Dermatology, The University of Vermont Medical Center, Burlington, Vermont, USA

Corresponding Author: Negar Esfandiari MD, Larner College of Medicine, The University of Vermont, 89 Beaumont Ave, Burlington, VT 05405, Tel: 802-922-6906, Email: Negar.Esfandiari@outlook.com

Abstract

Subcutaneous fat necrosis of the newborn is a disease affecting neonates in the first weeks to months of life. It is characterized by dermal edema and underlying fat necrosis, typically presenting with firm, erythematous subcutaneous plaques and nodules, often located on the shoulders, back, buttocks, thighs, and extremities. We report an unusual presentation of liquefactive subcutaneous fat necrosis of the newborn in a two-week old term infant. The neonatal period was complicated by respiratory failure requiring intubation and severe encephalopathy. After completion of therapeutic hypothermia, the patient developed fluctuant and liquefactive nodules on her back. The neonate also had initial hypocalcemia that required treatment and then developed hypercalcemia, that resolved without intervention. The nodules and plaques on her back persisted into the first year of life and then gradually started to improve when she was 13 months old.

Keywords: hypercalcemia, liquefactive, newborn, fat necrosis, subcutaneous, therapeutic hypothermia, ultrasound

Introduction

Subcutaneous fat necrosis of the newborn (SCFN) is a disease affecting neonates in the first weeks to months of life [1,2]. It is characterized by dermal edema and underlying fat necrosis, typically presenting with firm, erythematous subcutaneous plaques and nodules, often located on the shoulders, back, buttocks, thighs, and extremities [1,2]. Subcutaneous fat necrosis of the newborn can

present in pre-term, term, and post-term infants [1,2]. Although there are cases of SCFN with no visible overlying skin changes, there is often erythema and associated skin color changes, such as a red-to-violaceous hue [1,2]. The nodules and plaques are usually tender and painful, but SCFN may also be asymptomatic [3]. The risk factors for SCFN include maternal gestational diabetes, pre-eclampsia, cocaine use, calcium-channel blocker use during pregnancy, maternal-fetal Rh incompatibility, the use of forceps during delivery, fetal umbilical cord prolapse, meconium aspiration, perinatal asphyxia, infections/neonatal sepsis, fetal macrosomia, newborn anemia or thrombocytosis, the use of therapeutic cooling, and infant cardiac surgery [1,3,4].

Case Synopsis

A term female infant born at 40 weeks and two days gestation via emergency C-section for fetal bradycardia secondary to placental abruption was admitted to the neonatal intensive care unit. The patient's birth weight was 4.23kg (98% percentile) and Apgar scores were 0/0/2 at 1, 5, and 10 minutes, respectively. The neonatal period was complicated by respiratory failure requiring intubation and severe encephalopathy. She received therapeutic hypothermia for a duration of four days. After completion of therapeutic hypothermia, the patient was found to have fluctuant nodules across her left upper back extending to her lumbar spine, for which a dermatology consult was enlisted.

Physical examination revealed a large, irregularly shaped, soft nodular plaque on the patient's central

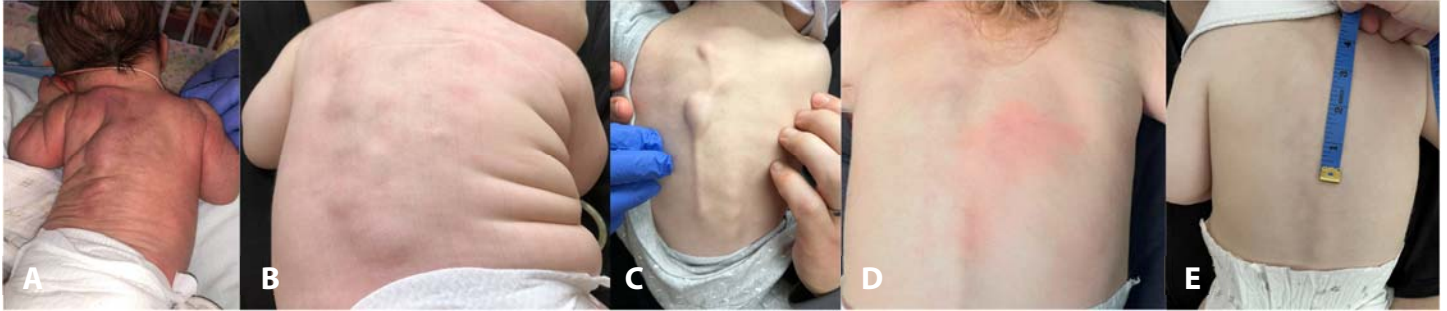


Figure 1. Progression of the patient's subcutaneous fat necrosis of the newborn, from age two weeks to 17 months. **A)** Large and irregularly shaped nodules, and soft and extremely fluctuant cystic plaques (patient age: two weeks). **B)** Less fluctuant and firmer subcutaneous plaques on the back (patient age: two months). **C)** A firm, mobile nodule and plaque on the mid lateral upper back (patient age: 10 months). **D)** Significantly smaller and softer plaques on the mid upper back (patient age: 13 months). **E)** Almost complete resolution of plaques (patient age: 17 months).

to left upper back. At the superior and inferior ends of this plaque were firmer nodules, whereas the center was fluctuant (**Figure 1A**). An ultrasound of the back was obtained, which demonstrated an ill-defined region of hypoechoic soft tissue in the right upper back with interspersed fluid collections and increased peripheral color Doppler vascularity. The largest collection measured approximately 1.4cm×0.2cm×4cm on ultrasound (**Figure 2**). Invasive procedures such as skin biopsy were avoided owing to concern for infection, persistent drainage, and poor healing. A presumed diagnosis of subcutaneous fat necrosis of the newborn was made based on the clinical history, the physical examination findings of subcutaneous nodules and plaques with overlying erythema and edema, as well as the ultrasound findings. The patient had three notable risk factors for developing SCFN. The patient was large for gestational age, experienced fetal hypoxia, and underwent therapeutic hypothermia for treatment of hypoxic-ischemic encephalopathy.

The patient required multiple doses of calcium gluconate for treatment of hypocalcemia. Subsequently, when she was 16 days old, her calcium levels became elevated and peaked to 11.8mg/dl (reference range 8.3-10.6mg/dl). However, she remained asymptomatic and did not require intervention. The patient was discharged from the hospital at four weeks of age, with follow-up with a multidisciplinary care team consisting of neurology, gastroenterology, nephrology, dermatology, ophthalmology, nutrition, and social services. Her calcium levels were checked twice in the first two

weeks after discharge and then again once every 2-4 months until the age of 11 months.

The patient presented to the dermatology clinic for follow-up at two months of age. On physical examination, her back had firmer and less fluctuant subcutaneous plaques, which no longer extended to the left scapular skin (**Figure 1B**).

She was seen again in the dermatology clinic for follow-up at the age of 10 months. On physical examination, her back had a firm mobile nodule (**Figure 1C**). Although previous blood work had demonstrated intermittently elevated calcium levels, this had normalized without intervention by this visit at the age of 10 months. A repeat ultrasound of the chest at age 11 months demonstrated elongated circumscribed nonvascular echogenic tissue with regions of nodularity, entirely encased in a continuous band of hypoechoic fibrous appearing tissue. Although atypical in appearance, these findings were still favored to represent sequela of presumed liquefactive fat necrosis. The patient was

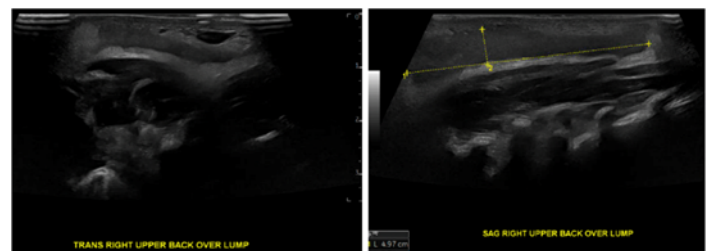


Figure 2. Ultrasound of chest at age two weeks. Ill-defined region of hypoechoic soft tissue in the right upper back with interspersed fluid collections and increased peripheral color Doppler vascularity. The largest collection measuring approximately 1.4cm×0.2cm×4cm.

seen in follow-up at age 13 and 17 months and had notable improvement, with a decrease in size of her truncal plaques (**Figure 1D, E**). A repeat ultrasound at age 17 months demonstrated a decrease in thickness of the previously described lesion in the right upper back; there had also been interval change in the echogenicity suggesting developing mineralization. Findings were most compatible with evolving fat necrosis with a hypoechoic encapsulating rim. Repeat serum calcium levels remained normal. Given the degree of improvement, there will likely be complete resolution in the future without a need for any surgical revision.

Case Discussion

There are different theories behind the mechanism that causes fat necrosis. One proposed mechanism is related to the composition of fat in neonates, as there is a higher amount of saturated fatty acids in the neonatal hypodermis as compared to adults. These saturated fatty acids have a higher melting point and with tissue insult, such as through mechanical stress or tissue hypoxia, this fat crystallizes at colder temperatures, which leads to necrosis [1,5]. Subcutaneous fat necrosis of the newborn presents with firm plaques and nodules. However, in our patient, the lesions were unusually fluctuant and determined to be liquefactive, which is an uncommon presentation. A few reports have been published which illustrate atypical cases of SCFN, such as with a fluctuant lobulated cystic plaque [6], a firm nodule with central fluctuance [7], fluctuant abscess-like nodules [8,9], and formation of a hematoma and skin necrosis [10]. Furthermore, SCFN often spontaneously resolves within weeks to months [3,4]. However, our patient continued to harbor residual lesions of SCFN at 11 months of age, which was unusual given its persistent duration and lack of spontaneous resolution. At age 13 months, the plaques started to decrease in size and started to show more notable improvement such that they were almost completely resolved by age 17 months.

The differential diagnosis for SCFN includes sclerema neonatorum, fibrous tumors, lipoblastoma, post-vaccination subcutaneous fat inflammation, cold panniculitis, and cellulitis [1,2,11]. Diagnosis is often

made with ultrasound imaging [1]. If a biopsy is obtained, histology would demonstrate necrotizing granulomas, lobular panniculitis with a mixed inflammatory infiltrate, foreign body giant cells, and needle-shaped clefts in adipocytes [1,5]. Infants who have been diagnosed with SCFN should be screened for hypercalcemia; notably, the development of hypercalcemia may be delayed for up to 6 months [11,12]. Signs of hypercalcemia include irritability, lethargy, hypotonia, emesis, dehydration, seizures, renal failure, and death [1,5,11-13]. Del Pozzo-Magana et al. have outlined screening recommendations for patients with SCFN [14]. If the baseline calcium levels are normal, then the calcium should be re-checked weekly for the first month and then monthly until 6 months of age, or until after the skin findings resolve. If there is hypercalcemia at baseline, then the calcium levels should be re-checked twice weekly until it returns within normal limits. Then it should be checked monthly until 6 months of age, or until after the skin findings resolve [14]. If the neonate develops symptomatic or persistent hypercalcemia, it should be promptly treated; treatments include intravenous hydration with normal saline, furosemide, corticosteroids, bisphosphonates, calcitonin, citrate (to prevent kidney stone formation), and a low vitamin D and calcium diet [13,14]. In addition to testing total and ionized calcium levels, further baseline labs should include evaluating glucose, triglycerides, creatinine, and platelet counts [14]. A baseline abdominal ultrasound (liver, spleen, and kidneys) should also be considered and repeated at three months to assess for internal calcinosis [14]. If the patient has hypercalcemia or calcinosis, repeat abdominal ultrasounds should be obtained every 3-6 months and then annually until two normal imaging results are obtained [12,14]. Although often a benign and self-limited form of panniculitis, SCFN of the newborn can pose significant harm to the infant through metabolic derangements and complications, including hypoglycemia, hypertriglyceridemia, hypercalcemia, thrombocytopenia; these can lead to kidney injury and renal failure [2,11]. Another possible complication of SCFN is the development of subcutaneous atrophy [4].

Subcutaneous fat necrosis of the newborn is often self-resolving and treatment should focus on

symptomatic care [12]. Surgical removal of the nodules may also be considered in certain cases, such as with the presence of ulcerated plaques, skin necrosis, calcifications, hematoma, or lack of regression [10,12,15,16]. In our patient, the hypercalcemia was asymptomatic and resolved without treatment. The patient underwent a follow-up ultrasound that documented stability and involution of the remaining plaque and given the significant improvement, no surgical revision was clinically necessary.

Conclusion

Subcutaneous fat necrosis of the newborn is a disease that can affect pre-term, term, and post-term

neonates in the first weeks to months of life. It is characterized by dermal edema and underlying fat necrosis, typically presenting with firm, erythematous subcutaneous plaques and nodules and is often diagnosed with ultrasound imaging. Hypercalcemia is a possible complication of this disease and laboratory work should be monitored. We present an unusual presentation of SCFN in an infant who had fluctuant and liquefactive nodules, with persistent nodules and plaques into the first year of life; near resolution was observed by the age of 17 months.

Potential conflicts of interest

The authors declare no conflicts of interest.

References

- Restrepo R, Inarejos Clemente EJ, Corral G, et al. Subcutaneous fat necrosis of the newborn: a pictorial essay of an under-recognized entity. *Pediatr Radiol.* 2022;53:313-323. [PMID: 36151218].
- Mitra S, Dove J, Somisetty SK. Subcutaneous fat necrosis in newborn—an unusual case and review of literature. *Eur J Pediatr.* 2011;170:1107-1110. [PMID: 21318229].
- Rubin G, Spagnut G, Morandi F, Valerio E, Cutrone M. Subcutaneous fat necrosis of the newborn. *Clin Case Rep.* 2015;3:1017-1020. [PMID: 26734138].
- Mahé E, Girszyn N, Hadj-Rabia S et al. Subcutaneous fat necrosis of the newborn: a systematic evaluation of risk factors, clinical manifestations, complications and outcome of 16 children. *Br J Dermatol.* 2007;156:709-715. [PMID: 17493069].
- Repiso-Jiménez JB, Márquez J, Sotillo I, García-Bravo B, Camacho F. Subcutaneous fat necrosis of the newborn. *J Eur Acad Dermatol Venereol.* 1999;12:254-257. [PMID: 10461649].
- Balfour E, Antaya RJ, Lazova R. Subcutaneous fat necrosis of the newborn presenting as a large plaque with lobulated cystic areas. *Cutis.* 2002;70:169-173. [PMID: 12353893].
- Lund JJ, Xia L, Kerr S, Stratman EJ, Patten SF. The utility of a touch preparation in the diagnosis of fluctuant subcutaneous fat necrosis of the newborn. *Pediatr Dermatol.* 2009;26:241-243. [PMID: 19419492].
- Schubert PT, Razak R, Jordaan HF. Fine-Needle Aspiration as a Method of Diagnosis of Subcutaneous Fat Necrosis of the Newborn. *Pediatr Dermatol.* 2016;33:e220-e221. [PMID: 27125326].
- Schubert PT, Razack R, Vermaak A, Jordaan HF. Fine-needle aspiration cytology of subcutaneous fat necrosis of the newborn: the cytology spectrum with review of the literature. *Diagn Cytopathol.* 2012;40:245-247. [PMID: 22334526].
- Heskin L, Khan MAA, Ho PH, Burge T. Subcutaneous fat necrosis requiring plastic surgical intervention in an infant treated with whole-body cooling [published correction appears in *JPRAS Open.* 2021;30:172-173]. *JPRAS Open.* 2017;15:61-65. [PMID: 32158800].
- Stefanko, NS, Drolet, BA. Subcutaneous fat necrosis of the newborn and associated hypercalcemia: A systematic review of the literature. *Pediatr Dermatol.* 2019;36:24-30. [PMID: 30187956].
- O' Brien N, Hayes B. Subcutaneous fat necrosis of the newborn. *BMJ Case Rep.* 2019;12:e231458. [PMID: 31843770].
- Tran JT, Sheth AP. Complications of subcutaneous fat necrosis of the newborn: a case report and review of the literature. *Pediatr Dermatol.* 2003;20:257-261. [PMID: 12787278].
- Del Pozzo-Magaña BR, Ho N. Subcutaneous Fat Necrosis of the Newborn: A 20-Year Retrospective Study. *Pediatr Dermatol.* 2016;33:e353-e355. [PMID: 27574011].
- Perrotta R, Virzi D, Tarico MS. A rare case of congenital ulcerated subcutaneous fat necrosis of the newborn. *J Plast Reconstr Aesthet Surg.* 2010;63:e801-e802. [PMID: 20584635].
- Beuzeboc Gérard M, Aillet S, Bertheuil N, et al. Surgical management of subcutaneous fat necrosis of the newborn required due to a lack of improvement: a very rare case. *Br J Dermatol.* 2014;171:183-185. [PMID: 24359190].