

UC Davis

UC Davis Previously Published Works

Title

Effect of valacyclovir on EHV-5 viral kinetics in horses with equine multinodular pulmonary fibrosis

Permalink

<https://escholarship.org/uc/item/0qt629cm>

Journal

Journal of Veterinary Internal Medicine, 32(5)

ISSN

0891-6640

Authors

Easton-Jones, Charlotte A
Madigan, John E
Barnum, Samantha
et al.

Publication Date

2018-09-01

DOI

10.1111/jvim.15230

Peer reviewed

STANDARD ARTICLE

Effect of valacyclovir on EHV-5 viral kinetics in horses with equine multinodular pulmonary fibrosis

Charlotte A. Easton-Jones¹  | John E. Madigan² | Samantha Barnum² | Lara K. Maxwell³ | Sandra D. Taylor⁴ | Terry Arnesen⁵ | Nicola Pusterla²

¹William R Pritchard Veterinary Medical Teaching Hospital, University of California Davis, California

²Department of Medicine and Epidemiology, University of California, Davis, California

³Department of Physiological Sciences, Center for Veterinary Health Sciences, Oklahoma State University, Stillwater, Oklahoma

⁴Department of Veterinary Clinical Sciences, Purdue University, West Lafayette, Indiana, IN

⁵Stillwater Equine Veterinary Clinic, Stillwater, Minnesota

Correspondence

C. Easton-Jones, University of California Veterinary Medical Teaching Hospital, 1 Shields Avenue, Davis, CA 95616.
Email: caeastonjones@ucdavis.edu

Funding information

University of California, Davis Center for Equine Health with funds provided by the State of California satellite wagering fund and contributions by private donors.

Background: Equine herpesvirus-5 is commonly isolated from the lungs of horses with EMPF, suggesting an etiological link. Valacyclovir is used empirically to treat EMPF; however, no data is available concerning its impact on EHV-5 viral kinetics.

Objectives: To determine the effect of oral administration of valacyclovir on EHV-5 viral load measured by qPCR in blood, nasal secretions (NS) and BALF in horses with EMPF.

Animals: Six horses diagnosed with EMPF.

Methods: A prospective clinical trial was performed. Horses received 10 days of PO administered valacyclovir (loading dose 30 mg/kg, maintenance dose 20 mg/kg). Blood, NS, and BALF were collected for EHV-5 viral kinetics analyses during treatment. Blood and NS were collected every other day. BALF was collected on day 0 and day 10.

Results: There was no statistical difference in median EHV-5 viral load between day 0 and day 10 for all samples tested. In blood median EHV-5 viral load was 7676 (range 575-39 781) on day 0 and 6822 (range 1136-18 635) glycoprotein B (gB) gene copies per million cells on day 10. For NS median EHV-5 viral load was 2.944×10^6 (range 184 691-3.394 $\times 10^9$) on day 0 and 8.803×10^6 (range 251 186-9.868 $\times 10^8$) gB gene copies per million cells on day 10. For BALF median EHV-5 viral load was 59,842 (range 61-315 655) on day 0 and 185 083 (range 3562-542 417) gB gene copies per million cells on day 10.

Conclusions and Clinical Importance: Valacyclovir might not be an effective short-term antiviral treatment but efficacy in treatment of EMPF is unknown.

KEYWORDS

anti-viral drugs, herpesvirus, interstitial pneumonia, qPCR

1 | INTRODUCTION

Equine multinodular pulmonary fibrosis (EMPF) is a chronic, progressive, interstitial lung disease of adult horses. The disease is characterized histologically by marked interstitial fibrosis and mixed inflammatory cell infiltration of the lungs.^{1,2} The exact pathogenesis and predisposing factors currently remain elusive; however, there is increasing evidence

Abbreviations: BALF, bronchoalveolar lavage fluid; EBV, Epstein Barr virus; EHV-1, equine herpesvirus-1; EHV-5, equine herpesvirus-5; EMPF, equine multinodular pulmonary fibrosis; HHV-4, human herpesvirus-4; HPLC, high performance liquid chromatography; IPF, idiopathic pulmonary fibrosis; NSAIDs, non-steroidal anti-inflammatory drugs; qPCR, quantitative polymerase chain reaction

that equine herpesvirus-5 (EHV-5) is associated with EMPF. Equine herpesvirus-5 has been detected from the lungs of the majority of EMPF cases described in the literature, suggesting an etiological link.¹⁻¹¹ Furthermore, pulmonary fibrosis has recently been experimentally induced with EHV-5 isolated from the lungs of horses with EMPF and inoculated endoscopically into the accessory lung lobe of clinically normally horses. Nodular pulmonary fibrosis and myofibroblast induction occurred in the EHV-5 inoculated horses.³ Parallels have been drawn between human idiopathic pulmonary fibrosis (IPF) and EMPF. In IPF, gammaherpesviruses such as human herpesvirus-4 (HHV-4; Epstein Barr Virus [EBV]) are believed to be important cofactors in development of the condition.^{4,12-15} Current theories suggest that EHV-5 might be an

This is an open access article under the terms of the Creative Commons Attribution-NonCommercial License, which permits use, distribution and reproduction in any medium, provided the original work is properly cited and is not used for commercial purposes. © 2018 The Authors. Journal of Veterinary Internal Medicine published by Wiley Periodicals, Inc. on behalf of the American College of Veterinary Internal Medicine.

inciting cause of epithelial injury in EMPF cases, with the development of an unrestrained, disproportionate healing response resulting in pulmonary fibrosis.^{4,7}

Current treatment of EMPF cases is focused on attempting to control the ongoing pulmonary inflammation and prevent further fibrosis.^{5,7} Corticosteroids and nonsteroidal anti-inflammatory drugs (NSAIDs) are frequently used to reduce pulmonary inflammation and control pyrexia. Tetracycline antimicrobial drugs, including minocycline and doxycycline, can attenuate the activity of metalloproteinases and are beneficial in murine models of pulmonary disease.¹⁶ Tetracycline antimicrobial drugs are often employed for their antifibrotic and anticollagenase effects.⁵ Use of the antiviral prodrug valacyclovir has been described in 1 horse with EMPF that was reported to be clinically healthy 2 years after treatment.^{11,17} Valacyclovir is produced by ester linking of acyclovir with the amino acid L-valine, increasing the drug's oral bioavailability. After oral administration, the prodrug valacyclovir is promptly hydrolysed to acyclovir, an inhibitor of viral DNA polymerase. Valacyclovir has been used both prophylactically and therapeutically in equine herpesvirus-1 (EHV-1) outbreaks to decrease viremia and virus shedding.¹⁸ Treatment of horses with PO administered valacyclovir is relatively expensive and to the authors' knowledge, there are currently no studies investigating the effect of valacyclovir on EHV-5 viral kinetics in horses with EMPF. We hypothesised that treatment with valacyclovir would decrease the EHV-5 viral load as measured by real-time quantitative polymerase chain reaction (qPCR) of blood, nasal secretions (NS), and bronchoalveolar lavage fluid (BALF) in horses with EMPF. The objective of our study was to determine the effect of oral administration of valacyclovir on qPCR EHV-5 viral kinetics on blood, NS and BALF in horses with EMPF. Plasma samples collected during the maintenance phase of treatment were analyzed by high performance liquid chromatography (HPLC) to ensure the acyclovir concentrations obtained were comparable to previous studies.^{15,18}

2 | MATERIALS AND METHODS

2.1 | Study population

The study population consisted of 6 adult horses with a median age of 19 years (range 11–22 years) and examined between 2015 and 2017. Four horses were seen at the William R. Pritchard Veterinary Medical Teaching Hospital, School of Veterinary Medicine, University of California at Davis. One horse was seen at the Veterinary Teaching Hospital, College of Veterinary Medicine, Purdue University and 1 horse was examined at Stillwater Equine Veterinary Clinic in Minnesota. The horses belonged to the following breeds: Quarter Horse (n = 2), Warmblood (n = 1), Thoroughbred (n = 1), Paint (n = 1), and Saddlebred (n = 1). The study population included 3 geldings and 3 mares. All horses presented with tachypnea, increased respiratory effort, fever and weight loss. Five horses were diagnosed with EMPF based on consistent histopathological results and qPCR-positive EHV-5 testing of lung tissue or BALF. The remaining horse had consistent clinicopathological and diagnostic imaging findings and was qPCR positive

for EHV-5 on testing of BALF but the owners declined confirmation by histopathology and EHV-5 qPCR testing of lung tissue.

2.2 | Sample analysis

The study was designed as a prospective clinical trial during which horses diagnosed with EMPF would undergo 10 days of treatment with PO administered valacyclovir. This duration of valacyclovir treatment was selected based on previous evidence that 1–2 weeks of PO administered valacyclovir treatment was sufficient to decrease viremia and virus shedding of EHV-1 in horses.¹⁸ Throughout treatment, the viral load of EHV-5 was measured via qPCR of blood, NS and BALF. The horses in our study were treated with a loading dose of 30mg/kg valacyclovir (Valtrex, GlaxoSmithKline, Research Triangle Park, North Carolina) PO q8h for the 1st 48 hours. The dose was then decreased to 20 mg/kg valacyclovir PO q12h for a further 192 hours. This protocol was chosen based on pharmacokinetic studies demonstrating that these dosages achieved appropriate therapeutic concentrations of acyclovir in the blood for treatment of EHV-1.¹⁹ Four horses required administration of flunixin meglumine (Banamine, Merck Animal Health, Madison, New Jersey) (0.5mg/kg PO q12h) to control fevers over the 10-day treatment course. After 10 days of valacyclovir treatment, these 4 horses were administered minocycline (minocycline hydrochloride, Actavis Pharma Inc, Parsippany, New Jersey; 4 mg/kg PO q12h) and dexamethasone (Dexamethasone, Bimeda-MTC Animal Health Inc, Cambridge, Ontario, Canada; 0.1 mg/kg IV or IM q24h). The remaining 2 horses presented later in the course of the disease process based on severity of diagnostic imaging findings and clinical signs. Therefore, these 2 horses received combination treatment with valacyclovir, dexamethasone (0.1 mg/kg IV or IM q24h), flunixin meglumine (0.5 mg/kg PO q12h), and minocycline (4 mg/kg PO q12h).

Blood and NS for EHV-5 qPCR were collected every other day during treatment (days 0, 2, 4, 6, 8, and 10). For each horse, whole blood was collected into a 3-mL evacuated glass vial containing EDTA and refrigerated before processing for nucleic acid extraction. Two 15-cm rayon-tipped swabs (Puritan Sterile Rayon Tipped Applicators) were used to collect NS. The swabs were placed into the ventral meatus of either the right or left nostril and allowed to absorb the secretions for approximately 5 seconds while gently turning the swab. After collection of the NS, both swabs were immediately placed into a red-top tube (no anticoagulant) and refrigerated until nucleic acid processing. Bronchoalveolar lavage fluid was collected on day 0 (before treatment) and day 10 (after valacyclovir treatment was completed). The horses were sedated with a combination of detomidine hydrochloride (Dormosedan, Zoetis, Parsippany, New Jersey; 0.01 mg/kg IV) and butorphanol tartrate (Torbugesic, Zoetis, Parsippany, New Jersey; 0.01 mg/kg IV) for BALF collection. A 240-cm BAL tube was passed into the ventral meatus of either the left or right nostril and into the trachea. To reduce coughing and irritation during passing of the BAL tube, 50 mL of 1% lidocaine (Xylocaine, Fresenius Kabi USA LLC, Lake Zurich, Illinois IL) was instilled in the distal trachea and bronchi. The tube continued to be passed until it was wedged in the most distal bronchus. The tube was held in position while 240 mL of warm sterile 0.9% saline was injected into the BAL tube. The BALF was then recovered into sterile 60 mL syringes and the fluid was refrigerated

until processing for nucleic acid extraction. If multiple syringes of BALF were retrieved, a pooled sample of BALF (equal amounts from each syringe) was submitted for analysis. Pretreatment and post-treatment BALF qPCR results were available for 5 horses. The 6th horse had the pretreatment BALF analyzed and the owner declined the post-treatment BAL.

Nucleic acid extraction from whole blood, NS and BALF were performed as previously described.²⁰ Briefly, an automated nucleic acid extraction system (CAS-1820 X-tractor Gene) was used. Blood, NS, and BALF were assayed for the presence of the glycoprotein B (gB) gene of EHV-5. All samples were assayed for the presence of the housekeeping gene eGAPDH as previously described to ensure sample quality and effectiveness of nucleic acid extraction.²¹ Standard curves for EHV-5 and eGAPDH, expressed as EHV-5 gB gene copies per million cells, were performed to allow complete quantification of EHV-5 target molecules.²⁰

2.3 | Acyclovir assay

Serum concentrations of acyclovir were determined by HPLC. Blood samples were collected from all horses during the predicted steady-state phase of treatment (day 4) to determine steady-state peak and trough plasma acyclovir concentrations.¹⁹ Peak samples were collected 45 minutes after oral administration of valacyclovir. Trough samples were collected 12 hours after administration of the previous valacyclovir dose, just before the next dose. Ten milliliter of whole blood was collected into a vacuum-sealed tube containing lithium heparin. The tube was centrifuged within an hour of collection at 2800g for 5 minutes. Plasma was separated and frozen at -80°C until analysis. Plasma acyclovir concentrations were determined by HPLC, as previously described.¹⁹

2.4 | Data analysis

A Mann Whitney test was used to compare the differences in EHV-5 gB genes per million cells measured by qPCR between day 0 and day 10 for each of the 3 sample types (whole blood, NS, and BALF). *P* values $< .05$ were considered statistically significant.

3 | RESULTS

There was no statistical difference in median EHV-5 viral load between day 0 and day 10 as measured by qPCR in whole blood, NS, and BALF (Figure 1). The median and range EHV-5 viral loads in gB gene copies per million cells for each sample type are included in Table 1. The peak acyclovir concentrations obtained were (mean \pm s.d. = 1.48 ± 0.6 $\mu\text{g}/\text{mL}$) and the trough acyclovir concentrations obtained were (mean \pm s.d. = 0.53 ± 0.26 $\mu\text{g}/\text{mL}$; Figure 2); 5/6 (83%) of the horses were euthanized because of progression of clinical signs. These signs included continued weight loss, fevers uncontrolled by administration of NSAIDs and development of respiratory distress. Median time from diagnosis to euthanasia was 34 days (range 18–63 days). One horse is currently alive at 1 year after diagnosis and is maintained on fluticasone (Flovent, GlaxoSmithKline, Research

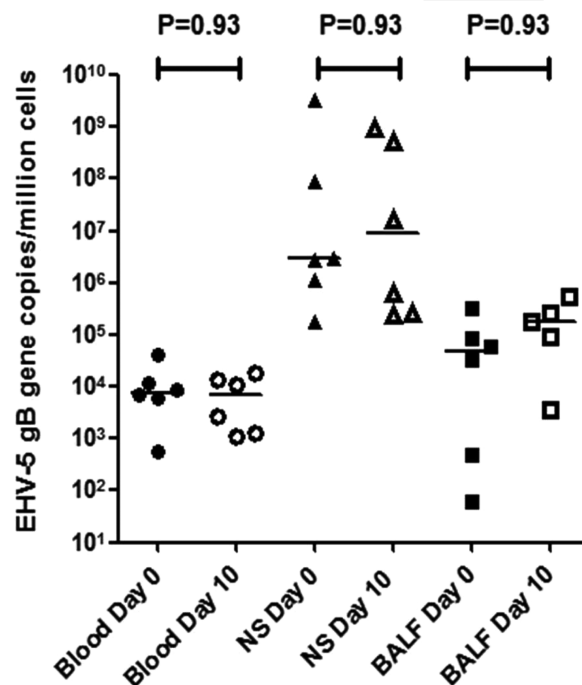


FIGURE 1 Median EHV-5 viral load (gB gene copies per million cells) in blood, NS, and BALF before treatment (day 0) and after 10 days (day 10) of oral administration of valacyclovir treatment in 6 horses with equine multinodular pulmonary fibrosis

Triangle Park, North Carolina; 2.4 $\mu\text{g}/\text{kg}$ q12h inhaled). The horse has gained weight (current BCS = 6/9), complete blood count has normalized and it is clinically healthy with the exception of mild tachypnea.

4 | DISCUSSION

In our study, valacyclovir was not effective at decreasing the viral load of EHV-5 in horses with EMPF. There was no significant change in EHV-5 viral load in any of the 3 sample types measured. Individual variation in EHV-5 viral load was evident in the samples tested over the 10 days of treatment but median values were consistent. In all horses tested, EHV-5 viral load in BALF increased after the treatment, indicating ongoing viral replication in the lungs. Acyclovir administered PO has poor bioavailability and therefore the use of the prodrug valacyclovir is necessary to ensure adequate acyclovir plasma concentrations.^{22–24} Acyclovir has a time-dependent pharmacokinetic-pharmacodynamic pattern with trough acyclovir plasma concentrations most predictive of acyclovir efficacy.¹⁸ Mean trough acyclovir concentration achieved was slightly lower but comparable to the mean trough concentration achieved in the previous Maxwell et al. study.¹⁹ The mean peak acyclovir concentrations attained were considerably lower than those achieved previously.¹⁹ These differences were likely attributable to the delivery method of the valacyclovir. In our study, the valacyclovir tablets were administered PO via a syringe in contrast to the intragastric delivery utilized in the previous study. Oral administration of valacyclovir allowed ease of delivery of the drug but might have resulted in a partial loss of the dose.

TABLE 1 Median and range EHV-5 viral load (gB gene copies per million cells) in blood, NS, and BALF during 10 days of oral administration of valacyclovir treatment in 6 horses with equine multinodular pulmonary fibrosis

	Blood			Nasal secretions			BALF		
	Median	Min	Max	Median	Min	Max	Median	Min	Max
Day 0	7676	575	39,781	2 944 476	184 691	3 394 468 530	59 842	61	315 655
Day 2	7538.5	412	53,561	7 010 820	453 248	998 849 768			
Day 4	5957.5	880	56,122	8 324 702	5858	144 798 989			
Day 6	2119	1382	49,853	9 020 104	1 521 240	506 622 081			
Day 8	3966	400	15,125	110 967 745	4 455 882	2 032 360 056			
Day 10	6822	1136	18,635	8 802 966	251 186	986 784 611	185 083	3562	542 417

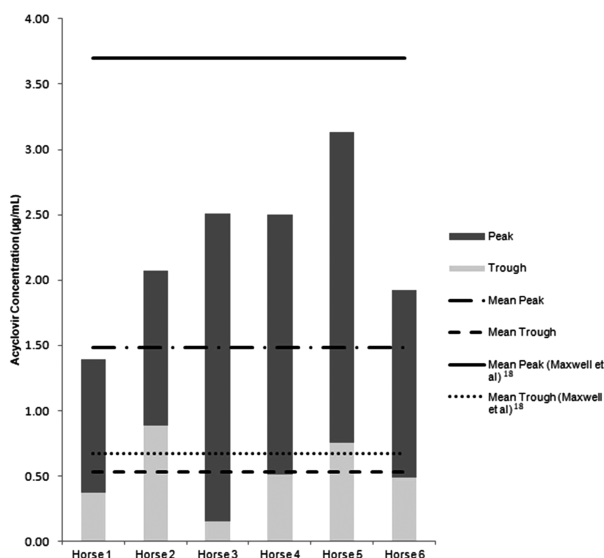
Our study confirmed that a loading dose of 30 mg/kg PO q8h for 2 days followed by a maintenance dose of 20 mg/kg PO q12h maintains therapeutic serum acyclovir concentrations for the alphaherpesvirus EHV-1.¹⁸ In comparison, EHV-5 is a slow-growing gammaherpesvirus that is challenging to culture. As a result, establishing anti-viral sensitivity testing for EHV-5 is difficult and the IC₅₀ for EHV-5 is currently unknown.^{1,2,17,25} The dose or duration of treatment of valacyclovir in our study might therefore have been inadequate to alter EHV-5 viral loads. Human studies using valacyclovir in the treatment of the gammaherpesvirus EBV have decreased viral load with prolonged treatment of up to 12 months. Oral administration of valacyclovir (500 mg/day) reduced the number of EBV infected B cells in blood but not the number of EBV DNA copies per B cell.²⁶ The cost of valacyclovir treatment in horses (~\$25/day) makes such prolonged treatment with valacyclovir unpractical for most owners.

Consistent with previous case reports, horses with EMPF had a poor outcome in our study, with 5/6 horses euthanized.^{6,8-10} Interestingly, the single surviving horse was the youngest horse in the study and appeared to present earlier in the disease course as evidenced by clinical presentation, less marked radiographic changes and notably lower BALF EHV-5 viral load on presentation compared with the

other horses in the study. Given the irreversibility of pulmonary fibrosis, it appears logical that identifying and treating horses earlier in the disease course to prevent further fibrosis would be more likely to produce a favorable outcome. A similar correlation has been noted in human cases of IPF with improved response to treatment generally noted in younger patients with less marked disease.^{27,28} The combination of strains or genotypes of EHV-5 present in a horse with EMPF might have clinical importance; however, further work is necessary to determine whether strain variability is an important component of pathogenicity.²⁹ In human IPF cases, clinical phenotypes with discrete comorbidities and survival times have been defined. A subset of patients have a rapidly progressive disease course with a shorter survival time known as accelerated IPF.^{30,31} The differences in survival times noted in our study and previous studies might be indicative of varying phenotypes with different rates of progression. Whether this difference is dependent on genetic, environmental, viral or a combination of factors is currently unclear.

The main limitations of our study were the small sample size and nonhomogenous study population because of the sporadic nature of EMPF. In the interests of ensuring the comfort of the horses during the study, treatment with additional medications was necessary. Four cases received NSAIDs and in the remaining 2 cases, delaying conventional treatment with antifibrotic drugs and corticosteroids was considered unethical. Ideally, the effects of valacyclovir would have been considered in isolation with no concurrent treatments. One horse in the study had consistent clinicopathological and diagnostic imaging findings and was qPCR positive for EHV-5 testing of BALF but EMPF was not confirmed on lung biopsy specimen or on postmortem examination. Recent studies have displayed that detection of EHV-5 in BALF is very strongly associated with EMPF.^{5,32} The detection of EHV-5 in BALF combined with consistent diagnostic imaging findings warranted inclusion of this horse as a presumptive case of EMPF.

In conclusion, our study showed that 10 days of oral administration of valacyclovir treatment at the chosen dosage was insufficient to alter EHV-5 viral kinetics in horses with EMPF. The study did not seek to determine the efficacy of valacyclovir treatment of horses with EMPF. Given the associated costs of treatment, it is recommended that conventional treatment with anti-fibrotic medications and anti-inflammatories (steroidal and nonsteroidal) continues to be the mainstay of treatment. There is currently limited knowledge concerning the susceptibility of equine gammaherpesviruses, such as EHV-5, to antiviral medications.

**FIGURE 2** Mean peak and trough plasma concentrations of acyclovir (µg/mL) obtained during the predicted steady-state phase treatment with PO administered valacyclovir in 6 horses with equine multinodular pulmonary fibrosis. The mean peak and trough acyclovir concentrations obtained in a previous study by Maxwell et al. (2008) are shown

ACKNOWLEDGMENTS

Locations work was performed at University of California Veterinary Medical Teaching Hospital, Davis; Experimental and Clinical Pharmacology Laboratory, CVHS, Oklahoma State University; Purdue University Veterinary Teaching Hospital; Stillwater Equine Veterinary Clinic, Minnesota. Project funded by a resident grant from the University of California, Davis Center for Equine Health with funds provided by the State of California satellite wagering fund and contributions by private donors. Presented as a research abstract at the 2017 American College of Veterinary Internal Medicine Forum, National Harbor, MD.

CONFLICT OF INTEREST DECLARATION

Authors declare no conflict of interest.

OFF-LABEL ANTIMICROBIAL DECLARATION

The use of valacyclovir in horses in our study was off-label.

INSTITUTIONAL ANIMAL CARE AND USE COMMITTEE (IACUC) OR OTHER APPROVAL DECLARATION

Sample collection and animal use was approved by the IACUC at the University of California at Davis. Owner consent was obtained for animals used in our study.

ORCID

Charlotte A. Easton-Jones  <http://orcid.org/0000-0002-4663-6982>

REFERENCES

- Williams KJ, Maes R, Del Piero F, et al. Equine multinodular pulmonary fibrosis: A newly recognized herpesvirus-associated fibrotic lung disease. *Vet Pathol.* 2007;44:849–862.
- Wong DM, Belgrave RL, Williams KJ, et al. Multinodular pulmonary fibrosis in five horses. *J Am Vet Med Assoc.* 2008;232:898–905.
- Williams KJ. Experimental induction of pulmonary fibrosis in horses with the gammaherpesvirus equine herpesvirus 5. *PLoS One.* 2013;8:e777754.
- Williams KJ. Gammaherpesviruses and pulmonary fibrosis: Evidence from humans, horses and rodents. *Vet Pathol.* 2014;51:372–384.
- Wilkins PA. Equine multinodular pulmonary fibrosis: Diagnosis and treatment. *Equine Vet Educ.* 2013;25:393–397.
- Hart KA, Barton MH, Williams KJ, et al. Multinodular pulmonary fibrosis, pancytopenia and equine herpesvirus-5 infection in a Thoroughbred gelding. *Equine Vet Educ.* 2008;20:469–476.
- Dunkel B. Pulmonary fibrosis and gammaherpesvirus infection in horses. *Equine Vet Educ.* 2012;24:200–205.
- Belgrave RL. Review of the diagnosis, treatment, and management of equine multinodular pulmonary fibrosis (Five Cases). *AAEP Proc.* 2009; 55:304–306
- Spelta CW, Axon JE, Begg A, et al. Equine multinodular pulmonary fibrosis in three horses in Australia. *Aust Vet J.* 2013;91:274–280.
- Niedermaier N, Poth T, Gehlen H. Clinical aspects of multinodular pulmonary fibrosis in two warmblood horses. *Vet Rec.* 2010;166: 426–430.
- Schwarz B, Schwendenwein I, van den Hoven R. Successful outcome in a case of equine multinodular pulmonary fibrosis (EMPF) treated with valacyclovir. *Equine Vet Educ.* 2013;25:389–392.
- Richeldi L, Collard HR, Jones MG. Idiopathic pulmonary fibrosis. *Lancet.* 2017;389:1941–1952.
- Yonemaru M, Kasuga I, Kusumoto H, et al. Elevation of antibodies to cytomegalovirus and other herpes viruses in pulmonary fibrosis. *Eur Respir J.* 1997;10(9):2040–2045.
- Schooley R, Carey R, Miller G, et al. Chronic Epstein-Barr virus infection associated with fever and interstitial pneumonitis. *Ann Intern Med.* 1986;104:636–643.
- Doran P, Egan J. Herpesviruses: A co factor in the pathogenesis of idiopathic pulmonary fibrosis. *Am J Physiol Lung Cell Mol Physiol.* 2005; 289:709–710.
- Rempe S, Hayden JM, Robbins RA, Hoyt JC. Tetracyclines and pulmonary inflammation. *Endocr Metab Immune Disord Drug Targets.* 2007;7: 232–236.
- Wong DM, Maxwell LK, Wilkins PA. Use of antiviral medications against equine herpes virus associated disorders. *Equine Vet Educ.* 2010;22:244–252.
- Maxwell LK, Bentz BG, Gilliam LL, et al. Efficacy of the early administration of valacyclovir for the therapy of neuropathogenic EHV-1 in horses. *Am J Vet Res.* 2017;78:1126–1139.
- Maxwell LK, Bentz BG, Bourne DW, Erkert RS. Pharmacokinetics of valacyclovir in the adult horse. *J Vet Pharmacol Ther.* 2008;31: 312–320.
- Pusterla N, Mapes S, Wademan C, White A, Hodzic E. Investigation of the role of lesser characterised respiratory viruses associated with upper respiratory tract infections in horses. *Vet Rec.* 2013;172:315.
- Pusterla N, Mapes S, Wilson WD. Use of viral loads in blood and nasopharyngeal secretions for the diagnosis of EHV-1 infection in field cases. *Vet Rec.* 2008;162:728–729.
- Wilkins PA, Papich M, Sweeney RW. Pharmacokinetics of acyclovir in adult horses. *J Vet Emerg Crit Care.* 2005;15:174–178.
- Bentz BG, Maxwell LK, Erkert RS, et al. Pharmacokinetics of acyclovir after single intravenous and oral administration to adult horses. *J Vet Intern Med.* 2006;20:589–594.
- Garre B, Shebany K, Gryspeerdt A, et al. Pharmacokinetics of acyclovir after intravenous infusion of acyclovir and after oral administration of acyclovir and its prodrug valacyclovir in healthy adult horses. *Antimicrob Agents Chemother.* 2007;51:4308–4314.
- Fortier G, van Erck E, Pronost S, Lekeux P, Thiry E. Equine gammaherpesviruses: Pathogenesis, epidemiology and diagnosis. *Vet J.* 2010; 186:148–156.
- Hoshino Y, Katano H, Zou P, et al. Long-term administration of valacyclovir reduces the number of Epstein-Barr virus (EBV)-infected B cells but not the number of EBV DNA copies per B cell in healthy volunteers. *J Virol.* 2009;83:11857–11861.
- Ley B, Collard HR, King T Jr. Clinical course and prediction of survival in idiopathic pulmonary fibrosis. *Am J Respir Crit Care Med.* 2011;183: 431–440.
- Aiello M, Bertorelli G, Bocchino M, et al. The earlier, the better: Impact of early diagnosis on clinical outcome in idiopathic pulmonary fibrosis. *Pulm Pharmacol Ther.* 2017;44:7–15.
- Back H, Ullman K, Leijon M, et al. Genetic variation and dynamics of equid herpesvirus 5 in individual horses. *J Gen Virol.* 2016;97:169–178.
- King TE Jr, Pardo A, Selman M. Idiopathic pulmonary fibrosis. *Lancet.* 2011;378:1949–1961.
- Selman M, Carrillo G, Estrada A, et al. Accelerated variant of idiopathic pulmonary fibrosis: clinical behavior and gene expression pattern. *PLoS One.* 2007;2:e482.
- Pusterla N, Magdesian KG, Mapes SM, Zavadovskaya R, Kass PH. Assessment of quantitative polymerase chain reaction for equine herpesvirus-5 in blood, nasal secretions and bronchoalveolar lavage fluid for the laboratory diagnosis of equine multinodular pulmonary fibrosis. *Equine Vet J.* 2017;49:34–38.

How to cite this article: Easton-Jones CA, Madigan JE, Barnum S, et al. Effect of valacyclovir on EHV-5 viral kinetics in horses with equine multinodular pulmonary fibrosis. *J Vet Intern Med.* 2018;32:1763–1767. <https://doi.org/10.1111/jvim.15230>