

# UC Davis

## Dermatology Online Journal

### Title

Clear cell papulosis: report and review

### Permalink

<https://escholarship.org/uc/item/0rf8h71b>

### Journal

Dermatology Online Journal, 24(1)

### Authors

Seykora, Caitlin M

Dalton, Scott R

Brown, Patrick J. Brown J

### Publication Date

2018

### License

[CC BY-NC-ND 4.0](https://creativecommons.org/licenses/by-nc-nd/4.0/)

Peer reviewed

# Clear cell papulosis: report and review

Caitlin M. Seykora DO, Scott R. Dalton DO, Patrick J. Brown<sup>2</sup> MD

Affiliations: <sup>1</sup>San Antonio Uniformed Services Health Education Consortium, San Antonio, Texas, San Antonio Uniformed Services Health Education Consortium, Duluth, Minnesota, <sup>2</sup>Private practice, Duluth, Minnesota

Corresponding Author: Caitlin M. Seykora DO, 59 MDSP/SGMD/Dermatology, 1100 Wilford Hall Loop Bldg 4554, JBSA Lackland, TX 78236, Email: c.m.seykora@gmail.com

## Abstract

A 12-month-old boy presented with three months of asymptomatic hypopigmented flat-topped papules on the suprapubic skin and lower abdomen. Emollients and topical steroids offered no improvement and the patient was referred to the dermatology department. Shave biopsy revealed a papillated epidermis with scattered solitary mononuclear clear cells at all levels of the epidermis and an overlying basket weave orthokeratosis. The cells were epithelioid with increased amphophilic cytoplasm. Immunohistochemical staining was positive for CK7, CEA, and CAM5.2 and negative for S100, CD1a, and Mart-1. These findings were consistent with clear cell papulosis. No treatment was recommended as these lesions were asymptomatic. However, yearly follow up was recommended given the resemblance of these cells to those of Paget disease. Review of the literature demonstrates a total of 31 biopsy confirmed cases with AE1, CEA, and EMA positivity and S100 negativity as the most consistent staining properties. A recent retrospective review of 19 cases documents long term follow-up of at least six years and up to 21 years. The results suggested a tendency toward self-resolution and an absence of malignant progression, supporting the benign nature of these lesions.

*Keywords: clear cell papulosis, primary intraepidermal Paget disease, extramammary Paget disease*

## Introduction

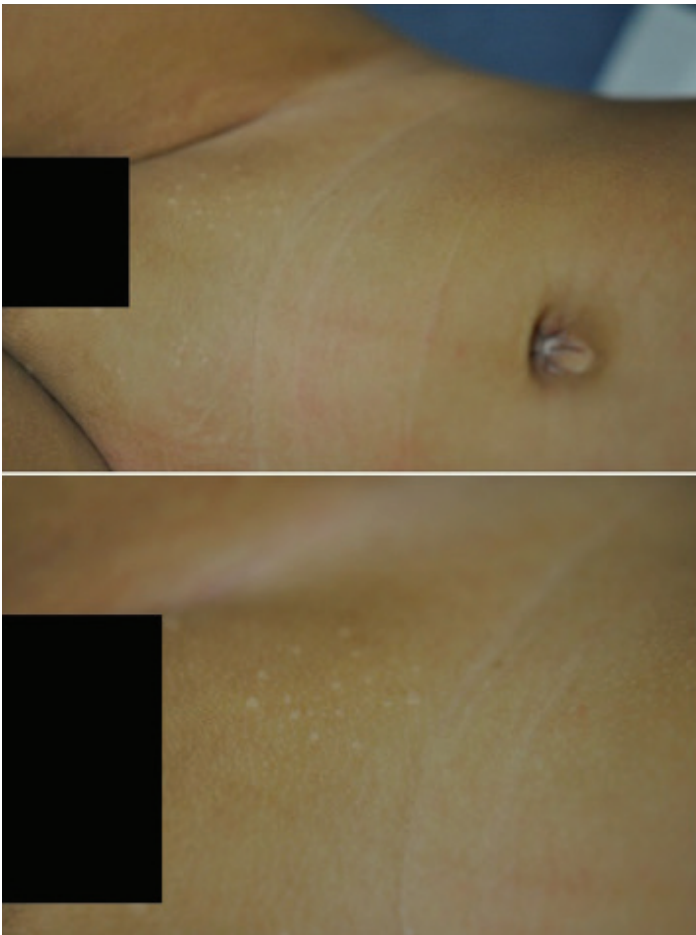Clear cell papulosis is a seemingly rare condition with a total of 31 histopathologically confirmed cases reported since 1987 [1]. Clear cell papulosis is most commonly reported in Asians less than 6 years old, but has also been described in Italy [2], in Hispanic siblings

living in the United States [3], and in one adult [4]. It is characterized by numerous hypopigmented macules and flat-topped papules that most commonly affect the suprapubic area, lower abdomen, and buttocks. Clear cell papulosis often appears along the milk lines but has also been reported on the arms and back. The differential diagnosis includes verruca plana, tinea versicolor, guttate lichen sclerosus, and confetti macules of tuberous sclerosis. An underlying cause has not been elucidated.

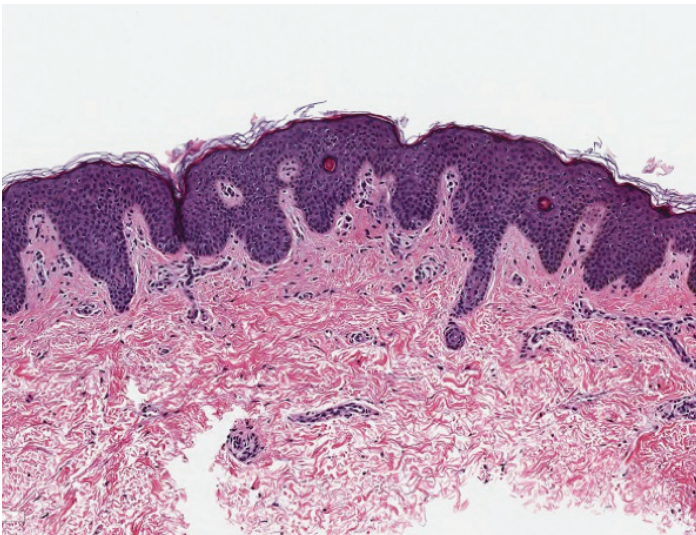
## Case Synopsis

A 12-month-old boy presented with a three month history of apparently asymptomatic hypopigmented areas on the suprapubic skin and lower abdomen (**Figure 1**). Emollients and topical corticosteroids failed to resolve the lesions and the patient was referred to the dermatology department. There was no history of prior rash in the area. The lesions did not appear to be symptomatic and no family members or caregivers had similar lesions. The patient did not attend daycare and his only regular contacts were his parents and grandmother. His birth history was uncomplicated and he was meeting milestones appropriately. On examination there were approximately 20 discrete 1-2 mm, flat-topped, well-circumscribed round hypopigmented papules on the lower abdomen and suprapubic skin, which appeared to cluster around the milk lines. The differential diagnosis included flat warts, lichen sclerosus, confetti macules, pityriasis alba, pityriasis versicolor, and clear cell papulosis.

Shave biopsy of a representative lesion revealed a papillated epidermis with scattered solitary mononuclear clear cells at all levels of the epidermis and an overlying basket weave orthokeratosis (**Figure 2**). The cells were epithelioid with increased

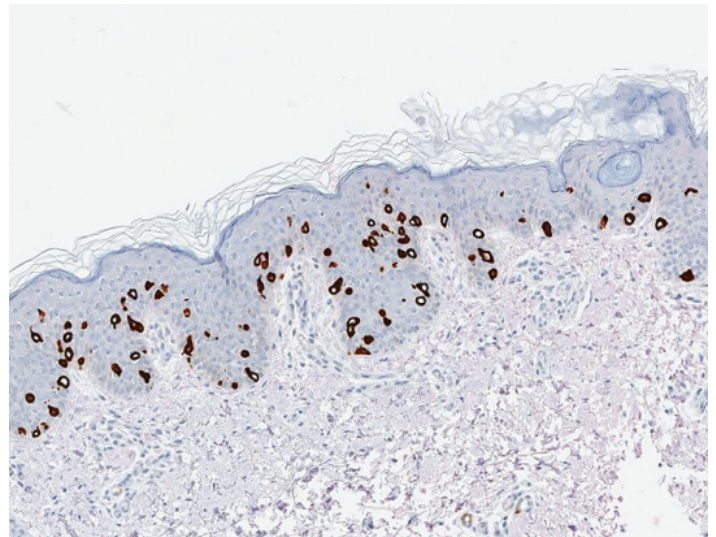


**Figure 1:** Photographs showing the hypopigmented papules on the lower abdomen and suprapubic skin.

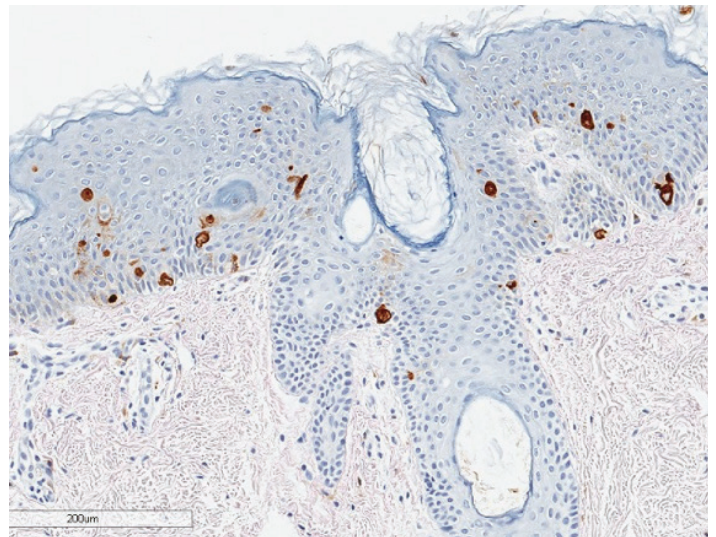


**Figure 2:** Photomicrograph of papillated epidermis with scattered solitary mononuclear clear cells at all levels of the epidermis and an overlying basketweave stratum corneum with orthokeratosis. H&E, 10%.

amphophilic cytoplasm. Immunohistochemical staining was positive for CK7, CEA, and CAM5.2 (Figures 3, 4) and negative for S100, CD1a, and Mart-



**Figure 3:** Pagetoid cells are highlighted with CK7.



**Figure 4:** Pagetoid cells highlighted by CEA.

1 (not shown).

Biopsy of a lesion was consistent with clear cell papulosis. Given the asymptomatic nature no intervention was performed. However, yearly monitoring for changes in appearance or new lesions was recommended.

### Case Discussion

The natural progression of clear cell papulosis is not known given the small number of reported cases. Some authors have suggested long term surveillance given the similarity of these cells microscopically and immunohistochemically to those of extramammary Paget disease or primary intraepidermal Paget disease. Similar to Paget disease, clear cell papulosis also demonstrates large cells with amphophilic

**Table 1.** Staining characteristics of confirmed clear cell papulosis biopsies reported since 1987.

Paper	Patient #	PAS	MC	AB	CI	F-M	VVG	AE1	AE3	CEA	EMA	CK7	GCDFP-15	CAM 5.2	Her2/neu	P53	ER	PR	S100	Mart-1
Kuo, et al. 1987	1	V	V	V	V	-	ND	+	+	+	+	ND	ND	ND	ND	ND	ND	ND	-	ND
Kuo, et al. 1995	2	V	V	V	V	D	ND	+	ND	+	+	ND	V	ND	ND	ND	ND	ND	ND	ND
	3	V	V	V	V	D	ND	+	ND	+	+	ND	V	ND	ND	ND	ND	ND	ND	ND
	4	V	V	V	V	D	ND	+	ND	+	+	ND	V	ND	ND	ND	ND	ND	ND	ND
Kim, et al. 1997	5	-	ND	ND	ND	-	ND	+	ND	+	+	ND	+	ND	ND	ND	ND	ND	-	ND
Lee, et al. 1998	6	ND	V	ND	ND	D	ND	+	+	+	+	ND	ND	ND	ND	ND	ND	ND	-	ND
	7	ND	V	ND	ND	D	ND	+	+	+	+	ND	ND	ND	ND	ND	ND	ND	-	ND
	8	ND	V	ND	ND	D	ND	+	+	+	+	ND	ND	ND	ND	ND	ND	ND	-	ND
Gianotti, et al. 2001	9	ND	ND	ND	ND	ND	ND	+	ND	+	+	ND	ND	ND	ND	ND	ND	ND	-	ND
Mohanty, et al. 2002	10	ND	-	-	ND	-	ND	ND	ND	+	+	+	ND	ND	ND	ND	ND	ND	-	ND
Kumarasinghe, et al. 2004	11	+	+	+	ND	D	ND	+	+	+	+	+	-	+	ND	ND	ND	ND	-	ND
Chong, et al. 2005	12	+	ND	ND	ND	ND	ND	+	ND	+	ND	ND	ND	ND	ND	ND	ND	ND	-	ND
Benouni, et al. 2007	13	+	-	ND	ND	ND	ND	ND	ND	+	ND	+	ND	ND	ND	ND	ND	ND	-	ND
	14	ND	+	ND	ND	ND	ND	ND	ND	+	+	+	ND	ND	ND	ND	ND	ND	-	ND
Farley-Loftus, et al. 2008	15	+	ND	ND	ND	ND	ND	ND	ND	ND	ND	ND	ND	ND	ND	ND	ND	ND	ND	ND
Yu, et al. 2009	16	ND	+	ND	ND	ND	ND	+	+	+	+	+	+	+	-	-	-	-	-	-
Tseng, et al. 2010	17	+	+	+	+	ND	ND	+	+	+	+	ND	ND	ND	ND	ND	ND	ND	ND	ND
	18	+	+	+	+	D	ND	+	ND	+	+	ND	+	ND	ND	ND	ND	ND	ND	ND
	19	+	+	+	+	D	ND	+	ND	+	+	ND	+	ND	ND	ND	ND	ND	ND	ND
	20	+	+	+	ND	D	D	+	ND	+	+	ND	+	ND	ND	ND	ND	ND	ND	ND
	21	+	+	+	+	ND	ND	+	ND	+	+	ND	+	ND	ND	ND	ND	ND	ND	ND
	22	ND	ND	ND	ND	ND	+	ND	ND	ND	ND	ND	ND	ND	ND	ND	ND	ND	ND	ND
	23	+	+	+	+	ND	ND	+	ND	+	+	ND	ND	ND	ND	ND	ND	ND	ND	ND

Paper	Patient #	PAS	MC	AB	CI	F-M	VVG	AE1	AE3	CEA	EMA	CK7	GCDFP-15	CAM 5.2	Her2/neu	P53	ER	PR	S100	Mart-1
	24	+	ND	ND	+	ND	ND	+	ND	ND	ND	ND	ND	ND	ND	ND	ND	ND	ND	ND
	25	ND	ND	ND	ND	ND	ND	+	ND	ND	ND	ND	ND	+	ND	ND	ND	ND	ND	ND
	26	ND	ND	ND	ND	ND	ND	+	ND	ND	ND	ND	ND	ND	ND	ND	ND	ND	ND	ND
Wysong, et al. 2011	27	ND	-	ND	-	ND	ND	+	ND	ND	ND	+	+	+	ND	ND	-	-	-	ND
Sim, et al. 2011	28	ND	ND	ND	ND	D	ND	ND	ND	+	+	+	ND	ND	ND	ND	ND	ND	-	-
Kim, et al. 2016	29	ND	ND	ND	ND	ND	ND	ND	ND	+	ND	+	ND	ND	ND	ND	ND	ND	-	ND
Bisi dos Santons, et al. 2016	30	+	ND	ND	ND	ND	ND	ND	ND	+	+	+	ND	ND	ND	ND	ND	ND	-	ND
Sykora, et al. 2017	31	ND	ND	ND	ND	ND	ND	ND	ND	+	ND	+	ND	+	ND	ND	ND	ND	-	-

*PAS, periodic acid-Schiff; MC, Mucicarmine; AB, Alcian blue; CI, colloidal iron; F-M, Fontana-Masson; VVG, Verhoeff-van Gieson; CEA, carcinoembryonic antigen; EMA, epithelial membrane antigen; CK7, cytokeratin 7, GCDFP-15, gross cystic disease fluid protein 15; ER, estrogen receptor; PR, progesterone receptor; V, variable staining; ND, stain not done; D, decreased staining; +, positive staining; -, negative staining*

cytoplasm scattered or nested within the epidermis. Furthermore, both Paget disease and clear cell papulosis are typically CK7, CEA, and PAS positive but S100 negative [5].

However, there is no data to suggest that cells in clear cell papulosis are precursors to Paget cells. Until recently, long term follow-up data was not available. In 2010, Tseng et al. [6] published data from 19 biopsy confirmed cases at their institution that were followed for at least six years. In their series, three patients had complete resolution of their lesions and nine patients had a reduction in number. Two had the same number of papules but the lesions had become less apparent over time. No treatment was administered in any patient owing to the asymptomatic nature. Furthermore, there were no cases of malignant transformation reported, even in patients followed for up to 21 years.

Yu, et al. [7], stained the cells in one case for Her2/neu as Paget cells in malignant lesions typically stain positively. Their case demonstrated negative staining for Her2/neu, p53, ER, and PR leading them to postulate a benign course. This histologic pattern has been reproduced in at least one other case, further supporting that clear cell papulosis is a benign process [8].

Given the somewhat non-specific histologic findings in clear cell papulosis, special stains are often employed with varying success. **Table 1** summarizes staining characteristics for biopsy confirmed cases reported since 1987 [1-4, 6-17]. AE1, CEA, and EMA staining were positive in 100% of the cases in which they were performed. Conversely, S100 appears to be consistently negative. It follows that we should consider these stains among the more reliable methods of confirming this condition histologically, when the clinical context is appropriate for clear cell papulosis.

## Conclusion

In summary, this is a rare entity that affects both sexes in a 1.4:1 female/male ratio based on our review of all reported cases. It is typically diagnosed prior to puberty, favors the anterior trunk and is asymptomatic. Immunohistochemistry may be helpful in solidifying this rare diagnosis in the

appropriate clinical context. The potential for malignant transformation is likely very low given what is known to date regarding natural history of clear cell papulosis, but the possibility of malignant transformation should not be completely discarded until more is known about the etiopathogenesis of this condition.

## References

1. Kuo TT, Chan HL, Hsueh S. Clear cell papulosis of the skin A new entity with histogenetic implications for cutaneous Paget's disease. *Am J Surg Pathol*. 1987 Nov;11(11):827-34. [PMID: 2823621].
2. Gianotti R, Cambiaghi S, Locatelli A, Gelmetti C. Clear cell papulosis (pagetoid papulosis) in a non-Asian patient. *Dermatology*. 2001;203(3):260-1. [PMID: 11701984].
3. Benouni S, Kos L, Ruggeri SY, North PE, Drolet BA. Clear cell papulosis in Hispanic siblings. *Arch Dermatol*. 2007 Mar;143(3):358-60. [PMID: 17372100].
4. Mohanty SK, Arora R, Kakkar N, Kumar B. Clear cell papulosis of the skin. *Ann Diagn Pathol*. 2002 Dec;6(6):385-8. [PMID: 12478491].
5. Elston, D., Ferringer, T. and Ko, C. (2014). *Dermatopathology*. [Philadelphia]: Saunders/Elsevier.
6. Tseng FW, Kuo TT, Lu PH, Chan HL, Chan MJ, et al. Long-term follow-up study of clear cell papulosis. *J Am Acad Dermatol*. 2010 Aug;63(2):266-73. [PMID: 20605258].
7. Yu Y, Sukhatme S, Loo DS. Clear cell papulosis: a connection of clear cells to toker cells or paget disease. *Arch Dermatol*. 2009 Sep;145(9):1066-8. [PMID: 19770459].
8. Wysong A, Sundram U, Benjamin L. Clear-cell papulosis: a rare entity that may be misconstrued pathologically as normal skin. *Pediatr Dermatol*. 2012 Mar-Apr;29(2):195-8. [PMID: 22142549].
9. Lee JY, Chao SC. Clear cell papulosis of the skin. *Br J Dermatol*. 1998 Apr;138(4):678-83. [PMID: 9640379].
10. Sim JH, Do JE, Kim YC. Clear cell papulosis of the skin: acquired hypomelanosis. *Arch Dermatol*. 2011 Jan;147(1):128-9. [PMID: 21242411].
11. Kim SW, Roh J, Park CS. Clear Cell Papulosis: A Case Report. *J Pathol Transl Med*. 2016 Sep;50(5):401-3. PubMed PMID: 27237133; [PMCID: PMC5042892].
12. Kim YC, Bang D, Cinn YW. Clear cell papulosis: case report and literature review. *Pediatr Dermatol*. 1997 Sep-Oct;14(5):380-2. [PMID: 9336811].
13. Chong WS, Ong BH, Kumarasinghe SP. Hypopigmented papules in an Asian boy. *Pediatr Dermatol*. 2005 May-Jun;22(3):268-9. [PMID: 15916582].
14. Bisi Dos Santos JE, Ribeiro de Miranda MF. Clear Cell Papulosis: Report of a Case With Unique Clinical and Histologic Findings. *Am J Dermatopathol*. 2016 Dec;38(12):924-926. [PMID: 27875365].
15. Farley-Loftus R, Bossenbroek NM, Rosenman K, Schaffer JV. Clear cell papulosis. *Dermatol Online J*. 2008 Oct 15;14(10):19. [PMID: 19061618].
16. Kumarasinghe SP, Chin GY, Kumarasinghe MP. Clear cell papulosis of the skin: a case report from Singapore. *Arch Pathol Lab Med*. 2004 Nov;128(11):e149-52. [PMID: 15504078].
17. Kuo TT, Huang CL, Chan HL, Yang LJ, Chen MJ. Clear cell papulosis: report of three cases of a newly recognized disease. *J Am Acad Dermatol*. 1995 Aug;33(2 Pt 1):230-3. [PMID: 7542673].