

# UCSF

## UC San Francisco Previously Published Works

### Title

Role of trauma and infection in childhood hemorrhagic stroke due to vascular lesions.

### Permalink

<https://escholarship.org/uc/item/0rm394bp>

### Journal

Neurology, 81(6)

### Authors

Singhal, Nilika

Hills, Nancy

Sidney, Stephen

et al.

### Publication Date

2013-08-06

### DOI

10.1212/WNL.0b013e31829e6f5f

Peer reviewed

# Role of trauma and infection in childhood hemorrhagic stroke due to vascular lesions

Nilika Shah Singhal, MD  
Nancy K. Hills, PhD  
Stephen Sidney, MD,  
MSc  
Heather J. Fullerton, MD,  
MAS

Correspondence to  
Dr. Fullerton:  
FullertonH@neuropeds.ucsf.edu

## ABSTRACT

**Objective:** Trauma and infection have been postulated as “triggers” for hemorrhage from underlying brain vascular lesions (arteriovenous malformations, cavernous malformations, and aneurysms) in pediatric hemorrhagic stroke. We decided to perform an association study examining these environmental risk factors.

**Methods:** In this case-control study nested within the cohort of 2.3 million children enrolled in a Northern California integrated health plan (1993–2004), we identified childhood hemorrhagic stroke cases through electronic searches of diagnostic and radiology databases, confirmed through chart review. Three age- and facility-matched controls per case were randomly selected from the study population. Exposure variables were measured using medical records documented before stroke diagnosis. Main outcome measure was hemorrhagic stroke.

**Results:** Of 132 childhood, non-neonatal hemorrhagic stroke cases, 65 had underlying vascular lesions: 34 arteriovenous malformations, 16 cavernous malformations, and 15 aneurysms. A documented exposure to head and neck trauma in the prior 12 weeks was present in 3 cases (4.6%) with underlying vascular lesions, compared with no controls ( $p < 0.015$ ). However, all 3 vascular lesions were aneurysms, and traumatic pseudoaneurysms were possible. Recent minor infection (prior 4 weeks) was present in 5 cases (7.7%) and 9 controls (4.6%) ( $p = 0.34$ ).

**Conclusions:** Our observed association between trauma and hemorrhagic stroke with a vascular lesion may be explained by traumatic pseudoaneurysms. Neither recent head or neck trauma nor infection appeared to be a “trigger” for pediatric hemorrhagic stroke due to underlying vascular malformations. *Neurology*® 2013;81:581–584

## GLOSSARY

**KPNC** = Kaiser Permanente Northern California; **KPSS** = Kaiser Pediatric Stroke Study.

Hemorrhagic strokes account for 50% of all childhood strokes<sup>1</sup> and are devastating: up to one-third die and 40% have permanent neurologic deficits.<sup>2,3</sup> Of all pediatric hemorrhagic strokes, vascular lesions (arteriovenous malformations, cavernous malformations, or aneurysm) account for nearly 50%.<sup>4</sup> To date, most studies have evaluated secondary hemorrhage risk factors in terms of intrinsic characteristics of malformations,<sup>5</sup> but risk factors related to what promotes primary hemorrhage have not been evaluated. As more vascular malformations are discovered as incidental findings on imaging studies, it is increasingly important to identify factors promoting hemorrhage from these otherwise asymptomatic lesions.

Neurosurgeons and neurologists anecdotally caution against contact sports for children with known vascular malformations or aneurysms because of concern that trauma could trigger a hemorrhage. In addition, recent systemic infection has been postulated as a trigger for subarachnoid hemorrhage in adults, perhaps related to the formation and rupture of aneurysms.<sup>6</sup> Association studies examining environmental risk factors for hemorrhage from vascular lesions in children are lacking. We hypothesized that antecedent recent infection or trauma may predispose children to incident hemorrhage from vascular lesions.

From the Departments of Neurology (N.S.S., N.K.H., H.J.F.), Pediatrics (H.J.F.), and Epidemiology and Biostatistics (N.K.H.), University of California, San Francisco; and Division of Research (S.S.), Kaiser Permanente Northern California, Oakland.

Go to [Neurology.org](http://Neurology.org) for full disclosures. Funding information and disclosures deemed relevant by the authors, if any, are provided at the end of the article.

**METHODS** This is a case-control study nested within a population-based cohort identified as part of the Kaiser Pediatric Stroke Study (KPSS). The KPSS identified stroke cases within the cohort of 2.3 million children enrolled between January 1993 and December 2004 in Kaiser Permanente Northern California (KPNC), a nonprofit, managed care organization providing health care to one-third of the population of Northern California.<sup>4,7</sup> Methods for case ascertainment were described previously.<sup>4,7</sup> In brief, cases were identified through electronic searches of diagnostic and radiology databases, including claims databases that capture care outside of KPNC. Two neurologists confirmed cases through independent chart review of paper and electronic medical records using prespecified criteria; a third neurologist arbitrated disputes. This report includes only cases of hemorrhagic stroke (intracerebral or subarachnoid hemorrhage) in children aged 29 days to 19 years. Three population-based controls per case were randomly selected from the cohort of 2.3 million children, with pairwise matching for birth year, year of enrollment in the KPNC system, and primary care facility. Matching by facility was intended to control for any potential disparity in quality of care.

A pediatric RN-trained medical records analyst used a predefined protocol to review all electronic and traditional records and abstract data. To prevent recall bias, all exposure variables were defined as documented in the medical records before the stroke diagnosis, or, for controls, before the “index date,” defined as the date of the stroke for that control’s matched case. “Recent infection” was a documented medical encounter for an infection within 4 weeks preceding hemorrhage or index date; the time frame was based on studies of recent infection and ischemic stroke.<sup>8</sup> “Head or neck trauma” was defined as a documented

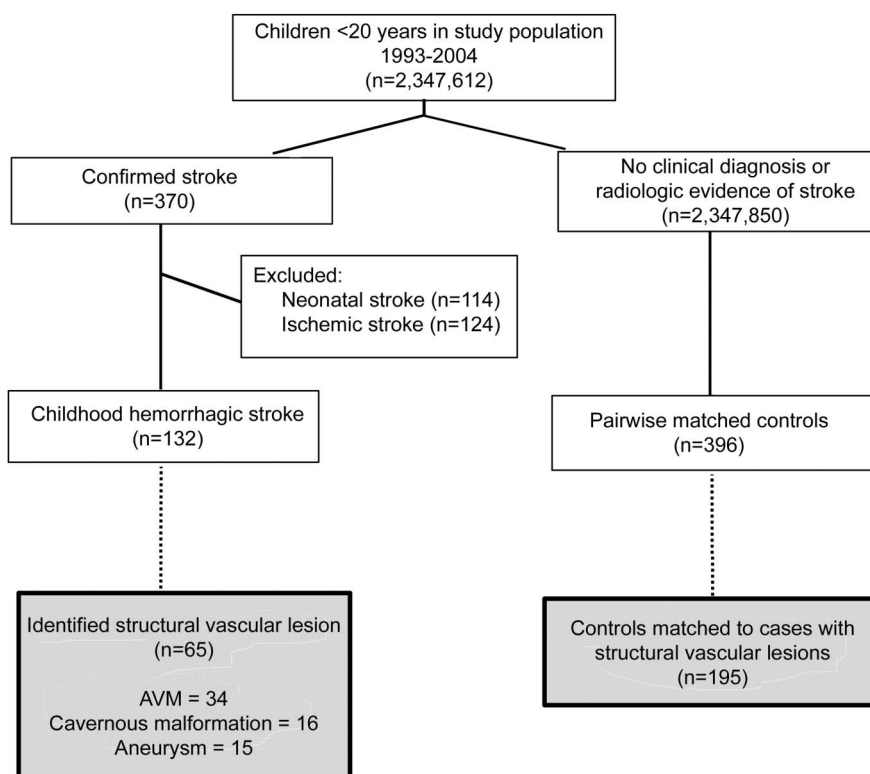
encounter for such trauma within 12 weeks preceding; a wide time range was selected because the period of highest risk has not been well-defined. A single pediatric stroke neurologist (H.J.F.) also reviewed all case clinical records, pre- and poststroke diagnosis, to secondarily classify the cause(s) of strokes.

Our analysis included all childhood hemorrhagic stroke cases with a vascular lesion and their matched controls. We performed conditional logistic regression to account for pairwise matching. For risk factors that occurred in the cases but not in the controls, we could not calculate univariate odds ratios, and compared these predictors with Fisher exact tests. Risk factors were considered to be absent if no mention of the condition was found during chart review.

**Standard protocol approvals, registrations, and patient consents.** The institutional review boards at KPNC and University of California, San Francisco approved the study procedures. Patient consent was waived for this retrospective study.

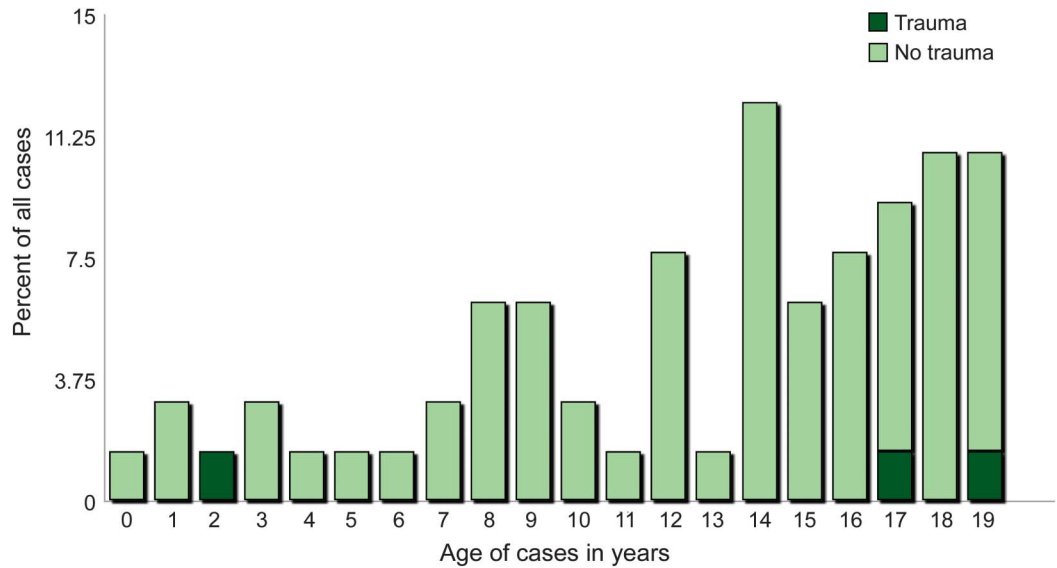
**RESULTS** Of the 132 cases of non-neonatal hemorrhagic stroke in our cohort, 65 were found to have a vascular lesion: 34 arteriovenous malformations, 16 cavernous malformations, and 15 aneurysms (figure 1). Two had a prior stroke, before the study period. Hemorrhages occurred at all ages (figure 2). There was no association between recent infection and hemorrhage from a vascular lesion (table). Head or neck trauma was a risk factor, present in 3 cases (4.6%) vs none of the controls. All 3 cases had cerebral aneurysms; however, in one, a spontaneous

**Figure 1** Flow diagram demonstrating identification of cases and controls



This flow diagram demonstrates how hemorrhagic stroke cases and controls were identified within the population of 2.3 million children younger than 20 years of age enrolled in Kaiser Permanente Northern California, 1993–2004. AVM = arteriovenous malformation.

**Figure 2** Age distribution of 65 cases of hemorrhagic stroke with vascular lesions



This bar graph demonstrates the age distribution of the 65 children younger than 20 years of age with hemorrhagic stroke with identified structural vascular lesions. The light-colored bars indicate those children without identified antecedent trauma. The dark-colored bars indicate the 3 cases with preceding (within 12 weeks) head or neck trauma. None of the children had documented antecedent (within 4 weeks) infection.

hemorrhage may have led to the trauma, and 2 likely had traumatic pseudoaneurysms. A 2.5-year-old, previously healthy girl had a spell of “shaking” followed by collapse with a large object hitting her head when she fell, with subsequent unconsciousness for 1 hour.

Imaging demonstrated subarachnoid hemorrhage and a “saccular aneurysm” of the left supraclinoid internal carotid artery on conventional angiography, treated with surgical clipping. An 18-year-old, previously healthy boy was involved in a collision while driving; he was found unconscious. Imaging showed subarachnoid hemorrhage and a left ophthalmic artery bilobed aneurysm vs pseudoaneurysm. During surgical treatment, the surgeon saw evidence of arterial laceration and concluded it was a pseudoaneurysm. A 16-year-old, previously healthy boy was riding a skateboard when he was hit by a car. Imaging showed a small subdural and subarachnoid hemorrhage. Ten days later, he presented with “garbled speech” and obtundation. Imaging revealed a new temporal intracerebral hemorrhage and an anterior temporal artery aneurysm, characterized as a “traumatic aneurysm” by the treating neurosurgeon. Chart review of all 65 cases revealed no incidence in which a history of trauma was elicited after the stroke diagnosis to suggest that trauma acted as a trigger.

**Table** Univariate risks for hemorrhagic stroke from a vascular lesion in children (29 days to 19 years of age)

Characteristic	Cases (n = 65)	Controls (n = 195)	p Value
Age, y, mean (SD)	12.7 (11.3, 14.0)	12.7 (12.0, 13.5)	
Male, n (%)	36 (55.4)	109 (55.9)	0.53
Race, n (%)			<0.0001
White	19 (29.2)	66 (33.8)	
Black	7 (10.8)	15 (7.7)	
Hispanic	20 (30.8)	26 (13.3)	
Asian	11 (16.9)	24 (12.3)	
Native American	1 (1.5)	0	
Unknown	7 (10.8)	63 (32.3)	
<b>Recent environmental exposures</b>			
Head or neck trauma, past 12 wk, n (%)	3 (4.6)	0	<0.015 <sup>a</sup>
Head or neck trauma, past 1 wk, n (%)	3 (4.6)	0	<0.015 <sup>a</sup>
Days from trauma to stroke/index date, median	0.1		
Loss of consciousness, n (%)	3 (4.6)	0	<0.062 <sup>a</sup>
Admission for trauma, n (%)	3 (4.6)	0	<0.015 <sup>a</sup>
Skull fracture	0	0	
Minor acute infection, past 4 wk, n (%)	5 (7.7)	9 (4.6)	0.341

<sup>a</sup>Fisher exact test was used.

**DISCUSSION** In a KPSS study using the same methodology to identify risk factors for childhood ischemic stroke, recent encounters for both infection and head or neck trauma were prevalent and significant risk factors.<sup>9</sup> Although plausible that these environmental factors could act as “triggers” for incident hemorrhage from an aneurysm or vascular malformation, we found no evidence to support that hypothesis. The apparent association with trauma was, on careful review of clinical histories, likely explained by either traumatic pseudoaneurysms or trauma as a consequence of the hemorrhagic

stroke, rather than the cause. Chart review of all cases in this population-based cohort revealed no instances in which trauma was thought to have triggered a hemorrhage from an underlying vascular lesion.

Despite our cohort size of 2.3 million children, our study was limited by a small number of cases, which precluded an evaluation of risk factors for first vs recurrent hemorrhagic stroke. However, we were powered at >80% to detect associations of the same strength observed in our study of ischemic stroke (odds ratios of 6 for infection and 8 for trauma).<sup>9</sup> Other limitations include the retrospective nature of our study and our inability to review vascular imaging. In addition, only exposures to trauma or infection that triggered a health care visit were considered for this study, thus by definition excluding exposures that did not trigger a visit; this may have resulted in missing some exposures related to stroke. Strengths of the study are the population-based cohort and the ability to minimize recall bias by using medical records documented before the stroke diagnosis.

These data provide some limited reassurance that trauma and infection are not strong triggers for hemorrhagic stroke in children with vascular lesions.

#### AUTHOR CONTRIBUTIONS

Nilika Shah Singhal, MD, participated in data analysis and interpretation and drafting of the manuscript. Nancy K. Hills, PhD, contributed to data analysis and interpretation. Stephen Sidney, MD, MSc, participated in acquisition of data and study supervision. Heather J. Fullerton, MD, MAS, contributed to study concept and design, study supervision, and critical revision of the manuscript for important intellectual content.

#### STUDY FUNDING

Supported by a National Institute of Neurological Disorders and Stroke Independent Scientist Award (K02 NS053883; PI Heather Fullerton).

#### DISCLOSURE

The authors report no disclosures relevant to the manuscript. Go to [Neurology.org](http://Neurology.org) for full disclosures.

Received December 4, 2012. Accepted in final form April 29, 2013.

#### REFERENCES

1. Broderick JP, Talbot T, Prenger E, Leach A, Brott T. Stroke in children within a major metropolitan area: the surprising importance of intracerebral hemorrhage. *J Child Neurol* 1993;8:250–255.
2. Blom I, De Schryver EL, Kappelle LJ, Rinkel GJ, Jennekens-Schinkel A, Peters AC. Prognosis of hemorrhagic stroke in childhood: a long-term follow-up study. *Dev Med Child Neurol* 2003;45:233–239.
3. Lo WD, Lee J, Rusin J, Perkins E, Roach ES. Intracerebral hemorrhage in children: an evolving spectrum. *Arch Neurol* 2008;65:1629–1633.
4. Fullerton HJ, Wu YW, Sidney S, Johnston SC. Recurrent hemorrhagic stroke in children: a population-based cohort study. *Stroke* 2007;38:2658–2662.
5. da Costa L, Wallace C, Brugge KG, O’Kelly C, Willinsky R, Tymianski M. The natural history and predictive features of hemorrhage from brain arteriovenous malformations. *Stroke* 2009;40:100–105.
6. Kunze AK, Annecke A, Wigger F, et al. Recent infection as a risk factor for intracerebral and subarachnoid hemorrhages. *Cerebrovasc Dis* 2000;10:352–358.
7. Agrawal N, Johnston SC, Wu WY, Sidney S, Fullerton HJ. Imaging data reveal a higher pediatric stroke incidence than prior US estimates. *Stroke* 2009;40:3415–3421.
8. Emsley HC, Hopkins SJ. Acute ischaemic stroke and infection: recent and emerging concepts. *Lancet Neurol* 2008;7:341–353.
9. Hills NK, Johnston SC, Sidney S, Zielinski BA, Fullerton HJ. Recent trauma and acute infection as risk factors for childhood arterial ischemic stroke. *Ann Neurol* 2012;72:850–858.

## Share Your Artistic Expressions in *Neurology* ‘Visions’

AAN members are urged to submit medically or scientifically related artistic images, such as photographs, photomicrographs, and paintings, to the “Visions” section of *Neurology*<sup>®</sup>. These images are creative in nature, rather than the medically instructive images published in the *NeuroImages* section. The image or series of up to six images may be black and white or color and must fit into one published journal page. Accompanying description should be 100 words or less; the title should be a maximum of 96 characters including spaces and punctuation.

Learn more at [www.aan.com/view/Visions](http://www.aan.com/view/Visions), or upload a Visions submission at [submit.neurology.org](http://submit.neurology.org).