

UCSF

UC San Francisco Previously Published Works

Title

3D bone-shape changes and their correlations with cartilage T1ρ and T2 relaxation times and patient-reported outcomes over 3-years after ACL reconstruction

Permalink

<https://escholarship.org/uc/item/0rz548g4>

Journal

Osteoarthritis and Cartilage, 27(6)

ISSN

1063-4584

Authors

Zhong, Q
Pedoia, V
Tanaka, M
[et al.](#)

Publication Date

2019-06-01

DOI

10.1016/j.joca.2019.01.017

Peer reviewed



HHS Public Access

Author manuscript

Osteoarthritis Cartilage. Author manuscript; available in PMC 2020 June 01.

Published in final edited form as:

Osteoarthritis Cartilage. 2019 June ; 27(6): 915–921. doi:10.1016/j.joca.2019.01.017.

3D Bone-shape changes and their correlations with cartilage T1ρ and T2 relaxation times and patient-reported outcomes over 3-years after ACL reconstruction

Qunjie Zhong,

Department of Radiology and Biomedical Imaging, University of California, San Francisco, San Francisco, CA, USA

Arthritis Clinic and Research Center, Peking University People's Hospital, Beijing, China

Valentina Pedoia,

Department of Radiology and Biomedical Imaging, University of California, San Francisco, San Francisco, CA, USA

Matthew Tanaka,

Department of Radiology and Biomedical Imaging, University of California, San Francisco, San Francisco, CA, USA

Jan Neumann,

Department of Radiology and Biomedical Imaging, University of California, San Francisco, San Francisco, CA, USA

Thomas M. Link,

Department of Radiology and Biomedical Imaging, University of California, San Francisco, San Francisco, CA, USA

Corresponding author: Xiaojuan Li, Department of Biomedical Engineering/ND20, 9500 Euclid Avenue, Cleveland Clinic, Cleveland, Ohio, USA, Tel. 216/442-8848; lix6@ccf.org.

Author contributions

- Conception and design: Xiaojuan Li, C. Benjamin Ma
- Analysis and interpretation of the data: Qunjie Zhong; Valentina Pedoia; Xiaojuan Li, Jianhao Lin, C. Benjamin Ma
- Drafting of the article: Qunjie Zhong; Xiaojuan Li
- Critical revision of the article for important intellectual content: all authors
- Final approval of the article: All authors
- Provision of study materials: Xiaojuan Li, Benjamin Ma
- Statistical expertise: Qunjie Zhong; Xiaojuan Li
- Obtaining of funding: Xiaojuan Li; Benjamin Ma
- Administrative, technical, or logistic support: Matthew Tanaka
- MRI WORMS grading: Jan Neumann, Thomas M. Link

Publisher's Disclaimer: This is a PDF file of an unedited manuscript that has been accepted for publication. As a service to our customers we are providing this early version of the manuscript. The manuscript will undergo copyediting, typesetting, and review of the resulting proof before it is published in its final citable form. Please note that during the production process errors may be discovered which could affect the content, and all legal disclaimers that apply to the journal pertain.

Conflict of interest

All authors have no conflicts of interests to disclose.

Benjamin Ma,

Department of Orthopedic Surgery, University of California, San Francisco, San Francisco, CA, USA

Jianhao Lin, and

Arthritis Clinic and Research Center, Peking University People's Hospital, Beijing, China

Xiaojuan Li

Department of Radiology and Biomedical Imaging, University of California, San Francisco, San Francisco, CA, USA

Program of Advanced Musculoskeletal Imaging (PAMI), Department of Biomedical Engineering, Cleveland Clinic, Cleveland, Ohio, USA

Abstract

Purpose—(1) To identify bone-shape changes from baseline to 3-years after anterior cruciate ligament reconstruction (ACLR); (2) to assess association between changes in bone-shape from baseline to 6-months and changes in cartilage matrix and patient functions and symptoms from baseline to 3-years after ACLR.

Methods—Bilateral knees of 30 patients with unilateral ACL injuries were scanned at baseline, 6-months, 1-, 2-, and 3-years after ACLR. Bilateral knees of 13 controls were scanned at baseline, 1- and 3-years. Mean T1 ρ and T2 values of each cartilage compartment were computed. Bone shape was quantified using statistical shape modeling (SSM) and 3D-MRI. Patient functions and symptoms were evaluated using Knee Injury and Osteoarthritis Outcome Score (KOOS).

Results—Statistically significant changes were observed in Femur 2 (medial femoral condyle shape), Femur 6 (intercondylar notch width), Tibia 1 (tibia plateau area), and Tibia 7 (medial tibia slope) over 3-years after ACLR. Statistically significant differences were observed between injured and control knees in several modes. Statistically significant correlations were found between changes in bone shape (Femur 6, Femur 8 [trochlea inclination and medial femoral condyle height], Tibia 1) from baseline to 6-months and that of cartilage T1 ρ and T2 and KOOS from baseline to 3-years after ACLR.

Conclusion—Bone shape remodeling occurs after ACLR, and early bone shape changes (within 6 months) correlated with cartilage matrix and patient outcomes at 3-years after ACLR. Bone shape can be a promising imaging biomarker that stratifies patients at high risk for post-traumatic osteoarthritis.

Keywords

Anterior cruciate ligament; Bone shape; Statistical shape modeling; Magnetic resonance imaging; Osteoarthritis

Introduction

Patients with anterior cruciate ligament (ACL) have a high risk of developing post-traumatic osteoarthritis (PTOA) even after ACL reconstruction (ACLR). Therefore, it is crucial to

identify the predictors of PTOA development and clinical outcomes following ACL injury and reconstruction.

Using radiographs, Eggerding et al. (1) showed that the bone shape after ACL rupture predicted clinical outcomes 2 years later. Hunter et al. (2) reported longitudinal tibial curvature changes after ACL injury. Using statistical shape modeling (SSM), Padoa et al. (3) developed 3D bone shape quantification methods and reported significant bone shape differences between ACL-injured and control knees and correlations between bone shape features and cartilage health at 1-year after ACLR.

Despite these promising results, no studies have yet investigated longitudinal changes of bone shape after ACL injury using comprehensive 3D modeling. The goals of this present study were to (1) identify distinct bone shape changes from baseline (after injury and before ACLR) to 3-years after ACLR; and (2) explore the association between changes in bone shape from baseline to 6-months vs. changes in cartilage T1 ρ and T2 relaxation times and Knee Injury and Osteoarthritis Outcome Score (KOOS) from baseline to 3-years after ACLR.

Methods

Subjects

Bilateral knees of 30 patients with unilateral ACL injury were scanned prior to ACLR (at BL), and at 6-months (6M), 1-year (1Y), 2-years (2Y), and 3-years (3Y) time points after reconstruction; Bilateral knees of 13 healthy controls were imaged at BL, 1Y and 3Y. The KOOS results of each participant were recorded at every visit. All patients underwent single-bundle ACLR with either hamstring or posterior tibialis grafts, and standard rehabilitation protocols were implemented postoperatively. The patients' activities were evaluated at BL (patients were asked to fill for the pre-injury activity), 6-months, 1-years, 2-years and 3-years using Marx scores. Informed consent was obtained from all of the participants.

MRI Imaging Protocols

All MRI examinations were performed using a 3.0 T MRI scanner (GE Healthcare, Milwaukee, WI, USA) with an 8-channel phased array knee coil (Invivo, Orlando, FL, USA) (Appendix Table 1).

Quantification of Bone Shape

An in-house developed 3D MRI-based SSM was applied for the tibia and femur of all subjects to extract and compare relevant bone shapes (3). First, tibia and femur were segmented semi-automatically. Then, a fully automatic landmark-matching algorithm on the basis of the analysis of local curvatures and spectral coordinates was implemented to map all vertices of the reference on the surface of all cases in the dataset. Last, principal component analysis was used to extract the key variation modes of all surfaces from the mean surface. The first 10 modes that demonstrated >90% of the total variations in the dataset were evaluated.

Quantification of Cartilage T1 ρ and T2 Relaxation Times

CUBE images from the injured knees were rigidly registered and down-sampled in the sagittal direction to match the first T1 ρ images. Cartilage was segmented semi-automatically using in-house developed software on the CUBE images into six compartments (lateral femoral condyle [LF], lateral tibia [LT], medial femoral condyle [MF], medial tibia, femoral trochlea, and patella) (4). All follow-up T1 ρ and T2 images, were registered non-rigidly to the first T1 ρ -weighted image of the injured knees at BL. The intensity-based multi-resolution pyramidal approach was implemented to accomplish the registration (5). T1 ρ and T2 maps were generated by fitting T1 ρ - and T2-weighted images with mono-exponential decay pixel-by-pixel. Mean T1 ρ and T2 values were calculated for each cartilage compartments.

Semi-Quantitative MRI Analysis

Abnormalities of the cartilage, meniscus, and bone marrow were evaluated blindly by musculoskeletal radiologists on the CUBE images using a modified whole-organ MRI score (WORMS) (6).

Statistical Analysis

Longitudinal bone shape changes of injured and control knees were analyzed using generalized estimating equation (GEE) adjusted for age, gender, and body mass index (BMI).

Bone shapes of injured and control knees were compared cross-sectionally at BL, 1Y and 3Y by using unpaired *t*-tests.

Partial Pearson correlation coefficients were calculated in the injured knees between bone mode changes from BL to 6M defined as:

$$\Delta Femur = Femur_{6M} - Femur_{BL}; \Delta Tibia = Tibia_{6M} - Tibia_{BL} \quad [EQ 1]$$

and T1 ρ and T2 changes from BL to 3Y defined as:

$$\Delta T1\rho = T1\rho_{3Y} - T1\rho_{BL}; \Delta T2 = T2_{3Y} - T2_{BL} \quad [EQ 2]$$

adjusted for demographics (age, gender, BMI), meniscus injury and treatment, time from injury to surgery, and cartilage WORMS of corresponding compartment at BL. Partial Pearson correlation coefficients were also calculated in the injured knees between bone mode changes from BL to 6M (Femur and Tibia) and KOOS changes from BL to 3Y (KOOS), adjusted for demographics (age, gender, BMI), meniscus injury and treatment, time from injury to surgery, and corresponding KOOS item at BL.

All the statistical analyses above were performed with IBM SPSS Statistics Version 20.0. The level of significance was $p < 0.05$.

Results

Demographic and Clinical Characteristics

The demographics of all subjects are shown in Appendix Table 2. No significant differences in age, gender and BMI were observed between patients with ACL injury and healthy controls.

The cartilage and meniscus WORMS gradings of injured knees at BL are shown in Appendix Table 3. Twelve patients had no meniscal tear and no treatment; 10 had tears but no treatment; 8 had tears and partial meniscectomy. No significant differences were found between Marx scores at BL and after 3 years, as shown in the Appendix Table 4.

Bone Shape Analysis

Statistically significant longitudinal changes were observed in two femur (Femur 2 and Femur 6) and two tibia (Tibia 1, Tibia 7) modes of the injured knees (Figure 1). Statistically significant differences were observed between injured and control knees in Femur 6 at BL, in Femur 6, Tibia 7 at 1Y, and in Femur 2, Femur 6, and Tibia 1 at 3Y (Figure 1).

We illustrated the major bone-shape features associated with each mode that showed significance in the study (Appendix Figure 1), with an effort to illustrate the physical meaning of bone modes. It shall be noted that these shape features are the major ones associated with these modes. Each mode represents a whole set of 3D bone shape features beyond a single shape feature.

Correlation Between the Changes of Bone Shape and That of Cartilage T1 ρ and T2 and KOOS

Statistically significant relationships between changes in bone shape (Femur 6, Femur 8, Tibia 1) from BL to 6M and changes in cartilage T1 ρ and T2 and KOOS from BL to 3Y were found (Table 1). Increasing width of the intercondylar notch (Femur 6) was predictive of more cartilage degeneration in LT and MF, and increasing area of the tibial plateau (Tibia 1) was predictive of more cartilage degeneration in LT. The MF's becoming more proximal and increases of the inclination of trochlea (Femur 8) were predictive of more cartilage degeneration in the patella and more pain.

Discussion

In this study, statistically significant bone shape changes, including femur sphericity, notch width, and tibial area and slope, were observed over 3-years after ACLR. The early bone shape changes (within the first 6-months after surgery), specifically femur notch width and alignment, and tibial area, were correlated with changes in cartilage T1 ρ and T2 relaxation times and patients' symptoms and function as measured with KOOS at 3-years after ACLR.

The tibia plateau area (Tibia 1) of injured knees started to increase from 1Y, and it was larger than the counterpart of control knees at 3Y. This increasing area of the tibia plateau might be an early sign of the joint degeneration after ACLR, as in the literature the area of the tibia plateau was reported to increase in response to risk factors for knee OA in healthy subjects

and to increase over time in subjects with knee OA (2). In addition, increasing in tibia plateau area from BL to 6M was predictive of more cartilage degeneration in LT from BL to 3Y in this study. Similarly, Antony et al. (7) suggested higher BL tibia bone area is associated with greater knee cartilage loss over 2 years by measuring a total of 324 subjects at BL and at 2Y. Haverkamp et al. (8) found out the width of tibia bones was increased in patients with OA, and knees with cartilage defects also had wider tibia bones compared with knees without cartilage defects. Increased posterior tibia slope has been suggested as not only a risk factor for initial ACL injury and the failure of ACLR graft (9, 10), but also a risk factor for OA (11). Increased posterior tibia slope, as indicated by Tibia 7, was observed in this study especially from 6M to 1Y. The posterior tibia slope was statistically significant higher in ACLR knees at 1Y compared with that of control knees. However, a decrease of tibia slope was observed from 2Y to 3Y, and a longer follow up is warrant to investigate this bone shape feature further.

For the femur, the sphericity of the MF condyle (Femur 2) of injured knees changed over time from oval to spherical at 6M. The sphericity change is probably due to the abnormal kinematics of ACLR. Lansdown et al. (12) found correlations of more spherical MF condyle with an increasingly anteriorly positioned tibia relative to the contralateral knee after injury and at 1-year after ACLR.

The intercondylar notch width (Femur 6) of injured knees was narrower than that of control knees at BL, which is consistent with results from previous studies that have demonstrated narrower width of the intercondylar notch is a morphological risk factor for ACL rupture (13). Furthermore, our study suggested increasing width of the intercondylar notch from BL to 6M is predictive of more cartilage degeneration in LT and MF from BL to 3Y. This was a surprising finding, because, normally, osteoarthritic knees tend to have a narrower intercondylar notch, and we would expect subjects with decreasing notch width would have more cartilage degeneration. It is not clear what the potential mechanism might be for the association between increasing notch width at the early postoperative stage (6M) and more cartilage degeneration at the later stage (3Y), which warrants further investigation.

Our results suggest the MF's becoming more proximal and inclination of trochlea increasing (Femur 8) from BL to 6M are predictive of not only more cartilage degeneration in the patella, but also more knee pain at later stages. Previously, Landsdown et al. (12) reported the association between MF becoming more proximally and greater side-to-side difference in the tibia position at the extended position measured by loaded MRI 1-year after ACLR. This observation, with results from our study, suggests there is an interrelationship between bone geometry, joint biomechanics, and degeneration after ACL injuries.

Interestingly, the Femur 8 mode was the only one that showed a statistically significant correlation with patient-reported symptoms, specifically pain, at 3Y after ACLR. This correlation may be partially due to the trochlear geometry changes as presented by this mode. Previously, Kalichman et al. (14) found that increasing trochlear angle was associated with WOMAC pain levels in subjects with symptomatic knee OA. In another study with 70 patients 5–10 years after ACLR, Culvenor et al. (15) observed that patellofemoral OA was associated with worse knee-related symptoms.

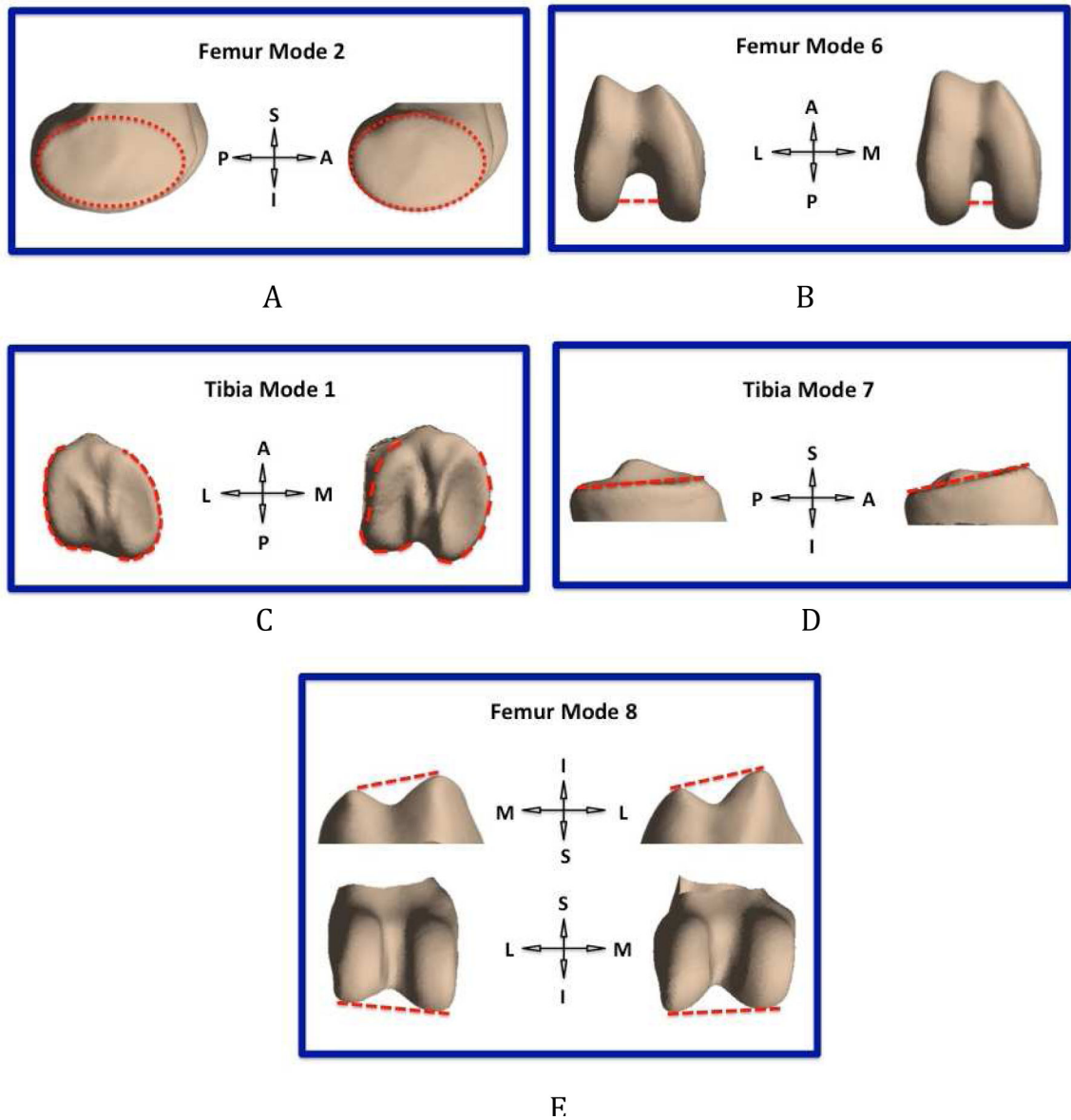
Despite the promising outcomes above, several limitations must be acknowledged: (1) Patellae were not included in the SSM; (2) The interval between ACL injury and ACLR spanned 4–37 weeks, which may have introduced variations to the data; (3) WORMS grading has limitations for evaluating acutely injured knees and other scoring system such as ACLOAS shall be considered for future studies. It should be noted, however, that the cartilage lesion grading is very similar with WORMS and ACLOAS. Also meniscal grading is similar but ACLOAS adds post-operative findings such meniscal repair and meniscectomy, which is not applicable to our study as pre-operative lesions were analyzed; (4) The study sample size was relatively small and since this is an exploratory and hypothesis forming study results were not adjusted for multiple comparisons. (5) The clinical significance of the observed bone shape findings remains unclear and needs to be explored in future studies.

In conclusion, our results suggest statistically significant bone shape changes occur after ACL injury and reconstruction. Early bone shape changes predicted cartilage degeneration and patient self-reported outcomes including pain at later stages. Such imaging markers could help to stratify patients who have high risks of developing PTOA after ACLR.

Role of the funding source

The study was supported by NIH/NIAMS P50 AR060752.

Appendix Figure 1.



The physical interpretation of bone shape modes. Bottom: representative shapes from control knees; right: representative shapes from ACL injured knees. (A) Femur Mode 2: (medial femoral condyle shape); (B) Femur Mode 6: (notch width); (C) Tibia Mode 1: (tibia plateau area); (D) Tibia Mode 7: (medial tibia slope); (E) Femur Mode 8: (trochlea inclination and medial femoral condyle height). A: anterior; P: posterior; S: superior; I: inferior; M: medial; L: lateral. Note: these shape features are the major ones associated with these modes. Each mode represents a whole set of 3D bone shape features beyond a single shape feature.

Appendix Table 1.: MRI image protocol for cartilage and bone shape

Sequence	TR/TE (ms)	ETL	Matrix	FOV (cm)	Slice thickness (mm)	Other parameters
Sagittal T2 fast spin-echo (FSE)	4,000/49.3	9	512*512	16	1.5	-
Sagittal 3D fast spin-echo (CUBE)	1500/25	32	384*384	16	1	-
Spin-lock frequency 500 Hz						
Sagittal Combined T1 ρ/T2-weighted (MAPSS)	9/3		256*128	14	4	T1ρ time spin-lock [0,10,40, 801 ms]
T2 preparation TE [0,13.7, 27.3, 54.7] ms						

TR: repetition time; TE: echo time; ETL: Echo train length; FOV: field of view

Appendix Table 2.: The baseline demographic characteristics

	ACL injury subjects (N=30)	Healthy controls (N=13)
Age (Years old)	32.00±7.97	33.84±5.03
Gender	Female	8 (61.54%)
	Male	5 (38.46%)
BMI (Kg/m ²)	24.10±2.71	23.62±2.52
Time from Injury to Surgery (Days)	74.38±53.52 (28–257)	
Time from Injury to Baseline MRI Scanning (Days)	17.70±28.80 (1–158)	

Appendix Table 3.: The baseline WOMBS of cartilage and meniscus of injured knees

Cartilage WOMBS											
	Grade	Frequency	Percent (%)		Grade	Frequency	Percent (%)		Grade	Frequency	Percent (%)
MFC	0	27	18	LFC	0	25	16.67	P	0	23	15.33
	1	1	0.67		1	2	1.33		1	2	1.33
	2	1	0.67		2	2	1.33		2	2	1.33
	3	1	0.67		3	1	0.67		3	3	2
MT	0	25	16.67	LT	0	16	10.67	TrF	0	26	17.33
	1	5	3.33		1	9	6		1	2	1.33
	2	0	0		2	5	3.33		2	0	0
	3	0	0		3	0	0		3	2	1.33
Meniscus WOMBS											
	Grade	Frequency	Percent (%)		Grade	Frequency	Percent (%)		Grade	Frequency	Percent (%)
MM	0	14	46.67		LM	0	12			40	

Cartilage WORMS								
Grade	Frequency	Percent (%)	Grade	Frequency	Percent (%)	Grade	Frequency	Percent (%)
1	4	13.33				1	5	16.67
>=2	12	40				>=2	13	43.34

Cartilage WORMS grading scales: 0 = normal cartilage; 1 = normal thickness but increased or otherwise abnormal signal on fluid sensitive sequences; 2 = partial thickness focal defect <1 cm in greatest width; 3 = multiple areas of partial-thickness defects intermixed with areas of normal thickness, or a partial-thickness defect wider than 1 cm but <75% of the region.

Meniscus modified WORMS grading scales: 0 = normal; 1 = intrasubstance abnormalities; 2 = non-displaced tear.

Appendix Table 4.: Marx Scores of the patients' activities at each time point (BL was for pre-injury activity)

Running					
BL	6-Months	1-Years	2-Years	3-Years	
2.33±0.69	1.78±0.81	1.83±0.79	2.22±0.65	2.22±1.00	
Cutting					
BL	6-Months	1-Years	2-Years	3-Years	
2.08±1.00	1.58±1.16	1.50±0.90	1.58±0.79	1.92±0.90	
Decelerating					
BL	6-Months	1-Years	2-Years	3-Years	
2.29±0.83	1.71±0.99	1.86±0.77	1.93±0.62	2.43±0.65	
Pivoting					
BL	6-Months	1-Years	2-Years	3-Years	
2.22±0.67	1.89±1.05	1.56±0.88	1.78±0.83	2.11±0.60	

References

1. Eggerding V, van Kuijk KS, van Meer BL, Bierma-Zeinstra SM, van Arkel ER, Reijman M, et al. Knee shape might predict clinical outcome after an anterior cruciate ligament rupture. *Bone Joint J.* 2014;96-B(6):737–42. [PubMed: 24891572]
2. Hunter D, Nevitt M, Lynch J, Kraus VB, Katz JN, Collins JE, et al. Longitudinal validation of periarticular bone area and 3D shape as biomarkers for knee OA progression? Data from the FNIH OA Biomarkers Consortium. *Ann Rheum Dis.* 2016;75(9):1607–14. [PubMed: 26483253]
3. Padoia V, Lansdown DA, Zaid M, McCulloch CE, Souza R, Ma CB, et al. Three-dimensional MRI-based statistical shape model and application to a cohort of knees with acute ACL injury. *Osteoarthritis Cartilage.* 2015;23(10):1695–703. [PubMed: 26050865]
4. Carballido-Gamio J, Bauer JS, Stahl R, Lee KY, Krause S, Link TM, et al. Inter-subject comparison of MRI knee cartilage thickness. *Med Image Anal.* 2008;12(2):120–35. [PubMed: 17923429]
5. Padoia V, Su F, Amano K, Li Q, McCulloch CE, Souza RB, et al. Analysis of the articular cartilage T1rho and T2 relaxation times changes after ACL reconstruction in injured and contralateral knees and relationships with bone shape. *J Orthop Res.* 2017;35(3):707–17. [PubMed: 27557479]
6. Peterfy CG, Guermazi A, Zaim S, Tirman PF, Miaux Y, White D, et al. Whole-Organ Magnetic Resonance Imaging Score (WORMS) of the knee in osteoarthritis. *Osteoarthritis Cartilage.* 2004;12(3):177–90. [PubMed: 14972335]

7. Antony B, Ding C, Stannus O, Cicuttini F, Jones G. Association of baseline knee bone size, cartilage volume, and body mass index with knee cartilage loss over time: a longitudinal study in younger or middle-aged adults. *J Rheumatol.* 2011;38(9):1973–80. [PubMed: 21724707]
8. Haverkamp DJ, Schiphof D, Bierma-Zeinstra SM, Weinans H, Waarsing JH. Variation in joint shape of osteoarthritic knees. *Arthritis Rheum.* 2011;63(11):3401–7. [PubMed: 21811994]
9. Beynnon BD, Hall JS, Sturnick DR, Desarno MJ, Gardner-Morse M, Tourville TW, et al. Increased slope of the lateral tibial plateau subchondral bone is associated with greater risk of noncontact ACL injury in females but not in males: a prospective cohort study with a nested, matched case-control analysis. *Am J Sports Med.* 2014;42(5):1039–48. [PubMed: 24590006]
10. Beynnon BD, Vacek PM, Sturnick DR, Holterman LA, Gardner-Morse M, Tourville TW, et al. Geometric profile of the tibial plateau cartilage surface is associated with the risk of non-contact anterior cruciate ligament injury. *J Orthop Res.* 2014;32(1):61–8. [PubMed: 24123281]
11. Khan N, Shepel M, Leswick DA, Obaid H. Increasing lateral tibial slope: is there an association with articular cartilage changes in the knee? *Skeletal Radiol.* 2014;43(4):437–41. [PubMed: 24414035]
12. Lansdown DA, Padoia V, Zaid M, Amano K, Souza RB, Li X, et al. Variations in Knee Kinematics After ACL Injury and After Reconstruction Are Correlated With Bone Shape Differences. *Clin Orthop Relat Res.* 2017;475(10):2427–35. [PubMed: 28451863]
13. Whitney DC, Sturnick DR, Vacek PM, DeSarno MJ, Gardner-Morse M, Tourville TW, et al. Relationship Between the Risk of Suffering a First-Time Noncontact ACL Injury and Geometry of the Femoral Notch and ACL: A Prospective Cohort Study With a Nested Case-Control Analysis. *Am J Sports Med.* 2014;42(8):1796–805. [PubMed: 24866891]
14. Kalichman L, Zhu Y, Zhang Y, Niu J, Gale D, Felson DT, et al. The association between patella alignment and knee pain and function: an MRI study in persons with symptomatic knee osteoarthritis. *Osteoarthritis Cartilage.* 2007;15(11):1235–40. [PubMed: 17570690]
15. Culvenor AG, Lai CC, Gabbe BJ, Makdissi M, Collins NJ, Vicenzino B, et al. Patellofemoral osteoarthritis is prevalent and associated with worse symptoms and function after hamstring tendon autograft ACL reconstruction. *Br J Sports Med.* 2014;48(6):435–9. [PubMed: 24285782]

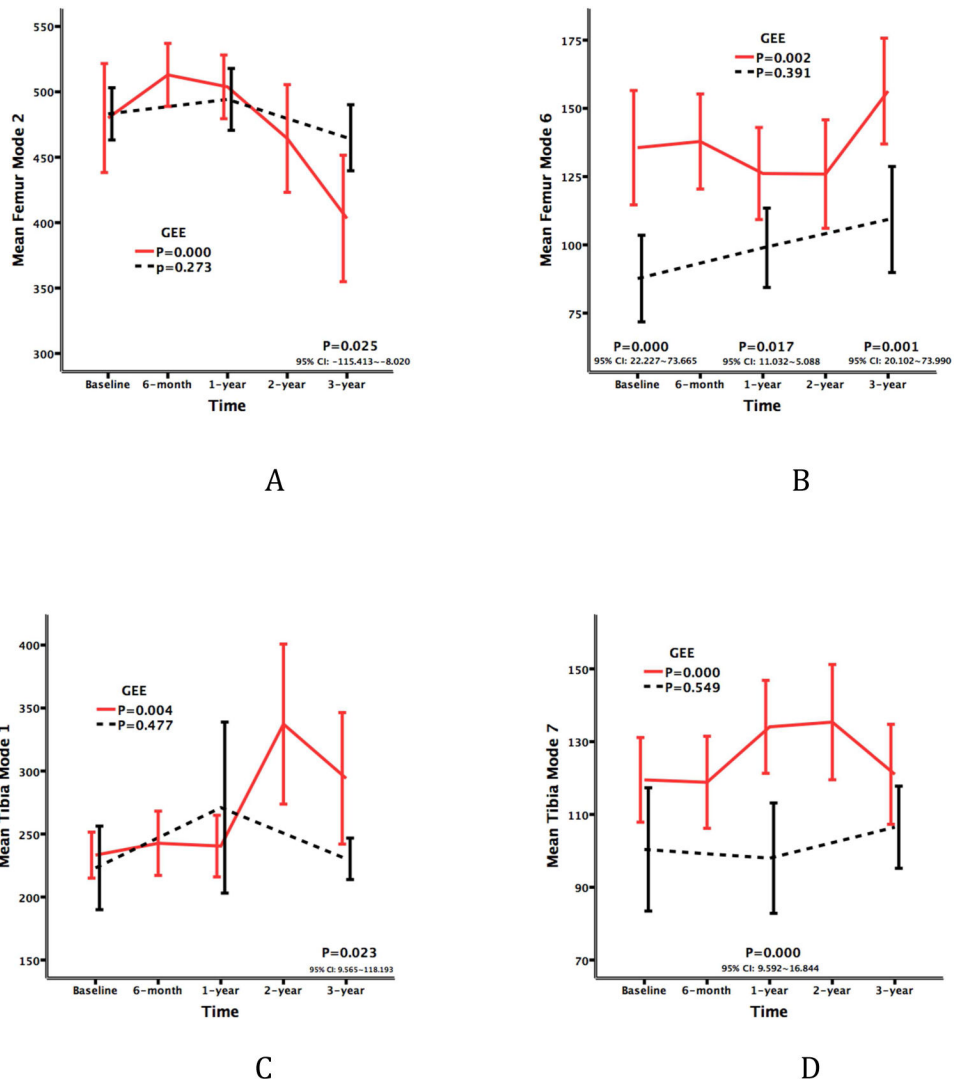


Figure 1. Longitudinal changes in bone-shape modes. (A) Femur Mode 2 (associated with medial femoral condyle shape); (B) Femur Mode 6 (associated with notch width); (C) Tibia Mode 1 (associated with tibia plateau area); (D) Tibia Mode 7 (associated with medial tibia slope). Red line, Injured knees group; black dashed line, Control knees group. P values of generalized estimating equation (GEE) models are shown on the right of each graph. P values <0.05 and 95% CI of cross-sectional comparison between injured and control knees at baseline, 1 year, and 3 years are shown within the text boxes above the X axis of each graph.

Table 1.

Relationship between the changes of bone shape and that of cartilage T1ρ & T2 and KOOS

Bone Shape F6		Cartilage LT Tip		Cartilage MF T2	
BL F6 135.60±56.11	6M F6 137.87±46.64	BL T1ρ 34.33±2.94	3Y T1ρ 34.60±3.55	BL T2 30.17±2.23	3Y T2 33.33±2.17
		R=-0.419 95% CI: -0.681~-0.063	P=0.023	R=-0.472 95% CI: -0.715~-0.172	P=0.010
Bone Shape F8		Cartilage Patella T2		KOOS Pain	
BL F8 264.97±49.03	6M F8 256.70±39.13	BL T2 28.23±2.39	3Y T2 29.53±3.19	BL 76.89±17.37	3Y 91.8±9.07
		R=0.510 95% CI: 0.177~0.739	P=0.005	R=-0.556 95% CI: -0.773~-0.223	P=0.003
Bone Shape T1		Cartilage LI T2			
BL T1 233.27±48.92	6M T1 242.67±68.28	BL T2 25.50±2.24	3Y T2 25.73±2.27		
		R=0.433 95% CI: 0.080~0.690	P=0.019		

Author Manuscript

Author Manuscript

Author Manuscript

Author Manuscript