

# UC San Diego

## UC San Diego Previously Published Works

### Title

Perinatal (fetal and neonatal) choroid plexus tumors: a review

### Permalink

<https://escholarship.org/uc/item/0sm7q5q7>

### Journal

Child's Nervous System, 35(6)

### ISSN

0256-7040

### Authors

Crawford, John R

Isaacs, Hart

### Publication Date

2019-06-01


### DOI

10.1007/s00381-019-04135-x

Peer reviewed



# Perinatal (fetal and neonatal) choroid plexus tumors: a review

John R. Crawford<sup>1,2,3</sup> · Hart Isaacs Jr<sup>3,4</sup> 

Received: 13 September 2018 / Accepted: 20 March 2019 / Published online: 5 April 2019  
© Springer-Verlag GmbH Germany, part of Springer Nature 2019

## Abstract

**Introduction** The object of this review is to describe the choroid plexus tumors (CPTs) occurring in the fetus and neonate with regard to clinical presentation, location, pathology, treatment, and outcome.

**Materials and methods** Case histories and clinical outcomes were reviewed from 93 cases of fetal and neonatal tumors obtained from the literature and our own institutional experience from 1980 to 2016.

**Results** Choroid plexus papilloma (CPP) is the most common tumor followed by choroid plexus carcinoma (CPC) and atypical choroid plexus papilloma (ACPP). Hydrocephalus and macrocephaly are the presenting features for all three tumors. The lateral ventricles are the main site of tumor origin followed by the third and fourth ventricles, respectively. CPTs of the fetus are detected most often near the end of the third trimester of pregnancy by fetal ultrasound. The extent of surgical resection plays an important role in the treatment and outcome. In spite of excellent survival, which is especially true in the case of CPP, surgical resection may carry significant risks in an immature baby. Given the neonatal low blood volume and increased vascularity of the tumors, there is potential risk for hemorrhage. Although advances in neurosurgical techniques have led to a greater degree of complete surgical resections, survival for the perinatal CPC group remains low even with multimodality therapies.

**Conclusion** Perinatal CPTs have variable overall survivals depending on degree of surgical resection and tumor biology. An increased understanding of the molecular features of these tumors may lead to improved therapies and ultimately survival.

**Keywords** Fetal choroid plexus papilloma · Neonatal choroid plexus papilloma · Fetal choroid plexus carcinoma · Neonatal choroid plexus carcinoma · Fetal atypical choroid plexus papilloma · Neonatal atypical choroid plexus papilloma · Congenital brain tumor · Intracranial hemorrhage

## Introduction

Choroid plexus tumors (CPTs) are papillary neoplasms of neuroectodermal origin arising from the choroid plexus epithelium of the cerebral ventricles [6, 9, 14, 22, 27, 32, 33, 35, 36, 42, 44, 47, 54, 56–58, 65, 66, 68, 81]. CPTs are uncommon comprising only 10% of all brain tumors in infants and 5% of all perinatal brain tumors [20, 31, 35, 64]. Due to their

rarity and because they mimic more common intracranial conditions, such as hemorrhage, infection, and hydrocephalus secondary to congenital defects, these tumors may be missed [36, 79]. The majority of CPTs are diagnosed during the first year of life and are often times sporadically detected. In some cases, CPTs are found in association with cancer predisposition syndromes including Aicardi and Li-Fraumeni syndromes. The Li-Fraumeni syndrome is associated with a TP53 chromosomal anomaly [2, 27, 76]. Aicardi syndrome is an X-linked disorder whose manifestations are generally observed in utero and at birth [24]. The Li-Fraumeni syndrome may present in the perinatal period with a malignant neoplasm such as a rhabdomyosarcoma in addition to choroid plexus carcinoma (CPC) [28].

CPTs are classified by the World Health Organization (WHO) as grade 3 malignant choroid plexus carcinoma (CPC); grade 2, intermediate atypical choroid plexus papilloma (ACPP); and grade 1 benign choroid plexus papilloma (CPP) [47]. Lower grade CPTs are more prevalent than higher grade ones; CPPs outnumber CPCs by a ratio of 2:1. CPTs

✉ Hart Isaacs, Jr  
hisaacs@ucsd.edu

<sup>1</sup> Department of Neurosciences, University of California San Diego School of Medicine, La Jolla, CA, USA

<sup>2</sup> Department of Pediatrics, University of California San Diego School of Medicine, La Jolla, CA, USA

<sup>3</sup> Rady Children's Hospital San Diego, San Diego, CA, USA

<sup>4</sup> Department of Pathology, University of California San Diego School of Medicine, San Diego, CA, USA

generally present with rapid onset of hydrocephalus in the perinatal period, a sign that should alert clinicians to pursue neuroimaging. The purpose of this study is to review the clinical and pathologic features of this very rare tumor of the fetus and neonate.

## Materials and methods

Clinical information from 93 fetuses and neonates diagnosed with CPTs were obtained from the published literature utilizing a National Library of Medicine (PubMed) search from 1980 to 2016 together with data from the authors' personal unpublished experiences in cases collected from Children's Hospital Los Angeles and Rady Children's Hospital San Diego. The terms used for literature search included choroid plexus tumors, choroid plexus papilloma, choroid plexus carcinoma, atypical choroid plexus papilloma, fetal, and neonatal.

**Definitions** The review is confined to fetuses with CPTs that are found at birth or on the first day of life and neonates with tumors discovered during the first 3 months of life. Only cases with adequate clinical and pathological data and where outcomes of pregnancy and survival were described were reviewed. Data were collected regarding initial presentation, sex of the fetus or neonate, gestational age, birth weight, tumor location, tumor size, histology and grade, treatment, and outcome. Tumor diagnosis was confirmed in patients on this study by histological confirmation of biopsy or surgical and/or autopsy material. The length of follow-up ranged from 1 week to 10 years.

## Results

Hydrocephalus, macrocephaly, and intracranial mass are the chief presenting signs of CPTs. Lateral ventricles are the main sites of origin followed by the third and fourth ventricles [16, 36]. CPP is the most common neoplasm followed by CPC and ACPP (Table 1). The majority of neoplasms are detected by ultrasonography most often toward the end of the third trimester of pregnancy. Lower grade CPTs are more common than higher ones. There are significant differences in overall survival ranging from 40 to 80%. CPP has twice the survival rate of CPC; ACPP is intermediate between the two (Table 1). Data show that surgery plays an important role in the treatment and outcome. Total tumor resection is the mainstay of treatment of CPTs. The exact role of adjuvant therapy in the treatment of CPTs is problematic; currently, surgery and, in the case of CPC, adjuvant chemotherapy and radiation are used. However, the exact role of adjuvant therapy in this age group requires further study and review [67, 81, 85].

## Choroid plexus papilloma

CPP is a neoplasm composed of epithelial cells that line the ventricular choroid plexuses [1, 3–5, 7, 9, 11, 13, 15–17, 19, 23, 24, 29, 31–37, 39, 41, 46, 50, 52, 53, 55, 59, 63–69, 72–76, 78–80] (Fig. 1a). In the pediatric age group, half occur in the first year of life [4, 12, 30, 41, 66, 76–78]. Hydrocephalus, macrocephaly, and a mass on imaging are the major presenting findings. CPTs also are responsible for stillbirth [12, 26]. An association of a giant melanocytic nevus and CPP in a neonate has been described [50].

The papilloma grows into a ventricle producing a space, occupying finely nodular lesion readily visualized on imaging studies [9, 11, 13, 35, 36]. Lateral ventricles are the main sites of origin (64%) (Table 1). Less often, CPP arises from a third or fourth ventricle [1, 29, 47, 59, 64]. At the time of diagnosis, hydrocephalus is noted in practically all cases and is attributed to oversecretion of CSF and/or tumor blockage of the ventricular system [20]. When large volumes of CSF are produced by the tumor, eventually marked dilatation of the entire ventricular system occurs. Massive hydrocephalus and severe cortical atrophy may be detected in utero or found at birth [15, 19, 76].

## Pathology

The papilloma has a finely nodular, pink, cauliflower-like gross appearance (Fig. 1a). Ventricular tumors measure as large as 9 cm in diameter. Some are enormous, filling the entire intracranial cavity [25, 35, 36]. Microscopically, they consist of many finger-like papillary formations composed of a delicate fibrovascular core covered by uniform, regular cuboidal to columnar epithelial cells resembling the choroid plexus [16, 36, 47, 65] (Fig. 1a).

**Immunohistochemical findings** CPPs show immunoreactivity with vimentin and cytokeratin while transthyretin and s-100 protein are variably positive [9, 42, 65]. An elevated mitotic rate is used as an indicator as to whether a CPP is malignant or not. The Ki67/MIB1 labeling index for CPPs is given at 1.9% [65]. However, it should be mentioned that a recent report states that increased mitotic activity is prognostic only in the older child [71].

CPP consists of several histologic variants. *Villous hypertrophy (VH) versus CPP VH* is defined as diffuse bilateral enlargement of the ventricular choroid plexus(s) [7, 17, 19, 23, 78, 79]. This variant is described as an important cause of shunt-resistant hydrocephalus in fetuses and infants secondary to excessive production of CSF. Imaging reveals a bulky appearance of two or more choroid plexuses [79]. When shunting fails, CSF accumulations and ascites occur [79]. This condition interchangeably has been called VH,

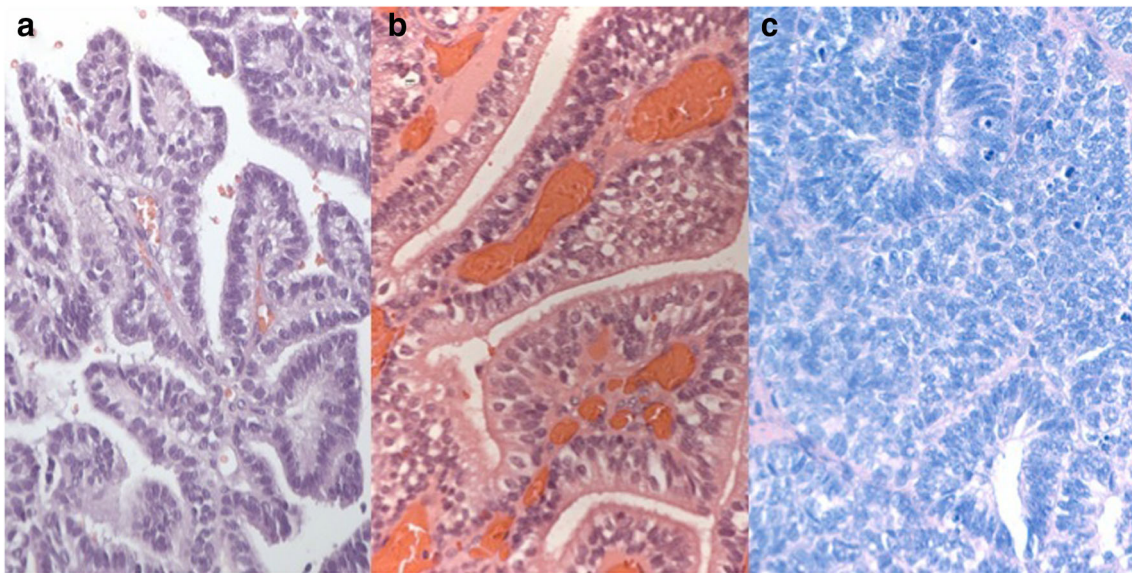
**Table 1** Clinical characteristics of choroid plexus tumors of the fetus and neonate

	Choroid plexus papilloma N = 53	Atypical choroid plexus papilloma N = 9	Choroid plexus carcinoma N = 31
Male	30	5	19
Female	18	4	10
Gender not available	5	5	2
Fetuses	19	5	10
Neonates	34	4	11
Gestation age (weeks)	34 <sup>4</sup> (range, 21–40) <sup>5</sup>	32 <sup>4</sup> (range, 21–39)	32 <sup>4</sup> (range, 21–38)
Birth weight (g)	3300 (range, 2370–4394)	NA	2925 (range, 2370–3685)
Presenting features			
Hydrocephalus	29	2	10
Macrocephaly	20	7	9
head circumference (cm)	42 (range, 36–56)	42 (range 40–46)	42 (range, 35–48)
Intracranial mass on ultrasound	28	9	6
Bulging fontanel	12	2	5
Ophthalmologic signs	11	1	3
Seizures	8	–	–
Aicardi syndrome	4	1	3
Li-Fraumeni syndrome	–	–	2
Diastasis of sutures	3	2	3
Hypotonia	3	–	2
Dystocia	2	1	2
Stillbirth	–	–	2
Deformed cranium	–	–	2
Hemiparesis/hemiplegia	2	–	–
Cutaneous hemangioma	2	–	2
Vomiting	2	–	4
Tumor location			
Left lateral ventricle	20	1	12
Right lateral ventricle	14	1	5
3rd ventricle	12	2	2
4th ventricle	7	1	4
Bilateral ventricles	–	1	–
Number of patients treated	43	5	29
Ventriculoperitoneal shunt	29/43 (67%)	5/5 (100%)	11/31 (35%)
Surgery alone	43/53 (81%)	4/5 (80%)	14/29 (48%)
Surgery + chemotherapy	–	–	14/29 (48%)
Overall survival	53/53 (81%)	6/9 (67%)	14/31 (45%)

bilateral choroid plexus hyperplasia or bilateral CPP. In addition, imaging of the involved brains often shows severe hydrocephalus and cortical atrophy [19].

**Cysts, cystic CPP.** Cysts develop within the tumor or adjacent cortex in 7.5% of patients with CPPs. They are found on imaging either before birth, after birth, or following surgical resection [2, 19, 31, 41, 52, 76]. Cysts range in size and occur on or directly beneath the ependymal lining. They vary from less than 1 cm to as large as 6.5 cm. Microscopically, the cysts are lined by cuboidal to columnar choroid plexus–like cells and contain pale yellow fluid. Cysts markedly increase in size

in utero [52]. Most occur concomitantly in patients with CPPs, 4/53 or 7.5%. There is some debate regarding their histogenesis. Microscopically, the cysts are lined by single layers of cuboidal to columnar and occasionally squamous epithelium which is consistent with choroid plexus origin [4]. In addition, they are described in the Aicardi syndrome [2]. Some produce intermittent obstruction through stromal invasion. Levy et al. suggest that CPPs with a benign cellular appearance and presence of local brain invasion, and absence of the normal villous architecture at the site of invasion could be classified as CPP rather than CPC.



**Fig. 1** Histological features of fetal/neonatal choroid plexus papilloma (a), atypical choroid plexus papilloma (b), and choroid plexus carcinoma (c)

They propose that patients with this histology respond to surgical therapy alone without the need for adjuvant treatment [45].

#### Treatment and outcome

CPP has a better prognosis among all CPTs. Most patients who receive gross total resection as their primary treatment survive [4, 5, 15, 27, 36, 44, 50, 54, 57, 66, 70, 74, 75]. Approximately half of the patients with CPP receive a pre- or postoperative VPS (29/53 or 55%) inserted for varying lengths of time. Survival with surgical resection alone approximates 95% in this age group (Table 1). When the tumor embolization regimen was added to two CPP cases prior to surgery, both infants survived [3]. Siegfried et al. reported similar survivals (100%) in 54 CPPs under the age of 18 [67].

In spite of excellent survivals, surgical resection of CPT may have significant risks in an immature baby. Given low blood volume, extensive hemorrhage may occur due to the highly vascular nature of the tumor [5, 36, 62]. Moreover, during the operation, abnormal blood clotting defects may appear [5]. Frequently, there is difficulty in finding or identifying the choroidal vessel(s) supplying the tumor which are needed for cannulation or ablation [20]. The use of irradiation as part of the adjuvant treatment regimen in the fetus and neonate is not recommended in this age group and gives devastating neurocognitive consequences of radiation therapy in young children [67, 72, 73].

#### Atypical choroid plexus papilloma

ACPP is neoplasm of neuroepithelial origin consisting of epithelial cells that are thought to be derived from the ventricular

choroid plexuses. This tumor is responsible also for the rapid onset of perinatal hydrocephalus and occasionally stillbirth [20, 30, 49, 53, 68]. Nine patients, consisting of five fetuses and four neonates with this diagnosis, were identified in the literature (Table 1). In common with CPP and CPC hydrocephalus, an intracranial mass and macrocephaly are the presenting findings. Fetuses with ACPP are found most often by prenatal imaging [20, 25, 30, 64]. The tumor has greater recurrence and mortality rates than CPP but lesser ones than those of CPC.

#### Pathology

ACPPs range in size from 2 to 8 cm. Gross and microscopic findings resemble those of CPP. In addition to the finely nodular, whitish-pink, cauliflower-like gross appearance of CPP, scattered, flattened gray areas may be seen on the outer tumor surfaces. Microscopically, the atypical changes consist of foci of hypercellular epithelium, few mitoses, crowding, shortening, broadening of villi, and piling up of cells obscuring villous formations (Fig. 1b). Other varying degrees of atypia described are pleomorphism, hyperchromasia, and focal necrosis [25, 30, 36–38, 40, 49, 65, 68]. In keeping with the definition of ACPP, neither invasion of adjacent brain tissue nor metastases are present [46]. Nevertheless, microscopic distinction between ACPP and CPC often can be difficult. ACPP is classified by the World Health Organization (WHO) as an intermediate grade 2 [47]. A low mitotic activity index (proliferation index) has been used for distinguishing ACPP from CPC [37]. As mentioned above, there are recent reports stating that increased mitotic activity is prognostic only in older children [37, 70].

## Treatment and outcome

Surgical resection, embolization, and chemotherapy are the main forms of treatment [20, 30, 80]. Locating and cannulating tiny choroidal tumor feeding vessels, especially those of low birth weight premature infants, can be a difficult technical problem when performing a surgical resection or embolization. To avoid this, neoadjuvant chemotherapy has been used to reduce tumor vascularity allowing for a higher degree of safe surgical resection [20, 60, 80, 83]. Irradiation is not recommended for infants because of its damaging effects on developing tissues [70, 85]. Siegfried et al. reported outcomes of 26 patients under the age of 18 years with ACPP. Of these, 18 had a complete resection. Twenty-three percent were treated with chemotherapy. The authors report 92% of patients in complete remission and only one death [67].

The overall survival rate of perinatal ACPP patients is 67%, which is intermediate between CPP, 81%, and CPC, 45% (Table 1).

## Choroid plexus carcinoma

CPCs account for less than 1% of childhood brain tumors and are found usually in infants less than 3 years of age. Fewer than half of CPCs are reported in the first year of life [38, 40, 46, 58, 76, 81]. Some are associated with certain cancer predisposing conditions, for example, the Aicardi and the Li-Fraumeni syndromes [1, 21, 24, 28, 69, 74, 77]. Manifestations of the Aicardi syndrome are found in utero or at birth. There is a high frequency of TP53 germline mutations associated with the Li-Fraumeni syndrome; 36% of patients with CPC in this review had the defect [28].

Like other members of the CPT group, hydrocephalus is the leading initial, presenting finding, next are macrocephaly and an intracranial tumor detected by imaging. CPCs are highly invasive frequently metastasizing by the time of diagnosis. Some are found at birth [22, 58]. CSF cytological examination for malignant cells should be an integral part of the patient's initial evaluation [36]. The lateral ventricles are the most common primary sites (Table 1) [4, 11, 12, 19, 31, 66]; less common locations are the third and fourth ventricles [8, 10, 18, 81, 82]. Metastases occur predominately along the cerebrospinal fluid axis; however, extra CNS metastatic disease has been reported in the abdomen, lung, and bone [81].

## Pathology

CPC is classified as a malignant neoplasm, stage 3 by the World Health Organization (WHO) [47]. The gross appearance varies from a grayish white cauliflower-like mass similar to CPP and ACPP to a smooth, purple, firm mass or an ill-defined, soft, mushy, gray, piece of tissue with foci of hemorrhage and necrosis. Tumors range in size; the largest one here

measured 10.5 cm in diameter. Some are enormous, filling almost the entire intracranial cavity. Histological findings

Diagnosis of CPC rests on certain histologic criteria including hypercellularity, pleomorphic nuclei, increased mitotic activity, vascular proliferation, and infiltration into the adjacent brain [9, 42] (Fig. 1c). CPCs show a high proliferative activity with Ki67 [37, 65]. Differential diagnosis includes papillary ependymoma, metastatic carcinoma, and atypical teratoid rhabdoid tumor (ATRT) [9, 42, 65]. The epithelial antigens cytokeratin and vimentin are not expressed by either medulloblastoma or ATRT. Some CPCs may contain areas that resemble the small, blue cell, anaplastic rhabdoid tumor, but this entity can be ruled out by the presence of INI-1 gene product reactivity [9, 65]. Other tumors in the differential diagnosis include the anaplastic ependymoma that consists of dense collections of small, darkly staining malignant cells plus papillary structures with nuclear atypia and bizarre and multinucleated giant cells [9, 36]. Areas of malignancy may resemble those of metastatic undifferentiated carcinoma.

## Treatment and outcome

Surgery plays an important role in the treatment and outcome. Gross total resection is the goal and main treatment initially [16, 40, 48, 60, 61]. Due to the highly vascular nature of CPC, surgery may be severely compromised by extensive intraoperative hemorrhage and the infant's small total circulating blood volume [20, 22, 64, 66]. If surgery can be performed before irreversible brain damage has occurred as the result of severe hydrocephalus and/or hemorrhage, a favorable outcome can be anticipated [60]. Although surgical resection remains the most important factor for long-term survival, adjuvant therapy is required for treatment of residual, recurrent, or tumor metastases [43, 48, 58, 67, 82, 84, 85]. Malick et al. performed a review of 284 patients (median age 2 years) from 89 studies [48]. More than half of patients had a gross total or near total resection. At a median follow-up of 18 months, the progression-free survival was a dismal 13 months. While this study was not specific to the fetus or neonate, survival in children more than 5 years of age with multimodality chemotherapy and radiation had improved survival. In the retrospective series reported by Siegfried et al. of CPC under the age of 18, the 5-year overall survival was 64.7% [67]. However, the overall survival for fetuses and neonates with CPC remains low.

## Molecular advances in choroid plexus tumors

Rapid advances in brain tumor genetics have led to a greater understanding of the biology of CPTs. Merino et al. analyzed 100 CPTs for copy number, gene expression, and methylation profiles [51]. CPCs were defined as having hypodiploid and hyperdiploid copy number. Somatic mutations in TP53 were

observed in 60% of CPCs, while TP53 germline variants were detected in 24% of cases [51]. Chromosomal gains/losses were able to distinguish CPC from CPP/ACPP, which provides evidence that CPP and ACPP may be a single biologic entity. Thomas et al. performed methylation profiling in a series of 92 CPTs (29 CPP, 32 ACPP, 31 CPC), 13 of which were under 1 year of age [71]. Methylation cluster analysis revealed three unique subgroups, two of which (groups 1 and 3) were comprised solely of pediatric CPTs. Group 1 was comprised of CPP and ACPP, while group 3 contained CPP, ACPP, and CPC. Group 1 had gains in chromosomes 12, 9p, and 11. Group 3 revealed losses in chromosomes 6q,6p,22,11p,1,6,19q and gains of 1p32-35.1 [71]. Only 1 of 42 patients in groups 1–2 progressed. In the case of group 3, the progression-free survival was 72 months (range 55–89 months). All CPC in group 3 had a shorter progression-free survival (55 months, range 36–73 months) [71]. Overall, these studies have given us more insight into the molecular underpinnings of CPTs that may someday provide improved adjuvant therapies, particularly for CPC.

## Discussion

Our retrospective review of perinatal CPTs consisting of a literature review from case histories of 93 fetal and neonatal CPTs obtained from the world literature and personal files from 1980 to 2016 comprises the most comprehensive analysis in this age group. The retrospective nature of the literature review was the biggest limitation of the manuscript especially in determining accurate progression-free and overall survival. The limited clinical information regarding extent of surgical resection, adjuvant therapies, and long-term follow-up obtained from a literature review precludes an accurate Kaplan-Meier estimate of overall and event-free survivals among the various CPT subtypes.

Several CPT treatment approaches have been proposed [59, 65, 78, 80, 81]. Approximately half the patients in this review received a VP shunt. CPT treatment begins with surgical resection (gross total resection if possible), which is then followed by adjuvant therapy in the case of CPC and an observational approach in CPP and ACPP [78].

In cases of incomplete resection, residual or recurrent tumor, or metastases, patients received some form of adjuvant chemotherapy [65, 78, 81]. CPPs are usually cured by surgery alone with a survival rate approaching 100% [63]. Some CPTs are considered inoperable because of their large size or the unstable condition of the infant. The overall survival rates for fetal/neonatal CPTs based on our review were 81% for CPP, 66.7% for ACPP, and 45.2% for CPC.

One of the puzzling unexplained aspects in the treatment of CPTs is the persistence of hydrocephalus accompanied by progressive parenchymal atrophy and subsequent intellectual

disability even in those patients who have undergone early total resection and placement of a VP shunt [19, 36, 58]. Hydrocephalus per se is a decisive factor in the choice of treatment and time of delivery. In some cases, it may be more life threatening than the tumor itself. If delivery is delayed until term, the prognosis may be worse for the hydrocephalic fetus than it would be for a non-hydrocephalic one [12]. An increased understanding of gene expression profiles, copy number analysis, and methylation profiles may allow for risk stratification based upon molecular genetics, and the possibility of improved adjuvant therapies, particularly in the case of CPC that are associated with high rates of TP53 mutations [51, 71].

## Compliance with ethical standards

**Conflict of interest** The authors declare no conflict of interest.

## References

1. Adra AM, Mejides AA, Salman FA (1994) Prenatal sonographic diagnosis of a third ventricle choroid plexus papilloma. *Prenat Diagn* 14:865–867
2. Aicardi J (2005) Aicardi syndrome. *Brain and Development* 27: 164–171
3. Aljared T, Farmer J, Tampieri D (2016) Feasibility and value of preoperative embolization of a congenital choroid plexus tumour in the premature infant: an illustrative case report with technical details. *Interv Neuroradiol* 22(6):732–735
4. Anselem O, Mezzetta L, Grangé G, Zerah M, Benard C, Marcou V, Fallet-Bianco C, Adamsbaum C, Tsatsaris V (2011) Fetal tumors of the choroid plexus: is differential diagnosis between papilloma and carcinoma possible? *Ultrasound Obstetr Gynecol* 38:229–232
5. Barber MA, Eguiluz I, Plasencia W, Medina M, Valle L (2009) Intracranial fetal hemorrhage due to choroid plexus papilloma. *Inter Gynecol Obstetr* 105:172–173
6. Bekiesinska Figatowska M, Jurkiewicz E, Duczowski M et al (2011) Congenital CNS tumors diagnosed on prenatal MRI. *Neuroradiol J* 24:477–481
7. Britz GW, Kim DK, Loeser JD (1996) Hydrocephalus secondary to diffuse villous hyperplasia of the choroid plexus. Case report and review of the literature. *J Neurosurg* 85:689–691
8. Broad RW, Allen PB (1984) Third ventricle choroid plexus carcinoma. *Canad J Neurol Sci* 11:461–465
9. Burger PC, Scheithauer BW (2007) Tumors of the central nervous system. Atlas of tumor pathology, 4th series, fascicle 7. Armed forces Institute of Pathology, Washington, D.C.
10. Carlotti CG, Salhia B, Weitzman S, Greenberg M, Dirks PB, Mason W, Becker LE, Rutka JT (2002) Evaluation of proliferative index and cell cycle protein expression in choroid plexus tumors in children. *Acta Neuropathol* 103:1–10
11. Cassart M, Bosson N, Garel C, Eurin D, Avni F (2008) Fetal intracranial tumors: a review of 27 cases. *Eur Radiol* 18:2060–2066
12. Cavalheiro S, Moron AF, Hisaba W, Dastoli P, Silva NS (2003) Fetal brain tumors. *Child Nerv Syst* 19:529–536
13. Chow PP, Horgan JG, Burns PN, Weltin G, Taylor KJ (1986) Choroid plexus papilloma: detection by real-time and Doppler sonography. *AJNR Am J Neuroradiol* 7:168–170
14. Chow E, Reardon DA, Shah AB (1999) Pediatric choroid plexus neoplasms. *Inter J Radiat Oncol Biol Phys* 44:249–254

15. Cohen ZR, Achiron R, Feldman Z (2002) Prenatal sonographic diagnosis of lateral ventricle choroid plexus papilloma in an in vitro fertilization-induced pregnancy. *Pediatr Neurosurg* 37: 267–270
16. Costa JM, Ley L, Claramunt E et al (1997) Choroid plexus papillomas of the III ventricle in infants. Report of three cases. *Child Nerv Syst* 13(5):244–249
17. D'Ambrosio AL, O'Toole JE, Connolly ES et al (2003) Villous hypertrophy versus choroid plexus papilloma: a case report demonstrating a diagnostic role for the proliferation index. *Pediatr Neurosurg* 39:91–96
18. de Oliveira RS, Deriggi DJ, Furlanetti LL et al (2015) The impact of surgical resection of giant supratentorial brain tumor in pediatric patients: safety and neurological outcome evaluated in 23 consecutive cases. *Child Nerv Syst* 31:67–75
19. Di Rocco C, Iannelli A (1997) Poor outcome of bilateral congenital choroid plexus papillomas with extreme hydrocephalus. *Eur Neurol* 37:33–37
20. Ditz C, Nowak G, Koch C et al (2013) Atypical choroid plexus papilloma in a newborn: prenatal diagnosis, preoperative tumor embolization, and resection. *J Neurol Surg Part A: Central Europe Neurosurg* 74:59–63
21. Donnenfeld AE, Packer RJ, Zackai EH, Chee CM, Sellinger B, Emanuel BS (1989) Clinical, cytogenetic, and pedigree findings in 18 cases of Aicardi syndrome. *Am J Med Genet* 32:461–467
22. Duffner PK, Kun LE, Burger PC, Horowitz ME, Cohen ME, Sanford RA, Krischer JP, Mulhern RK, James HE, Reigate HL, Friedman HS (1995) Postoperative chemotherapy and delayed radiation in infants and very young children with choroid plexus carcinomas. The Pediatric Oncology Group. *Pediatr Neurosurg* 22:189–196
23. Erman T, Gocer AI, Erdogan S et al (2003) Choroid plexus papilloma of bilateral lateral ventricle. *Acta Neurochir* 145:139–143
24. Frye RE, Polling JS, Ma LC (2007) Choroid plexus papilloma expansion over 7 years in Aicardi syndrome. *J Child Neurol* 22: 484–487
25. Gertz HJ, Unger M, Lobeck H (1990) Histological and immunocytochemical findings in a case of fetal choroid plexus papilloma. *Zentralbl Allg Pathol* 136:719–722
26. Gianella Borradori A, Zeltzer PM, Bode B et al (1992) Choroid plexus tumors in childhood. Response to chemotherapy, and immunophenotypic profile using a panel of monoclonal antibodies. *Cancer* 69:809–816
27. Gopal P, Debski R, Parker JC (2008) Choroid plexus carcinoma. *Arch Pathol Lab Med* 132:1350–1354
28. Gozali AE, Britt B, Shane L et al (2012) Choroid plexus tumors; management, outcome, and association with the Li-Fraumeni syndrome: Children's Hospital Los Angeles (CHLA) experience, 1991–2010. *Pediatr Blood Cancer* 58:905–909
29. Gupta P, Sodhi KS, Mohindra S et al (2013) Choroid plexus papilloma of the third ventricle: a rare infantile brain tumor. *J Pediatr Neurosci* 8:247–249
30. Hartge DR, Axt Fliedner R, Weichert J (2010) Prenatal diagnosis and successful postnatal therapy of an atypical choroid plexus papilloma—case report and review of literature. *J Clin Ultrasound* 38:377–383
31. Honda E, Hayashi T, Kuramoto S (1984) A case of choroid plexus papilloma in the lateral ventricle, complicated by a neuroepithelial cyst in the posterior fossa in a newborn infant. *Kurume Med J* 31: 115–124
32. Isaacs H Jr (2002) I. Perinatal brain tumors: a review of 250 cases. *Pediatr Neurol* 27:249–261
33. Isaacs H Jr (2002) II. Perinatal brain tumors: a review of 250 cases. *Pediatr Neurol* 27:333–342
34. Isaacs H Jr (2009) Fetal brain tumors: a review of 154 cases. *Am J Perinatol* 26:453–466
35. Isaacs H Jr (2013) Brain tumors. In: Isaacs H Jr (ed) *Tumors of the fetus and infant: an atlas*. Springer-Verlag, New York, pp 163–195
36. Isaacs H Jr (1997) Brain tumors. In: Isaacs H Jr (ed) *Tumors of the fetus and newborn: vol. 35 in the series major problems in pathology*. W.B. Saunders Co, Philadelphia, pp 223–228
37. Jeibmann A, Hasselblatt M, Gerss J, Wrede B, Egensperger R, Beschoner R, Hans VHI, Rickert CH, Wolff JE, Paulus W (2006) Prognostic implications of atypical histologic features in choroid plexus papilloma. *J Neuropathol Exp Neurol* 65:1069–1073
38. Joó GJ, Reiniger L, Papp C, Csaba Á, Komáromy H, Rigó J Jr (2014) Intrauterine diagnosis and pathology of fetal choroid plexus carcinoma—a case study. *Pathol Res Pract* 210:1156–1159
39. Jooma R, Grant DN (1983) Third ventricle choroid plexus papillomas. *Child Brain* 10:242–250
40. Kang HS, Wang KC, Kim IO, Kim SK, Chi JG, Cho BK (1997) Choroid plexus carcinoma in an infant. *J Korean Med Sci* 12:162–167
41. Kennedy EC, Cloney MB, Anderson RC et al (2015) Superior parietal lobule approach for choroid plexus papillomas without preoperative embolization in very young patients. *J Neurosurg Pediatr* 16:101–106
42. Kleihues P, Cavenee WK (1997) Pathology and genetics of tumors of the nervous system, vol 17. International Agency for Research on Cancer, World Health Organization, Lyon, pp 245–247
43. Kumabe T, Tominaga T, Kondo T et al (1996) Intraoperative radiation therapy and chemotherapy for huge choroid plexus carcinoma in an infant—case report. *Neurol Med Chir* 36:179–184
44. Kumar R, Achari G, Benerji D et al (2002) Choroid plexus papillomas of the cerebellopontine angle. *Neurol India* 50:352–358
45. Levy ML, Goldfarb A, Hyder DJ et al (2001) Choroid plexus tumors in children: significance of stromal invasion. *Neurosurg* 48: 303–309
46. Lippa C, Abroms IF, Davidson R, DeGirolami U (1989) Congenital choroid plexus papilloma of the fourth ventricle. *J Child Neurol* 4: 127–130
47. Louis DN, Perry A, Reifenberger G, von Deimling A, Figarella-Branger D, Cavenee WK, Ohgaki H, Wiestler OD, Kleihues P, Ellison DW (2016) The 2016 World Health Organization classification of tumors of the central nervous system: a summary. *Acta Neuropathol* 131(6):803–820
48. Mallick S, Benson R, Melgandi W, Rath GK (2017) Effect of surgery, adjuvant therapy, and other prognostic factors on choroid plexus carcinoma: a systematic review and individual patient data analysis. *Int J Radiat Oncol Biol Phys* 99(5):1199–1206
49. Manoranjan B, Provias JP (2011) Congenital brain tumors: diagnostic pitfalls and therapeutic interventions. *J Child Neurol* 26:599–614
50. McCune AB, Cohen BA, Gartner JC (1990) Congenital choroid plexus papilloma and giant nevomelanocytic nevus: report of a case. *J Am Acad Dermatol* 22:849–851
51. Merino DM, Shlien A, Villani A, Pienkowska M, Mack S, Ramaswamy V, Shih D, Tatevossian R, Novokmet A, Choufani S, Dvir R, Ben-Arush M, Harris BT, Hwang EI, Lulla R, Pfister SM, Achatz MI, Jabado N, Finlay JL, Weksberg R, Bouffet E, Hawkins C, Taylor MD, Tabori U, Ellison DW, Gilbertson RJ, Malkin D (2015) Molecular characterization of choroid plexus tumors reveals novel clinically relevant subgroups. *Clin Cancer Res* 21(1):184–192
52. Murata M, Morokuma S, Tsukimori K et al (2009) Rapid growing cystic variant of choroid plexus papilloma in a fetal cerebral hemisphere. *Ultrasound Obstet Gynecol* 33:116–118
53. Nejat F, Kazmi SS, Ardakani SB (2008) Congenital brain tumors in a series of seven patients. *Pediatr Neurosurg* 44:1–8
54. Newbould MJ, Kelsey AM, Arango JC et al (1995) The choroid plexus carcinomas of childhood: histopathology, immunocytochemistry, and clinicopathological correlations. *Histopathol* 28: 137–143



55. Noguchi A, Shiokawa Y, Kobayashi K et al (2004) Choroid plexus papilloma of the third ventricle in the fetus. Case illustration. *J Neurosurg* 100(2 Suppl Pediatr):224–224
56. Oi S, Kokunai T, Matsumoto S (1990) Congenital brain tumors in Japan (ISPN cooperative study): specific clinical features in neonates. *Child Nerv Syst* 6:86–91
57. Ortega Aznar A, Romero Vidal FJ, de la Torre J (2001) Neonatal tumors of the CNS: a report of 9 cases and a review. *Clin Neuropathol* 20:181–189
58. Packer RJ, Perilongo G, Johnson D et al (1992) Choroid plexus carcinoma of childhood. *Cancer* 69:580–585
59. Pascual Castroviejo I, Roche MC, Villarejo F et al (1982) Choroid plexus papillomas of the fourth ventricle. Report of 3 cases. *Childs Brain* 9:373–380
60. Pascual Castroviejo I, Villarejo F, Perez Higuera A (1983) Childhood choroid plexus neoplasms. A study of 14 cases less than 2 years old. *Eur J Pediatr* 140:51–56
61. Passariello A, Tufano M, Spennato P et al (2015) The role of chemotherapy and surgical removal in the treatment of choroid plexus carcinomas and atypical papillomas. *Child Nerv Syst* 31:1079–1088
62. Pietrini D, Chiano F, Tempara A et al (2004) Massive blood loss during removal of congenital choroid plexus tumors. *J Neurosurg Anesthesiol* 16:260–263
63. Radkowski MA, Naidich TP, Tomita T, Byrd SE, McLone DG (1988) Neonatal brain tumors: CT and MR findings. *J Comput Assist Tomogr* 12:10–20
64. Reddy D, Gunnarsson T, Scheinmann K et al (2011) Combined staged endoscopic and microsurgical approach of a third ventricular choroid plexus papilloma in an infant. *Minim Invasive Neurosurg* 54:264–267
65. Rickert CH, Paulus W (2001) Tumors of the choroid plexus. *Microsc Res Tech* 52:104–111
66. Romano F, Bratta FG, Caruso G et al (1996) Prenatal diagnosis of choroid plexus papillomas of the lateral ventricle. A report of two cases. *Prenat Diagn* 16:567–571
67. Siegfried A, Moron C, Munzer C et al (2017) A French retrospective study on clinical outcome in 102 choroid plexus tumors in children. *J Neuro-Oncol* 135:151–160
68. Stafrace S, Molloy J (2008) Extraventricular choroid plexus papilloma in a neonate. *Pediatr Radiol* 38:593–593
69. Taggard DA, Menezes AH (2000) Three choroid plexus papillomas in a patient with Aicardi syndrome. A case report. *Pediatr Neurosurg* 33:219–223
70. Thomas C, Ruland V, Kordes U, Hartung S, Capper D, Pietsch T, Gerß J, Wolff JEA, Paulus W, Hasselblatt M (2015) Pediatric atypical choroid plexus papilloma reconsidered: increased mitotic activity is prognostic only in older children. *Acta Neuropathol* 129:925–927
71. Thomas C, Sill M, Ruland V, Witten A, Hartung S, Kordes U, Jeibmann A, Beschorner R, Keyvani K, Bergmann M, Mittelbronn M, Pietsch T, Felsberg J, Monoranu CM, Varlet P, Hauser P, Olar A, Grundy RG, Wolff JE, Korshunov A, Jones DT, Bewerunge-Hudler M, Hovestadt V, von Deimling A, Pfister SM, Paulus W, Capper D, Hasselblatt M (2016) Methylation profiling of choroid plexus tumors reveals 3 clinically distinct subgroups. *Neuro-Oncology* 18(6):790–796
72. Tomita T, Naidich TP (1987) Successful resection of choroid plexus papillomas diagnosed at birth: report of two cases. *Neurosurg* 20:774–779
73. Tomita T, McLone DG, Flannery AM (1988) Choroid plexus papillomas of neonates, infants and children. *Pediatr Neurosci* 14:23–30
74. Uchiyama CM, Carey CM, Cherny WB et al (1997) Choroid plexus papilloma and cysts in the Aicardi syndrome: case reports. *Pediatr Neurosurg* 27:100–104
75. Vassallo M, Maruotti GM, Giuseppe MM et al (2012) Choroid plexus carcinoma: prenatal characterization by 3-dimensional sonography and magnetic resonance imaging, perinatal management, and natural history. *J Ultrasound Med* 31:337–339
76. Verma SK, Satyarthee GD, Shama BS (2014) Giant choroid plexus papilloma of the lateral ventricle in fetus. *J Pediatr Neurosci* 9:185–187
77. Volpe JJ (2008) Brain tumors and vein malformations. In: Volpe JJ (ed) *Neurology of the newborn*, 5th edn. WB Saunders Co, Philadelphia, pp 989–1005
78. Warren DT, Henderson G, Cochrane DD (2009) Bilateral choroid plexus hyperplasia: a case report and management strategies. *Child Nerv Syst* 25:1617–1622
79. Welch K, Strand R, Bresnan M (1983) Congenital hydrocephalus due to villous hypertrophy of the telencephalic choroid plexuses. Case report. *J Neurosurg* 59:172–175
80. Wind J, Bell RS, Bank WO et al (2010) Treatment of third ventricular choroid plexus papilloma in an infant with embolization alone. *J Neurosurg Pediatr* 6:579–582
81. Wolff JE, Sajedi M, Brant R et al (2002) Choroid plexus tumors. *Br J Cancer* 87:1086–1091
82. Wrede B, Liu P, Wolff JE (2007) Chemotherapy improves the survival of patients with choroid plexus carcinoma: a meta-analysis of individual cases with choroid plexus tumors. *J Neuro-Oncol* 85(3):345–351
83. Wrede B, Hasselblatt M, Peters O, Thall PF, Kutluk T, Moghrabi A, Mahajan A, Rutkowski S, Diez B, Wang X, Pietsch T, Kortmann RD, Paulus W, Jeibmann A, Wolff JEA (2009) Atypical choroid plexus papilloma: clinical experience in the CPT-SIOP-2000 study. *J Neuro-Oncol* 95(3):383–392
84. Zaky W, Finlay JL (2018) Pediatric choroid plexus carcinoma: biologically and clinically in need of new perspectives. *Pediatr Blood Cancer* 65(7):e27031
85. Zaky W, Dhall G, Khatua S, Brown RJ, Ginn KF, Gardner SL, Yildiz VO, Yankelevich M, Finlay JL (2015) Choroid plexus carcinoma in children: the Head Start experience. *Pediatr Blood Cancer* 62(5):784–789

**Publisher's note** Springer Nature remains neutral with regard to jurisdictional claims in published maps and institutional affiliations.