

UCSF

UC San Francisco Previously Published Works

Title

Acute liver injury in a Glatopa-treated patient with MS

Permalink

<https://escholarship.org/uc/item/0tv1t24s>

Journal

Neurology Neuroimmunology & Neuroinflammation, 4(4)

ISSN

2332-7812

Authors

Sabatino, Joseph J
Mehta, Neil J
Kakar, Sanjay
et al.

Publication Date

2017-07-01

DOI

10.1212/nxi.0000000000000368

Peer reviewed

Joseph J. Sabatino, Jr.,
MD, PhD
Neil J. Mehta, MD
Sanjay Kakar, MD
Scott S. Zamvil, MD,
PhD
Bruce A.C. Cree, MD,
PhD, MAS

*Neurol Neuroimmunol
Neuroinflamm*
2017;4:e368; doi: 10.1212/
NXL.0000000000000368

ACUTE LIVER INJURY IN A GLATOPA-TREATED PATIENT WITH MS

OPEN

Hepatotoxicity is rarely associated with glatiramer acetate (GA) treatment of relapsing MS. Here, we report a case of acute liver injury associated with generic GA (Glatopa, manufactured by Sandoz, a Novartis company, Holzkirchen, Upper Bavaria, Germany).

Case report. A 36-year-old woman presented with unilateral optic neuritis from which she recovered. Optic neuritis recurred at age 42. Brain MRI showed multiple T2-hyperintense white matter lesions and a gadolinium–diethylenetriamine penta-acetic acid–enhancing lesion. MS was diagnosed. The patient was treated with methylprednisolone 1 g/daily IV for 5 days. Concomitant medications included norethindrone/ethinyl estradiol with iron, vitamin D, calcium, and vitamin B12. The patient did not take supplements or abuse alcohol. Approximately 3 weeks later, the patient was started on generic GA. Influenza and meningococcal oligosaccharide vaccines were administered at the time she began GA.

Because of symptoms of injection pain, fatigue, nausea, and constipation, the patient discontinued GA after 13 daily injections. The following day, the patient developed worsening nausea with vomiting, dyspnea with exertion, anorexia, fatigue, dark urine, and jaundice. The patient was found to have elevated liver function tests (aspartate aminotransferase = 1,188 U/L, alanine transaminase = 1,879 U/L, alkaline phosphatase = 177 U/L, and total bilirubin = 3.6 mg/dL) compared with normal values just 1 month prior (figure, A). The following laboratory values were negative or normal: HAV IgM, HBsAg, HBcAg IgG, HCV RNA, HCV antibody, HEV IgM, EBV IgM, CMV IgM, HIV, HSV PCR, urine toxicology screen, acetaminophen levels, ANA, and anti-smooth muscle antibody. HAV IgG, HBsAb, HEV IgG, and EBV IgG were positive. Twenty-four-hour urine copper (193 μ g/24 h [normal range 15–60 μ g/24 h]) was presumed to be elevated secondary to acute liver injury.

A liver biopsy showed severe portal, interface and panacinar, lymphocyte-predominant inflammation, with confluent necrosis, numerous apoptotic hepatocytes, and

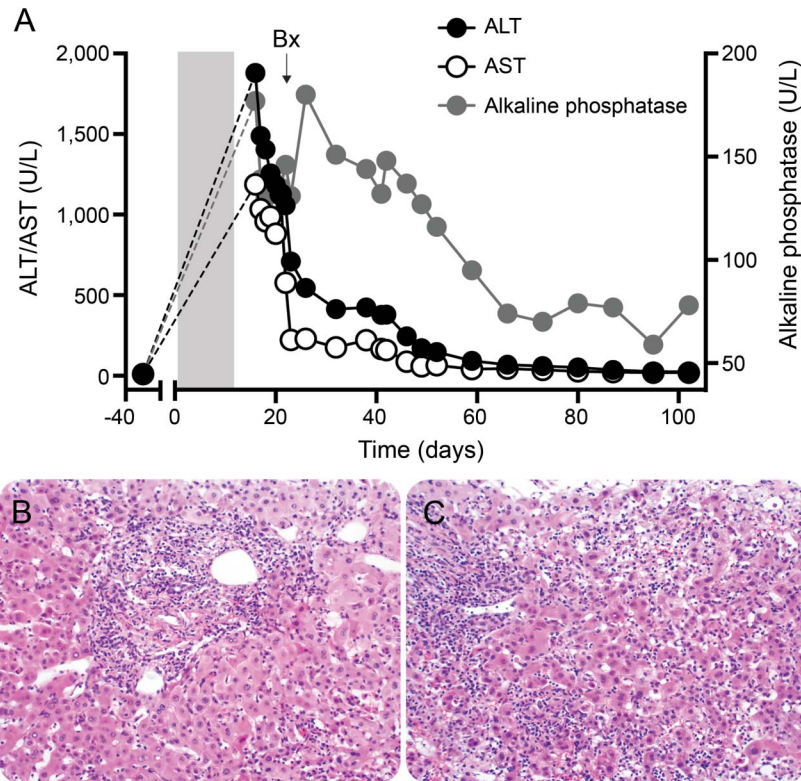
central perivenulitis (figure, B and C). The bile ducts were intact, and there was no significant ductular reaction. Steatosis, cholestasis, and fibrosis were not present. The patient was treated with IV corticosteroids followed by a several month taper of prednisone for possible autoimmune hepatitis. The patient's liver function tests normalized within 2 months.

Discussion. GA is a synthetic random copolymer of 4 amino acids (glutamic acid, lysine, alanine, and tyrosine) approved for treatment of relapsing-remitting MS. With more than 2,000,000 patient-years of exposure to GA, there are 13 published cases of hepatotoxicity (table e-1 at Neurology.org/nn). Previously reported cases are notable for prior treatment with interferon β , concomitant use of other potentially hepatotoxic drugs, and symptom onset 1–8 months after initiating GA. We report a rare case of acute liver injury in the setting of generic GA use. Liver injury associated with GA presents with a hepatocellular injury pattern without hyperglobulinemia, although autoimmune hepatitis can occur (Supplemental Table). Given our patient's negative autoimmune markers, lack of plasma cells on biopsy, and resolution of liver injury on a rapid prednisone taper, it is unlikely that this patient had autoimmune hepatitis. The administration of influenza and meningococcal vaccines seems unlikely to be contributory because neither vaccine is hepatotoxic. Seven years prior to the diagnosis of MS, our patient had a history of transaminitis, which was attributed to a viral etiology (associated with serologic evidence of prior hepatitis A and hepatitis E virus exposure), followed by many years of normal liver enzymes.

GA is classified as a nonbiological complex drug (NBCD) whose composition and in vivo activity are highly dependent on manufacturing processes.^{1,2} Systemic toxicities are extremely rare with GA, and there are no guidelines for drug safety monitoring. In prior clinical trials of Copaxone and generic GA, the incidence of liver dysfunction was equivalent to that of placebo-treated patients.³ Since approval, over 300 cases of Copaxone-associated liver-related abnormalities were reported to the United States Food and Drug Administration (US-FDA). In animal studies, transaminase elevations were observed with chronic high-dose GA.

Supplemental data
at Neurology.org/nn

Figure Liver injury after glatiramer acetate treatment



Liver function tests (panel A) were performed from February 17, 2016 (32 days prior to glatiramer acetate [GA]) to June 13, 2016 (102 days following the start of GA treatment). The gray rectangle represents the 13 days of GA treatment starting at day 0. Alanine transaminase (ALT) (normal range 10–30 U/L) and aspartate aminotransferase (AST) (normal range 6–29 U/L) are depicted on the left y-axis and alkaline phosphatase (alk phos [normal range 33–115 U/L]) on the right y-axis. Liver biopsy (indicated by “Bx” on panel A) on day 20 shows dense portal lymphocytic inflammation (panel B) with interface activity and normal bile ducts and shows lobular lymphocytic inflammation with confluent necrosis (panel C) (hematoxylin and eosin stain, 200 \times). This histologic picture along with the clinical presentation and temporal profile is consistent with drug-induced liver injury.

Significant hepatotoxicity, nephropathy, and skin reactions also occurred with protiramer (TV-5010), a glatiramoid with a higher molecular weight of the same molar ratio of amino acids as GA.⁴

Glatopa was approved as a GA biosimilar compound in 2015 without a requirement for proof of either efficacy or safety in clinical trials. Sandoz demonstrated Glatopa’s equivalence with Copaxone by similarities in chemistry, polymerization, biological, and immunologic properties.^{5,6} In a study by the US-FDA using 3 different analytic measures, distinct physicochemical differences were found between Copaxone and commercially available copolymer-1.⁷ Teva Pharmaceuticals also found differences in charge distribution, molecular density, monomolecular size, and the existence of a novel polypeptide group in Glatopa compared with Copaxone.² Therefore, differences in manufacturing between these NBCDs could cause different adverse event profiles. Given that generic GA is only recently available for clinical use in MS and is the likely cause of acute liver injury in the present case report, heightened awareness of

possible liver dysfunction and other adverse effects may be warranted.

From the Multiple Sclerosis Center (J.J.S., S.S.Z., B.A.C.C.), Department of Neurology, Division of Gastroenterology (N.J.M.), Department of Medicine, and GI-Hepatobiliary Pathology Service (S.K.), Department of Pathology, University of California San Francisco.

Author contributions: Dr. Sabatino contributed to interpretation of the data and drafting and revision of the manuscript. Dr. Mehta and Dr. Kakar contributed to interpretation of the data and revision of the manuscript. Dr. Zamvil and Dr. Cree contributed to interpretation of the data and drafting and revision of the manuscript.

Acknowledgment: The authors are grateful for Collin Spencer’s help in preparing the figure.

Study funding: No targeted funding reported.

Disclosure: J.J. Sabatino received research support from R25 NS00680, NMSS. N.J. Mehta reports no disclosures. S. Kakar received publishing royalties from Elsevier and Springer Publishing. S.S. Zamvil served on the data safety monitoring board for BioMS, Teva Pharmaceuticals, Eli Lilly and Com; is a member of the clinical advisory board for Myelin Repair Foundation; is deputy editor for Neurology® Neuroimmunology & Neuroinflammation; has a patent pending for Aquaporin-4 peptides and methods for using the same; has consulted for Biogen, Teva, EMD Serono, Genzyme, Novartis, and Roche; received research support from

Biogen, Teva, NIH, NMSS, and Alexander M. and June L. Maxisin Foundation. B.A.C. Cree consulted for AbbVie, Biogen, EMD Serono, Novartis, Sanofi Genzyme, Shire and received research support from Acorda, Celgene, Hoffman La Roche, MedImmune, Novartis, and Teva. Go to Neurology.org/nn for full disclosure forms. The Article Processing Charge was funded by the authors.

This is an open access article distributed under the terms of the Creative Commons Attribution-NonCommercial-NoDerivatives License 4.0 (CC BY-NC-ND), which permits downloading and sharing the work provided it is properly cited. The work cannot be changed in any way or used commercially without permission from the journal.

Received March 21, 2017. Accepted in final form May 1, 2017.

Correspondence to Dr. Cree: bruce.cree@ucsf.edu

1. Cohen J, Belova A, Selmaj K, et al. Equivalence of generic glatiramer acetate in multiple sclerosis: a randomized clinical trial. *JAMA Neurol* 2015;72:1433–1441.
2. Levin PS. Docket No. FDA-2007-D-0369; Product-Specific Bioequivalence Recommendations; Draft and Revised Draft Guidances for Industry; Comments of Teva Pharmaceuticals Industries Ltd. to the Draft Bioequivalence
3. Carter NJ, Keating GM. Glatiramer acetate. A review of its use in relapsing-remitting multiple sclerosis and in delaying the onset of clinically definite multiple sclerosis. *Drugs* 2010;70:1545–1577.
4. Ramot Y, Rosenstock M, Klinger E, Bursztyn D, Nyska A, Shinar D. Comparative long-term preclinical safety evaluation of two glatiramoid compounds (glatiramer acetate, Copaxone, and TV-5010, protiramer) in rats and monkeys. *Toxicol Pathol* 2012;40:40–54.
5. Anderson J, Bell C, Bishop J, et al. Demonstration of equivalence of a generic glatiramer acetate (Glatopa). *J Neurol Sci* 2015;359:24–34.
6. D'Alessandro JS, Duffner J, Pradines J, et al. Equivalent gene expression profiles between Glatopa and Copaxone. *PLoS One* 2015;10:1–19.
7. Rogstad S, Pang E, Sommers C, et al. Modern analytics for synthetically derived complex drug substances: NMR, AFFF-MALS, and MS tests for glatiramer acetate. *Anal Bioanal Chem* 2015;407:8647–8659.

Guidance for Glatiramer Acetate Injection. Available at: regulations.gov/document?D=FDA-2007-D-0369-0395. Accessed December 6, 2016.