

**UCLA**

**UCLA Previously Published Works**

**Title**

Epilepsy and Electroencephalographic Abnormalities in SATB2-Associated Syndrome.

**Permalink**

<https://escholarship.org/uc/item/0v29s4qk>

**Authors**

Lewis, Hannah  
Samanta, Debopam  
Örsell, Jenny-Li  
et al.

**Publication Date**

2020-11-01

**DOI**

10.1016/j.pediatrneurol.2020.04.006

Peer reviewed



Published in final edited form as:

*Pediatr Neurol.* 2020 November ; 112: 94–100. doi:10.1016/j.pediatrneurol.2020.04.006.

## Epilepsy and Electroencephalographic Abnormalities in *SATB2*-Associated Syndrome

Hannah Lewis, BA<sup>a</sup>, Debopam Samanta, MD<sup>b</sup>, Jenny-Li Örsell, MS<sup>c</sup>, Katherine A. Bosanko, MS<sup>d</sup>, Amy Rowell, MD<sup>e</sup>, Melissa Jones, MD<sup>f</sup>, Russell C. Dale, MD<sup>g</sup>, Sasidharan Taravath, MD<sup>h</sup>, Cecil D. Hahn, MD, MPH<sup>i</sup>, Deepa Krishnakumar, MD<sup>j</sup>, Sarah Chagnon, MD<sup>k</sup>, Stephanie Keller, MD<sup>l</sup>, Eveline Hagebeuk, MD, PhD<sup>m</sup>, Sheel Pathak, MDE<sup>n</sup>, E. Martina Bebin, MD, MPA<sup>o</sup>, Daniel H. Arndt, MD<sup>p</sup>, John J. Alexander, MD<sup>q</sup>, Gayatra Mainali, MBBS<sup>r</sup>, Giangennaro Coppola, MD<sup>s</sup>, Jane Maclean, MD<sup>t</sup>, Steven Sparagana, MD<sup>u</sup>, Nancy McNamara, MD<sup>v</sup>, Douglas M. Smith, MD<sup>w</sup>, Víctor Raggio, MD<sup>x</sup>, Marcos Cruz, MD<sup>y</sup>, Alberto Fernández-Jaén, MD, PhD, MS<sup>z</sup>, Maina P. Kava, MD<sup>aa,bb</sup>, Lisa Emrick, MD<sup>cc</sup>, Jennifer L. Fish, PhD<sup>dd</sup>, Adeline Vanderver, MD<sup>ee,ff</sup>, Guy Helman, BS<sup>gg,hh</sup>, Tyler M. Pierson, MD, PhD<sup>ii</sup>, Yuri A. Zarate, MD, MBA<sup>d,\*</sup>

<sup>a</sup>University of Arkansas for Medical Sciences School of Medicine, Little Rock, Arkansas

<sup>b</sup>Section of Child Neurology, Department of Pediatrics, University of Arkansas for Medical Sciences, Little Rock, Arkansas

<sup>c</sup>Division of Psychology, Department of Clinical Neuroscience, Karolinska Institutet, Stockholm, Sweden

<sup>d</sup>Section of Genetics and Metabolism, Department of Pediatrics, University of Arkansas for Medical Sciences, Little Rock, Arkansas

<sup>e</sup>Department of Radiology, University of Arkansas for Medical Sciences, Little Rock, Arkansas

<sup>f</sup>Houston Area Pediatric Neurology, Houston, Texas

<sup>g</sup>Kids Neuroscience Centre, Children's Hospital at Westmead, Faculty of Medicine and Health, University of Sydney, Australia

<sup>h</sup>Department of Pediatric Neurology, Coastal Childrens service, Wilmington, North Carolina

<sup>i</sup>Division of Neurology, Department of Paediatrics, The Hospital for Sick Children and University of Toronto, Toronto, Canada

<sup>j</sup>Department of Paediatric Neurology, Addenbrooke's Hospital, Cambridge, UK

<sup>k</sup>Division of Child and Adolescent Neurology, Children's Hospital of the Kings Daughters, Norfolk, Virginia

<sup>l</sup>Division of Pediatric Neurology, Department of Pediatrics, Emory University, Atlanta, Georgia

<sup>m</sup>Stichting Epilepsie Instellingen Nederland (SEIN) Zwolle, the Netherlands

\*Communications should be addressed to: Zarate; Arkansas Children's Hospital 1 Children's Way; Slot 512-22; Little Rock, AR 72202. yazarate@uams.edu (Y.A. Zarate).

Conflicts of interest: None of the authors have any conflicts of interest to disclose related to this work.

<sup>n</sup>Division of Pediatric and Developmental Neurology, Department of Neurology, Washington University School of Medicine, St. Louis, Missouri

<sup>o</sup>Department of Neurology, University of Alabama at Birmingham, Birmingham, Alabama

<sup>p</sup>Division of Pediatric Neurology, Department of Pediatrics, Beaumont Children's, Oakland University William Beaumont School of Medicine, Royal Oak, Michigan

<sup>q</sup>Division of Neurology, Seattle Children's Hospital, Seattle, Washington

<sup>r</sup>Division of Pediatric Neurology, Penn State College of Medicine, Hershey, Pennsylvania

<sup>s</sup>Department of Medicine, Surgery and Dentistry, Child and Adolescent Neuropsychiatry, University of Salerno, Italy

<sup>t</sup>Pediatric Neurology, Palo Alto medical foundation, San Jose, California

<sup>u</sup>Department of Neurology, Texas Scottish Rite Hospital for Children and University of Texas Southwestern Medical Center, Dallas, Texas

<sup>v</sup>Division of Child Neurology, Department of Pediatrics, Mott Children's Hospital, University of Michigan, Ann Arbor, Michigan

<sup>w</sup>Minnesota Epilepsy Group, Saint Paul, Minnesota

<sup>x</sup>Departamento de Genética, Facultad de Medicina, Udelar, Uruguay

<sup>y</sup>HighPoint Neurology Associates, Hendersonville, Tennessee

<sup>z</sup>Department of Pediatric Neurology, Hospital Universitario Quirónsalud and Universidad Europea de Madrid, Madrid, Spain

<sup>aa</sup>Department of Neurology, Perth Children's Hospital, Western Australia, Australia

<sup>bb</sup>School of Paediatrics and Child Health, University of Western Australia, Australia

<sup>cc</sup>Department of Pediatrics, Section of Neurology and Developmental Neuroscience, and Department of Molecular and Human Genetics, Baylor College of Medicine, Texas Children's Hospital, Houston, Texas

<sup>dd</sup>Department of Biological Sciences, University of Massachusetts Lowell, Lowell, Massachusetts

<sup>ee</sup>Division of Neurology, Children's Hospital of Philadelphia, Philadelphia, Pennsylvania

<sup>ff</sup>Department of Neurology, Perelman School of Medicine, University of Pennsylvania, Philadelphia, Pennsylvania

<sup>gg</sup>Murdoch Children's Research Institute, The Royal Children's Hospital, Victoria, Australia

<sup>hh</sup>Institute for Molecular Bioscience, The University of Queensland, Queensland, Australia

<sup>ii</sup>Departments of Pediatrics and Neurology & The Board of Governors Regenerative Medicine Institute, Cedars Sinai Medical Center, Los Angeles, California

## Abstract

**Background:** Seizures are an under-reported feature of the *SATB2*-associated syndrome phenotype. We describe the electroencephalographic findings and seizure semiology and treatment in a population of individuals with *SATB2*-associated syndrome.

**Methods:** We performed a retrospective review of 101 individuals with *SATB2*-associated syndrome who were reported to have had a previous electroencephalographic study to identify those who had at least one reported abnormal result. For completeness, a supplemental survey was distributed to the caregivers and input from the treating neurologist was obtained whenever possible.

**Results:** Forty-one subjects were identified as having at least one prior abnormal electroencephalography. Thirty-eight individuals (93%) had epileptiform discharges, 28 (74%) with central localization. Sleep stages were included as part of the electroencephalographies performed in 31 individuals (76%), and epileptiform activity was recorded during sleep in all instances (100%). Definite clinical seizures were diagnosed in 17 individuals (42%) with a mean age of onset of 3.2 years (four months to six years), and focal seizures were the most common type of seizure observed (42%). Six subjects with definite clinical seizures needed polytherapy (35%). Delayed myelination and/or abnormal white matter hyperintensities were seen on neuroimaging in 19 individuals (61%).

**Conclusions:** Epileptiform abnormalities are commonly seen in individuals with *SATB2*-associated syndrome. A baseline electroencephalography that preferably includes sleep stages is recommended during the initial evaluation of all individuals with *SATB2*-associated syndrome, regardless of clinical suspicion of epilepsy.

## Keywords

Glass syndrome; SATB2; Epilepsy; Electroencephalography; Seizure semiology

---

## Introduction

*SATB2*-associated syndrome (SAS, Glass syndrome) is an auto-somal dominant disorder characterized by neurodevelopmental delay with severe speech delay, palate and dental abnormalities, behavioral issues, sleeping difficulties, and abnormal neuroimaging.<sup>1-3</sup> The syndrome is caused by molecular alterations of *SATB2* (special AT-rich sequence-binding protein 2) including single-nucleotide variants, intragenic deletions and duplications, contiguous gene deletions, and translocations with secondary gene disruption.<sup>2,4</sup> *SATB2* is an important epigenetic regulator during neurodevelopment. *SATB2* acts as a transcription factor that regulates chromatin remodeling and as a modulator of numerous micro RNAs during and after corticogenesis.<sup>5-8</sup>

*SATB2* has recently been added to the list of epilepsy-related genes,<sup>9</sup> but the underlying mechanism is far from clear. Although clinical seizures have been reported in several individuals with SAS and with an estimated prevalence of approximately 20%, electroencephalographic (EEG) abnormalities are thought to be more prevalent than clinically suggested.<sup>1-3,10-12</sup>

To date, the electroclinical patterns and seizure treatment and outcome in SAS have been infrequently and inconsistently described. We aim to describe the seizure history and EEG abnormalities in a large cohort of individuals with SAS.

## Methods

### Subjects

This study was approved by the Institutional Review Board of the University of Arkansas for Medical Sciences. All participants and/or their guardians provided consent to participate. Participants were part of an SAS registry of genetically confirmed subjects from all over the world. These individuals were referred to this registry from a treating physician, an inquiry from a genetic testing laboratory, direct contact from a caregiver, or through the SAS support group. Individuals who were reported to have undergone EEG studies with or without documented clinical seizures were then selected for further review, and only those with an available EEG report were included in the study. For all included subjects, a retrospective chart review was completed. For completeness, a survey (using REDCap) about seizures and EEG results was sent to their guardian, and if available and willing to participate, their primary neurologist was contacted to clarify points of confusion.

### Electroencephalography and neuroimaging interpretation

Data from routine (under two hours) and long-term (over two hours) 21-channel EEG studies were included and recorded in the awake, drowsy, or sleep states. Procedures were performed at Arkansas Children's Hospital or other local institutions. All reports were reviewed with a single board-certified pediatric neurophysiologist (D.M.S.). Whenever possible, brain magnetic resonance (MRI) studies were also reviewed by select examiners (A.V, G.H., and A.R.).

### Molecular studies

Except for six individuals, the remaining participants were included in previous publications detailing their clinical and genetic investigations.<sup>2,10</sup> Individual SATB2-143 underwent molecular cytogenetic studies using whole-genome single-nucleotide polymorphism array (Affymetrix, Santa Clara, CA, USA). Individuals SATB2-153, SATB2-159, SATB2-164, and SATB2-1093 underwent whole-exome sequencing, whereas individual SATB2-11184 had whole-genome sequencing performed. Underlying molecular alterations were grouped as follows: large chromosomal deletions (2q33.1 deletions encompassing *SATB2* and other contiguous genes), truncating pathogenic variants (predicted nonsense and frameshift), missense variants, intragenic deletions, and canonical splice site variants.

## Results

Clinical records were reviewed from 101 individuals with confirmed SAS (age three months to 34 years) who had an EEG performed (54 reported as abnormal and 47 as normal per parental report). Of these, EEG reports from 51 subjects were available for review (10 normal and 41 abnormal). Our study population consisted of 41 individuals with abnormal

EEGs, who subsequently had their medical information and electroencephalographic data evaluated in more detail (Table 1).

### Neurodevelopment

Developmental delay and/or intellectual disability was present in all individuals. Many of these subjects also had documented behavioral problems such as attention-deficit/hyperactivity disorder and autism spectrum disorder (71%) as well as hypotonia (71%).

### MRI findings

Thirty-one individuals (75.6%) had neuroimaging studies available for review. Of these, abnormalities were reported in 21 (67.7%), most commonly as delayed myelination (61.9%) or abnormal white matter hyperintensities (T2/fluid-attenuated inversion recovery, 47.6%).

### Electroencephalographic findings

A total of 66 EEG studies were reviewed (1.6/individual) that were performed at an average age of 5.2 years (one to 12 years). Thirty-eight studies were routine short-term studies, and 28 were long-term continuous EEGs. In the 18 subjects who had multiple EEG reports, 14 subjects had abnormal findings on their first EEG (77.8%).

Thirty-eight subjects (92.7%) had epileptiform discharges, with 34 subjects having focal abnormalities (central spike or spike waves) that localized to central locations (73.7%), whereas four subjects (10.5%) had generalized (widespread) activity (Table 2). Of note, no clinical seizures were noted during the EEG recordings, although one subject had four subclinical seizures. Two additional individuals had potential seizures with one having possible subtle spasms (electrodecrements without definite clinical accompaniment) and another having gelastic episodes that displayed no EEG changes.

### Seizure semiology, epilepsy diagnoses, and nonepileptic events

Because no clinical seizures were captured on EEG studies, the diagnosis of epilepsy was determined by the treating physician using clinical information along with support from the abnormal findings on EEG.

In all, 17 of 41 (41.5%) individuals with abnormal EEGs had verified clinical seizures with a mean age of onset of 3.2 years (four months to six years) and with predominantly focal (partial) epilepsy with or without bilateral tonic-clonic seizures (41.2%). Individual SATB2-68, who has also carried a maternal inherited and likely pathogenic variant in *CACNA1H* (p.His515Tyr), was diagnosed with intractable infantile spasms and subsequently Lennox-Gastaut syndrome. Ten additional individuals had episodes that were labeled as possible seizures (staring spells, laughing fits, disorientation episodes). Other nonepileptic described events based on EEG or semiology included laughing or crying episodes and limb jerks. The presence of brain MRI abnormalities (28.6% individuals with abnormal brain MRI had clinical seizures versus 50% individuals with normal brain MRI,  $P = 0.42$ ) or type of mutation (53.3% of individuals with missense mutations had clinical seizures versus 34.6% of individuals with other genetic alterations,  $P = 0.33$ ) did not correlate with the diagnosis of clinical seizures.

## Sleep

There was considerable activation of epileptiform activity during sleep, most commonly represented as central spikes or central spike waves. When included as part of the EEGs performed, epileptiform activity was recorded during sleep in all instances (31 of 31 = 100%). Of these, 25 subjects (80.6%) had an increase in epileptiform activity and/or spread of that activity to other areas during drowsiness or sleep. Four individuals met (two subjects) or approached (two subjects) the limit for the diagnosis of electrical status epilepticus in sleep (ESES) based on their EEG reports. Of the subjects with epileptiform activity during sleep, 18 (58.1%) had subjective sleeping difficulties.

## Treatment

Twenty-nine subjects (70.7%) tried at least one antiepileptic medication (including three individuals on cannabidiol [CBD] or CBD oil). Of these, 10 subjects required three or more medications (Table 2, Fig). Other individuals without clinical seizures were started on antiepileptic medications based on clinical judgment of the treating neurologist for parental report of nonepileptic events with or without sleep disruption and considering EEG findings.

Overall, levetiracetam was the most commonly tried medication (15 individuals); however, overall it was not well-tolerated and only two subjects currently use it. The most common reasons for discontinuing levetiracetam included aggression, constipation, hallucinations, and rash. Oxcarbazepine, valproate, lamotrigine, and clobazam were the next most commonly tried medications (eight, eight, six, and five subjects, respectively) and were all well-tolerated with seven of eight, five of eight, five of six, and four of five still taking the medications currently.

Some individuals in this cohort also tried nonpharmacologic and/or herbal treatments. Three subjects tried artisanal CBD: one discontinued it, whereas two subjects continue to use it as monotherapy (although neither had a clinical diagnosis of epilepsy). Two other individuals tried a ketogenic diet, but both discontinued. One individual (SATB2–68) is subjectively well controlled currently after a vagus nerve stimulator placement and continued antiepileptic medications; however, objective EEG evaluations revealed electrodecrements without clinical accompaniment that could represent subclinical/electrographic epileptic spasms until age 4.5 years.

## Discussion

The neurodevelopmental, behavioral, skeletal, and craniofacial features of SAS have been previously well described.<sup>1,2,10,13</sup> The presence of epilepsy has been estimated at around 20% in SAS,<sup>2</sup> whereas in this report, we documented that electroencephalographic abnormalities are at least twice as common (41 of 101 individuals who reportedly underwent an EEG examination were confirmed to have abnormalities). In our cohort, epileptiform abnormalities were seen in at least 37.6% individuals undergoing EEG (38 of 101), but only 16.8% had clinical seizures (17 of 101).

Nearly half of the individuals with SAS in the five to 15 years age range have at least one type of sleep disorder, with younger individuals having more problems.<sup>14</sup> In this study, we

report that all individuals with abnormal EEG studies had activation of their EEGs during sleep stages with an increased frequency of epileptiform discharges and/or enlargement of the affected area during drowsiness or sleep. This includes four individuals who met or were close to meeting the requirements for ESES. The activation of epileptiform activity during sleep manifested in several different ways including sleep-activated seizures and poor sleep. It also suggests that SAS should be considered in the differential diagnosis of individuals being diagnosed with an epileptic encephalopathy of sleep.

White matter signal abnormalities are sometimes reported as an incidental finding in healthy children (1.9%). Among our cohort with abnormal EEG findings, a number of individuals presented with delayed myelination and/or abnormal white matter hyperintensities on neuroimaging. We documented a statistically significant higher frequency of white matter signal abnormalities in the group of individuals with abnormal EEGs who underwent neuroimaging (1.9% vs 32.3%,  $P = 0.0001$ ),<sup>15</sup> whereas we were unable to document a relationship between abnormal neuroimaging and the presence of clinical seizures. Further investigation will be required to determine a possible relationship between epilepsy, neuroinflammation, and white matter abnormalities in SAS.

Intriguingly, *Satb2*-deficient mice display reduced neuronal excitability, decreased excitatory synaptic inputs in CA1, and increased resistance to seizures.<sup>16</sup> This finding mirrors those of similar studies showing impaired long-term potentiation and memory,<sup>7,17</sup> whereas it is in marked contrast to our findings of reported epileptogenic tendencies in SAS suggesting that environmental or other factors could explain the discrepancy.

Individuals with SAS have a large spectrum of epilepsy diagnoses, with the most common being focal epilepsy. A variety of antiepileptic medications were used in this population. Although levetiracetam was the most likely to be used, it was one of the least tolerated agents mostly due to well-known behavioral side effects. The three medications that were well-tolerated and had the most patients with verified clinical seizures in the “well-controlled” category were oxcarbazepine, lamotrigine, and clobazam. At this point, we do not have convincing data to recommend one of these medications over another and the personal behavioral profile of a patient with SAS should be taken into consideration upon choosing a treatment strategy. Two individuals were currently being managed with artisanal CBD oil as monotherapy (neither diagnosed with seizures clinically). Of note, the endocannabinoid system, via the cannabinoid CB1 receptor has been shown to exert a regulatory role in corticogenesis and deep-layer neuron specification through the regulation of *Ctip2-Satb2* balance.<sup>18,19</sup>

There are several limitations to this study. The use of an online survey with data entered by caregivers may raise concerns over the validity of the data. To reduce errors in the data, medical records for all individuals were also reviewed and the opinion of the treating neurologist was collected whenever possible. Clinical presentations and seizure semiology (even after receiving clarification from the neurologists) were difficult to determine if they were epileptic in nature, which accounts for our considerable percentage from the possible/likely seizure group. With the main purpose of the study being to describe the seizure semiology, medical management, and the electrographic pattern of abnormalities in SAS,



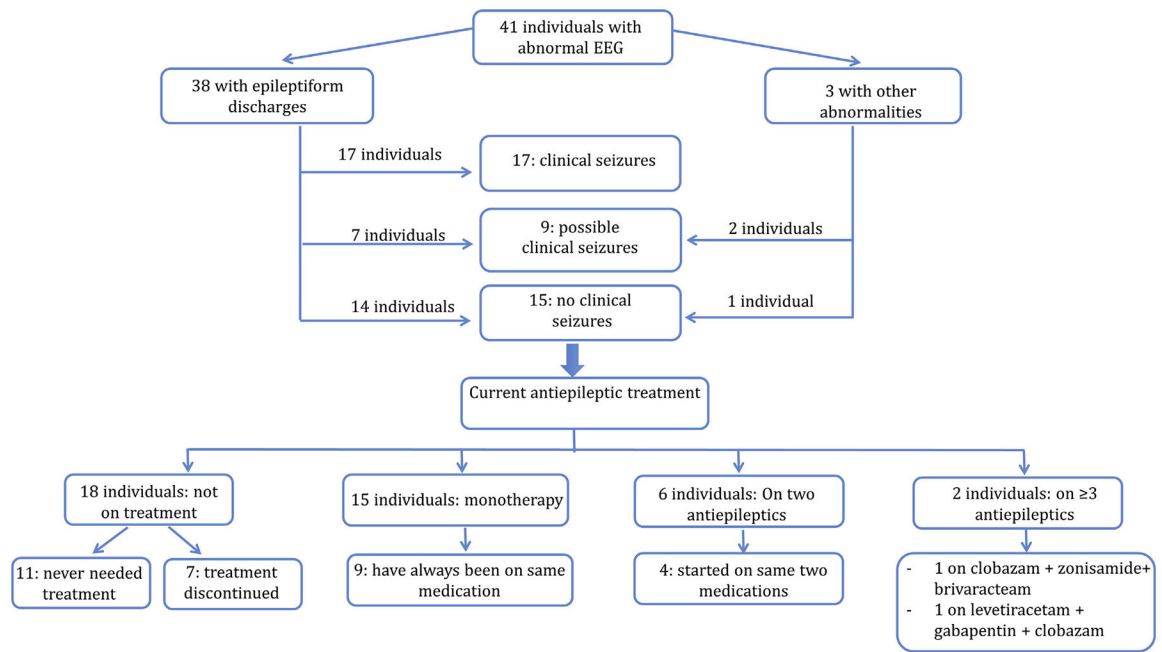
we concentrated on the population with confirmed abnormal prior EEG. Therefore, because we were unable to obtain all EEG reports regardless of the results to confirm parental reports, we cannot determine clear genotype/phenotype correlations that could result in higher epileptogenic risk or accurate frequency of clinical seizures/EEG abnormalities in SAS. Likewise, the clinical indication for the clinician to order the EEG was unknown in most cases, making the calculation of the rate of abnormalities even more difficult. Last, most individuals were diagnosed through comprehensive genetic evaluations, whereas other genomic alterations that could influence the phenotype were not systematically evaluated, and for at least one individual (SATB2–68), a concurrent mutation in a separate gene (*CACNA1H*) could explain his more severe phenotype. Despite these limitations, our results provide a more detailed outline of the electroclinical patterns and seizure management in SAS. Larger cohorts of individuals with SAS and epilepsy are crucial to develop a clearer understanding of epilepsy and EEG abnormalities in this population. Furthermore, future studies could also investigate which treatments for epilepsy are most effective for subjects with SAS while a better understanding of the pathophysiology underlying epilepsy in SAS could lead to individualized therapeutic strategies.

In summary, SAS should be part of the differential diagnosis for any child who presents with developmental delay and seizures, particularly in the presence of other suggestive craniofacial or dental features. Although current management recommendations for SAS suggest to obtain an EEG only if seizures are suspected,<sup>3,4</sup> considering the relatively high frequency of EEG abnormalities, we recommend that an EEG should be performed during initial evaluation in all individuals with SAS (abnormalities reported as early as infancy) and preferably including sleep stages due to the risk of generalized patterns with or without witnessed seizures and the small risk for ESES, which may remain undetected without EEG evaluation. Early detection of abnormal epileptiform activity on EEG during sleep or awake stages could help initiate further long-term EEG monitoring, characterize spells as epileptiform or non-epileptiform, and institute prompt treatment against subclinical seizures and ESES, which may limit cognitive and developmental deterioration in SAS individuals.

## References

1. Bengani H, Handley M, Alvi M, et al. Clinical and molecular consequences of disease-associated de novo mutations in SATB2. *Genet Med*. 2017;19:900–908. [PubMed: 28151491]
2. Zarate YA, Bosanko KA, Caffrey AR, et al. Mutation update for the SATB2 gene. *Hum Mutat*. 2019;40:1013–1029. [PubMed: 31021519]
3. Zarate YA, Fish JL. SATB2-associated syndrome: mechanisms, phenotype, and practical recommendations. *Am J Med Genet A*. 2017;173:327–337. [PubMed: 27774744]
4. Zarate YA, Kaylor J, Fish J. SATB2-associated syndrome. In: Adam MP, Ardinger HH, Pagon RA, et al., eds. *GeneReviews(R)*. 1993. Seattle (WA).
5. Acuna-Hidalgo R, Bo T, Kwint MP, et al. Post-zygotic point mutations are an underrecognized source of de novo genomic variation. *Am J Hum Genet*. 2015;97:67–74. [PubMed: 26054435]
6. Gyorgy AB, Szemes M, de Juan Romero C, Tarabykin V, Agoston DV. SATB2 interacts with chromatin-remodeling molecules in differentiating cortical neurons. *Eur J Neurosci*. 2008;27:865–873. [PubMed: 18333962]
7. Jaitner C, Reddy C, Abentung A, et al. Satb2 determines miRNA expression and long-term memory in the adult central nervous system. *Elife*. 2016;5.

8. Leone DP, Srinivasan K, Chen B, Alcamo E, McConnell SK. The determination of projection neuron identity in the developing cerebral cortex. *Curr Opin Neurobiol.* 2008;18:28–35. [PubMed: 18508260]
9. Roctus A, Olson HE, Smith L, et al. Genetic diagnoses in epilepsy: the impact of dynamic exome analysis in a pediatric cohort. *Epilepsia.* 2020;61: 249–258. [PubMed: 31957018]
10. Zarate YA, Smith-Hicks CL, Greene C, et al. Natural history and genotype-phenotype correlations in 72 individuals with SATB2-associated syndrome. *Am J Med Genet Part A.* 2018;176:925–935. [PubMed: 29436146]
11. Zarate YA, Kalsner L, Basinger A, et al. Genotype and phenotype in 12 additional individuals with SATB2-associated syndrome. *Clin Genet.* 2017;92: 423–429. [PubMed: 28139846]
12. Zarate YA, Perry H, Ben-Omran T, et al. Further supporting evidence for the SATB2-associated syndrome found through whole exome sequencing. *Am J Med Genet Part A.* 2015;167A:1026–1032. [PubMed: 25885067]
13. Zarate YA, Steinraths M, Matthews A, et al. Bone health and SATB2-associated syndrome. *Clin Genet.* 2018;93:588–594. [PubMed: 28787087]
14. Cotton AP, Gokarakonda S, Caffrey AR, Zarate YA, Kumar N. Behavioral phenotype and sleep problems in SATB2-associated syndrome. *Dev Med Child Neurol.* 2019.
15. Dangouloff-Ros V, Roux CJ, Boulouis G, et al. Incidental brain MRI findings in children: a systematic review and meta-analysis. *AJNR Am J Neuroradiol.* 2019;40:1818–1823. [PubMed: 31624116]
16. Li Y, Huang WY, Lv CY, et al. Satb2 ablation decreases PTZ-induced seizure susceptibility and pyramidal neuronal excitability. *Brain Res.* 2018;1695: 102–107. [PubMed: 29750936]
17. Li Y, You QL, Zhang SR, et al. Satb2 ablation impairs hippocampus-based long-term spatial memory and short-term working memory and immediate early genes (IEGs)-mediated hippocampal synaptic plasticity. *Mol Neurobiol.* 2017.
18. Diaz-Alonso J, Aguado T, Wu CS, et al. The CB(1) cannabinoid receptor drives corticospinal motor neuron differentiation through the Ctip2/Satb2 transcriptional regulation axis. *J Neurosci.* 2012;32:16651–16665. [PubMed: 23175820]
19. Diaz-Alonso J, Guzman M, Galve-Roperh I. Endocannabinoids via CB(1) receptors act as neurogenic niche cues during cortical development. *Philos Trans R Soc Lond B Biol Sci.* 2012;367:3229–3241. [PubMed: 23108542]



**FIGURE.** Electroencephalographic (EEG) findings, clinical description, and current treatment in 41 individuals with abnormal EEG. The color version of this figure is available in the online edition.

**TABLE 1.**

## Demographic and Clinical Characteristics of the Study Population

Characteristic	All Individuals With at Least One Abnormal EEG (n = 41)
Male	20 (48.8%)
Median age, years (range)	6.0 (1.5–20.5)
<2 years	2 (4.9%)
2–9 years	28 (68.3%)
10–17 years	9 (21.9%)
18 years	2 (4.9%)
Molecular alteration	
Missense variant	15 (36.6%)
Truncating variant	14 (34.1%)
Large deletion	6 (14.6%)
Intragenic deletion	5 (12.2%)
Splice site	1 (2.4%)
Neuroimaging	
At least 1 brain MRI available	31 (75.6%)
Abnormal	21 (67.7%)
Delayed myelination (n = 21)	13 (61.9%)
Hyperintense lesions (n = 21)	10 (47.6%)
Abnormal corpus callosum (n = 21)	5 (23.8%)
Large/dysmorphic ventricles (n = 21)	3 (14.3%)
Decreased white matter volume/atrophy (n = 21)	3 (14.3%)
Electroencephalograms	
Individuals with single study	23 (56.1%)
Individuals with multiple EEGs	18 (43.9%)
Abnormalities on the first EEG (n = 18)	14 (77.8%)
Epileptiform discharges	38 (92.7%)
Central (n = 38)	28 (73.7%)
Parietal (n = 38)	17 (44.7%)
Temporal (n = 38)	13 (34.2%)
Frontal (n = 38)	9 (23.6%)
Seizures	
Clinical seizures and epilepsy syndromes	17 (41.4%)
Focal (partial)	7 (41.2%)
Multifocal/generalized	5 (29.4%)
Atonic	4 (23.5%)
Benign Rolandic epilepsy	3 (17.6%)
ESES	3 (17.6%)
Lennox-Gastaut syndrome	1 (5.9%)
Infantile spasms	1 (5.9%)
Benign partial epilepsy of childhood	1 (5.9%)

Characteristic	All Individuals With at Least One Abnormal EEG (n = 41)
Possible seizures	9 (21.9%)
No seizures	15 (36.6%)

Abbreviations:

EEG = Electroencephalography

ESES = Electrical status epilepticus in sleep

MRI = Magnetic resonance imaging

Author Manuscript

Author Manuscript

Author Manuscript

Author Manuscript

TABLE 2.

## Clinical Characteristics and Treatment Response in 41 Individuals With SAS

SATB2 ID#	Genomic Alteration	EEG	Clinical Seizures	Age at Seizure Onset, Years	Epilepsy	Brain MRI	Current Medications	Other Prior Medications	Seizure Outcome
168	17.8Mb deletion at 2q32.1q33.1	ED	No	N/A	None	N/A	None	None	No clinical seizures
30	15Mb deletion at 2q33.1q34	SB	Possible	1	? Generalized tonic-clonic	Abnormal CC, small pons	None	LEV	Well controlled
19	8.4Mb deletion at 2q32.3q33.2	ED	Yes	3	Focal epilepsy	N/A	None	None	Well controlled
77	8.1Mb deletion at 2q33.1q33.3	ED, SB	Yes	N/A	Focal epilepsy	Normal	OXC	LEV	Well controlled
12	3.6Mb deletion at 2q33.1	ED	Possible	7	? Focal epilepsy (laughing fits with disorientation)	At, HM, T2H	LTG, OXC	CBD	Somewhat controlled
11	1.77Mb deletion at 2q33.1	ED	Possible	6	? Focal epilepsy	HM	None	None	Somewhat controlled
143	Intragenic deletion exons 5–11	ED	Yes	2	Mixed epilepsy (benign rolandic epilepsy, atonic, tonic-clonic)	Normal	GBP, TPM	LEV, OXC	Somewhat controlled
80	Intragenic deletion exons 4–8	Excess BA	No	N/A	None	N/A	None	None	No clinical seizures
2	Intragenic deletion exons 4–8	ED	Yes	4	Focal epilepsy	N/A	OXC	LEV, ESC	Somewhat controlled
92	Intragenic deletion exon 7	ED	Yes	2	Febrile seizures and generalized tonic-clonic epilepsy	HM, T2H	None	LEV, VPA, LTG	Well controlled
78	Intragenic deletion exon 4	ED	Possible	5	? Focal epilepsy (staring episodes)	Abnormal CC, At, HM, large Ven	OXC	-	Well controlled
159	c.163delG (p.Val55Trpfs*4)	ED, SB	No	N/A	None	N/A	None	None	No clinical seizures
136	c.257T>G (p.Leu86Arg)	ED, SB	No	N/A	Nonepileptic events	N/A	CBD	-	No clinical seizures
39	c.346G>T (p.Gly116*)	ED	No	N/A	Nonepileptic events	HM	CLZ	-	No clinical seizures
11184	c.580G>T (p.Glu194*)	ED	No	N/A	None	Normal	None	None	No clinical seizures
16	c.583dupT (p.Cys195Leufs*14)	ED, SB	Possible	N/A	? Focal epilepsy (staring episodes)	T2H	None	None	No clinical seizures

SATB2 ID#	Genomic Alteration	EEG	Clinical Seizures	Age at Seizure Onset, Years	Epilepsy	Brain MRI	Current Medications	Other Prior Medications	Seizure Outcome
114	c.715C>T (p.Arg239*)	ED	No	N/A	None	HM, T2H	CBD	LEV, ESC, LCM	No clinical seizures
121	c.715C>T (p.Arg239*)	ED, ESES like	No	N/A	Nonepileptic events	SC	VPA, LTG	-	No clinical seizures
68	c.760C>T (p.His254Tyr)	ED	Yes	0.3	Mixed epilepsy (infantile spasms, intractable focal epilepsy, generalized convulsive epilepsy, epilepsy with continuous spike/wave during slowwave sleep, Lennox-Gastaut syndrome)	Abnormal CC, At, HM	CLB, ZNS, BRI, VNS	VGB, LEV, CS, KD	Well controlled
46	c.1131_1132delGT (p.Ser378Profs*18)	ED, SB	Yes	5	Mixed epilepsy (both focal and generalized epilepsy : benign rolandic epilepsy, generalized tonic-clonic, absence, atonic)	Normal	CLB, LTG	-	Well controlled
41	c.1165C>T (p.Arg389Cys)	ED	Yes	6	Focal epilepsy	T2H	LTG	LEV	Well controlled
153	c.1165C>T (p.Arg389Cys)	ED	Yes	3	Mixed epilepsy (focal epilepsy of childhood, absence)	N/A	VPA	-	Somewhat controlled
34	c.1174-2A>G	ED, ESES like, SB	Yes	2	Focal epilepsy (staring episodes)	N/A	None	CLB	Somewhat controlled
112	c.1175G>A (p.Gly392Glu)	ED, ESES, SB	Yes	2	Focal epilepsy	Normal	LEV, GBP, CLB	-	Somewhat controlled
53	c.1196G>A (p.Arg399His)	ED	No	N/A	None	Abnormal CC, HM	OXC	LEV	No clinical seizures
94	c.1196G>A (p.Arg399His)	ED	No	N/A	Non epileptic events	Normal	None	VPA, ESM, PHT	No clinical seizures
134	c.1196G>A (p.Arg399His)	ED	Yes	2	Generalized epilepsy (absence)	N/A	OXC	-	Well controlled
98	c.1196delG (p.Arg399Leufs*14)	ED	Yes	5	Mixed epilepsy (intractable atonic seizures and benign rolandic epilepsy)	N/A	VPA	-	Well controlled
29	c.1285C>T (p.Arg429*)	ED	No	N/A	Nonepileptic events	Normal	LEV, B6	-	No clinical seizures
14	c.1286G>A (p.Arg429Gln)	SB	Possible	5	? Focal epilepsy (one tonic-clonic episode; staring episodes)	T2H	VPA	-	Somewhat controlled
23	c.1286G>A (p.Arg429Gln)	ED	Possible	4	? Focal epilepsy (Staring episodes)	T2H	None	Keppra	Somewhat controlled

SATB2 ID#	Genomic Alteration	EEG	Clinical Seizures	Age at Seizure Onset, Years	Epilepsy	Brain MRI	Current Medications	Other Prior Medications	Seizure Outcome
70	c.1286G>A (p.Arg429Gln)	ED	No	N/A	None	Normal	None	None	No clinical seizures
105	c.1286G>A (p.Arg429Gln)	ED	Possible	7	? Focal epilepsy (single convulsive episode, starting spells)	HM	None	None	Well controlled
164	c.1307A>T (p.Glu436Val)	ED, SB	Yes	5	Mixed epilepsy (focal, generalized atonic)	Abnormal CC, HM, large Ven	ZNS	-	Somewhat controlled
124	c.1375C>T (p.Arg459*)	ED	No	N/A	None	Normal	None	None	No clinical seizures
1093	c.1425_1426dupGG (p.Val476Glyfs*21)	ED	No	N/A	None	UF asymmetry, T2H	None	None	No clinical seizures
38	c.1495A>T (p.Lys499*)	ED	Possible	7	? Focal epilepsy (mouth twitching)	Large Ven, T2H	None	None	No clinical seizures
109	c.1554T>G (p.Cys518Trp)	ED, SB	Yes	2	Focal versus generalized epilepsy (atypical absence)	Normal	VPA, LTG	LEV, TPM	Somewhat controlled
75	c.1592dupA (p.Asn531Lysfs*21)	ED	Yes	4.5	Mixed epilepsy (both focal and intractable generalized nonconvulsive epilepsy, generalized convulsive epilepsy)	HM	None	VPA, LEV, B6, KD	Well controlled
7	c.1728delT (p.Glu577Serfs*47)	ED	No	N/A	Nonepileptic events	HM, T2H	CBZ	LEV, CBZ	No clinical seizures
116	c.1903G>T (p.Asp635Tyr)	ED, ESES	Yes	3	Focal epilepsy	HM	CLB, OXC	-	Well controlled

## Abbreviations:

AI = Atrophy

B6 = vitamin B6;

BA = Beta activity

BRI = Brivaracetam

CBD = Cannabidiol oil

CBZ = Carbamazepine

CC = Corpus callosum

CLB = Clobazam

CLZ = Clonazepam



CS = Corticosteroids  
ED = Epileptiform discharges  
EEG = Electroencephalography  
ESC = Eslicarbazepine  
ESES = Electrical status epilepticus in sleep  
ESM = Ethosuximide  
GBP = Gabapentin  
HM = Hypomyelination  
KD = Ketogenic diet  
LCM = Lacosamide  
LEV = Levetiracetam  
LTG = Lamotrigine  
MRI = Magnetic resonance imaging  
N/A = Not applicable  
NAV = Not available  
OXC = Oxcarbazepine  
PHT = Phenytoin  
SAS = *SATB2*-associated syndrome  
SB = Slow background  
T2H = T2 hyperintensities  
TPM = Topiramate  
UF = Uncinated fascicle  
Ven = Ventricles  
VGB = Vigabatrin  
VNS = Vagus nerve stimulation  
VPA = Valproate  
ZNS = Zonisamide