

UC Irvine

UC Irvine Previously Published Works

Title

The value of the glenohumeral joint cross-sectional area as a morphological parameter of glenohumeral osteoarthritis.

Permalink

<https://escholarship.org/uc/item/0xv562q1>

Journal

Medicine, 101(47)

Authors

Bang, Yun-Sic

Lee, Da

Kim, Taeyeun

et al.

Publication Date

2022-11-25

DOI

10.1097/MD.00000000000031424

Peer reviewed

The value of the glenohumeral joint cross-sectional area as a morphological parameter of glenohumeral osteoarthritis

Yun-Sic Bang, MD^a, Da Yeong Lee, MD^a, Taeyeun Kim, MD^a, Min-Ying Su, PhD^b, SoYoon Park, MD^c, Sooho Lee, MD^c, Jungmin Yi, MD^c, Hyunhae Kim, MD^c, Young Uk Kim, MD, PhD^{c,*}

Abstract

Glenohumeral joint (GHJ) space narrowing has been demonstrated to be an important morphologic parameter of glenohumeral osteoarthritis (GHO). However, the morphology of GHJ space is irregular because of degeneration of subchondral bone and articular cartilage. Thus, we devised GHJ cartilage cross-sectional area (GHJCCSA) as a new diagnostic morphological parameter to assess the irregular morphologic change of GHJ. GHJ samples were acquired from 33 patients with GHO and from 33 normal controls without evidence of GHO based on shoulder magnetic resonance imaging. T2-weighted coronal MRIs were collected at the GHJ level for all individuals. GHJCCSA and GHJ cartilage thickness (GHJCT) at the GHJ were measured on MRIs using a graphic measuring system. The GHJCCSA was measured as the whole cartilage cross-sectional area of the GHJ. The average GHJCCSA was $115.28 \pm 17.36 \text{ mm}^2$ in normal individuals and $61.77 \pm 13.74 \text{ mm}^2$ in the GHO group. The mean GHJCT was $2.06 \pm 0.35 \text{ mm}$ in normal individuals and $1.50 \pm 0.28 \text{ mm}$ in the GHO group. GHO patients had significantly lower GHJCCSA ($P < .001$) and GHJCT ($P < .001$) than normal individuals. Receiver operator characteristics curve analysis revealed that the optimal cutoff score of the GHJCCSA was 82.21 mm^2 , with a sensitivity of 97.0%, a specificity of 97.0%, and an area under the curve of 0.99 (95% CI: 0.97–1.00). Although GHJCCSA and GHJCT were both significantly associated with GHO, the GHJCCSA was a more sensitive measurement parameter.

Abbreviations: AUC = area under the curve, CI = confidence interval, GHJ = glenohumeral joint, GHJCCSA = glenohumeral joint cartilage cross-sectional area, GHJCT = glenohumeral joint cartilage space thickness, GHO = glenohumeral osteoarthritis, ROC = receiver operating characteristic, S-MRI = shoulder magnetic resonance imaging.

Keywords: cartilage, cross-sectional area, diagnosis, glenohumeral joint, glenohumeral osteoarthritis, thickness

1. Introduction

Glenohumeral osteoarthritis (GHO) is defined by degeneration of subchondral bone and articular cartilage with narrowing of the glenohumeral joint (GHJ).^[1–3] GHO causes functional limitation, disability, and pain, with an estimated prevalence of 4%. It is commonly understood that the GHJ space remains unchanged until the initiation of GHO, at which point joint space narrowing and progressive degenerative changes will occur.^[4–6] Only a few trials have been performed to evaluate the predictable value of shoulder magnetic resonance imaging (S-MRI) findings in diagnosing symptomatic GHO. Previous researches have evaluated the GHJ space narrowing using a single measurement called GHJ cartilage space thickness (GHJCT) at the approximate “halfway” or “middle” of the GHJ.^[7–9] Kircher et al have demonstrated that the GHJCT

decreases with increasing age.^[9] This age-dependent joint space narrowing is enhanced in patients with GHO. However, an irregular osteophyte formation can occur anywhere. Therefore, measurement inaccuracy could occur. It might be worthy to reconsider the predictable value of S-MRI findings obtained from a turbo spin echo coronal S-MRI in the diagnosis of symptomatic GHO.^[10] To analyze irregular narrowing of the GHJ, we propose that the GHJ cartilage cross-sectional area (GHJCCSA) is a new diagnostic morphological parameter. Compared to the GHJCT, the GHJCCSA does not suffer from mistake of measurement because the GHJCCSA measures the whole cross-sectional area of the GHJ. We hypothesize that the GHJCCSA is a main morphologic parameter in GHO diagnosis. Therefore, the objective of this study was to use S-MRI images to compare GHJCCSA and GHJCT between GHO patients and control individuals.

The authors have no funding and conflicts of interest to disclose.

This study conforms to the Declaration of Helsinki.

All data generated or analyzed during this study are included in this published article [and its supplementary information files].

^a Department of Anesthesiology and Pain Medicine, CHA Bundang Medical Center, CHA University, Seongnam, Republic of Korea, ^b Department of Radiological Sciences, University of California, Irvine, CA, USA, ^c Department of Anesthesiology and Pain Medicine, Catholic Kwandong University of Korea College of Medicine, International ST. Mary's Hospital, Incheon, Republic of Korea.

*Correspondence: Young Uk Kim, MD, PhD, Department of Anesthesiology and Pain Medicine, Catholic Kwandong University of Korea College of Medicine, International ST. Mary's Hospital, Simgokro, 100 Gil 25, Seo-Gu, Incheon City, Republic of Korea (e-mail: uk201@hanmail.net).

Copyright © 2022 the Author(s). Published by Wolters Kluwer Health, Inc. This is an open-access article distributed under the terms of the Creative Commons Attribution-Non Commercial License 4.0 (CCBY-NC), where it is permissible to download, share, remix, transform, and buildup the work provided it is properly cited. The work cannot be used commercially without permission from the journal.

How to cite this article: Bang Y-S, Lee DY, Kim T, Su M-Y, Park S, Lee S, Yi J, Kim H, Kim YU. The value of the glenohumeral joint cross-sectional area as a morphological parameter of glenohumeral osteoarthritis. *Medicine* 2022;101:47(e31424).

Received: 20 October 2021 / Received in final form: 29 September 2022 / Accepted: 30 September 2022

<http://dx.doi.org/10.1097/MD.00000000000031424>

Table 1
Comparison of characteristics of control and GHJO groups.

Variable	Control group n = 33	GHJO group n = 33	Statistical significance
Gender (male/female)	12/21	16/17	NS
Age (yr)	58.73 ± 8.81	60.55 ± 10.03	NS
GHJCT (mm)	2.06 ± 0.35	1.50 ± 0.28	$P < .001$
GHJCCSA (mm ²)	115.28 ± 17.36	61.77 ± 13.74	$P < .001$
Location (Rt/Lt)	15/18	18/15	NS

Data represent the mean ± standard deviation (SD) or the number of patients.

GHJO = glenohumeral joint osteoarthritis; GHJCT = glenohumeral joint cartilage thickness; GHJCCSA = glenohumeral joint cartilage cross-sectional area; NS = not statistically significant ($P > .05$).

2. Methods and Material

2.1. Patients

The retrospective research material used to support the findings of this research were approved by Catholic Kwandong Institutional Review Board. (IRB number: IS19RISI0061).

Individuals who visited the shoulder orthopedic clinic with shoulder pain from July 2017 to April 2019 and had taken S-MRI within 12 months of the last visit were reviewed retrospectively. Inclusion criteria of the GHO group were: a history of pain and tenderness in the GHJ; crepitation with movement of the joint that was often palpated anteriorly; persistent symptom (patients should be seen in follow-up at 6 to 8 weeks to reevaluate range of motion). We excluded subjects if patients had any of the following histories: inflammatory arthritis; humerus bone fracture; history of shoulder infection; acute clavicle fracture; or any history of shoulder surgery.

A total of 33 patients was confirmed by 2 board-certified experienced musculoskeletal radiologists. There were 16 (48.48%) men and 17 (51.52%) women with an average age of 60.55 ± 10.03 years (range, 43 to 80 years) (Table 1). To compare results between individuals with and without GHO, normal subjects were enrolled. Individuals who wanted to take S-MRI for the exact diagnosis of shoulder pain without evidence of GHO were enrolled for the normal group. In the normal group, 33 individuals (12 men and 21 women) were enrolled. Their average age was 58.73 ± 8.81 years (range, 40 to 83 years).

2.2. Imaging parameters

Shoulder assessment was performed using a 3T S-MRI system (Magnetom Skyra, Siemens, Medical Solutions, Germany) and a 3T Ingina scanners (Philips Healthcare, Eindhoven, Netherlands). For all S-MRI examinations, oblique coronal fat suppressed T2-weighted images were obtained with a slice thickness of 3 mm, slice gap of 0.9 mm, repetition time 4010-ms of/echo time 76-ms, 150×150 cm field of view, 512×256 matrix, and > 3 ETL.

2.3. Image analysis

GHJCCSA and GHJCT measurements were performed by one pain specialist who was blinded to the classification of shoulders. Oblique coronal T2-weighted S-MRIs were obtained at the GHJ. GHJCCSA and GHJCT were measured on S-MRI using an image analysis program (INFINITT PACS; Infinit Medical Solutions, Incheon, Seo-gu, Republic of Korea) (Figs. 1, 2A and B). The GHJCT was measured at the narrowest GHJ. The GHJCCSA was measured as the whole cross-sectional area of the cartilage of GHJ.

2.4. Statistical analysis

Student's *t* test was used to compare GHJCCSA and GHJCT between GHO and control groups. Receiver operating

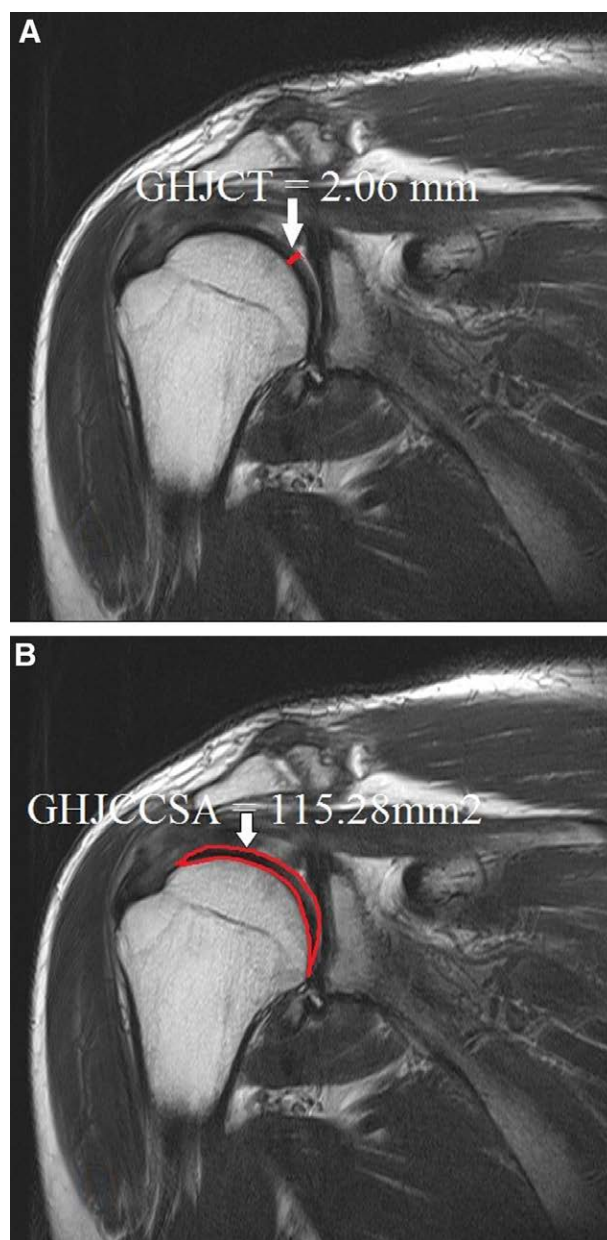


Figure 1. Measurement of both glenohumeral joint cartilage space thickness (GHJCT) (A) and glenohumeral joint cartilage cross-sectional area (GHJCCSA) (B) in the normal control group was carried out on oblique coronal T2-weighted S-MRI in the glenohumeral joint. S-MRI = shoulder magnetic resonance imaging.

characteristic curve was applied to assess diagnostic values of GHJCCSA and GHJCT. Area under the curve (AUC) with 95% confidence intervals (CIs), cutoff points, sensitivity, and specificity were obtained (IBM/SPSS Inc., Chicago, IL).

3. Results

There were 15 right shoulders and 18 left shoulders in the control group. The average GHJCCSA was 115.28 ± 17.36 mm² in the control group and 61.77 ± 13.74 mm² in the GHO group. There were 18 right shoulders and 15 left shoulders in the GHO group. The mean GHJCT was 2.06 ± 0.35 mm in the normal group and 1.50 ± 0.28 mm in the GHO group. GHO patients had significantly lower GHJCCSA ($P < .001$) and GHJCT ($P < .001$) than normal subjects (Table 1). Regarding the diagnostic accuracy of both GHJCCSA and GHJCT as predictors

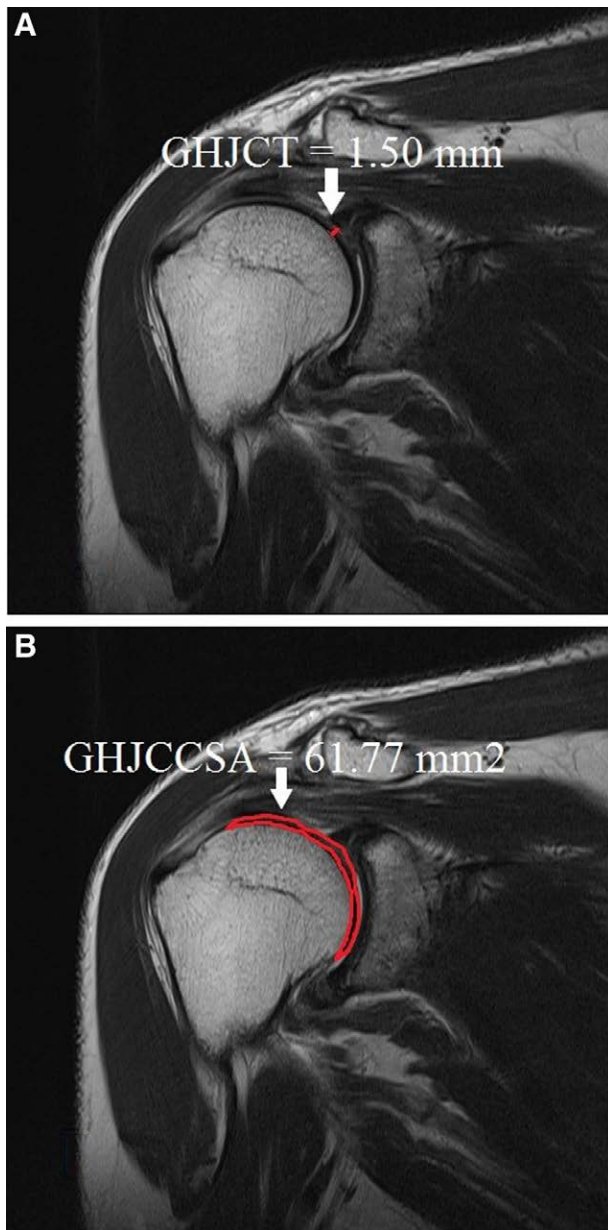


Figure 2. In the glenohumeral osteoarthritis (GHO) group, both glenohumeral joint cartilage space thickness (GHJCT) (A) and glenohumeral joint cartilage cross-sectional area (GHJCCSA) (B) were measured on oblique coronal T2-weighted shoulder magnetic resonance imaging.

of GHO, receiver operating characteristic curves revealed that the best cutoff score of the GHJCT was 1.82 mm, with a sensitivity of 90.9%, a specificity of 87.9%, and an AUC of 0.92 (95% CI: 0.85-0.99) (Table 2, Fig. 3). The best cutoff point of the GHJCCSA was 82.21 mm², with a sensitivity of 97.0%, a specificity of 97.0%, and an AUC of 0.99 (95% CI: 0.97-1.00) (Table 3, Fig. 2).

4. Discussion

The GHJ is one of the most common affected large joints following the hip and knee.^[9,11-13] Although the true prevalence of GHO is difficult to analyze, population-based researches have reported that about 20% of elderly populations have radiographic evidence of GHO.^[14-16] Major risk factors for GHO include obesity and female sex. Secondary causes of GHO

Table 2
Sensitivity and specificity of each cutoff point of the GHJCT.

GHJCT (mm)	Sensitivity (%)	Specificity (%)
1.11	9.1	100
1.23	24.2	93.9
1.45	42.4	93.9
1.82*	90.9	87.9
1.84	93.9	84.8
1.99	100	60.6

GHJCT = glenohumeral joint cartilage thickness.

*The best cutoff point on the receiver operating characteristic curve.

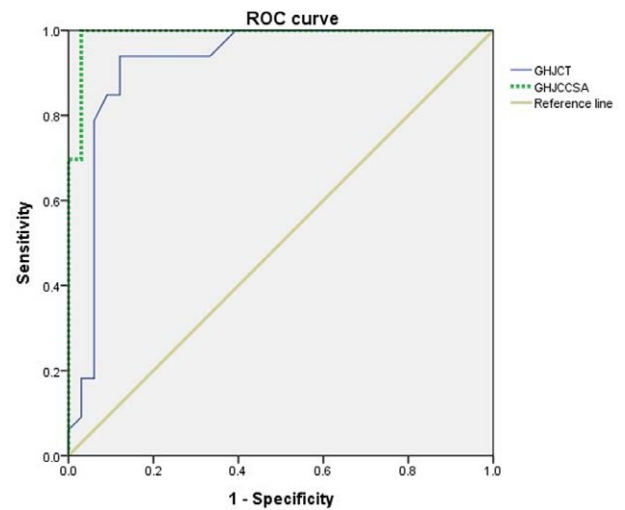


Figure 3. Receiver operating characteristic (ROC) curve of glenohumeral joint cartilage space thickness (GHJCT) and glenohumeral joint cartilage cross-sectional area (GHJCCSA) for prediction of glenohumeral osteoarthritis (GHO). The best cut off point of GHJCT versus GHJCCSA was 1.82 mm versus 82.21 mm², with a sensitivity of 90.9% versus 97.0%, a specificity of 87.9% versus 97.0%, and an AUC of 0.92 versus 0.99. GHJCT AUC (95% CI) = 0.92 (0.84–0.99); GHJCCSA AUC (95% CI) = 0.99 (0.97–1.00). AUC = area under the curve.

include crystalline or infectious arthropathy, avascular necrosis, prior trauma such as surgery and dislocation.^[17,18] Arthrogenic factors include presence of bony defects of either the humerus or glenoid, presence of a rotator cuff tear, and age at time of dislocation.^[10,18] Physical examination should be attempted to identify their etiologies within the shoulder such as bursitis and tendinosis and pathology of pain outside the shoulder should be excluded.^[19] Pain radiating down the arm and neck pain with provocative maneuvers such as Spurling’s test can rule out a cervical origin problem.^[20,21] A thorough neurovascular and neck examination should always be performed to diagnose properly.

The first step of treatment of primary GHO is nonoperative conservative management. Operative management of GHO is recommended for patients who have failed the first step of treatment.^[22-24] In elderly patients, total shoulder arthroplasty is a highly successful and reliable procedure. However, concerns regarding decreased activity levels and implant longevity have led orthopedic surgeons to pursue joint-preserving procedures in more active and younger patients. Radiograph is the first choice for staging and diagnosing GHO.^[25,26] As described above, posterior glenoid wear and joint space narrowing are commonly found. The presence of osteophytes and subchondral sclerosis from the humeral head is also an anticipated finding. Advanced imaging modalities are frequently necessary for exact diagnosis because they can provide important information for

Table 3
Sensitivity and specificity of each cutoff point of the GHJCCSA.

GHJCCSA (mm ²)	Sensitivity (%)	Specificity (%)
43.82	12.1	100
54.70	24.2	100
59.29	45.5	100
82.21*	97.0	97.0
85.48	100	97.0
106.64	100	60.6

GHJCCSA = glenohumeral joint cartilage cross-sectional area.

*The best cutoff point on the receiver operating characteristic curve.

staging disease progression, identification of concomitant rotator cuff or labral pathology, and preoperative planning.^[5,9,11] Only a few trials have evaluated the predictable value of S-MRI findings in diagnosing symptomatic GHO. Schleich et al have provided normative information for comparison of GHJ cartilage changes in various pathological disorders such as early GHO.^[27] Kircher et al have demonstrated that GHJCT decreases with increasing age. This age-dependent joint space narrowing is enhanced in patients with GHO.^[9]

However, previous articles assessed the GHJ space narrowing using a single measurement called GHJCT at the approximate “single halfway” of the GHJ. Therefore, a measurement error frequently occurs. We think that it might be worthy to reconsider the predictable value of S-MRI findings obtained from a coronal, turbo spin echo T2-weighted, fat-suppressed S-MRI in the diagnosis of symptomatic GHO.

To analyze narrowing of the GHJ, we devised the GHJCCSA as a new morphological parameter. In contrast to the GHJCT, the GHJCCSA is not influenced by this measurement bias because the GHJCCSA measures the cross-sectional area of the whole GHJ. Eventually, we found that the GHJCCSA was better than the GHJCT as a diagnostic parameter of GHO. In the current original research, we found that the GHJCCSA had a sensitivity of 97.0%, a specificity of 97.0%, and an AUC of 0.99 (95% CI: 0.97–1.00) to predict GHO. In contrast, the GHJCT had a sensitivity of 90.9%, a specificity of 87.9%, and an AUC of 0.92 (95% CI: 0.84–0.99). These findings suggest that the GHJCCSA is a better predictor of GHO than the GHJCT. We believe that our results can be used to improve the quality of diagnosis of the GHO.

This study has some limitations. There are several isolated GHJ pathology in the symptomatic shoulder such as rotator cuff tear arthropathy. However, we focused on GHO. Second, some alternative methods such as ultrasound, plain X-ray, arthrocentesis have been shown to be effective at discriminating GHO.^[28–33] Especially, ultrasound provides real-time imaging.^[28–33] However, we only measured GHJCCSA and GHJCT on S-MRI. Third, there might be some bias associated with measuring GHJCCSA and GHJCT on S-MRI. Even though we tried to check these diagnostic parameters in the oblique coronal T2-weighted image that best showed the GHJ, coronal images could be irregular.

5. Conclusion

Although GHJCCSA and GHJCT are both significantly associated with GHO, GHJCCSA is a more sensitive diagnostic parameter for GHO than GHJCT. We demonstrated that the most suitable cutoff value of the GHJCCSA was 82.21 mm², with sensitivity and specificity of 97.0% both. The optimal cutoff point of the GHJCT was 1.82 mm, with a sensitivity of 90.9% and a specificity of 87.9%. Thus, physicians should carefully evaluate the GHJCCSA rather than the GHJCT when assessing patients with GHO.

Acknowledgments

The all authors thank the International ST. Mary's Hospital.

Author contributions

Conceptualization: Young Uk Kim.

Data curation: Young Uk Kim.

Methodology: Min-Ying Su, SoYoon Park, Sooho Lee.

Resources: Jungmin Yi.

Software: Young Uk Kim.

Visualization: Young Uk Kim.

Writing – original draft: Young Uk Kim.

Writing – review and editing: Yun-Sic Bang, Da Yeong Lee, Taeyeun Kim, Hyunhae Kim, Young Uk Kim.

References

- Deutsch AL, Resnick D, Mink JH, et al. Computed and conventional arthrography of the glenohumeral joint: normal anatomy and clinical experience. *Radiology*. 1984;153:603–9.
- Fardet L, Messow M, Maillefert JF, et al. Primary glenohumeral degenerative joint disease: factors predisposing to arthroplasty. *Clin Exp Rheumatol*. 2003;21:13–8.
- Fealy S, Rodeo SA, Dicarolo EF, et al. The developmental anatomy of the neonatal glenohumeral joint. *J Shoulder Elbow Surg*. 2000;9:217–22.
- Carfagno DG, Ellenbecker TS. Osteoarthritis of the glenohumeral joint: nonsurgical treatment options. *Phys Sportsmed*. 2002;30:19–30.
- Franiel J. The use of ultrasound in the assessment of the glenoid labrum of the glenohumeral joint. Part I: Ultrasound anatomy and examination technique and W. Krzyzanowski, M. Tarczynska The use of ultrasound in the assessment of the glenoid labrum of the glenohumeral joint. Part II: Examples of labral pathologies. *J Ultrason*. 2012;12:500–3.
- Guyette TM, Bae H, Warren RF, et al. Results of arthroscopic subacromial decompression in patients with subacromial impingement and glenohumeral degenerative joint disease. *J Shoulder Elbow Surg*. 2002;11:299–304.
- Chang IR, Varacallo M. Anatomy, shoulder and upper limb, glenohumeral joint. In: *StatPearls*. Treasure Island (FL); 2019.
- Crowell MS, Tragord BS. Orthopaedic manual physical therapy for shoulder pain and impaired movement in a patient with glenohumeral joint osteoarthritis: a case report. *J Orthop Sports Phys Ther*. 2015;45:453–461, A451–453.
- Kircher J, Kuerner K, Morhard M, et al. Age-related joint space narrowing independent of the development of osteoarthritis of the shoulder. *Int J Shoulder Surg*. 2014;8:95–100.
- Rafii M. Non-contrast MR imaging of the glenohumeral joint. Part I. Normal anatomy. *Skeletal Radiol*. 2004;33:551–60.
- Kerr R, Resnick D, Pineda C, et al. Osteoarthritis of the glenohumeral joint: a radiologic-pathologic study. *AJR Am J Roentgenol*. 1985;144:967–72.
- Krzyzanowski W. The use of ultrasound in the assessment of the glenoid labrum of the glenohumeral joint. Part I: Ultrasound anatomy and examination technique. *J Ultrason*. 2012;12:164–77.
- Lee SY, Park HJ, Kwon HJ, et al. T2 relaxation times of the glenohumeral joint at 3.0 T MRI in patients with and without primary and secondary osteoarthritis. *Acta Radiol*. 2015;56:1388–95.
- Masjedi M, Johnson GR. Alteration of scapula lateral rotation for subjects with the reversed anatomy shoulder replacement and its influence on glenohumeral joint contact force. *Proc Inst Mech Eng H*. 2011;225:38–47.
- Ratcliffe A, Flatow EL, Roth N, et al. Biochemical markers in synovial fluid identify early osteoarthritis of the glenohumeral joint. *Clin Orthop Relat Res*. 1996:45–53.
- Rozenzwaig R, van Noort A, Moskal MJ, et al. The correlation of comorbidity with function of the shoulder and health status of patients who have glenohumeral degenerative joint disease. *J Bone Joint Surg Am*. 1998;80:1146–53.
- Seeger LL, Gold RH, Bassett LW. Magnetic resonance imaging of glenohumeral joint disease. *Invest Radiol*. 1988;23:650–1.
- Moor BK, Bouaicha S, Rothenfluh DA, et al. Is there an association between the individual anatomy of the scapula and the development of rotator cuff tears or osteoarthritis of the glenohumeral joint?: A radiological study of the critical shoulder angle. *Bone Joint J*. 2013;95-B:935–41.

- [19] Domenech-Garcia V, Peirotten AR, Imaz ML, et al. Not just sensitization: sympathetic mechanisms contribute to expand experimental referred pain. *Korean J Pain*. 2022;35:240–9.
- [20] Gurudut P, Godse AN. Effectiveness of graded motor imagery in subjects with frozen shoulder: a pilot randomized controlled trial. *Korean J Pain*. 2022;35:152–9.
- [21] Shin WJ. Emerging safety concerns in elderly patients undergoing shoulder surgery. *Korean J Anesthesiol*. 2021;74:4–5.
- [22] Merila M, Leibecke T, Gehl HB, et al. The anterior glenohumeral joint capsule: macroscopic and MRI anatomy of the fasciculus obliquus or so-called ligamentum glenohumerale spirale. *Eur Radiol*. 2004;14:1421–6.
- [23] Sinha I, Lee M, Cobiella C. Management of osteoarthritis of the glenohumeral joint. *Br J Hosp Med (Lond)*. 2008;69:264–8.
- [24] van der Meijden OA, Gaskill TR, et al. Glenohumeral joint preservation: a review of management options for young, active patients with osteoarthritis. *Adv Orthop*. 2012;2012:160923.
- [25] Viehofer AF, Snedeker JG, Baumgartner D, et al. Glenohumeral joint reaction forces increase with critical shoulder angles representative of osteoarthritis-A biomechanical analysis. *J Orthop Res*. 2016;34:1047–52.
- [26] Warner JJ, Caborn DN, Berger R, et al. Dynamic capsuloligamentous anatomy of the glenohumeral joint. *J Shoulder Elbow Surg*. 1993;2:115–33.
- [27] Schleich C, Bittersohl B, Antoch G, et al. Thickness Distribution of Glenohumeral Joint Cartilage. *Cartilage*. 2017;8:105–11.
- [28] Agarwal R, Jain G, Agarwal A, et al. Effectiveness of four ultrasonographic parameters as predictors of difficult intubation in patients without anticipated difficult airway. *Korean J Anesthesiol*. 2021;74:134–41.
- [29] Baek SJ, Lee JW, Chung S, et al. Clinical usefulness of ultrasound as an early diagnostic tool for neuroleukemiosis -a case report. *Korean J Anesthesiol*. 2021;74:65–9.
- [30] Jeong H, Choi JW, Sim WS, et al. Ultrasound-guided erector spinae plane block for pain management after gastrectomy: a randomized, single-blinded, controlled trial. *Korean J Pain*. 2022;35:303–10.
- [31] Mohanty CR, Bellapukonda S, Topono N, et al. Point-of-care ultrasonography as rescue for popliteal artery cannulation in prone position. *Korean J Anesthesiol*. 2021;74:276–7.
- [32] Al-Redouan A, Kachlik D. Suprascapular notch cross-sectional area by MRI do not yield accuracy in the diagnosis of suprascapular nerve entrapment - counter point of view. *Korean J Anesthesiol*. 2022.
- [33] Yoo SW, Ki MJ, Doo AR, et al. Prediction of successful caudal epidural injection using color Doppler ultrasonography in the paramedian sagittal oblique view of the lumbosacral spine. *Korean J Pain*. 2021;34:339–45.