

# UC Irvine

## UC Irvine Previously Published Works

### Title

Brainstem auditory evoked potentials and cochlear microphonics in the HMSN family with auditory neuropathy

### Permalink

<https://escholarship.org/uc/item/1061518p>

### Journal

Pflügers Archiv - European Journal of Physiology, 439(Suppl 1)

### ISSN

0031-6768

### Authors

Butinar, Dušan  
Starr, Arnold  
Vatovec, Jagoda

### Publication Date

2000

### DOI

10.1007/s004240000146

### Copyright Information

This work is made available under the terms of a Creative Commons Attribution License, available at <https://creativecommons.org/licenses/by/4.0/>

Peer reviewed

## Brainstem auditory evoked potentials and cochlear microphonics in the HMSN family with auditory neuropathy

Dušan Butinar<sup>1</sup> · Arnold Starr<sup>2</sup> · Jagoda Vatovec<sup>3</sup>

<sup>1</sup>Institute of Clinical Neurophysiology, University Medical Centre, Ljubljana, Slovenia, <sup>2</sup>University of California, Irvine, USA, <sup>3</sup>Department of Otorhinolaryngology and Cervicofacial Surgery, University Medical Centre, Ljubljana, Slovenia

**Abstract** The aim of this work was to assess the hearing impairment in patients with hereditary motor and sensory neuropathy (HMSN). Elevation of pure tone thresholds in the presence of preserved inner ear function as suggested by cochlear microphonics (CM), absent or markedly abnormal brainstem auditory evoked potentials (BAEP), and elevation of speech perception out of proportion to the pure tone loss were found in the patients. From 28 members of a Gypsy family, we examined two siblings aged 31 and 30 years and their nephew aged 20 years, all suffering from HMSN that was associated with auditory neuropathy. All three affected members with difficulty of understanding speech had following investigations: pure tone and speech audiograms, BAEP, cochlear microphonics, and nerve conduction studies (NCV). Results: the older two siblings had a flat 80 dB audiogram, whereas the younger one has flat 20 dB audiogram on the Lt. ear and 30 dB audiogram on the Rt. ear. All had no speech comprehension and no BAEP. Two patients had preserved cochlear microphonics on one ear. Peripheral nerves were electrically not elicitable, however, at the beginning of the disease nerve conduction was slow. Conclusion: in all three affected members with distinct clinical picture of HMSN their hearing impairment was proved to be due to severe auditory neuropathy in the presence of preserved inner ear function.

**Key words** auditory neuropathy · brainstem auditory evoked potentials · cochlear microphonics · hereditary motor and sensory neuropathy

### Introduction

Three members of a Gypsy family with hereditary motor and sensory neuropathy (HMSN) had communication problems due to loss of speech comprehension out of proportion to their pure threshold elevation. They did not benefit from hearing aids, therefore we postulated that their hearing deficit was due to a disorder of the cochlear nerve function in the presence of normal cochlear hair cell function [8]. The type of hearing disorder we are describing has been noted as a paradoxical absence of brainstem auditory evoked potentials (BAEP) in patients with only slightly impaired hearing [3,4,9]. Davis and Hirsh (1979) estimated that 1 in 200 hearing impaired subjects has this type of disorder [3]. Kraus et al. (1984) determined that approximately 15% of patients with no BAEP waves fit this category [6].

The aim of this study was to characterise the functional status of the auditory system in patients with hearing impairment due to auditory neuropathy. It is postulated that they have elevation of pure tone thresholds in the presence of preserved inner hair cell function as suggested by cochlear microphonics (CM) and absent or markedly abnormal BAEP.

### Materials and methods

Out of 28 members of a Gypsy family we examined two siblings aged 31 years and 30 years and their nephew aged 20 years, suffering from HMSN associated with auditory neuropathy.

Pure tone audiometry (250-8000 Hz) was performed by air and bone conduction signals. Speech comprehension test for numbers and for short syllables was done, and the percentage of correctly comprehended numbers and syllables was recorded. Brainstem auditory evoked potentials were recorded between ipsi- and contralateral earlobe electrode and vertex, with a bandpass 100-3000 Hz. Stimuli were alternate clicks presented monaurally at 10 Hz rate and intensity of 100 dB HL. Two averages were made at each test signal and the presence of reproducible components defined. Cochlear microphonics were recorded the same way. However, for stimulation a rarefaction and condensation clicks were used separately. Nerve conduction studies were done in distal and proximal limb segments.

## Results

All three affected family members had marked distal muscle atrophies, claw hands and equinovarus and pes cavus deformities of the legs. The nephew had polydactily on the hands. They had pronounced muscle weakness distally, absent reflexes and distal sensory loss for touch, pin and vibration. This severe motor and sensory degeneration developed before their age of ten.

The two siblings had a flat 80 dB audiogram, whereas their nephew had flat 20 dB audiogram on the Lt. ear and 30 dB audiogram on the Rt. ear. They hear sounds, but have no speech comprehension at all. They utilise lip reading to enable conversation. Their hearing loss developed in their teens. They all had no BAEP (Fig 1.) and two of them, a female sibling (Fig 2) and her nephew, had preserved cochlear microphonics.

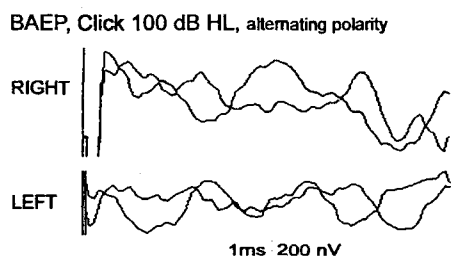


Fig. 1. Brainstem auditory evoked potentials in a female sibling aged 30 years. Absent potentials on either ear stimulation.

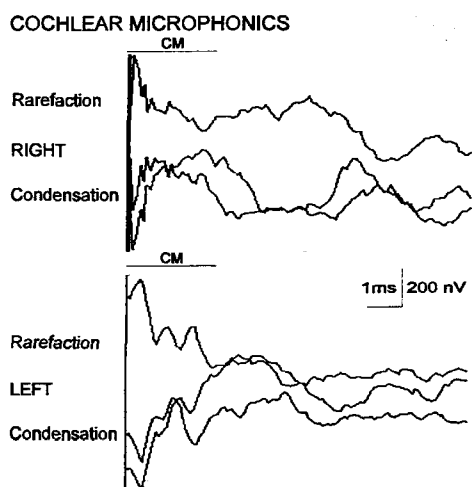


Fig. 2. Cochlear microphonics to rarefaction and condensation clicks.

It was not possible to perform nerve conduction studies in distal segments of hands and legs, as the nerves were electrically unelicitable. In proximal segments of the upper limbs, however, nerve conduction studies revealed nerve conduction velocities below 10 m/s in two patients. All three of them had initially slow distal nerve conduction velocities.

## Discussion

In three patients of a Gypsy family who all were affected with hereditary motor and sensory neuropathy associated with hearing loss, we proved that their hearing loss was due to the cochlear nerve dysfunction as a part of the generalised neuropathy in presence of the normal inner hair cell function as proved by preserved cochlear microphonics. Audiograms tested 10 to 20 years after the onset of the motor signs showed a pure tone loss without air bone gap that varied from mild to profound. They all had no speech comprehension at all and were using lip reading to enable conversation. No patient had any neural component of the auditory evoked potentials, beginning with wave I, activated by distal portion of the cochlear nerve [7]. Two of the three patients had evidence of cochlear microphonic potentials which are receptor potentials generated by both inner and outer hair cells to acoustic stimulation [1,2]. All these results suggest that the hearing loss in these patients is neural and not sensoryneural as cochlear haircell functions are preserved and auditory nerve responses are abnormal or absent. Electrophysiological studies were typical of demyelinating neuropathy. Similar findings were reported by Kalaydjieva et al. [5]. However, they stated patients have sensoryneural hearing loss, while we proved that the hearing loss is neural only, and therefore most probably a part of a hereditary neuropathy.

*Acknowledgement.* This work is supported by NIH - National institute on Deafness and Other Communication Disorders under prime grant no. DC02618-O1A2 and The Regents of the University of California.

## References

1. Aran J-M, Charlet de Sauvage R. Clinical value of cochlear microphonic recordings. In: Ruben RJ, Elberling C, Salomon G, eds. *Electroencephalography*. Baltimore: University Park Press, 1976:55-65.
2. Dallos P. Cochlear potentials. A status report. *Audiology* 1972; 11: 29-41.
3. Davis H, Hirsh SK. A slow brain response for low-frequency audiometry. *Audiology* 1979;18: 445.
4. Hildsheimer M, Muchnik C, Rubenstein M. Problems in interpretation of brainstem-evoked response audiometry results. *Audiology* 1993; 24: 374-9.
5. Kalaydjieva L, Nikolova A, Turnev I et al. Hereditary motor and sensory neuropathy-Lom, a novel demyelinating neuropathy associated with deafness in Gypsies. Clinical, electrophysiological and nerve biopsy findings. *Brain* 1998;121: 399-408.
6. Kraus N, Odzdamar Y, Stein L, Reed N. Absent auditory brain stem response: Peripheral hearing loss or brain stem dysfunction? *Laryngoscope* 1984; 94 (3): 400-6.
7. Møller AR. Neural generators of auditory evoked potentials. In: Jacobson JT, editor. *Principles and applications in auditory evoked potentials*. Boston: Allyn and Bacon, 1994: 23-46.
8. Starr A, Davis H, Hirsh SK. A slow brain response for low-frequency audiometry. *Audiology* 1979;18: 445.
9. Worthington DW, Peters J. Quantifiable hearing and no ABR: Paradox or error? *Ear Hearing* 1980;1 (5): 281-5.