

# UC Irvine

## UC Irvine Previously Published Works

### Title

Photoradiation therapy of gynecologic malignancies

### Permalink

<https://escholarship.org/uc/item/10t136qf>

### Journal

Gynecologic Oncology, 17(2)

### ISSN

0090-8258

### Authors

Rettenmaier, Mark A

Berman, Michael L

DiSaia, Philip J

et al.

### Publication Date

1984-02-01

### DOI

10.1016/0090-8258(84)90078-7

### Copyright Information

This work is made available under the terms of a Creative Commons Attribution License, available at

<https://creativecommons.org/licenses/by/4.0/>

Peer reviewed

## Photoradiation Therapy of Gynecologic Malignancies<sup>1</sup>

MARK A. RETTENMAIER, M.D., MICHAEL L. BERMAN, M.D., PHILIP J. DiSAIA,  
M.D., ROBERT G. BURNS, PH.D., M.D., AND MICHAEL W. BERNIS, PH.D.

*Department of Obstetrics and Gynecology, Division of Gynecologic Oncology, and Department of  
Developmental and Cell Biology, University of California, Irvine Medical Center,  
101 City Drive, Orange, California 92668*

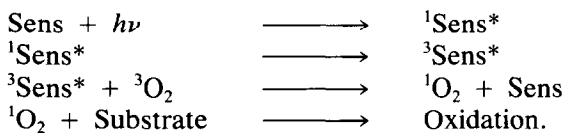
Received October 5, 1982

Four patients with gynecologic tumors recurrent either to the vagina or skin were treated with photoradiation therapy. A cytotoxic effect on the tumor was achieved by injecting hematoporphyrin derivative intravenously followed by exposing the treatment area to light of 630 nm from an argon-ion pumped-dye laser 72 hr later. Of seven tumor sites which were treated, one was completely destroyed, two were diminished in volume by more than 30%, and no response was seen in four. Toxicity was limited to one episode of facial edema and first-degree burn after prolonged exposure to bright artificial light. Phototherapy might be a useful treatment of some gynecologic tumors which recur after standard attempts at control of disease.

### INTRODUCTION

Many chemicals, when excited by visible light, can effect cytotoxicity [1]. This "photoradiation effect," which was first reported with eosin, has subsequently been demonstrated after light stimulation of a number of organic chemicals [2]. Crude hematoporphyrin was shown to cause regression of experimental gliomas in rats when activated by white light [3]. More recent work with hematoporphyrin derivative (HPD) has shown cytotoxic activity in a variety of other animal and human tumors while showing little toxicity to the host [4].

The intracellular cytotoxic agent produced by exposing tissue treated with HPD to light is known to be singlet oxygen, the metastable excited state of triplet molecular oxygen which is produced by the following series of reactions:



Where Sens is sensitizer (e.g., HPD), <sup>1</sup>Sens\* is the excited singlet state of the

<sup>1</sup> Supported in part by National Institute of Health Grants CA 32248, GM 23445, HL 15740, RR 01192, American Cancer Society Grant IN-120B, and University of California, Cancer Research Coordinating Committee Grant UCI-6485.

sensitizer,  $^3\text{O}_2$  is ground state triplet oxygen, and  $^1\text{O}_2$  is the excited singlet state of oxygen [5].

Light at wavelengths of 620 to 640 nm excites HPD to yield singlet oxygen [1]. Conventional and laser sources are capable of producing light with wavelengths in this range and have been used to treat animal and human tumors after infusion of HPD [6].

The initial cytotoxic effect of forming singlet oxygen in tissue is local vascular collapse with death of surrounding tissue occurring within hours [7]. Unfortunately, little is known about the intracellular location of photodynamic sensitizers, such as HPD; however, these compounds have been shown to concentrate in liposomes, mitochondria, and cell membranes [8–10]. Damage to these organelles by a photosensitizing chemical would contribute to cell death.

Hematoporphyrin derivative is selectively retained and concentrated in malignant cells after intravenous infusion. The mechanism for this preferential retention in neoplastic tissue is not understood completely; however, the difference in uptake between normal and malignant cells is sufficient to result in death of malignant cells with minimal injury to normal tissue after exposure to light [11].

The major limitation of "photoradiation therapy" (PRT) is the poor penetration of light through tissue. Consequently, most work in humans has been limited to treating malignancies near epithelial surfaces [1,4,6,7]. Many gynecologic tumors are "surface" malignancies and, therefore, accessible to PRT. We report our initial work using PRT in four patients with gynecologic cancers recurrent to epithelial surfaces.

## MATERIALS AND METHODS

Seven lesions were treated with PRT in four patients with gynecologic cancers recurrent either to the vagina or skin (Table 1). All patients had failed conventional attempts at control of their recurrent disease previously. Informed consent was obtained before PRT was initiated.

Hematoporphyrin derivative (HPD, Oncology Research and Development, Cheektowhea, New York) was given as an intravenous bolus at a dose of 3 mg/kg. All patients were instructed to avoid exposure to bright light for a 4-week period after its administration. Seventy-two hours later, the lesion and 2.0 to 4.0 cm of surrounding clinically uninvolved tissue were exposed to light of 630 nm provided by an argon-ion pumped-dye laser (Spectra Physics 375-50) delivering 800 mW with exposure times ranging from 280 to 480 sec. By individualizing these parameters for each lesion treated, the total light dose per lesion was calculated in joules/centimeter<sup>2</sup>. All PRT was given on an outpatient basis and follow-up examinations were performed at 24 and 72 hr and weekly thereafter.

## CASE PRESENTATIONS

### *Case No. 1*

A 73-year-old, Gravida 0, with Stage 1, Grade 2, endometrial adenocarcinoma underwent a total abdominal hysterectomy and bilateral salpingo-oophorectomy with selective pelvic lymph node sampling. The tumor which invaded more than 50% of the myometrium recurred 2 years later in the vaginal vault and was treated

TABLE 1  
 STUDY CHARACTERISTICS OF FOUR PATIENTS WITH RECURRENT GYNECOLOGIC CANCERS TREATED WITH PHOTORADIATION THERAPY

Diagnosis	HPD	Light dose (630 nm)	Result	Complications
1. Endometrial cancer recurrent to vulva and groin	3 mg/kg	40	Destruction of vulvar metastasis, persistence of groin metastasis	Edema and first-degree burn of face
2. Vaginal cancer recurrent to neovagina	3 mg/kg	Three overlapping 30-J fields	One-third reduction in tumor mass	None
3. Cervical cancer recurrent to vaginal apex	3 mg/kg	Two applications of 40 J separated by 24 hr	Necrosis of tumor surface	None
4. Vaginal cancer recurrent to skin of back	3 mg/kg	Two applications of 20 J separated by 24 hr	No change	None

with whole-pelvis radiation and one interstitial implant. After two additional years, the tumor recurred again in the vaginal vault and was treated with CT Provera. Progression of disease was observed in the vagina and multiple vulvar metastases developed. Chemotherapy was changed to Adriamycin and the symptomatic vulvar implants were treated with carbon dioxide laser vaporization. After a full course of Adriamycin had been administered, a regimen of Cytosan and *cis*-platinum was begun. The vulvar metastases recurred and a right-groin nodule was noted. Hematoporphyrin derivative was administered intravenously as described above. Seventy-two hours later, a right labial lesion and a nodule in the right groin were exposed to laser light at a total dose of 40 J/cm<sup>2</sup> each. Twenty-four hours later, both lesions were black and the surrounding skin was erythematous. One week after treatment, the labial lesion was necrotic, while the groin lesion had resumed its pretreatment appearance. Biopsy of both sites 1 month later showed no residual tumor at the labial location and persistence of a moderately differentiated adenocarcinoma in the groin. The patient had marked facial edema and first-degree burn lasting for 2 weeks following prolonged exposure to a dental operating light 48 hr after the injection of HPD.

#### *Case No. 2*

A 56-year-old, Gravida IV, Para III, with a verrucous carcinoma of the vagina was treated with a radical hysterectomy, upper vaginectomy, and pelvic lymphadenectomy. Three months later, a vaginal vault recurrence was discovered and treated with whole-pelvis external radiotherapy and one interstitial implant. Thirteen months later, the tumor again recurred and an anterior exenteration and vaginal vault reconstruction was performed. Despite these efforts, a third vaginal recurrence was discovered 20 months later. The histology of the tumor was unchanged and it extended from the introitus to the apex of the vagina along the left neovaginal sidewall. The patient was given HPD intravenously. Laser activation was performed in overlapping fields such that a minimal tumor light dose of 30 J/cm<sup>2</sup> was administered. Twenty-four hours later, the entire tumor was violaceous and the distal one-third was necrotic. Eight days after PRT, the distal one-third of the tumor had sloughed but the remainder appeared viable. No changes had been noted in nontumor tissue included in the light treatment fields.

#### *Case No. 3*

A 61-year-old, Gravida V, Para III, with a Stage IIIB carcinoma of the cervix was treated with whole-pelvis radiotherapy and brachytherapy. One year later, a vaginal vault recurrence was noted and a percutaneous needle biopsy revealed metastatic disease in the periaortic area. Eight courses of *cis*-platinum chemotherapy were administered, after which therapy was discontinued. There had been total tumor regression in the vaginal vault and a CT scan of the periaortic area no longer demonstrated adenopathy. Eight months later, however, a plaque of tumor measuring 3.0 × 3.0 × .5 cm was noted at the vaginal apex and *cis*-platinum therapy was reinstated but, because of renal toxicity, stopped after only four courses. Phototherapy of the persistent vaginal metastasis was performed. A light dose of 40 J/cm<sup>2</sup> was administered and because no change in the treatment

area was seen at 24 hr, the same light dose was repeated without administering further HPD. Necrosis of the tumor was apparent 48 hr later. Three weeks after PRT, no tumor was evident clinically; however, a biopsy of the vaginal apex revealed squamous cell carcinoma.

#### Case No. 4

A 67-year-old, Gravida III, Para II, was treated for carcinoma *in situ* of the cervix with a total abdominal hysterectomy and bilateral salpingo-oophorectomy in 1964. Fifteen years later, an undifferentiated carcinoma of the vaginal apex was diagnosed and treated with whole-pelvis and interstitial radiotherapy. A transvaginal biopsy of a pelvic mass and percutaneous biopsy of the periaortic area revealed recurrent tumor 16 months later. The patient was treated with eight courses of *cis*-platinum, after which three skin nodules appeared on the skin of the back. Aspiration revealed squamous cell carcinoma in all of the nodules. All three nodules were treated with PRT employing a light dose of 20 J/cm<sup>2</sup> to each. Because no change was seen at 24 hr, the light dose was repeated. Slight erythema and induration was evident in each treatment area 48 hr after the initial light application; however, there were no other changes suggesting a cytotoxic effect and aspiration of each area 3 weeks after PRT revealed persistent squamous cell cancer.

### DISCUSSION

Exploitation of subtle differences between cancer cells and normal cells has been responsible for major advances in radiation therapy and chemotherapy. Yet, some noncancer cells inevitably are damaged when these modalities are administered. A clinically useful cytotoxic agent specific for neoplastic tissue and without host toxicity is not currently a reality; however, photoradiation therapy (PRT) might approach this ideal because it can produce irreversible cell injury in malignant tissue while sparing adjacent normal tissues.

This manuscript describes a technique by which a nontoxic organic dye, hematoporphyrin derivative (HPD), is administered systemically and is selectively retained in neoplastic tissue over a period of days. Exposure of tissue containing this agent to light of the proper wavelength results in the intracellular liberation of singlet oxygen, an oxidizing agent, which produces cell death. Neoplastic cells are more susceptible to this photoradiation effect than normal tissue containing lower quantities of HPD in the same light field.

Activating light of precise wavelength and known power can be produced by laser sources. This light, when directed through fiber optic cables, can be focused on tumors arising from or metastasizing to epithelial surfaces. With several notable exceptions, such as ovarian cancer, most early and many recurrent gynecologic tumors are located on external surfaces and, therefore, are accessible to PRT. In the present pilot study, four patients with recurrent gynecologic malignancies were treated with PRT after conventional means to control their disease had been exhausted. Of the seven tumor sites treated, a vulvar metastasis of endometrial origin responded completely and two vaginal recurrences of cervical origin responded partially. No response was seen in a second cutaneous recurrence

of endometrial origin and in three cutaneous metastases of vaginal origin in one patient. Toxicity was limited to moderate edema and a first-degree burn of the face in one patient following prolonged exposure to a bright artificial light source.

No conclusion can be reached regarding the efficacy of PRT in the treatment of gynecologic malignancies from this initial study. The specificity for neoplastic tissue and minimal toxicity make PRT an appealing modality for treatment of a variety of cancers. Variables such as tumor size, location, and histology must be studied before an optimum response to treatment can be predicted. It is interesting to note that the best response to PRT in this study occurred in a small, superficial, labial recurrence of a moderately differentiated endometrial adenocarcinoma, whereas poorer results were seen after treatment of squamous cell recurrences ranging from a large, well-differentiated, verrucous cancer to small metastases of an undifferentiated vaginal tumor.

Photoradiation therapy might find future use as an alternative to local resection in patients who have failed standard therapies or who are considered poor surgical risks. Other possibilities might include presurgical shrinkage of large tumors and destruction of microscopic disease at surgical margins. Adaptation of laser light sources to the laparoscope and the hysteroscope might further extend the usefulness of PRT in gynecology. In an attempt to eliminate the only serious known side effect of systemic HPD administration, cutaneous photosensitivity, we have recently developed a form of HPD which can be applied topically. Animal studies have indicated selective retention of HPD in areas of induced squamous dysplasia after topical application of this compound (manuscript in preparation). We have initiated a pilot study of PRT in human vaginal and vulvar intraepithelial neoplasia after treatment with this local form of HPD and will report our results in the future. Further studies of the role of PRT in gynecologic cancer therapy should be encouraged.

## REFERENCES

1. Dougherty, T. J., Kaufman, J. E., Goldfarb, A., Weishaupt, K. R., Boyle, D. G., and Mittleman, A. Photoradiation therapy for the treatment of malignant tumors, *Cancer Res.* **38**, 2628-2635 (1978).
2. Tappenier, H., and Jesionek, A. Therapeutische versuche mit fluoreszierenden stoffe, *Muench Med. Wochschr.* **1**, 2042-2044 (1903).
3. Diamond, L., Granelli, S., McDonagh, A. F., Nielsen, S., Wilson, C. B., and Jaenicke, R. Photodynamic therapy of malignant tumors, *Lancet* **2**, 1175-1177 (1972).
4. Kelly, J. F., Snell, M. E., and Berenbaum, M. Photodynamic destruction of human bladder carcinomas, *Brit. J. Cancer* **31**, 237-244 (1975).
5. Weishaupt, K. R., Gomer, C. J., and Dougherty, T. J. Identification of singlet oxygen as the cytotoxic agent in photo-inactivation of a murine tumor, *Cancer Res.* **36**, 2326-2329 (1976).
6. Forbes, I. J., Cowled, P. A., Leong, A. S. Y., Ward, A. D., Black, R. B., Blake, A. J., and Jacka, F. J. Phototherapy of human tumors using hematoporphyrin derivative, *Med. J. Aust.* **2**, 489-493 (1980).
7. Dougherty, T. J., Lawrence, G., Kaufman, J. H., Boyle, D., Weishaupt, K. R., and Goldfarb, A. Photoradiation in the treatment of recurrent breast carcinoma, *J. Natl. Cancer Inst.* **62**(2), 231-234 (1979).
8. Allison, A. C., Magnus, J. A., and Yuoung, M. R. Role of lysosomes and of cell membranes in photosensitization, *Nature (London)* **209**, 874-878 (1966).
9. Lamola, A. A. *Research in Photobiology*, Plenum, New York (1977).

10. Berns, M. W., Dahlman, A., Johnson, F. M., Burns, R., Sperling, D., Gultiman, M., Siemens, A., Walter, R., Wright, W., Hammer-Wilson, M., and Wile, A. In vitro cellular effects of hematoporphyrin derivative, *Cancer Res.* **42**, 2325-2329 (1982).
11. Dougherty, T. J., Grindney, G. B., Fiel, R., Weishaupt, K. R., and Boyle, D. G. Photoradiation therapy II. Cure of animal tumors with hematoporphyrin and light, *J. Natl. Cancer Inst.* **55**, 115-121 (1975).